



Official Journal Issued by
Faculty of
Veterinary Medicine

Benha Veterinary Medical Journal

Journal homepage: <https://bvmj.journals.ekb.eg/>



Since 1990

Original Paper

Effect of moxifloxacin and role of vitamin E on antioxidant enzymes activity in rats

Gamal El-Din A.M. Shams¹, Suhair A. Abd El-Latif¹ and Samar I. Ghanem²

¹Pharmacology Department, Faculty of Veterinary Medicine, Zagazig University, Zagazig, Al Sharkia, Egypt.

²Alahrar Teaching Hospital, Zagazig, Al Sharkia, Egypt.

ARTICLE INFO

Keywords

Antioxidant activity

Histopathology

Moxifloxacin

Vitamin E

Received 11/11/2019

Accepted 20/05/2020

Available On-Line

08/09/2020

ABSTRACT

Our investigation was carried out to assess the protective impact of vitamin E against Moxifloxacin's possible adverse effects. Blood samples were collected at the 1st, 7th, 14th, 21st day after treatment. Collection of kidneys tissue samples was conducted at the 7th and 14th days after treatment. On Day 14 post-treatment with moxifloxacin, our results showed that there was multifocal hepatic necrosis of variable sizes that partially replaced by macrophages and occasionally with giant cells formation. The hepatic blood vessels were moderately congested, and the bile ducts were proliferated with characteristic portal round cells aggregation and portal fibrosis. Examined sections from kidney showed cystic dilatation of few tubules in the medulla and cortex of the kidneys. The renal pelvis revealed focal sloughing and hyperplastic changes in the transitional epithelium. Focal interstitial and perivascular aggregation of round cells and eosinophils were observed. The renal blood vessels were mildly congested. On Day 14 moxifloxacin and vitamin E; sections showed normal hepatic parenchyma with residual portal biliary proliferation and fibrosis. Minute focal hepatic necrotic areas partially replaced by round cells were also seen. Also, there were apparently normal nephron units with mild degenerative changes in some tubular epithelium and cyst dilatation in some renal tubules. Therefore, Vitamin E should be taken with moxifloxacin to decrease its adverse effects.

1. INTRODUCTION

Fluoroquinolones constitute a class of anti-microbials since they were presented in 1980. These anti-microbials show a wide range of antibacterial action including strong effects for Gram-negative aerobic and anaerobic living beings and also on Gram-positive and atypical pathogens (Oliphant and Green, 2002; Owens and Ambrose, 2005).

Fluoroquinolone anti-microbials are utilized in the medication of a wide number of bacterial diseases however are perceived as a gathering to be related with medicate actuated phototoxicity (Leone et al., 2003; Owens and Ambrose, 2005; Thompson, 2007; de Guidi, 2011).

The system of activity of fluoroquinolones is restraint of deoxyribonucleic acid (DNA) gyrase (topoisomerase II) and topoisomerase IV enzymes which are involved with bacterial DNA replication, translation, repair, and recombination (Thompson, 2007; Reus et al., 2012).

Moxifloxacin is considered as a contrasting option to - lactams and macrolides for the treatment of intense bacterial sinusitis and lower respiratory tract diseases (Thompson, 2007; Van Bambeke and Tulkens, 2009).

Among clinically created fluoroquinolones phototoxicity positions as takes after: sparfloxacin lomefloxacin > ciprofloxacin norfloxacin > ofloxacin > moxifloxacin (Oliphant and Gree, 2002; Owens and Ambrose, 2005).

Moxifloxacin is a fourth generation Fluoroquinolone antimicrobial operator, (at first called BAY 12-8039) and it is advertised worldwide under the brand name Avelox.

Moxifloxacin is a wide range anti-biotic that is dynamic against both Gram-positive and Gram-negative microorganisms. Moxifloxacin is a promising new agent that may have added substance movement to existing antituberculous agents by evaluating the action and wellbeing of moxifloxacin in the underlying phase of tuberculosis treatment (Committee of infectious diseases, 2006).

Fluoroquinolones (Moxifloxacin and Ciprofloxacin) cause arthrotoxicity in adolescent creatures and have been related with reversible musculoskeletal occasions in youngsters and adults. Other unfriendly impacts related with fluoroquinolones incorporate (focal sensory system, liver and kidney harmfulness, photosensitivity) (Committee of infectious diseases, 2006).

2. MATERIAL AND METHODS

2.1. Drugs and chemicals:

Moxifloxacin 400 mg (Avelox, IV, Future Pharmaceutical Industries)

Vitamin E 1000 mg capsule (Pharco Pharmaceutical Industries CO., Alex., Egypt) was dissolved in corn oil.

* Corresponding author: and Samar I. Ghanem, Alahrar Teaching Hospital, Zagazig, Al Sharkia, Egypt.

2.2. Animals

Eighty adult male albino rats weighted 150-200 g were used in the study. They were purchased from laboratory animal farm, Faculty of Veterinary Medicine, Zagazig University. They were housed in polypropylene cages in a temperature and humidity-controlled room. All animals were given access to food, water and libitum. They were kept for two weeks before being used to ensure stabilization.

2.3. Experimental design

Rats were classified into 4 groups each contain 20 rats. The 1st group (control) were not medicated and received normal saline. The 2nd group (vitamin E) received repeated oral doses of vitamin E (100 mg/kg BW), once daily, for successive 21 days as a standard antioxidant. The 3rd group (Moxifloxacin therapeutic dose) received a repeated oral, once daily, dose of moxifloxacin (7.2 mg/kg BW) for successive 21 days. The 4th group (Moxifloxacin and Vitamin E) received repeated, once daily, of Moxifloxacin (7.2 mg/kg BW) and Vitamin E (100 mg/kg BW) for 21 days (Paget GE, Barnes, 1964).

2.4. Preparation of serum and tissue samples

At the end of experiment (24 hrs after the last dose) rats were sacrificed and blood samples were collected in a sterile Wassermann tube without anticoagulant from 5 rats / group at the 1st, 7th, 14th and 21st days post treatment and allowed to clot for 30 minutes and serum was separated by centrifugation at 3000 rpm for 15 minutes. Serum was stored at -20 °C in Eppendorf tubes till the time of work for determination of serum level of antioxidant enzymes.

Liver and kidney of each rat were collected at 7th and 14th days post-treatment. They were isolated and kept in 10% phosphate-buffered formalin for histopathological examination.

2.5. Biochemical markers of antioxidant activity

The activities of catalase (CAT), superoxide dismutase (SOD), glutathione peroxidase (GPX) and Malondialdehyde (MDA) were determined (Aebi, 1984; Nishikimi et al., 1972; Pagila and Valentine, 1967, respectively).

2.6. Hepatic and renal histopathological evaluation

Liver and kidney tissues were settled in 10% formalin for 24 hrs at that point tissue handling and paraffin blocks preparation were done (Bancroft and Stevens 1982).

2.7. Statistical analysis.

The obtained data were statistically investigated utilizing prism version 6 except those histopathological scoring, were done by (ANOVA).

3. RESULTS

3.1. Effect of moxifloxacin, vitamin E and their combination on biochemical markers of antioxidant enzymes

3.1.1. CAT enzyme activity:

At the 1st day, there was an increase in catalase activity (200.91±2.34U/L) compared to (184.46±2.85 U/L) for the

moxifloxacin group. A critical elevation in the activity was recorded in the 7th day (208.99±5.27 U/L) compared to (193.40±1.91 U/L) for the moxifloxacin group. At the 14th day, there was an increase in catalase activity (221.06±3.83 U/L) compared to (208.50±1.36 U/L) for the moxifloxacin group. Finally, at the 21st day resulted in an increase in catalase activity (228.56±2.89 U/L) compared to (216.01±0.806 U/L) for the moxifloxacin group, as showed in table (1).

3.1.2. SOD activity:

At the 1st day, there was a significant increase in SOD activity (14.11±0.732 U/ml) compared to (9.21±0.490 U/ml) for the moxifloxacin group. A critical rise in SOD activity was recorded in the 7th day (19.39±0.871 U/ml) compared to (13.88±0.937 U/ml) for the moxifloxacin group. In the 14th day, there was an increase in SOD activity (20.88±0.698 U/ml) compared to (17.68±0.743 U/ml) for the moxifloxacin group. And finally, the 21st day resulted in an increase in SOD activity (22.95±0.187U/ml) compared to (20.26±0.738 U/ml) for the moxifloxacin group.

3.1.3. GPX concentration:

At the 1st day, there was a significant increase in GPX activity (97.73±1.40 U/L) compared to (85.08±2.49 U/L) for the moxifloxacin group. A critical elevation in GPX activity was recorded in the 7th day (108.13±4.52 U/L) compared to (92.62±2.69 U/L) for the moxifloxacin group. In the 14th day, there was an increase in GPX activity (114.72±2.57 U/L) compared to (99.78±2.43 U/L) for the moxifloxacin group. And finally, the 21st day resulted in an increase in GPX activity (119.00±3.97 U/L) compared to (110.39±2.96 U/L) for the moxifloxacin group.

3.1.4. MDA concentration

At the 1st day, there was a significant decrease in MDA activity (11.74±0.946 nmol/ml) compared to (17.28±0.590 nmol/ml) for the moxifloxacin group. A significant decrease in MDA activity was observed in the 7th day (8.49±0.290 nmol/ml) compared to (11.82±6.24 nmol/ml) for the moxifloxacin group. In the 14th day, there was a slightly decrease in MDA activity (7.82±0.326nmol/ml) compared to (7.78±0.544 nmol/ml) for the moxifloxacin group. And finally, the 21st day resulted in a slightly decrease in MDA activity (7.72±0.302 nmol/ml) compared to (7.35±0.289 nmol/ml) for the moxifloxacin group.

3.2. Histopathological results:

3.2.1. Moxifloxacin 7th day:

The examined liver revealed mild to moderate congestion of hepatic blood vessels with mild lymphocytic cellular aggregation and Kupffer cells hypertrophy with moderate aggregations of round cells in the portal triads. Renal tissues showed shrinkage and lobulation of some glomeruli. Focal interstitial round cells aggregations, Moderate congestion of the renal blood vessels and perivascular edema. Degenerative changes in a moderate number of renal tubules mainly cloudy swelling and hydropic degeneration were detected.

Table 1 The effect of vitamin E (100mg/kg, P.O. once daily), Moxifloxacin (7.2mg/kg, P.O. once daily) and their combination for 21 consecutive days on antioxidant enzymes of rats at 1st, 7th, 14th, and 21st days of drugs withdrawal

Days	Groups	CAT (U/L)	SOD (U/ml)	GPX (U/L)	MDA (nmol/ml)
1 st Day	Control	241.39±3.49	22.54±1.69	112.93±1.92	7.04±0.141
	Vitamin E	247.28±5.12	23.90±2.05	111.40±3.30	6.75±0.506
	Moxifloxacin	184.46±2.85	9.21±0.49	85.08±2.49	17.28±0.590
	Moxifloxacin + vitamin E	200.91±2.34	14.11±0.73	97.73±1.40	11.74±0.946
7 th Day	Control	233.77±2.47	20.91±1.19	116.91±0.96	7.11±0.522
	Vitamin E	235.01±4.91	22.58±0.85	113.51±1.45	7.52±0.343
	Moxifloxacin	193.44±1.91	13.88±0.93	92.62±2.69	11.82±0.624
	Moxifloxacin + vitamin E	208.99±5.27	19.39±0.87	108.13±4.52	8.49±0.290
14 th Day	Control	228.78±8.22	20.04±0.62	116.04±3.99	7.05±0.533
	Vitamin E	224.15±8.02	21.59±0.99	111.25±5.83	7.64±0.142
	Moxifloxacin	208.50±1.36	17.68±0.74	99.78±2.43	7.78±0.544
	Moxifloxacin + vitamin E	221.06±3.83	20.88±0.69	114.72±2.57	7.82±0.326
21 st Day	Control	229.69±5.25	21.58±0.92	118.48±2.75	7.43±0.076
	Vitamin E	227.58±5.06	21.78±0.40	114.60±4.82	7.66±0.163
	Moxifloxacin	216.01±0.80	20.26±0.73	110.39±2.96	7.35±2.289
	Moxifloxacin + vitamin E	228.56±2.89	22.95±0.18	119.00±3.97	7.72±0.302

Means (±SE, n=5) within the same column carrying different superscripts are significantly different at P<0.05.

3.2.2. Moxifloxacin 14th day:

Liver sections showed multifocal hepatic necrosis partially replaced by macrophages occasionally with giant cells formation. The hepatic blood vessels were moderately congested, and the bile ducts were proliferated with characteristic portal round cells aggregation and portal fibrosis. Examined sections from kidney showed cystic dilatation of few tubules in the medulla and cortex. The renal pelvis revealed focal sloughing and hyperplastic changes in the transitional epithelium. Focal interstitial and perivascular aggregation of round cells and eosinophils were observed. The renal blood vessels were mildly congested with mild perivascular edema.

3.2.3. Moxifloxacin +vitamin E 7th day:

Most of examined hepatic sections revealed apparently normal hepatic parenchyma with residual portal biliary proliferation, round cells infiltration and minute focal interstitial round cells aggregation. Examined renal sections showed apparently normal nephron units with mild degenerative changes in some tubular epithelium in the form of cloudy swelling and hydropic degeneration with cystic dilatation of few tubules in the cortex and medulla.

3.2.4. Moxifloxacin + vitamin E 14th day:

Hepatic sections showed normal hepatic parenchyma with residual portal biliary proliferation and fibrosis. Minute focal hepatic necrotic areas partially replaced by round cells were also seen. Most of examined renal sections showed apparently normal nephron units with mild degenerative changes in some tubular epithelium represented by cloudy swelling and hydropic degeneration with cystic dilatation of few tubules in the cortex and medulla.

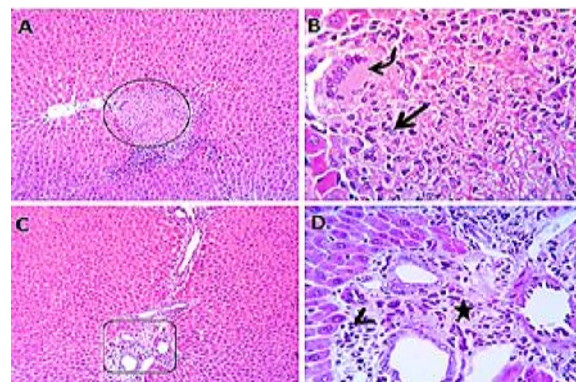
4. DISCUSSION

Antioxidants are substances that shown, at low concentrations, contrasted to those of an oxidizable substrate (e.g. proteins, lipids, carbohydrates and nucleic acids) altogether delays or suppress oxidation of that substrate (Halliwell et al., 1996).

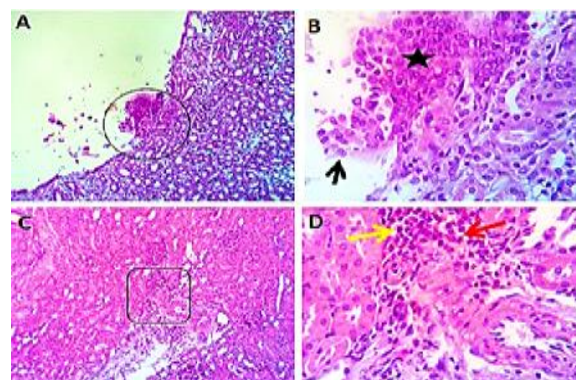
Reactive oxygen species (ROS) are constantly created as a metabolic item by basically all tissues in moderately small amounts. Every mammalian cells contain various

distinctive enzymatic and non-enzymatic antioxidants that serve to counteract or limit oxidative tissue damage.

The principal line of safeguard against oxidative insult are the antioxidant enzymes superoxide dismutase, catalase, and glutathione peroxidase. The non-enzymatic guards incorporate an assortment of low molecular weight scavenger, and reductants, and also a few different iron chelators (Halliwell et al., 1994).



Photomicrograph of Liver showing multifocal hepatic necrosis (circle), partially replaced by macrophages (arrow) and giant cells (curved arrow). Bile ducts proliferated (red arrow) with characteristic portal round cells aggregation (arrow-head) and fibrosis (star). Centro-lobular degenerative changes (curved red arrow) in some hepatic lobules and hypertrophied Kupffer cells (red arrow-head). H&E X 100 (A, C, E), 400 (B, D, F).



Photomicrograph of kidney showing focal sloughing (arrow) and hyperplastic changes (black star) in the transitional epithelium of pelvis, Focal interstitial and perivascular aggregation of round cells (yellow arrow) and eosinophils (red arrow). Some of the cortical and medullary tubules showing cyst changes. The renal blood vessels showing congestion (curved arrow) with mild perivascular edema. A few renal tubules showing degenerative and necrotic changes (curved red arrows). H&E X 100(A, C, E, G), 400 (B, D, F, H).

An extraordinary supporter of non-enzymatic assurance against lipid peroxidation is Vitamin E (vitamin E), a known free radical scavenger (Rikans et al., 1991). Vitamin E as a lipid solvent, chain-breaking antioxidant (Kagan et al., 1992) plays a critical defensive part against oxidative stress (Fraga et al., 1987) and prevents the creation of lipid peroxides by searching free radicals in biological membranes (Suga et al., 1984).

It has been suggested that free radicals created after medication by fluoroquinolones, assume a critical part in these antibiotics' toxicity (Martinez et al., 1998; Committee of infectious diseases, 2006; Thompson, 2007).

Numerous antioxidant enzymes, including superoxide dismutase (SOD), catalase (CAT), and glutathione peroxidase (GPx), are viable in evacuating destructive ROS. Lacking action of intracellular antioxidant enzymes can make damage to cell structures. Whenever unbalanced, it might prompt oxidation of polyunsaturated fatty acids in lipids, amino acids in proteins, and obliterate DNA (Finaud et al., 2006; Mari et al., 2010).

In this study, it has been observed that moxifloxacin causes critical changes in the activities of the antioxidant enzymes: SOD, CAT, and GPx in melanocytes. SOD ensures cells by dismutation superoxide anion into the pro-radical hydrogen peroxide, which thusly is inactivated to water and oxygen by catalase or other H₂O₂-evacuating enzymes such as glutathione peroxidase (Finaud et al., 2006).

Vitamin E is a lipid-solvent vitamin, of which α -tocopherol is the strongest. Vitamin E acts as an antioxidant in cells, intruding on the spread of lipid peroxidation in the plasma membrane and in this way safeguarding membrane integrity (Chow, 1991).

Very responsive molecules called free radicals can cause tissue damage by responding with polyunsaturated fatty acids in cell membranes, the degree of tissue damage is the consequence of the harmony between the free radicals created and the antioxidant protective defense system (Lawrence and Adrienne, 1987).

Vitamin E is the best lipid-dissolvable, chain-breaking antioxidant, shielding cell membrane from peroxidative damage. Free radicals have been involved in the improvement of degenerative sicknesses and conditions (Lester, 1991).

When the antioxidant defense in the human body becomes overwhelmed, oxidative stress to the parts frequently happens, initiating inflammatory, adaptive, and reparative procedures (Borut and Rok, 2014).

As of late, vitamin E is being widely examined because of its activity against oxidative stress (Kumar and Adarad, 1988).

Its defensive part on biological membranes are identified with its impact on delaying the side effects of aging (Enesco et al., 1980)

The in vivo function of vitamin E as an antioxidant has not yet been completely studied (Kumar and Adarad, 1988). Ongoing investigations have uncovered that vitamin E has an antioxidative activity in shielding cells from damage by highly responsive superoxide free radicals (Yoshioka et al., 1987).

Vitamin E normalized levels of catalase, superoxide dismutase, glutathione peroxidase, malondialdehyde and enhanced histopathological changes occur in liver and kidney induced by receiving of moxifloxacin. The possible pathway can be clarified through structure of Vitamin E,

the side chain in the 2-position encourages the consolidation and maintenance of vitamin E in bio films, with the goal that the 6-position is responsible for rummaging free radicals and ending lipid peroxidation. Antioxidant impact of vitamin E is shown through insurance of polyunsaturated fatty acids from oxidation by reactive oxygen species making adjustment of membrane and breaking of antioxidant chains that counteract responsive oxygen species harm to membrane.

In this study vitamin E administered at a dose of (100 mg/kg, P.O. once daily) to clarify the hepatic-nephroprotective effect on rats, we find a critical rise in the activities of anti-oxidative stress enzymes (SOD, CAT, GPX) besides a decrease in MDA activity.

Activities of ALT and AST are accepted marker of hepatocellular injury in human and animal models, Elevated plasma ALT and AST may be linked with membrane leakage of the hepatocyte cytosolic contents which is reflected in significant elevation of the plasma of rats treated with different doses of Moxifloxacin (Kumar and Adarad, 1988).

5. CONCLUSION

Moxifloxacin has an oxidative stress effect and could cause some histopathological changes in liver and kidney cells of rats. Vitamin E has a protective effect against Moxifloxacin's side effects. The combination of vitamin E and Moxifloxacin declared better results compared to Moxifloxacin alone.

CONFLICT OF INTEREST

The authors declare no conflict of interest.

6. REFERENCES

1. Aebi H. 1984. Colourimetric determination of catalase activity. *Methods Enzymol.*, 105: 121-126.
2. Bancroft, J.D.; Stevens, A. 1982. *Theory and Practice of Histological Techniques*. Churchill Livingstone. 2ed. London. p 41-59; 95-108.
3. Chow CK. 1991. Vitamin E and oxidative stress. *Free Rad. Biol. Med.*, 11: 215-232.
4. Committee of infectious diseases 2006. The use of systemic and topical fluoroquinolones" *AAP News and Journals*, volume 118 /issue3.
5. de Guidi G, Bracchitta G. and Catalfo A. 2011. Photosensitization reactions of fluoroquinolones and their biological consequences. *Photochem. Photobiol.*, 87:1214-1229
6. Enesco H. and Verdone E. S. 1980. α -Tocopherol increases lifespan in the rotifer *Philo-dina*. *Exp Gerontol.*, 15: 335-338.
7. Finaud J, Lac G. and Filaire E. 2006. Oxidative stress: relationship with exercise and training. *Sports Med.*, 36:327-358
8. Fraga CG, Arias RF, Llesuy SF, Koch OR. and Boveris A. 1987. Effect of Vit E-and se-lenium-deficiency on rat liver chemiluminescence *Biochem J.*, 242: 383-386.
9. Halliwell B. 1994. Free radicals and antioxidants: A Personal View *Nutr Rev J.*, 253-265.
10. Halliwell B. 1996. Vitamin C. Antioxidant or prooxidant in vivo? *Free Radical Res.*, 25: 439-454.
11. Kagan VE, Bakalova RA, Koynova GM, Tyurin VA, Serbinova EA. and Petkov VV. 1992. Antioxidant protection of the brain against oxidative stress. *Free Radicals in the Brain. Aging, Neurological and Mental Disorders*. (Eds.: L.

- Packer, L. Prilipko, Y. Christen) Springer-Verlag. Berlin. Pp:49-61.
12. Kumar De. and Adarad R. 1988. Physiological antioxidants and antioxidative enzymes in vitamin E-deficient rats. *Toxicology Letters*, 44: 47-54
 13. Lawrence J Machlin and Adrienne Bendich. 1987. Antioxidant protective defense against free radicals. *The FASEB Journal*, 1 (6): 441-445.
 14. Leone R, Venegoni M, Motola D, Moretti U, Piazzetta V, Cocci A, Resi D, Mozzo F, Velo G, Burzillieri L, Montanaro N. and Conforti A. 2003. Adverse drug reactions related to the use of fluoroquinolone antimicrobials. *Drug Saf.*, 26:109–120
 15. Mari M, Colell A, Morales A, von Montfort C, Garcia-Ruiz C. and Fernandez-Checa JC. 2010. Redox control of liver function in health and disease. *Antioxid Redox Signal*, 12:1295–1331
 16. Martinez LJ, Sik RH. and Chignell CF. 1998. Fluoroquinolone antimicrobials: singlet oxygen, superoxide anion and phototoxicity. *Photochem Photobiol.*, 67:399–403
 17. Nishikimi M, Roa NA. and Yogi K. 1972. Measurement of superoxide dismutase, *Bioch. Biophys. Res. Commun.*, 46: 849-85.
 18. Oliphant CM. Green GM. 2002. Quinolones: a comprehensive review. *Clin Pharmacol.*, 65: 455–464
 19. Owens RC. and Ambrose PG. 2005. Antimicrobial safety: focus on fluoroquinolones. *Clin Infect Dis.*, 41:144–147
 20. Paget GE. and Barnes JM. 1964. Evaluation of Drug Activities: Pharmacometrics. Laurence and Bacharach, Vol 1, Academic Press, New York. Pp. 133 - 166
 21. Pagila DE. and Valentine WN. 1967. Studies on quantitative and qualitative characterization of erythrocyte glutathione peroxidase. *J Lab Clin Med.* 70 (1):158-169.
 22. Reus AA, Usta M, Kenny JD, Clements PJ, Pruiboom-Bress J, Avlott M, Lynch AM. and Krul CA. 2012. The in vivo rat skin photomicronucleus assay: phototoxicity and photogenotoxicity evaluation of six fluoroquinolones. *Mutagenesis* 27:721–729
 23. Rikans LE, Moore DR. and Snowden CD. 1991. Sex-dependent differences in the effects of aging on antioxidant defense mechanisms of rat liver. *Biochimica. et Biophysica. Acta*, 1074: 195-200.
 24. Suga T, Watanabe T, Matsumoto Y. and Horie S. 1984. Effects of long-term vitamin E deficiency and restoration on rat hepatic peroxisomes. *Biochimica et Biophysica Acta*, 794: 218-224
 25. Thompson AM. 2007. Ocular toxicity of fluoroquinolones. *Clin Exp Ophthalmol.*, 35: 566–577
 26. Van Bambeke F. and Tulkens PM. 2009. Safety profile of the respiratory fluoroquinolone moxifloxacin: comparison with other fluoroquinolones and other antibacterial classes. *Drug Saf.*, 32:359–378.
 27. Yoshioka T, Motoyama H, Yamasaki F, Ando M, Takehara Y. and Yamasaki M. 1987. Lipid peroxidation and vitamin E levels during pregnancy in rats. *Biol Neonate.* 52: 223-231.