

## Laparoscopic appendectomy for perforated appendicitis; a comparison with open appendectomy

**Ziad Abdel Raouf Ismail<sup>a</sup>, Mohammed Abdel Shafy Mohamed<sup>a</sup>, Asmaa Gaber Rizk<sup>a</sup>, Mohamed Yousef Ahmed<sup>a</sup> and Hamdy Mohamed Hussein<sup>a</sup>**

<sup>a</sup>Department of general surgery, Qena Faculty of Medicine, South Valley University.

### **Abstract:**

**Background:** Perforated appendicitis is one of the common surgical emergencies which need immediate surgical intervention. For many years, the classic open appendectomy still seems to be the routine treatment of perforated appendicitis. The improvement of technology and an increase in laparoscopic experience have been central to the development of laparoscopic surgery. The aim of this study is to compare outcome of laparoscopic versus open surgery for surgical management of perforated appendicitis in our locality.

**Patients and Methods:** This is a prospective study that included 40 patients with perforated appendicitis admitted at general surgery department in Qena university hospital “between April 2018 to April 2019”, 20 patients underwent open appendectomy and 20 had laparoscopic surgery. All patients subjected to: full clinical evaluation, diagnostic modalities as: laboratory investigation, plain X-ray erect and abdominal sonography.

**Results:** All cases were completed successfully. A 20 patient underwent open conventional surgery their mean age  $29.80 \pm 7.32$  years. While those underwent laparoscopic surgery were 20 patients and their mean of age  $28.80 \pm 7.37$  years. There were statistically significant differences between studied groups regarding operative time, time to return to a normal diet, length of hospital stay and postoperative complications.

**Conclusion:** Laparoscopic surgery for perforated appendicitis is safe and carries many advantages of minimally invasive techniques. So, it should be used selectively, reserving the traditional open approach.

**Key words:** Perforated appendicitis, Treatment, Open, Laparoscopic, Peritonitis.

### **Introduction**

Appendicitis is the most common cause of abdominal pain and a prevalent reason for emergency surgery. The risk of developing appendicitis through lifetime is approximately 8.6% for male and 6.7% for female (Wang et al, 2019).

Of all the patients presenting with acute appendicitis, 13% to 20% have a perforated appendicitis. Men have a greater risk of

approaches: laparoscopic, and the classic approach, i.e. open appendectomy. Since its description by McBurney, open appendectomy has become the procedure of choice for acute appendicitis (Dai and Shuai, 2017).

The field of surgery has dramatically changed since the advent of laparoscopy (Spaner and Warnock, 1997).

Laparoscopic appendectomy was first introduced by Semm (Semm, 1983).

Nowadays, three quarters of the appendices are removed laparoscopically; however, the efficacy and superiority of the laparoscopic appendectomy has been under debate. The data favor laparoscopic appendectomy resulting in shortened hospital stay, lesser postoperative pain, quicker overall recovery, and lower rates of wound infections. Laparoscopic appendectomy over open appendectomy also benefits in a better visualization and identification of other abdominal pathologies that can mimic acute appendicitis (Pogoreliac et al, 2019).

However, Laparoscopic appendectomy for perforated appendicitis has gained only partial acceptance among many surgeons so, the role of LA in the management of perforated appendicitis remains controversial (Piskun et al, 2001).

So, we conducted this study to assess the efficacy of laparoscopic versus open appendectomy in perforated appendicitis.

#### **Patients and methods**

Patients received appropriate management of their septic condition, including resuscitative measures for shocked patients. Twenty patients underwent conventional open appendectomy for perforated appendicitis and 20 patients underwent laparoscopic appendectomy were evaluated prospectively.

All patients subjected to:

1. Complete clinical assessment including: Full history taking, Complete clinical examination.

2. Full investigations including: Complete blood count, Blood Sugar, Serum creatinine, Prothrombin time and concentration, Serum electrolytes level, Screening for HIV, HCV, and HBsAg, ECG.

3. Abdominal ultrasonography: For detection of appendix and site of perforation also, detection if there is periappendicular abscess and intraperitoneal fluid collection.

4. Plain x-ray abdomen erect position: May show appendiceal faecalith; gas in the appendix; air-fluid levels or distension of the terminal ileum as signs of inflammatory process in appendix.

#### **Randomization:**

Patients randomly classified into two groups by method of closed envelop each one included twenty patients, all these patients were consented (oral and written informed consent)

**The inclusion criteria:** patients with perforated appendicitis with age between 18-50 years old.

#### **The exclusion criteria are:**

- Patients with non-complicated appendicitis.
- Patients with appendicular mass.
- Hemodynamic instability despite hydration.
- Septic shock.
- Previous abdominal surgeries.
- Major medical co-morbidities.

Comparison was done between the 2 groups over a year postoperative for:

#### **a. Primary (main):**

Intra-operative complications, wound infection, postoperative pain scores, time to return to normal diet and time to return to work.

#### **b. Secondary (subsidiary):**

Operation time, hospital stay and incisional hernia.

#### **Operative technique:**

##### **1. Laparoscopic appendectomy: (fig. 1:3)**

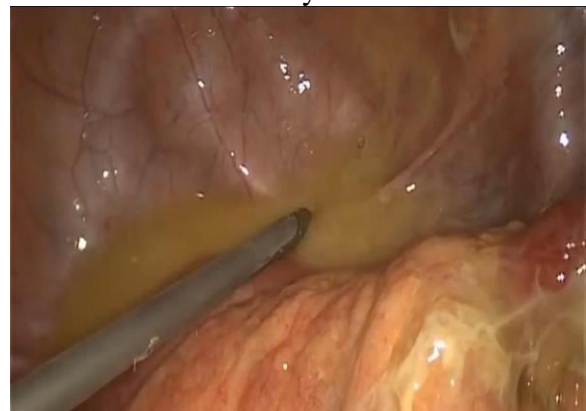The patient is supine with straight legs. The patient is secured to the bed to enable placement in moderate Trendelenburg position with a tilt to the left promotes easy shift of small bowel from the surgical field. A nasogastric tube and urinary catheter were inserted. The surgeon stands in the left

side of the patient. Pneumoperitoneum was established using CO<sub>2</sub> under pressure below 14 mm Hg. A 10 mm trocar was used for 30° view angle camera through the umbilicus and two further 5 mm ports were inserted one at left iliac fossa and the other at suprapubic region.

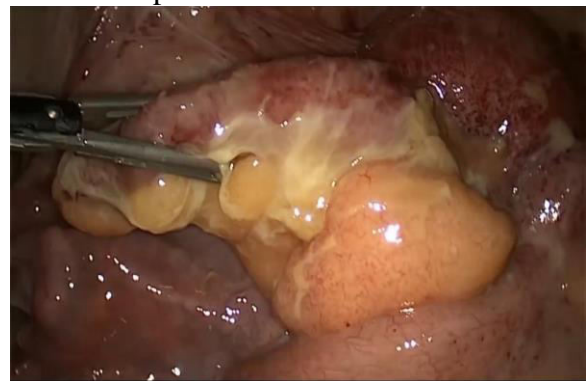
#### Steps of the Operation:

A stab incision is made at the lower aspect of the umbilicus and insertion of a 10 mm trocar then the first diagnostic inspection is made with camera of a 30° view angle in order to exclude any iatrogenic intra-abdominal injury and to explore the entire abdominal cavity for detection of any unexpected pathology, injury or any lesion, second stab incision is then made in the left iliac fossa under visual control and insertion of 5 mm trocar and third stab incision is made in suprapubic region for another 5 mm trocar. The patient is moved to lie in the head-down lateral position slightly displaced to the left. Through the magnifying laparoscope, fibrin deposits can be recognized in the lower abdomen. In addition, the whole lower abdomen including the parietal peritoneum are in a highly inflammatory condition and serosanguineous fluid can usually be seen in the area of the pelvis and caecal pole. Suction of the collection in pelvis and area of caecal pole was done then identifying the perforated appendix that covered by adhesions with omentum, caecum and terminal ileum and appears as a one mass. It is often possible to expose the site of perforation through gentle manipulation with caecum and adhesiolysis done by dissection with use of non-traumatic grasper forceps and harmonic energy device. Once anatomy is clearly visualized the appendix is grasped with a grasping forceps and skeletonization of the appendix is performed by traction on the mesoappendix with an atraumatic forceps. The mesoappendix including the appendicular artery is

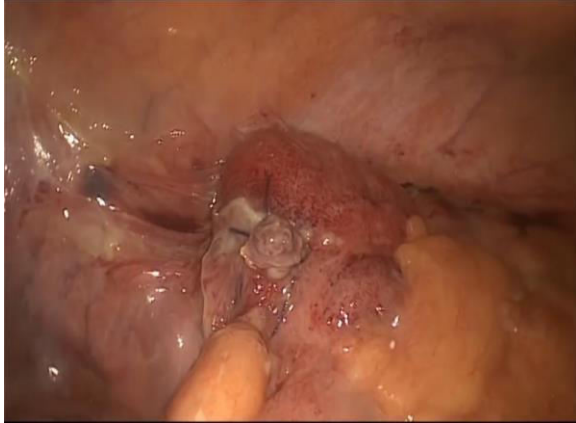coagulated with harmonic energy device until the base of the appendix is reached. The base of the appendix is ligated with extracorporeal knot using vicryl 2/0, then coagulation of base of appendix above the knot using harmonic energy device and then cut of appendix through the coagulation area by sharp scissors then the appendix will be placed in a plastic bag before removal through the port site. Intensive irrigation and aspiration of pelvis and site of operation at right iliac fossa by saline using suction device and good haemostasis was done. Insertion of plastic drain that placed in pelvis through left side working port then the instruments and the ports were removed. Telescope was removed. Closure of the wounds was done in layers.



(Fig. 1) Laparoscopic picture of suction of turbid intraperitoneal fluid collection.



(Fig. 2) Laparoscopic picture showing perforated appendicitis.



(Fig. 3) Laparoscopic picture showing stump of the appendix.

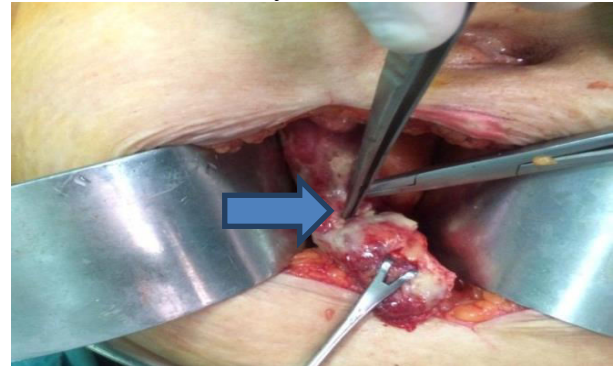
## 2. Open appendectomy: (fig. 4&5)

The patient placed in the supine position. Through gridiron incision or right paramedian incision (rarely used).

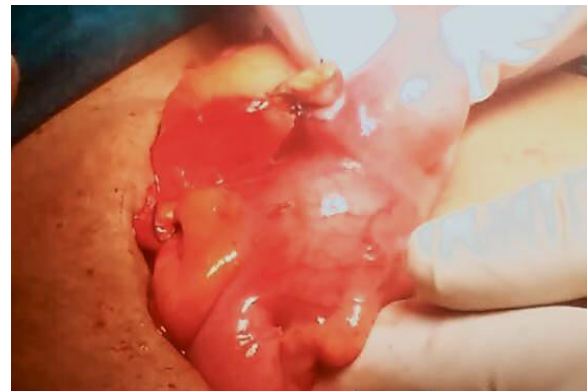### Steps of the Operation:

Following skin and subcutaneous fat incision, the external oblique sheath is incised and the muscles are split, then opening of the peritoneum and the appendix is identified by locating the caecum as the lateral most structure and following the Taenia Coli to the base of the appendix. The perforated appendix is covered by adhesions, adhesiolysis was done by gentle dissection and sometimes by sharp dissection until drainage of pus then suction of pus. Grasping of appendix by using babcock forceps and gentle traction to create a window in mesoappendix at the base of appendix which include the appendicular artery to ligate it using vicryl 2/0 suture and cut it and reaching to base of the appendix, then crushing the base of the appendix and clamped distal to the crushed area. The base of appendix is ligated using vicryl 2/0 suture and separated distally with a sharp knife. In case of a perforation at the base of the appendix, sutures should be used to close the caecal defect which should be applied prior to disconnection of the appendix. Peritoneal

lavage at field of operation and pelvis using saline, good haemostasis was done then insertion of pelvic drain then closure of abdominal wall in layers.



(Fig. 4) Open operative picture showing perforated appendix and site of perforation at head of arrow.



(Fig. 5) Open operative picture showing stump of the appendix post appendectomy.

### Postoperative care:

Removal of nasogastric tube and urinary catheter on first day postoperative. Postoperatively the patients were assessed to grade the pain severity and analgesic requirement. Pain severity was determined according to the following scale: 0= pain free, 1= pain only on touching the site of surgery, 2= pain with extensive movements, 3= pain with moderate movement, 4= pain with any movement at all and 5= pain requiring bed rest. Operative time in minutes and hospital stay in days were assessed. Nothing by mouth, giving intravenous fluids, broad spectrum antibiotic, proton-pump inhibitor and opioid analgesic was administered during the entire

postoperative hospital stay. After return of intestinal movement patient started liquid diet, and subsequently solid dietary meals were introduced.

#### Follow up:

Follow-up of patients with perforated appendicitis in outpatient clinic through: injection third generation cephalosporins antibiotic for three days after discharge (Table 1) antibiotic (Amoxicillin Clavulanate) tablet, oral metronidazole tablet, oral analgesic tablet and oral H2 blocker tablet. This treatment continued until removal of stitches.

#### Statistical Analysis

All patients had been analyzed using Statistical package for Social Sciences (SPSS).

#### Results

##### Age and sex of patients: (table 1)

Age			
Mean ± Standard deviation			P- Value
Classified		Overall	Open Vs Laparoscopic
Patients with open appendectomy	Patients with laparoscopic appendectomy		
29.80 ± 7.32	28.80 ± 7.37	29.40 ± 7.29	0.529
Sex			
(Total Number of each group n= 40 [20 open + 20 laparoscopic])			
Classified			Overall
Male	12 (60 %)	12 (60 %)	24 (60 %)
Female	8 (40 %)	8 (40 %)	16 (40 %)

Forty patients were admitted to emergency department at Qena university hospital with perforated appendicitis from April 2018 to April 2019 were included in our study, 20

patients underwent open conventional surgery their mean age ( $29.80 \pm 7.32$ ). While those underwent laparoscopic surgery their mean of age ( $28.80 \pm 7.37$ ). In both the laparoscopic group and the open group there were 12 males and 8 females. There was no significant difference in age and sex distribution.

#### (Table 1) Age and sex in both groups.

##### According to clinical data: (table 2)

The main clinical presentation was abdominal pain in both groups (40) patients; Generalized 17 in open group and 16 in laparoscopic group & localized in other patients.

Fever in 5 patients in open group and 4 patients in laparoscopic group.

Vomiting in 7 patients in both open and laparoscopic groups.

The duration of symptoms (in hours) preoperative in open repair was ( $19 \pm 8.08$ ) and in laparoscopic procedure was ( $19 \pm 8.08$ ).

#### (Table 2) Different symptoms before open Vs laparoscopic appendectomy + Mean duration of symptoms.

	Open appendectomy		Laparoscopic appendectomy		P- Value
	Frequency	Percentage	Frequency	Percentage	
Vomiting	7	35 %	7	35 %	0.742
Localized abdominal pain	3	15 %	4	20 %	0.362
Generalized abdominal pain	17	85 %	16	80 %	0.512
Sensation of fever	5	25 %	4	20 %	0.094

##### Mean ± Standard deviation [In Hours]

Duration of symptoms	19 ± 8.08	19 ± 8.08
----------------------	-----------	-----------

#### Operative time:

Unifactorial analysis demonstrated that operative time was significantly increased by choosing the open approach ( $80.90 \pm 10.37$ ) min rather than in laparoscopic group ( $67.90 \pm 15.23$ ) min.



### Post-operative follow up:

The number of narcotic injection used/day were significantly less in the laparoscopy group compared with the open surgery group ( $1.233 \pm 0.430$ ) doses vs. ( $4.3 \pm 0.75$ ) doses.

Time to return to a normal diet was also significantly shorter in the laparoscopy group ( $2.07 \pm 0.520$ ) days compared with open group ( $4.4667 \pm 0.8604$ ) days.

Mean Visual analogue score (VAS) of Pain at first day postoperatively is less in laparoscopic group than open group; P value (0.0003).

The duration of abdominal drainage was significantly shorter in the laparoscopy group ( $4.1 \pm 2.3$ ) days compared with open group ( $7.4 \pm 4.1$ ) days.

The length of hospital stay was significantly shorter in the laparoscopy group ( $5.43 \pm 1.34$ ) days compared with open group ( $8.67 \pm 2.52$ ) days.

Time to return to work (in days) shorter in laparoscopy group ( $16.334 \pm 5.812$ ) days compared with open group ( $26 \pm 12.9412$ ) days.

### As regard intra-operative and post-operative complications: (fig. 6)

One conversion from laparoscopy to open appendectomy due to extensive cecal adhesions interfering with mobilization of the appendix.

The postoperative complications were higher in the open group than the laparoscopic group and there was statistical significant difference between open and laparoscopic surgery.

One patient developed wound infection in laparoscopic group in comparison with 7 patients in open group, All wound infections were managed conservatively with dressings; P value (0.02).

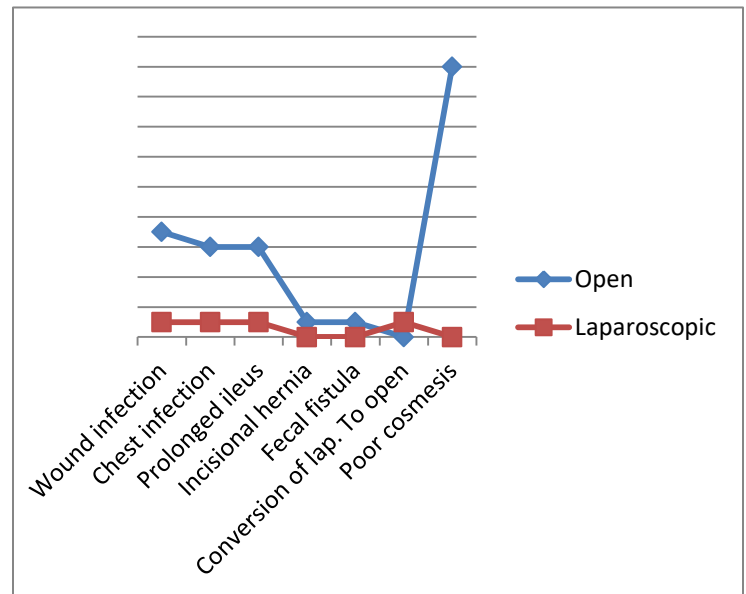
The incidence of chest infection and pneumonia increased in open group than in laparoscopic group 6 patients vs. 1 patient and all patients treated by antibiotics; P value (0.03).

Prolonged ileus post-operative more in open group than in laparoscopic group, 6 patients vs. 1 patient due to less manipulation of the intestine by laparoscopic technique; P value (0.03).

Post-operative incisional hernia occurred in one patient in OA (5%).

Fecal fistula was present in one patient who is the same patient presented after that by incisional hernia in OA (5%) 4 days after operation, managed conservatively and healed within 2 weeks.

Cosmeses more common in laparoscopic procedures due to small incision and less wound infection; P value (0.0001).



(Fig. 6) A line gram showing different post-operative complications for both open and laparoscopic groups.

### Discussion

Acute appendicitis is the most common reason for an urgent abdominal operation, with a lifetime incidence of 7%–15%. Each year, nearly 300 000 Americans are hospitalized for appendicitis (Davidson et al, 2017).

Of all the patients presenting with acute appendicitis, 13% to 20% have a perforated appendix. Men have a greater risk of perforation of the appendix (18%) than do women (13%) (Nazir et al, 2019).

Perforated appendicitis is associated with increased morbidity rates and longer hospital stay. In the same time, open surgery has problems such as surgical site infection, wound dehiscence, and incisional hernia. Therefore, seeking a laparoscopic surgery is warranted (**Talha et al, 2019**).

In the current study we aimed to compare the clinical outcomes of open appendectomy and laparoscopic appendectomy for perforated appendicitis among adult people over one year follow up, 40 cases divided into two groups laparoscopic group and open group with insignificant differences between two groups as regard demographic data, The mean age was 28.80 years in the laparoscopic appendectomy group and 29.80 years in the open appendectomy group, Both laparoscopic surgery group and open surgery group contained 12 male patients (60.0%) and 8 female patients (40.0%).

A study done by (**Muhammad et al, 2013**), conducted a similar study and reported that the mean age in the laparoscopic appendectomy group was  $32 \pm 14$  years; the mean age of patients in the open appendectomy group was  $34 \pm 13$  years.

In the current study we found that there was insignificant differences between two groups as regard time of pain started preoperative p-value 1.00

In agreement with our result (**Aziret et al, 2017**), showed that the durations of primary pain were  $37.9 (\pm 28)$  (8-120) minutes in the LA group and  $45.4 (\pm 38)$  (6-168) minutes in the OA group with insignificant differences.

In the current study as regard operative time there was significant longer time in open group p-value 0.003

In agreement with our result the mean operating time in both groups, the mean operating time for the laparoscopic surgery group was  $(46.98 \pm 2.99)$  minutes) which was significantly shorter than the  $(53.02 \pm 2.88)$  minutes) from the open surgery group ( $p < 0.000$ ) as shown by (**Nazir et al, 2019**).

However, our findings of shorter mean operating times via the laparoscopic approach align with studies by (**Tiwari et al, 2011**), who found a mean operating time for laparoscopic appendectomy were  $(47.8 \pm 14.5)$  minutes) and  $(49.10 \pm 12.5)$  minutes) for open appendectomy.

Moreover (**Aziret et al, 2017**), showed that the mean operation time  $(76.7 \pm 17.5)$  minutes) of the LA group was higher than that of the OA group  $(60.1 \pm 21.8)$  minutes) a statistically significant difference was found between the two groups with respect to this parameter ( $p=0.001$ ).

In our study we found that the number of narcotic injection used/day were significantly less in the laparoscopy group compared with the open group  $(1.233 \pm 0.430)$  doses vs.  $(4.3 \pm 0.75)$  doses; P value (0.00278).

Many studies have reported that patients who underwent LA had less postoperative pain and decreased need for analgesics (**Sauerland S et al, 2010; Cipe G et al, 2014**).

In our study time to return to a normal diet was also significantly shorter in the laparoscopy group  $(2.07 \pm 0.520)$  days compared with open group  $(4.4667 \pm 0.8604)$  days ; P value (0.00670).

There was earlier return of oral intake in LA than in OA but statistically insignificant as reported by (**Garg et al, 2009**).

In our results we found that the duration of abdominal drainage was significantly shorter in the laparoscopy group  $(4.1 \pm 2.3)$  days compared with open group  $(7.4 \pm 4.1)$  days ; P value ( $< 0.0001$ ), in agreement with our study (**Guller et al, 2004**) duration of drainage was significantly shorter in LA than OA.

In the current study we found that time to return to work and normal activities was also significantly shorter in the laparoscopy group  $(16.334 \pm 5.812)$  days compared with

open group ( $26 \pm 12.9412$ ) days ; P value (0.0012).

This explained by (Liu et al, 2017), as they showed that the impact of patient's pain on daily activities was also lower in laparoscopic group from the 8th to the 22th day after operation ( $P=0.01$ ).

On the other hand another study showed that there was no difference between the 2 groups with respect to the performance of routine daily activities and the limitation imposed by the surgery on such activities on day 1, day 2, day 3, and at 2 weeks postoperatively (Katkhouda et al, 2005).

In our study we found that postoperative complications were higher in open group than laparoscopic group with statistical significant difference.

One patient (5%) developed wound infection in laparoscopic group in comparison with 7 patients (35%) in open group, All wound infections were managed conservatively with dressings; P value (0.02).

The incidence of chest infection and pneumonia increased in open group than in laparoscopic group 6 patients vs. 1 patient and all patients treated by antibiotics ; P value (0.03).

Prolonged ileus post-operative more in open group than in laparoscopic group, 6 patients vs. 1 patient due to less manipulation of the intestine by laparoscopic technique ; P value (0.03), Post-operative incisional hernia occurred in one patient in OA (5%).

Fecal fistula was present in one patient who is the same patient presented after that by incisional hernia in OA (5%) 4 days after operation, managed conservatively and healed within 2 weeks.

In (Talha et al, 2019), regarding postoperative complications, ileus and wound-related complications were found to be higher in OA while intra-abdominal abscess (IAA) and chest infection were higher in LA but statistically insignificant.

Three cases of incisional hernia were encountered in the 2nd and 3rd postoperative months in OA. No mortality was recorded in either group.

According to (Aziret et al, 2017), showed that surgical-site infection was observed in a total of six patients among the two groups, occurring in five patients (13.9%) in the OA group and in one patient (1.3%) in the LA group. In these patients, wound cultures were taken, prophylactic antibiotics were started, and surgical-site care was administered until complete healing occurred. In a total of two patients (2.7%), incisional hernia was observed in the left trocar-site on the 3rd and 5th postoperative days. Also, among both groups, a major complication was observed in a total of one patient in the OA group. A partial pulmonary embolism was observed in one patient, who was admitted to the emergency room with breathlessness after the postoperative 15th day.

### Conclusion

Surgical repair is the main of treatment of patients with perforated appendicitis. Laparoscopic surgery for perforated appendicitis is safe and carries many advantages of minimally invasive surgery. So, it should be used selectively, reserving the traditional open approach for patients presenting with shock on admission. Laparoscopic surgical repair of perforated appendicitis is a safe and reliable procedure. It is associated with less postoperative pain, reduced chest complications, shorter postoperative hospital stay, earlier return to normal daily activities than the conventional open surgery and shorter mean operating time than an open appendectomy.



## References

**Aziret M, Çetinküner S, Erdem H, Kahramanca Ş, Bozkurt H, Dülgeroğlu O et al., (2017):** Comparison of open appendectomy and laparoscopic appendectomy with laparoscopic intracorporeal knotting and glove endobag techniques: A prospective observational study. *Turkish journal of surgery.* 33(4):258.

**Cipe G, Idiz O, Hasbahceci M, Bozkurt S, Kadioglu H, Coskun H et al., (2014):**Laparoscopic versus open appendectomy: where are we now. *Chirurgia (Bucur).* 109(4):518-22.

**Dai L, Shuai J (2017):** Laparoscopic versus open appendectomy in adults and children: a meta-analysis of randomized controlled trials. *United European gastroenterology journal.* 5(4):542-53.

**Davidson GH, Flum DR, Talan DA, Kessler LG, Lavalley DC, Bizzell BJ et al., (2017):**Comparison of Outcomes of antibiotic Drugs and Appendectomy (CODA) trial: a protocol for the pragmatic randomised study of appendicitis treatment. *BMJ open.* 7(11):e016117.

**Garg CP, Vaidya BB, Chengalath MM (2009):** Efficacy of laparoscopy in complicated appendicitis. *International journal of surgery.* 7(3):250-2.

**Guller U, Hervey S, Purves H, Muhlbaier LH, Peterson ED, Eubanks S et al., (2004):** Laparoscopic versus open appendectomy: outcomes comparison based on a large administrative database. *Annals of surgery.* 239(1):43.

**Katkhouda N, Mason RJ, Towfigh S, Gevorgyan A and Essani R (2005):**Laparoscopic versus open

appendectomy: a prospective randomized double-blind study. *Annals of surgery.* 242(3):439.

**Liu Y, Cui Z, Zhang R (2017):** Laparoscopic versus open appendectomy for acute appendicitis in children. *Indian pediatrics.* 54(11):938-41.

**Mohamed AA, Mahran KM (2013):** Laparoscopic appendectomy in complicated appendicitis: Is it safe?. *Journal of minimal access surgery.* 9(2):55.

**Nazir A, Farooqi SA, Chaudhary NA, Bhatti HW, Waqar M, and Sadiq A (2019):**Comparison of open appendectomy and laparoscopic appendectomy in perforated appendicitis. *Cureus* 11(7).

**Piskun G, Kozik D, Rajpal S, Shaftan G and Fogler R (2001):** Comparison of laparoscopic, open, and converted appendectomy for perforated appendicitis. *Surgical endoscopy.* 15(7):660-2.

**Pogorelic Z, Buljubasic M, Susnjar T, Jukic M, Pericic TP and Juric I (2019)**Comparison of open and laparoscopic appendectomy in children: A 5-year single center experience. *Indian pediatrics* 56(4):299-303.

**Sauerland S, Jaschinski T, Neugebauer EA (2010):** Laparoscopic versus open surgery for suspected appendicitis. *Cochrane Database of Systematic Reviews* (10).

**Semm K (1983):** Endoscopic appendectomy. *Endoscopy.* 15(02):59-64.

**Spaner SJ, Warnock GL (1997):** A brief history of endoscopy, laparoscopy, and laparoscopic surgery. *Journal of Laparoendoscopic & Advanced Surgical Techniques.* 7(6):369-73.

**Talha A, El-Haddad H, Ghazal AE and Shehata G (2019):** Laparoscopic versus open appendectomy for perforated appendicitis in adults: randomized clinical trial. *Surgical endoscopy*. 28:1-8.

**Tiwari MM, Reynoso JF, Tsang AW and Oleynikov D (2011):** Comparison of outcomes of laparoscopic and open appendectomy in management of uncomplicated and complicated appendicitis. *Annals of surgery*. 254(6):927-32.

**Wang D, Dong T, Shao Y, Gu T, Xu Y and Jiang Y (2019)**Laparoscopy versus open appendectomy for elderly patients, a meta-analysis and systematic review. *BMC surgery*. 19(1):54.