

REVIEW OF LITERATURE

Trematode granuloma in children

Vedhanayaki R, DO¹, Rathinam SR, FAMS, PhD¹

Introduction

Infection as the cause of uveitis is common in the developing world and the etiology differs depending on the regional variation¹. Such infections may be due to bacterial, viruses, fungal or parasitic causes². Parasites are organisms that acquire nutrition from the hosts they live on. Protozoa, helminths and ecto parasites are the main class of human parasites. Parasitic uveitis is more restricted to the tropical countries owing to the geography, culture, local environment and socio-economic status of the patients³.

Ocular parasitosis is infection caused by parasites that infect humans and cause ocular complications. The inflammation in the eye may be primarily due to the direct damage by the parasite and its released toxic products, or secondary to the reaction hosted by the body's immune system⁴.

Trematode, a group of flatworms, which belong to the helminth class, can cause food and water borne infections. These are multicellular organisms that are generally visible to naked eye in the adult stage. Trematode granuloma is one such water borne infection posing threat to children's vision bathing in the river contaminated with trematode infected snails. These children present with ocular inflammation after exposure to river water; the inflammation responds favourably if identified earlier and treated adequately.

Epidemiology

Helminthic infections are major public issues in developing countries. Lack of hygiene, poor public health education, and restricted medical access contribute to infectious diseases in these countries. The Southeast Asian and Indian subcontinent in particular are at risk for exposure to several foodborne and waterborne infections. But there is lack of epidemiologic investigations on parasitic diseases of

trematode origin in the area because of lack of awareness and screening programs.

The epidemiology of ocular parasitosis depends on the habitat of the infective organisms, their hosts and also the cultural status and the habits of the population. Trematode granuloma is caused by a water borne trematode which infects the snails in the fresh water. Humans are accidental hosts in their life cycle. The history in these patients usually starts with playing or swimming in the contaminated fresh water ponds in the river belts. Often there were cluster of children with similar presentation and also worsening of symptoms after taking bath in the pond every time. It is commonly seen in young boys above the age of 4 and less commonly in female children. This may be secondary to the cultural restriction on females to take bath in open water sources in that belt.

Cluster of such trematode granuloma cases were identified in several south Indian villages in Tamil nadu and Kerala and reported as early as 2001 by Rathinam et al⁵⁻⁶ and the etiological agent has been proven with molecular evidence more recently in 2012 as *Procerovum varium*⁷. Similar cluster was reported from different geographical locations along the basin of river Nile by R.M. Amin et al from Egypt with granulomatous anterior uveitis after swimming in the river⁸⁻⁹. Here again the etiological agent was proven by molecular diagnostics to be trematode. A single case report from Thailand reported in 2006, a worm from conjunctiva removed and proved to be *Philophthalmus* sp., a trematode that parasitizes the eyes of birds¹⁰. Similar case report of ocular infection by *Philophthalmus* was reported in Mexico also¹¹.

Life cycle

Several reports have identified adult worms in the conjunctival sac of birds¹². Some authors reported the

Correspondence to:

Professor Rathinam SR, FAMS, PhD

¹Department of Uvea, Aravind Eye Hospital and Post Graduate Institute of Ophthalmology, Madurai, Tamil Nadu, India

Email: rathinam@aravind.org

Full list of author information is available at the end of the article.

parasite as a trematode belonging to Procerovum Varium. When these birds come in contact with water the adult worms release the eggs. The eggs hatch into miracidia, and infect the snails, which act as intermediate host. These miracidia mature to form cercariae in the intermediate host which are snails, Melanoid Tuberculata. (Figures 1 & 2) These cercariae have to reach eyes of birds. Instead they reach human eye when these children swim in the pond where these infected snails live. Humans become accidental host if infected with the cercariae. Several other species of trematode (*F. hepatica*, *Schistosoma* sp. etc) infection has also been reported in human eye¹³. The cercariae of *Schistosoma* sp parasites are known to induce dermatitis in patients exposed to infested ponds or rivers. These cercariae die after they penetrate the skin; their death causes a localized inflammatory reaction.



Figure 1: Snail Melanoid tuberculata, first intermediate host of Trematodes

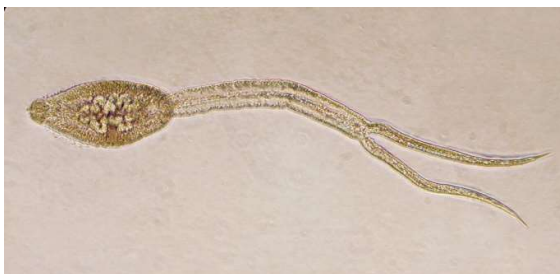

Figure 2: Cercaria released from the snails, can enter conjunctiva or the Cornea

Systemic manifestations

After swimming in the infested water, patients usually develop itching all over the body and swelling of the buccal and genital mucosa before the occurrence of ocular manifestations. These symptoms disappear on

Correspondence to:

Professor Rathinam SR, FAMS, PhD

¹Department of Uvea, Aravind Eye Hospital and Post Graduate Institute of Ophthalmology, Madurai, Tamil Nadu, India

Email: rathinam@aravind.org

Full list of author information is available at the end of the article.

their own and patients remember this event only on specific questioning.

Ocular manifestations

The cercariae of the trematode penetrate deep into the episclera and then develop subconjunctival granuloma (Figure 3). In few cases these cercariae can enter the anterior chamber through the limbal structures and develop anterior chamber granuloma with or without granulomatous uveitis. (Figure 4)

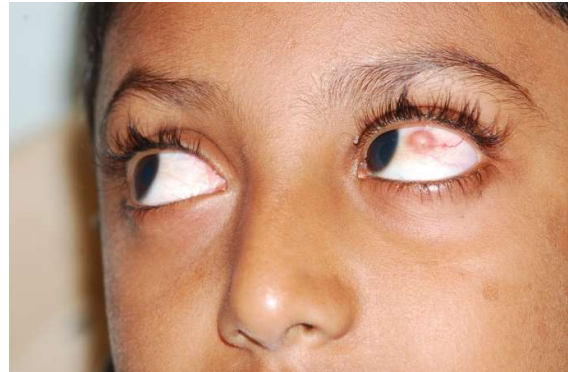

Figure 3: Sub conjunctival granuloma

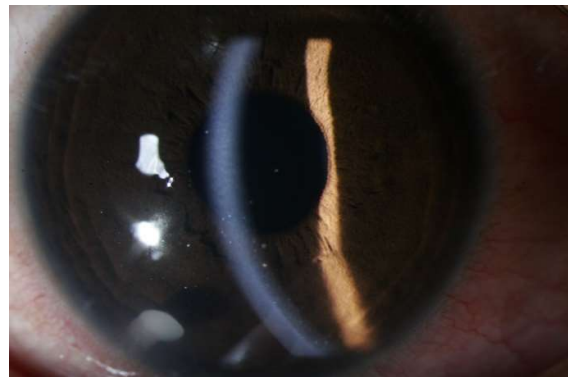

Figure 4: Single anterior chamber granuloma with granulomatous keratic precipitates

The presentation is usually unilateral. However bilateral involvement is seen in few cases. There may be more than one nodule and these nodules are usually 2-5 mm in diameter (Figure 5). They are mostly located in the retro-corneal surface in the inferior quadrant. There may be associated granulomatous Keratic precipitates and anterior chamber reaction (Figure 6). The granuloma is well circumscribed and white in colour. In case of sub conjunctival granuloma usually the lesion is in the palpebral area. Few patients can even present with granuloma in their lid mimicking a chalazia. Usually

©JORS

<http://jors.journals.ekb.eg/>

vision is good except for in cases where the recurrent inflammation causes complicated cataract or retro corneal membrane (Figures 7 & 8) secondary to the large AC granuloma which reaches the visual axis. Prolonged steroid use can cause cataract and glaucoma in few patients.

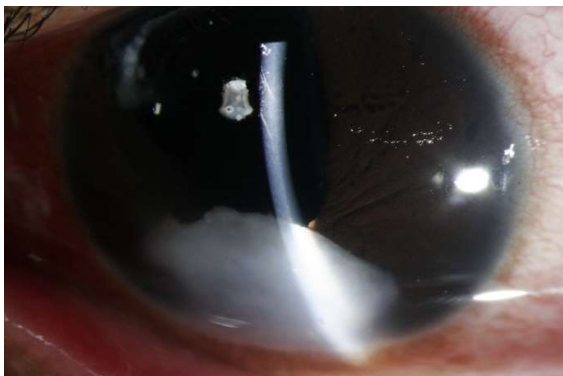

Figure 5: Two anterior chamber granulomas in same eye

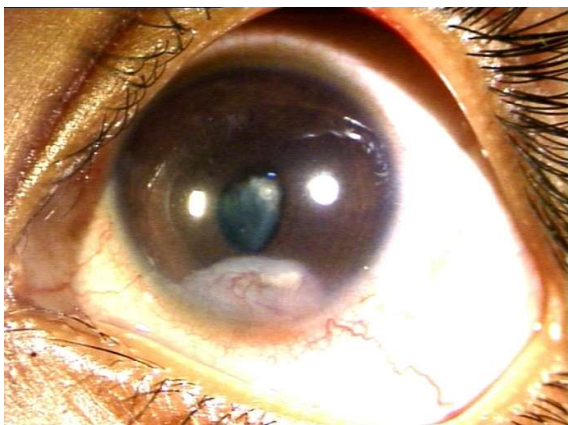


Figure 6: Highly vascularised retrocorneal membrane with complicated cataract

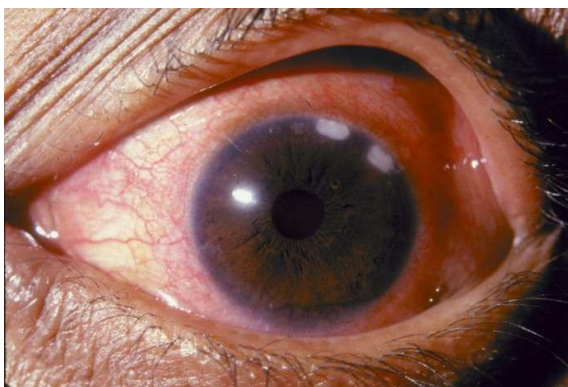

Figure 7: Dense retrocorneal membrane with peripheral anterior synechiae

Course of the disease

Usually smaller lesions resolve completely if identified earlier and treated with topical or oral steroids. Larger lesions can leave behind retro-corneal scars even after surgical removal. Complicated cataract can be seen in cases with repeated inflammation and in cases where treatment is not adequate. Very rarely, these nodules if left untreated can lead to phthisis of the eye due to recurrent inflammation.

Differential Diagnosis

Being a granulomatous disease, all the infectious and non-infectious causes of granulomatous uveitis has to be ruled out, even when there is a temporal association of taking bath in infected ponds. These include ocular tuberculosis, sarcoidosis, foreign body granuloma, fungal granuloma and Xanthelasma¹⁴. Occasionally ocular tuberculosis may closely mimic trematode granuloma. When there is no history of swimming, molecular diagnostics or histopathology may prove tubercular etiology.

Investigations

Based on the presentation, Complete blood count, Differential count, Mantoux, Erythrocyte Sedimentation Rate, serum ACE, Imaging of chest and abdomen need to be done.

The diagnosis of parasitic diseases is much more difficult when the patient is not a definite host but is instead an intermediate or accidental host; in such cases, fecal egg identification is of no use. Serum samples are also unreliable mainly because of cross-reactive antigens. Histopathology or molecular diagnostics can play a vital role in overcoming these obstacles and may lead to a precise diagnosis.

The cases where granuloma was larger it can be excised or aspirated. In case of anterior chamber granuloma it can be aspired through a paracentesis wound. It is a simple procedure with no complications in some patients. But when the lesion is highly vascularised it can cause severe bleeding. In addition, the disease being most common among children, it has to be done under general anaesthesia. Subconjunctival granuloma can be excised in toto. One has to be careful not to injure extra ocular muscles. The aspirate has to be sent for Bacterial and Fungal culture along with Hemotoxylin–Eosin

Correspondence to:

Professor Rathinam SR, FAMS, PhD

¹Department of Uvea, Aravind Eye Hospital and Post Graduate Institute of Ophthalmology, Madurai, Tamil Nadu, India

Email: rathinam@aravind.org

Full list of author information is available at the end of the article.

©JORS

<http://jors.journals.ekb.eg/>

staining, Periodic acid Schiff and Ziehl-Neelson staining to rule out other infective causes. Histopathology of the trematode granuloma usually reveals an inflammatory process made up of lymphocytes, neutrophils, and eosinophils mixed with histiocytes. The conjunctival nodule on histopathological analysis may show a necrotizing granuloma containing a tegument of trematode. Splendore-Hoeppli reaction can be seen in few cases where eosinophilic material can be seen surrounding or adjacent to the trematode¹⁵. It is not possible to visualize the teguments in all cases may be because the parasite structures disintegrate rapidly secondary to localised inflammatory reaction.

Molecular diagnostics is the investigation of choice in confirming the diagnosis in these patients. The samples can be tested with nested PCR that targets the MPB64 and 28S rDNA genes to rule out tuberculosis. The samples can be subjected to assays with targeting rDNA spanning the internal transcribed spacer (ITS) 2 sequence of the trematode with custom-designed primers. The real-time PCR-amplified products if analysed with bidirectional sequencing and BLAST analysis can identify the trematode upto the species level.

Treatment

Usually children with nodules less than 3 mm respond well to topical steroids. When the response is not adequate these patients can be started on oral steroids after ruling out other infectious causes. Oral steroids are usually started at the dose of 1mg/kg body weight and then tapered weekly.

Lesions larger than 3 mm in diameter usually need surgical intervention. Under general anaesthesia, the subconjunctival nodule can be completely excised. The anterior chamber nodule has to be reached through a paracentesis wound and aspirated.

These patients are then continued on oral and topical steroids till the inflammation settles. Constant watch has to be kept as there is always chance of recurrence when these patients indulge in water sports in the same water resources

Prevention

To educate the patients and their attenders regarding the chance of recurrence or worsening of clinical picture on indulging in swimming in same infected pond. This usually provides good response in reduction of the occurrence of cohort of new cases in the same belt. A

Correspondence to:

Professor Rathinam SR, FAMS, PhD

¹Department of Uvea, Aravind Eye Hospital and Post Graduate Institute of Ophthalmology, Madurai, Tamil Nadu, India

Email: rathinam@aravind.org

Full list of author information is available at the end of the article.

Knowledge Attitude Practice Study can be done in these areas to analyse the existing situation in the area and the awareness of the local population of the same. This will help in future planning on the health education in endemic areas. If possible to escalate the problem to the health resources department to clean the water beds which act as the nodal points for all these cases.

Author information

Dr. Vedhanayaki Rajesh, DO

Professor SR Rathinam, FAMS, PhD

¹Department of Uvea, Aravind Eye Hospital and Post Graduate Institute of Ophthalmology, Madurai, Tamil Nadu, India

Received Date: November 5, 2019

Accepted Date: May 26, 2020

Published Online: September 12, 2020

References

1. Rathinam SR, Cunningham ET Jr. Infectious causes of uveitis in the developing world. *Int Ophthalmol Clin.* 2000;40:137-52.
2. Sabrosa NA, Cunningham ET Jr, Arevalo JF. Ocular nematode and trematode infections in the developing world. *Int Ophthalmol Clin.* 2010;50(2):71-85.
3. Hoti SL, Tandon V. Ocular parasitoses and their immunology. *Ocul Immunol Inflamm.* 2011;19(6):385.
4. Amal R, Nimir, Ahmed Saliem. Ophthalmic Parasitosis: A Review Article. *Interdiscip Perspect Infect Dis.* 2012 Sept 16.
5. Rathinam S, Fritsche TR, Srinivasan M, et al. An outbreak of trematode-induced granulomas of the conjunctiva. *Ophthalmology.* 2001;108(7):1223-9.
6. Rathinam, Sivakumar R, Kim R, Usha and Narsing A. Rao. Presumed trematode-induced granulomatous anterior uveitis: a newly recognized cause of intraocular inflammation in children from south India *American Journal of Ophthalmology*, Volume 133, Issue 6, 773 – 779.
7. Lalan Kumar Arya, Sivakumar R. Rathinam, Prajna Lalitha. Trematode Fluke *Procerovum varium* as cause of ocular inflammation in Children. *Emerging Infectious Diseases.* Vol. 22, No. 2, February 2016.
8. Amin RM, Goweida M, Bedda A, Kamel A, Radwan A. Clinical Patterns and Causes of Intraocular Inflammation in a Uveitis Patient Cohort from Egypt. *Ocul Immunol Inflamm.* 2019;27(6):859-867.
9. A El Nokrashy, WA Samra, D Sobeih, A Lamin. Treatment of presumed trematode-induced

- granulomatous anterior uveitis among children in rural areas of Egypt - Eye, 2019 - nature.com.
10. Waikagul J, Dekumyoy P, Yoonuan T, Praevanit R. Conjunctiva philophthalmosis: a case report in Thailand. *Am J Trop Med Hyg* 2006; 74:848–9.
 11. Sarah G H Sapp, Rashed N Alhabshan, Henry S Bishop, Ocular Trematodiasis Caused by the Avian Eye Fluke *Philophthalmus* in Southern Texas, *Open Forum Infectious Diseases*, Volume 6, Issue 7, July 2019.
 12. Umadevi K, Madhavi R. Observations on the morphology and life-cycle of *Procerovum varium* (Trematoda: Heterophyidae). *Syst Parasitol.* 2000;46(3):215-25.
 13. Dalimi A, Jabarvandb M. Fasciola hepatica in the human eye. *Trans R Soc Trop Med Hyg.* 2005;99:798–800.
 14. Rathinam, S R, and Manohar Babu. “Algorithmic approach in the diagnosis of uveitis.” *Indian journal of ophthalmology* vol. 61,6 (2013): 255-62. doi:10.4103/0301-4738.114092.
 15. Read, Russell W. et al .Splendore-Hoeppli Phenomenon in the Conjunctiva: Immunohistochemical Analysis. *American Journal of Ophthalmology*, Volume 140, Issue 2, 262.e1 - 262.e7

Correspondence to:

Professor Rathinam SR, FAMS, PhD

¹Department of Uvea, Aravind Eye Hospital and Post Graduate Institute of Ophthalmology, Madurai, Tamil Nadu, India

Email: rathinam@aravind.org

Full list of author information is available at the end of the article.

©JORS

<http://jors.journals.ekb.eg/>