



EVALUATION OF DIFFERENT TECHNIQUES USED TO AVOID THE FORMATION OF DOG EAR AT LATERAL END OF MASTECTOMY SCAR

Ann Samy⁽¹⁾, Mahmoud Hemida⁽¹⁾, Moustafa Abo Elsouid,⁽¹⁾ Mohamed Hany⁽¹⁾, Rabie Ramadan⁽¹⁾

⁽¹⁾Department of Experimental and Clinical Surgery, Medical Research Institute, Alexandria University, Egypt

ABSTRACT:

Background: Following a standard mastectomy for breast cancer in obese and/or large sized breast patients, a fold of skin often persists at the lateral end of the scar lying at or above the bra line. The redundant skin, causes poor cosmetic results, interfere with wearing of external breast prosthesis and causes discomfort. We aimed to evaluate different techniques used to avoid the formation of dog ear at lateral end of mastectomy scar.

Patients And Methods: This study prospectively included 60 patients admitted to the department of surgery, Alexandria Medical Research Institute who were planned for modified radical mastectomy. Patients were randomly divided into 3 groups: Group 1 underwent fishtail technique, group 2 underwent tear drop technique and group 3 underwent modified suturing technique and were followed up for one month and three months post-operatively for determination of the presence of dog ear and patient's satisfaction regarding cosmetic outcome and comfortability.

Results: Incidence of dog ear in fish tail group patients was less than that for group 2 and group 3 yet the difference is not significant less (P 0.431). Patient satisfaction, doctor satisfaction and patient comfortability were significantly higher in group 1 than group 2 and 3 (P=0.046, 0.042 and 0.021 respectively).

Conclusion: Fishtail, teardrop and modified suturing techniques dealt well with the redundant skin lateral to mastectomy scar with no significant difference between the three techniques regarding dog ear incidence. While fish tail technique was significantly better in patient satisfaction, comfortability and doctor satisfaction than tear drop and modified suturing techniques.

Key Words: Breast cancer, Modified radical mastectomy, Mastectomy incision, dog ear, Cosmetic results.

INTRODUCTION

More than 1.6 million new cases of breast cancer are diagnosed worldwide each year making it the commonest female cancer worldwide. ⁽¹⁾ Surgery is the main line of treatment of breast cancer either breast conserving surgery or mastectomy. ⁽²⁾ Still up to half of all breast cancer patients undergo a

mastectomy as their primary surgical procedure. An additional group of patients goes on to completion mastectomy following unfavorable pathology results after initial breast-conserving surgery. ⁽³⁾

The oncological outcome is the first goal of breast cancer management, but the functional result and

reduction of morbidity are also the indicators for quality of operative treatment. ⁽⁴⁾ With the increasing interest in cosmetic out-come, more attention has been paid to optimize the mastectomy scar. ⁽⁵⁾ Following a standard mastectomy for breast cancer in obese and/or large sized breast patients, a fold of skin often persists at the lateral end of the scar lies at or above the bra line. Its actual incidence is unclear but appears to be a common clinical problem especially in the obese patients. Skin closure achieving a good functional and cosmetic result can be challenging ^(3,5,6)

Despite being a minor morbidity; dog ear not only have a bad cosmetic appearance, but it can cause irritation and interfere with arm movement, wearing a brassiere or fitting an external prosthesis causing long term complaint that may even require surgical correction. ^(4,7) Dog ear management is important in Egyptian patients owing to the high prevalence of female obesity reaching 39.5% in 2008. ⁽⁸⁾

There are many techniques to tackle dog ear during mastectomy, but few prospective studies to assess those techniques. Fish shaped incision is the most commonly prospectively studied technique in the largest number of studies. But tear drop incision and modified incision suturing were not evaluated enough in the past studies. This study aimed to evaluate three of the common,

easy and applicable techniques namely Y closure, tear drop incision and modified incision suturing used to avoid the dog-ear deformity at lateral end of mastectomy scar regarding the efficacy to prevent the formation of dog-ear and patient satisfaction (cosmetic outcome and comfortability in wearing a brassiere or external prosthesis).

PATIENTS AND METHODS

The study was conducted on 60 female patients with breast cancer who were indicated for modified radical mastectomy, admitted to the department of Experimental and Clinical Surgery, Medical Research Institute, University of Alexandria from June 2016 to February 2017. All patients were obese (body mass index BMI>35) and/or large-breasted (cup C or more). All patients were randomized (using sealed envelopes) pre-operatively into three groups, fishtail group, tear drop group and modified suturing group. Informed consent was obtained from all eligible patients. The study was approved by local ethical committee. All patients included in this study were subjected to complete history taking, full clinical examination (general examination, BMI and local breast examination), laboratory investigations including routine laboratory investigations, radiological investigations (breast imaging, ultrasound mammogram both breasts, ultrasound abdomen and pelvis, plain X-ray chest and CT if needed, plain X-ray spine and bone scan if indicated), design marking of the flaps according to the technique planned and were submitted to MRM.

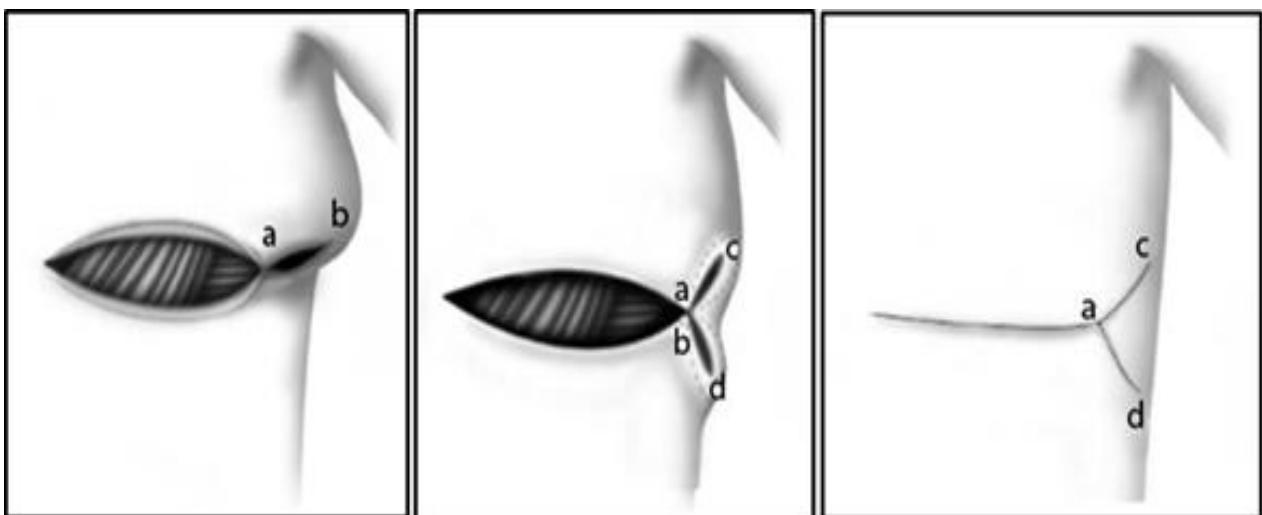
Group 1 underwent fish-tail plasty, after completion of MRM performed via a transverse elliptical incision. Start closing with the medial aspect of the wound initially, and then the skin at the lateral end of the mastectomy wound is sutured to the lateral of the anterior axillary line. The

stay suture converts the redundant skin fold into two areas which can be excised separately as two ellipses. Care must be taken to avoid narrowing the fish-tail base which carries the blood supply to the advanced skin; it should be at least 1.5 times the length of the two limbs of fish-tail plasty. After excising the redundant skin, the wound is closed as a Y or fish-tail plasty.⁽⁷⁾ (figure1)

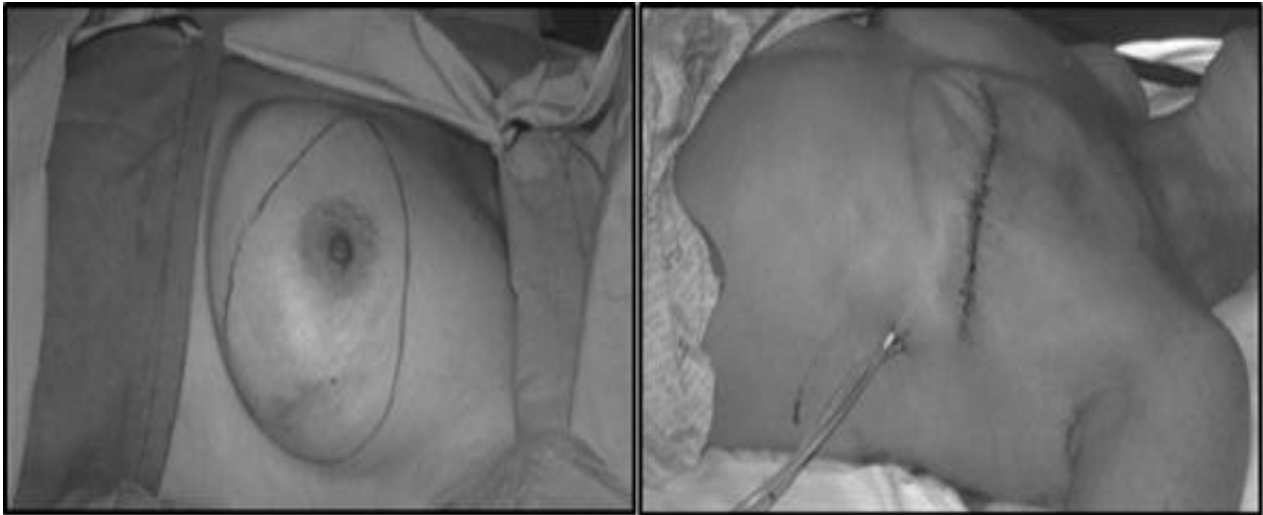
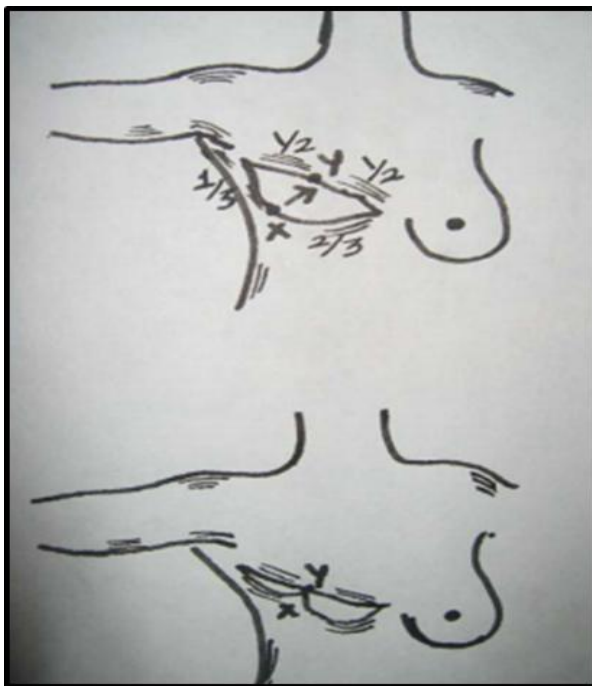
Group 2 underwent tear drop incision, the major axis of the breast base ellipse is established and the vertices of the ellipse are marked medially and laterally. The breast is retracted caudally with the flat of the hand and the two points are connected by a straight line. This is repeated with the breast retracted in acephalad direction. This results in a lentiform or teardrop shaped ellipse. The symmetry of the ellipse is then reconstituted and marked. The resultant mastectomy scar will be a straight line or have some lateral upward obliquity.⁽⁹⁾ (figure2)

Group 3 underwent modified incision suturing, after completion of MRM through elliptical incision, a point approximately one third of the way from the lateral apex along the inferior aspect of the incision is sutured to a point more medially on the superior flap. The lateral part of the incision can then be secured using dermal sutures, eliminating the dog-ear.⁽¹⁰⁾ (figure3).

All patients were followed up and evaluated immediately postoperatively, one month and three months postoperatively for determination of the presence of dog ear deformity at lateral end of mastectomy scar and Patient's satisfaction regarding cosmetic outcome and comfortability in wearing a brassiere or external prosthesis. A group of subjective points of assessment were used to evaluate the outcome of surgery by using questionnaire to all patients about the scar need any revision surgery and meeting the patients' expectations. And were categorized as follows very satisfied, satisfied, neutral, dissatisfied in the three studied groups. Also complications were recorded.



(Figure 1)⁽⁷⁾

(Figure 2)⁽⁹⁾(Figure3)⁽¹⁰⁾

STATISTICAL ANALYSIS

Data were fed to the computer and analyzed using IBM SPSS software package version 20.0. Qualitative data were described using number and percent. Quantitative data were described using range (minimum and maximum), mean, standard deviation and median. Significance of the obtained results was judged at the 5% level. The used tests were chi-square test: for categorical variables to compare between different groups, Fisher's

Exact or Monte Carlo correction: correction for chi-square when more than 20% of the cells have expected count less than 5 and ANOVA test (F test): for normally quantitative variables, to compare between more than two studied groups.

RESULTS

The study included 60 obese and/or large breasted female patients with breast cancer who were indicated for modified radical mastectomy, admitted to the department of Experimental and Clinical Surgery, Medical Research Institute, University of Alexandria divided into three comparable groups. The studied preoperative and operative data as shown in table (I) included age, BMI, medical comorbidities (diabetes mellitus, hypertension), breast size, tumor location and operative time ($P= 0.806, 0.406, 0.622, 0.760, 0.762, 0.362$ and 0.343 respectively). There was no statistical significant difference regarding preoperative data between the three studied groups. The studied postoperative data as shown in table (II) included hospital stay, wound complication, length of scar, patient satisfaction, doctor satisfaction and patient comfortability). With no statistical difference between three groups regarding hospital stay, wound complication and scar length ($P=0.511, 0.499$ and 0.528). Incidence of dog ear in fish tail group was less than in the other two groups [2 (10%), 3 (15%), 3 (15%) respectively] yet the difference was not significant ($P 0.98$). The sums of the very satisfied and satisfied in the three groups were 19 (95%), 12 (60%) and 12 (60%) respectively, with a significant increase in fish tail group than the other two groups. Figures 4-6 show examples of different studied techniques.

Table (1):- Comparison between the three studied groups according to the pre-operative data.

	Group I (n=20)		Group II (n=20)		Group III (n=20)		P
Age (years)							
Range	40.0-70.0		38.0-70.0		38.0-68.0		0.806*
Mean	52.15		53.85		53.30		
S.D.	7.76		9.14		8.05		
Median	55.0		54.0		56.0		
BMI (kg/m²)							
Range	35.20-41.80		35.20-41.80		35.40-41.60		0.406*
Mean	38.62		38.43		39.28		
S.D.	2.10		2.31		1.82		
Medical comorbidities	No.	%	No.	%	No.	%	
Diabetes Mellitus	13	65.0	11	55.0	10	50.0	0.622**
Hypertension	9	45.0	9	45.0	7	35.0	0.760**
Breast size	No.	%	No.	%	No.	%	
C	12	60.0%	10	50.0%	12	60.0%	0.762**
More than C	8	40.0%	10	50.0%	8	40.0%	
Tumor location	No.	%	No.	%	No.	%	
UOQ	5	25.0	4	20.0	5	25.0	0.362**
UIQ	3	15.0	5	25.0	4	20.0	
Central	4	20.0	3	15.0	3	15.0	
LOQ	5	25.0	4	20.0	5	25.0	
LIQ	3	15.0	4	20.0	3	15.0	

BMI: body mass index, **UOQ:** upper outer quadrant, **UIQ:** upper inner quadrant, **LOQ:** lower outer quadrant,

LIQ: lower inner quadrant.

* Analysis of variance test

** Chi-square test

Results are considered significant if P< 0.05

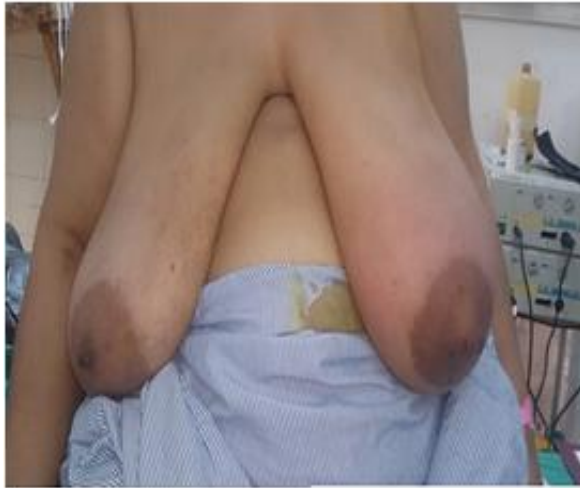Table (2):- Comparison between the three studied groups is according to the post-operative data.

	Group I (n=20)		Group II (n=20)		Group III (n=20)		P
Hospital stay (days)							
Range	1-3		1-3		2-3		
Mean	2.1		2.25		2.6		0.511*
S.D.	0.35		0.39		0.22		
Wound complications	No.	%	No.	%	No.	%	
<i>No complication</i>	14	70.0	15	75.0	14	70.0	0.521**
<i>Complication:</i>							
Dog ear	2	10.0	3	15.0	3	15.0	0.98**
Wound infection	3	15.0	2	10.0	2	10.0	0.98**
Dehiscence	2	10.0	1	5.0	0	0.0	0.78**
Flap necrosis	2	10.0	1	5.0	1	5.0	0.89**
Seroma	5	25.0	4	20.0	5	25.0	0.97**
Length of scar (cm)							
Range	4.0-8.0		5.0-9.0		6.0-10.0		0.528*
Mean	6.54		7.65		8.22		
S.D.	1.72		1.69		1.98		
Patients satisfaction	No.	%	No.	%	No.	%	
Very satisfied	11	55.0	5	25.0	6	30.0	
Satisfied	8	40.0	7	35.0	6	30.0	0.046**
Neutral	1	5.0	6	30.0	3	15.0	
Unsatisfied	0	0.0	2	10.0	5	25.0	
Doctor satisfaction	No.	%	No.	%	No.	%	
Very satisfied	12	60.0	6	30.0	7	35.0	
Satisfied	8	40.0	8	40.0	7	35.0	0.042**
Neutral	0	0.0	5	25.0	5	25.0	
Unsatisfied	0	0.0	1	5.0	1	5.0	
Patients comfortability	No.	%	No.	%	No.	%	
Very good	12	60.0	6	30.0	5	25.0	
Good	7	35.0	6	30.0	6	30.0	
Fair	1	5.0	7	35.0	4	20.0	0.021**
Poor	0	0.0	1	5.0	5	25.0	

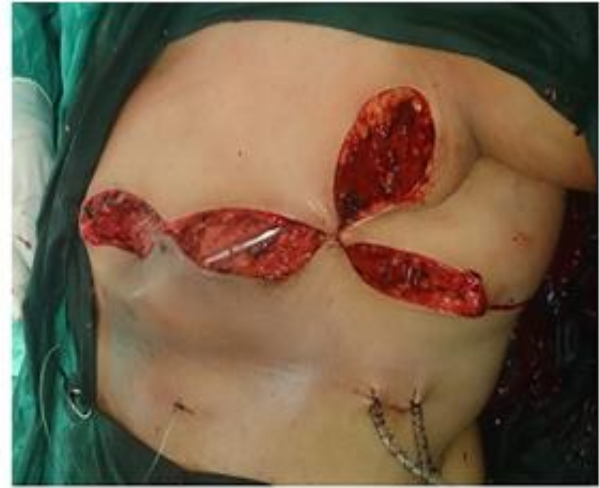* Analysis of variance test

** Chi-square test

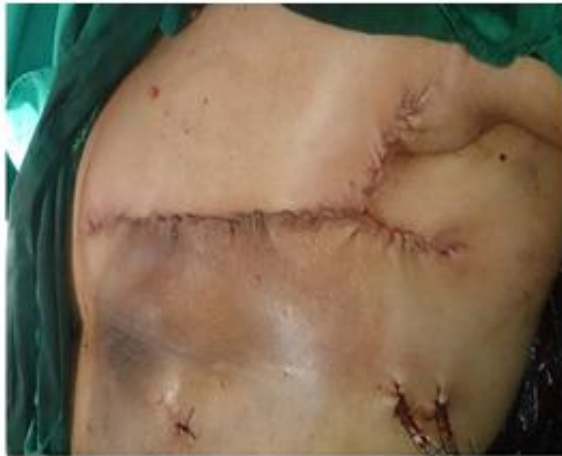Results are considered significant if P< 0.05



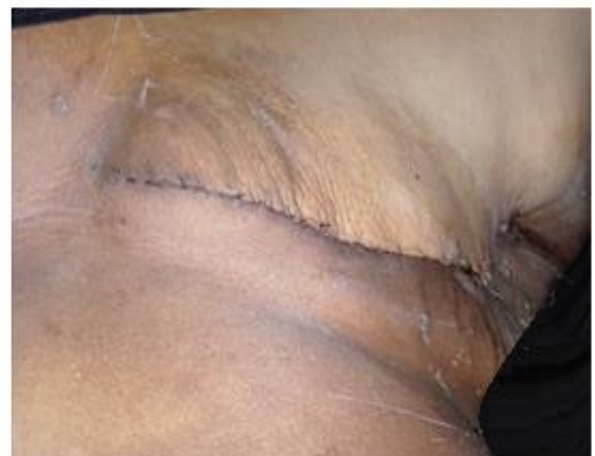(a)



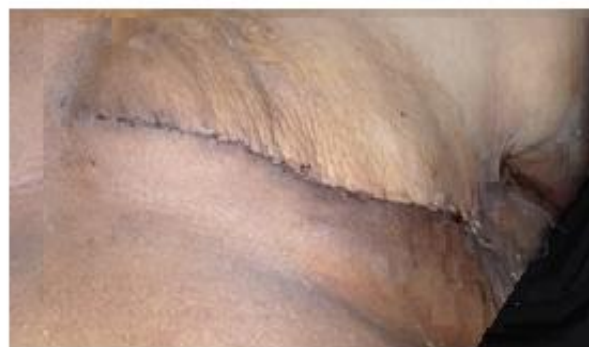(b)



(c)



(d)



(e)

Figure 4:- 59 years old ♀ patient with left breast cancer, BMI=40, cup size D, underwent MRM with fish tail plasty. (a) preoperative picture, (b) intraoperative picture, (c) immediate postoperative picture, (d) one month follow up picture, (e) three months follow up picture.

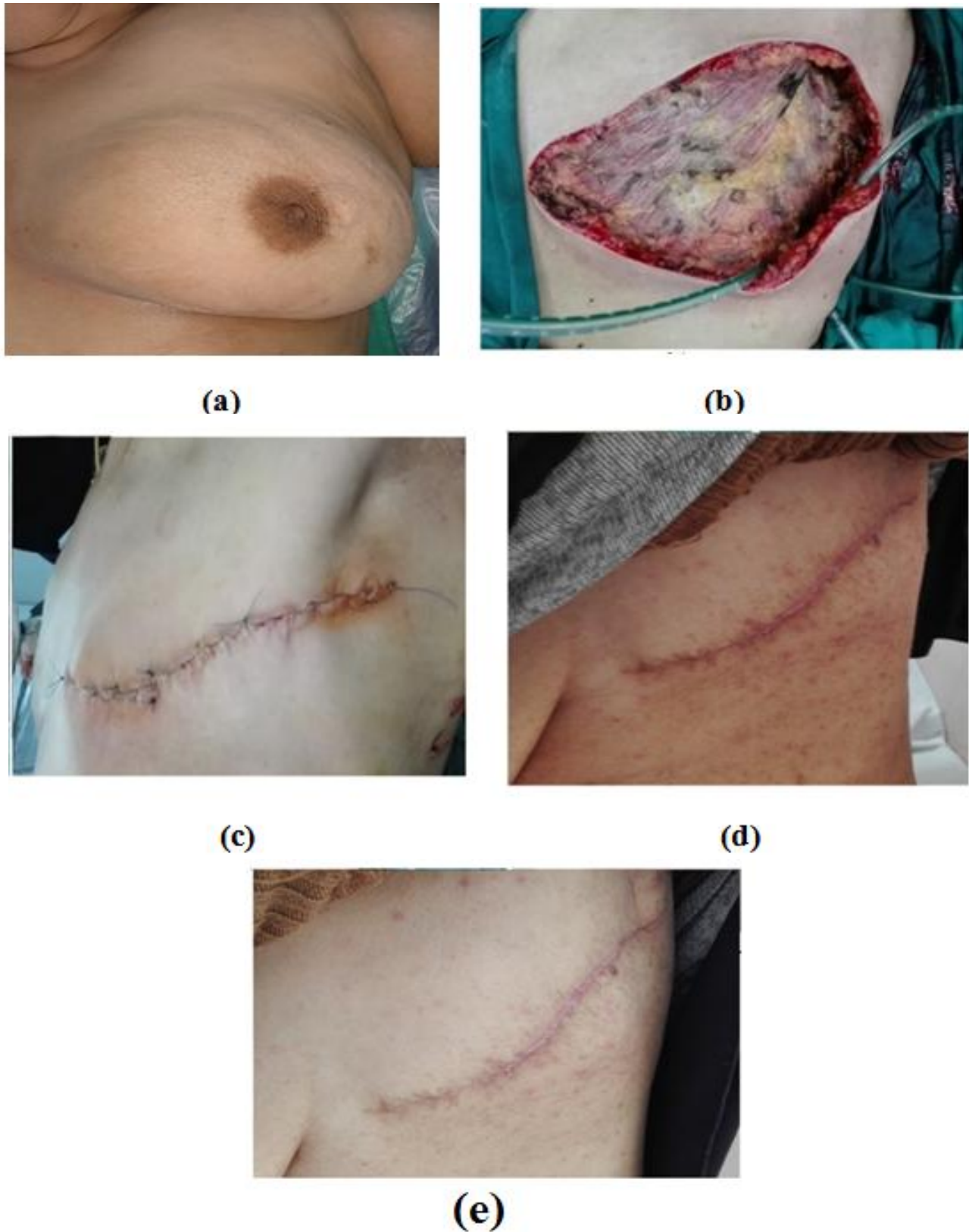
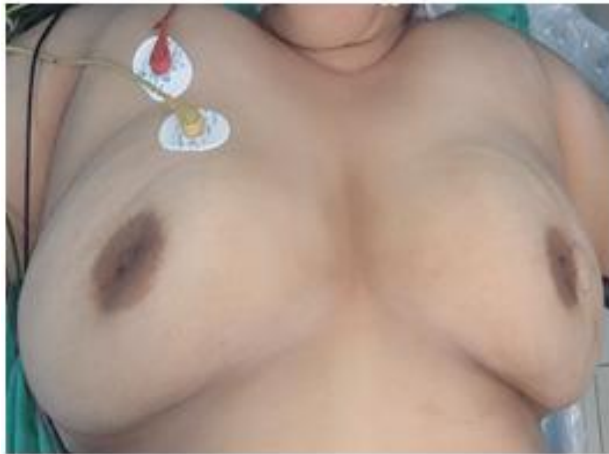
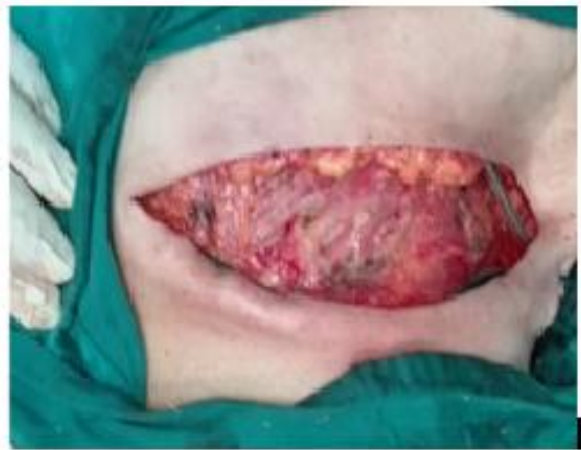
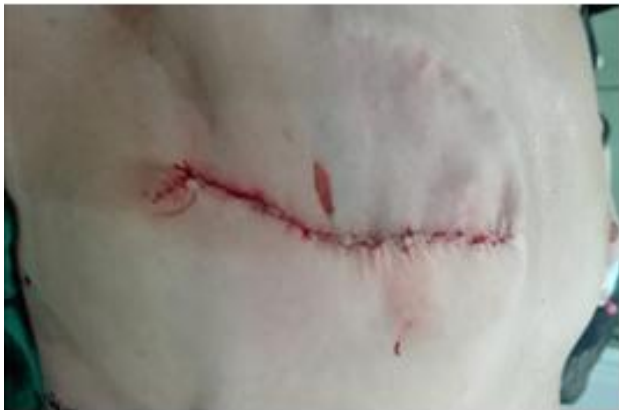Figure (5): 62 years old ♀ patient with left breast cancer, BMI=38, cup size C, underwent MRM with tear drop technique. (a) preoperative picture, (b) intraoperative picture, (c) immediate postoperative picture, (d) one month follow up picture, (e) three months follow up picture.



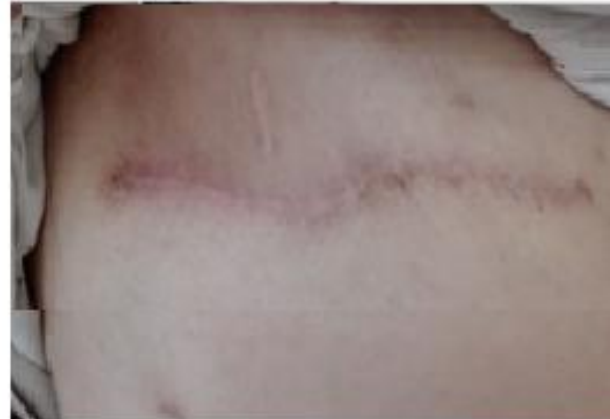(a)



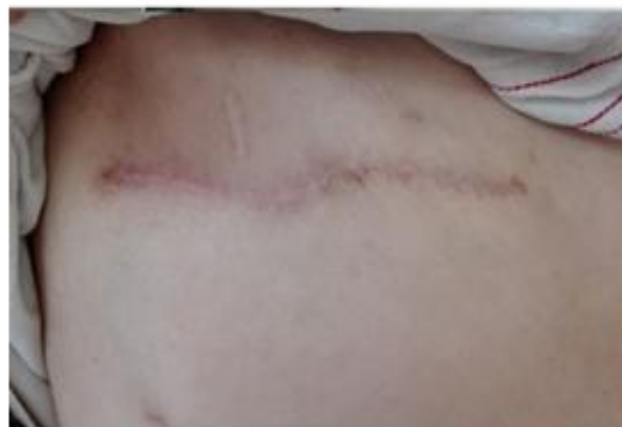(b)



(c)



(d)



(e)

Figure (6):- 49 years old ♀ patient with right breast cancer, BMI=35, cup size C, underwent MRM with lateral one third point of the lower flap to the middle of the upper flap. (a) preoperative picture, (b) intraoperative picture, (c) immediate postoperative picture, (d) one month follow up picture, (e) three months follow up picture.

DISCUSSION

Breast surgery deal with important part of the body of female, the scar of the breast operation is psychological more than physical. Both the cosmetic and functional results can be impaired by presence of dog ear which is neither aesthetically pleasing nor comfortable. It can be a great concern to the patient and a source of long-term complaint that may even require surgical correction. A surgeon who pays attention to prevent this problem will have a much happier patient after this procedure. It is the breast surgeons' responsibility to remove the excess fat pad during mastectomy, thereby avoiding a lateral dog ear, the need for further surgery and ensuring optimal patient comfort.⁽¹¹⁾

In Our study Fishtail, teardrop and modified suturing techniques were effective in prevention of formation of dog ear at the lateral end of mastectomy scar with no significant difference between the three techniques. Patient satisfaction, comfortability and doctor satisfaction were significantly better in the fish tail group in than the other two groups tear drop and modified suturing. While there is no statistical difference between the three groups regarding incidence of dog ear. In our study dog ear remained after correction in two cases (10%) in fish tail technique group, one due to inadequate excision of redundant skin after the stay suture taken between the lateral end of the scar and the point of the flap at the anterior axillary line, the other because of dehiscence of the anchoring suture to the chest wall. While Szynglarewicz reported zero incidence of lateral dog ear deformity in all his study cases using fish tail technique.⁽⁴⁾ Three cases (15%) developed dog ear in tear drop technique group in our study as a result of inadequate excision the fat pad in the lateral broader of the incision. However R. Thomas *et al*, reported good long term elimination of the lateral dog ear in 20 patients using teardrop method.⁽³⁾ three cases (15%) in modified suturing technique in our study developed dog ear due to length discrepancy between the lateral aspect of the superior and inferior incision and also because the technique was novel for the operating surgeons. In our study incidence of dog ear was more in group three, still not significantly higher. None of the eight patients in our study who had dog ear asked for any further correction. May be our study had more incidences of dog ears because our entire sample was of obese patients and/or of large breast sized which increases the probability of dog ear formation.

Generally speaking; following mastectomy the incidence of surgical site infection was found variable. The incidence of infection in the three techniques used in our study was three cases (15%) in fish tail group at the apex of the fish tail, two cases (10%) in tear drop group, two cases (10%) in modified suturing group and were all treated conservatively (dressing and antibiotics). Vilar-Compte *et al* reported that post-operative infection occurred in 36% of cases following mastectomy.⁽¹²⁾ While in 2013, Davis *et al* reported that infection after mastectomy despite it is considered as a clean operation

ranging from 1% to 26% and the incidence in that study was 2.3% in patients undergoing mastectomy.⁽¹⁵⁾ Szynglarewicz *et al*, reported that post-operative infection occurred in 0.85 % of cases at the apex of fish tail was effectively managed with the conservative approach.⁽⁴⁾ Also Hussein *et al*, reported that infection happened in 7,2 % of cases of fish tail plasty technique.⁽⁷⁾ The study of Davis *et al*, reported that the strongest influence on post-operative infection is the morbid obesity that increase the risk by 1.3 times as it is associated with impaired wound healing and tissue hypoxia.⁽¹³⁾ This can explain the relatively higher incidence of infection in our study because our entire sample was of obese patients and also the high prevalence of diabetic patients in our sample (56%).

Regarding incidence of wound dehiscence in the current study, it occurred in two cases (10%) in fish tail group, one cases (5%) in tear drop group and none of the cases of modified suturing group and all of them on top of infection. Also flap necrosis occurred in two cases (10%) in fish tail group, one case (5%) in tear drop group and one case (5%) in modified suturing group, it was managed with the excision and sewing under local anesthesia. Seroma presented in five cases (25%) in fish tail group, four cases (20%) in tear drop group and five cases (25%) in modified suturing group. Similar to Szynglarewicz *et al*, study which reports that marginal skin flap necrosis occurred in 2 elderly patients. Necrosis of margins of the axillary triangle was not noticed. A discrete necrosis of the apex occurred in one woman with diabetes. It was treated with necrectomy and successfully healed by second intention.⁽⁴⁾ On the other hand, Vilar-Compte *et al*, documented that wound dehiscence occurred in 10.8 % of cases, 4.8% occurred on top of infection. They also described that flap necrosis occurred in 23.9% of cases half of them on top of infection. Seroma presented in 25.6% of patients.⁽¹²⁾ Comparing our study to Vilar-Compte *et al*, control case study⁽¹²⁾ shows that adding our three techniques didn't increase the incidence of different complications, which shows our techniques to be safe and applicable.

Assessing patients satisfaction, comfortability and doctors satisfaction with questionnaires showed that the technique used with more satisfactory results is fish tail plasty technique despite the Y shaped scar. Similar to Szynglarewicz outcomes were evaluated by the physician as good in all the patients and were assessed by the women themselves as good in all cases, with the exception of one patient with the necrosis of the apex of the axillary triangle.⁽⁴⁾

Our study showed that tear-drop incision incorporates the tumor and provides adequate clearance of the primary lesion, axillary fat pad in the broader part of the incision. A cosmetically sound and flat scar is obtained because of the approximation of a teardrop defect results in a linear scar. But its results are variable as it is dependent on the point of closure of the lateral apex of the incision. Our results are similar to the results of Mirza *et al*. study.⁽⁹⁾

Also our study showed that modified suturing technique is simple does not require additional incisions and is cosmetically acceptable to the patient, both aesthetically and for bra/prosthesis fitting. This technique may create a length discrepancy between the lateral aspect of the superior and inferior incision, hence resulting in some lateral superior wound puckering and potentially shifting the lateral dog ear to the superior part of the wound.

We concluded that fish tail technique advantages are its excellent exposure to the axilla, the ease of performing the operation and its safety. Its disadvantages are adding an additional limb scar apart from the linear scar. However, this additional Y limb scar is usually well concealed under the arm, if the apex of the 'fish-shaped' incision or Y closure is placed at or lateral to the anterior axillary line and skin necrosis at apex of Y incision which is not common and can be prevented by maintaining a broad base between the two Y limbs. In the fish tail group there was a significant increase in patient satisfaction, comfortability and doctor satisfaction than the other two groups tear drop and modified suturing which makes it the best technique in this study regarding its results.

CONCLUSION AND RECOMMENDATION

Fishtail, teardrop and modified suturing techniques dealt well with the redundant skin lateral to mastectomy scar with no significant difference between the three techniques regarding their efficacy in prevention dog ear. While fish tail technique was significantly better regarding patient satisfaction, comfortability and doctor satisfaction than tear drop and modified suturing techniques; further studies are recommended with larger volume of cases to confirm the results of the current study.

REFERENCES

1. Ferlay J, Soerjomataram I, Dikshit R, Eser S, Mathers C, Rebelo M, *et al.* Cancer incidence and mortality worldwide: sources, methods and major patterns in GLOBOCAN 2012. *Int J Cancer* 2015;136(5):E359-86.
2. Wright MJ. Surgical treatment of breast cancer. *Medscape-Drugs & Diseases* [Last Updated: 7 Apr, 2014]. Available from:<http://emedicine.medscape.com/article/1276001-overview>. [Accessed On: 4 Nov, 2016].
3. Thomas R, Mouat C, King B. Mastectomy flap design: the 'waisted teardrop' and a method to reduce the lateral fold. *ANZ journal of surgery*. 2012 May 1;82(5):329-33.
4. Szynglarewicz B, Matkowski R, Kasprzak P, Halon A, Szelachowska J, Forgacz J, *et al.* Mastectomy approach with Y-shaped incision: a technique designed for women with obesity. *Int J Gynecol Cancer* 2009;19(8):1454-8.
5. Farrar WB, Fanning WJ. Eliminating the dog-ear in modified radical mastectomy. *Am J Surg* 1988;156 (5):401-2.
6. Lim GH, Tan HF. Surgical techniques to avoid lateral dog ear of the mastectomy scar: A systematic review. *Int J Surg* 2016;26:73-8.
7. Maged Hussien, Daltrey IR, Dutta S, *et al.* Fish-tail plasty: a safe technique to improve cosmesis at the lateral end of mastectomy scars. *The Breast* 2004; 13: 206-9.
8. <http://apps.who.int/nutrition/landscape/report.aspx?iso=egy>.
9. Mirza M, Sinha KS, Fortes-Mayer K. Tear-drop incision for mastectomy to avoid dog-ear deformity. *Ann R Coll Surg Engl* 2003;85(2):131.
10. Devalia H, Chaudhry A, Rainsbury RM, Minakaran N, Banerjee D. An oncoplastic technique to reduce the formation of lateral 'dog-ears' after mastectomy. *Int Semin Surg Oncol* 2007;4:29.
11. Schnur PL. Axillary skin flaps (dog ears). *Oper Tech Gen Surg* 2002;4(3):265-9.
12. Vilar-Compte D, Jacquemin B, Robles-Vidal C, Volkow P. Surgical site infections in breast surgery: case-control study. *World journal of surgery*. 2004 Mar 1;28(3):242-6.
13. Davis GB, Peric M, Chan LS, Wong AK, Sener SF. Identifying risk factors for surgical site infections in mastectomy patients using the National Surgical Quality Improvement Program database. *The American Journal of Surgery*. 2013 Feb 28;205(2):194-9