

IJMA



INTERNATIONAL JOURNAL OF MEDICAL ARTS

Volume 3, Issue 1 (Winter 2021)

<http://ijma.journals.ekb.eg/>

Print ISSN: 2636-4174

Online ISSN: 2682-3780



Available online at Journal Website
<https://ijma.journals.ekb.eg/>
Main subject [Basic Science [Physiology, Toxicology]] *

Original article

Effect of Oral Exposure to Bisphenol-A on The Liver and Kidney of Adult Male Albino Rats

Mohamed Ali Mahmoud Abbas ^[1], Samir Atef Farid Elmetwally^[2]; Mokhtar Ahmed Mokhtar Abo-Elfotouh^[2]

Department of Physiology, Damietta Faculty of Medicine, Al-Azhar University, Egypt^[1]

Department of Forensic Medicine and Clinical Toxicology, Damietta Faculty of Medicine, Al-Azhar University, Egypt^[2]

Corresponding author: Mohamed Ali Mahmoud Abbas
Email: drmohamedali122@gmail.com

Received at: August 04, 2020; Revised at: September 13, 2020; Accepted at: September 13, 2020

DOI: [10.21608/IJMA.2020.37970.1152](https://doi.org/10.21608/IJMA.2020.37970.1152)

ABSTRACT

Background: The organic composite of two phenolic neighbors [BPA] is Bisphenol A [BPA]. It is also commonly called propane 2,2 bis[4-hydroxyphenyl]. BPA is a voluminous industrial chemical used to manufacture epoxy resins and plastics.

Aim of the work: Evaluation of the effect of oral Bisphenol A on the liver and kidney of adult male albino rats.

Materials and Methods: Forty adult male albino rats [local strain] were divided into four groups [each 10 rats]. First is the control group, second is the low does BPA, third is moderate does BPA, and four is the high does BPA. The duration of exposure extended to 30 days. Then, blood samples have been collected for the measurement of serum aspartate aminotransferase [AST], serum alanine aminotransferase [ALT], blood urea, serum creatinine, superoxide dismutase [SOD], catalase, and glutathione. Also, hepatic and renal tissue samples were prepared for histopathological study.

Results: Oral administration of BPA in a dose of 50, 100, and 150 Mg/kg/day for 30 days led to a significant increase in the blood levels of ALT, AST, urea, and creatinine associated with a significant reduction in the blood levels of superoxide dismutase, Glutathione peroxidase, and catalase. There were few vacuolations of hepatocytes and congested blood vessels of the liver that were associated with changes in the kidney [narrow cortex, dilated tubules, and hypercellular glomeruli].

Conclusion: Bisphenol A oral exposure for 30 consecutive days is associated with several changes in biochemical parameters that indicate liver and kidney injury.

Keywords: Bisphenol A; Liver; kidney; Adult Male; Albino Rats.

This is an open-access article registered under the Creative Commons, ShareAlike 4.0 International license [CC BY-SA 4.0] [<https://creativecommons.org/licenses/by-sa/4.0/legalcode>].

Please cite this article as: Abbas MA, Samir AFE, Abo-Elfotouh MAM. Effect of Oral Exposure to Bisphenol A on the Liver and Kidney of Adult Male Albino Rats IJMA 2021; 3[1]: 930-937. DOI: [10.21608/IJMA.2020.37970.1152](https://doi.org/10.21608/IJMA.2020.37970.1152)

* Main subject and any subcategories have been classified according to the research topic.

INTRODUCTION

The widely used industrial chemical is bisphenol A [BPA], 2,2-bis [4-Hydroxyphenyl] propane. It produces about 2-3 million tons a year and is one of the main monomers used for polymerization reactions in plastic manufacturing. BPA is used for certain dental insulating products, carbonless receipt paper, digital media [compact discs [CDs], and digital versatile discs [DVDs]]^[1]. BPA is used in baby bottles, water bottles, and food containers^[2]. Previous studies reported that BPA was measurable in the dust, air particles, and water, making exposure widespread. BPA is used to manufacture epoxy and polycarbonate resins^[3].

Inflammation and oxidative stress are closely related to liver fibrosis, which is the main contributor to hepatic failure^[4]. Small amounts of BPA can be leached from the polymer containers or metallic resins that line the metal cans to the stored food and water, especially at high temperatures [such as during sterilization cycles]. This is why the diet of contaminated food and tainted beer water is the biggest BPA susceptibility source ^[5]. For starters, reusable baby bottles, food packaging materials, canned vegetable liquid, and dental dentures^[4]. BPA administration has contributed to liver fibrosis, which indicates a rise in serum hepatic enzymes, liver hydroxyproline content, and histopathological changes in particularly increased deposition of collagen fibers through the portal tract ^[5].

It is not easy to study bisphenol-A effects on human individuals, especially with different doses. In addition, it is not well-known the association between Laboratory and histopathological changes in either liver or kidney. The renal effects of the exposure to bisphenol A did not well addressed previously.

AIM OF THE WORK

This study aimed to show the effect of various doses of bisphenol-A on adult male albino rats' liver and kidney.

MATERIALS AND METHODS

Animals and experimental design:

This study was conducted on 40 local strain adult male rats, attained from the Nile Pharmaceuticals Company, Cairo, Egypt. These rats weigh 90-120g. The animals have housed in

the animal lab of The Faculty of Medicine [Al-Azhar University] [5 rats in each cage, with the following dimensions: 80 x 40 x 20 cm according to the Guidelines for Use and Carriage of Laboratory Animals]. The animals were provided with good temperature, ventilation, humidity, and normal dark/light exposure and fed on chow dietary diets during the whole time of the study [30 days].

Rats were divided into four groups [each contains 10 rats]: **Group I [Control group]:** Rats of this group take olive oil orally 0.5 ml for 30 days. **Group II [Low does BPA]:** Rats of this group given Bisphenol A [BPA] dissolved in olive oil orally at a dose of 50 Mg/kg/day for 30 days. **Group III [Moderate does BPA]:** Rats of this group given BPA dissolved in olive oil orally at a dose of 100 Mg/kg/day for 30 days. **Group IV [High does BPA]:** Rats of this group given BPA dissolved in olive oil orally at a dose of 150 Mg/kg/day for 30 days.

Bisphenol A [BPA]: Purchased from [Sigma Pharmaceuticals Company]. **Ethyl Ether** [Analar, Nile Pharmaceutical]: For anesthesia.

Blood and tissue collection: All rats were anesthetized by placing in a closed aesthetical box filled with ether vapor at the close of the experimental time. By adding fluid ether frequently to a cotton wool ball on the box's base, ether vapor was preserved. The blood was drained by a heparinized capillary tube from the retro-orbital plexus. Blood was left to coagulate and centrifuged for 10 minutes at a pace of 3000 to get the serum. Serum has been drawn into Eppendorf tubes and stored frozen at -20°C^[6] until determination of aspartate aminotransferase [AST] and alanine aminotransferase [ALT]^[7], urea^[8], creatinine^[9], superoxide dismutase [SOD]^[10], catalase^[10] and glutathione peroxidase^[11]. The liver and kidney have been excised and stored in 10% formalin solution for histopathological analysis. Tissue samples were made of paraffin tubes; different sections were collected, hematoxylin and eosin [Hx and E] stains were stained, and light microscopic examination had been performed at the pathology department [Damietta Faculty of Medicine, Al-Azhar University].

Statistical analysis: The input and analysis of data were carried out with the computer program the Statistical Package for Social Science [SPSS], version 22 [IBM@SPSS® Inc., Chicago, USA]. All

findings have been shown as a mean \pm standard deviation. Mean values for the various groups have been compared using a one-way analysis of variance. The post hoc analysis was used to determine significantly different mean values for the least significant difference [LSD]. $P < 0.05$ indicate a significant difference

RESULTS

Results from current work showed a significant increase in the mean ALT, AST, urea, creatinine levels in Groups II, III, and IV compared to the control group. In addition, a higher dose of bisphenol A is associated with a significant reduction in the average values of SOD, GPX, and catalase levels compared with the control group [Table 1].

The mean values of ALT, AST, and Creatinine in Group III, Group IV, was significantly improved in the dose of 100 and 150 Mg/ kg/ day for 30 days and the mean value of urea associated with an

insignificant reduction in addition to a significant reduction in the mean value of SOD, GPX and catalases compared with group II [Table 2 & 3].

Histopathological examination of liver and renal tissues are presented in figures [1 through 8]. Briefly, changes observed in examined sections were dose-dependent [i.e., with increasing dose, the alterations were increased and progressed to a more advanced stage. At a dose of 50 Mg/kg/day for 30 days, liver tissues showed few hepatocyte vacuolations and congestion of blood vessels. At 100 Mg/kg/day for 30 days, the hepatocyte vacuolations become moderate, marked with significant congestion with a dose of 150mg/kg/day for 30 consecutive days. Besides, renal changes were in the form of mild narrowing of the cortex, with mildly dilated tubules and mild glomerular hypercellularity at the dose of 50mg. These changes were moderate and then marked as the doses of 100 and 150mg, respectively.

Table [1]: Comparison between group I and studied groups [Mean \pm SD].

	Group I	Group II	Group III	Group IV
ALT[U/L]	31.2 \pm 2.25	46.7 \pm 1.6*	57.1 \pm 2.33*	65.6 \pm 2.7*
AST[U/L]	27.9 \pm 1.19	40.6 \pm 3.13*	54.2 \pm 2.8*	61.8 \pm 1.47*
Urea[mg/dl]	26.5 \pm 1.77	54.0 \pm 4.99*	55.7 \pm 2.11*	57.2 \pm 2.57*
Creatinin [mg/dl]	0.51 \pm 0.01	0.55 \pm 0.02*	0.58 \pm 0.01*	0.71 \pm 0.05*
SOD[mg/dl]	70.7 \pm 2.01	55.2 \pm 2.39*	41.6 \pm 1.5*	40.0 \pm 1.83*
GPX[mg/dl]	21.8 \pm 1.34	18.9 \pm 0.99*	14.5 \pm 0.85*	12.6 \pm 0.96*
CAT[mg/dl]	63.6 \pm 2.46	53.2 \pm 2.65*	45.1 \pm 1.9*	39.1 \pm 4.04*

* indicate significance compared to group I.

Table [2]: Comparison between group II and other studied groups

	Group II	Group III	Group IV
ALT[U/L]	46.7 \pm 1.6	57.1 \pm 2.33*	65.6 \pm 2.7*
AST[U/L]	40.6 \pm 3.13	54.2 \pm 2.8*	61.8 \pm 1.47*
Urea[mg/dl]	54.0 \pm 4.99	55.7 \pm 2.11	57.2 \pm 2.57
Creatinine [mg/d]	0.55 \pm 0.02	0.58 \pm 0.01*	0.71 \pm 0.05*
SOD[mg/d]	55.2 \pm 2.39	41.6 \pm 1.5*	40.0 \pm 1.83*
GPX[mg/d]	18.9 \pm 0.99	14.5 \pm 0.85*	12.6 \pm 0.96*
CAT[mg/d]	53.2 \pm 2.65	45.1 \pm 1.9*	39.1 \pm 4.04*

* indicate significance compared to group II.

Table [3]: Comparison between group III and group IV.

	Group III	Group IV
ALT[U/L]	57.1 \pm 2.33	65.6 \pm 2.7
AST[U/L]	54.2 \pm 2.8	61.8 \pm 1.47
Urea[mg/dl]	55.7 \pm 2.11	57.2 \pm 2.57
Creatinine [mg/d]	0.58 \pm 0.01	0.71 \pm 0.05
SOD[mg/d]	41.6 \pm 1.5	40.0 \pm 1.83
GPX[mg/d]	14.5 \pm 0.85	12.6 \pm 0.96
CAT[mg/d]	45.1 \pm 1.9	39.1 \pm 4.04

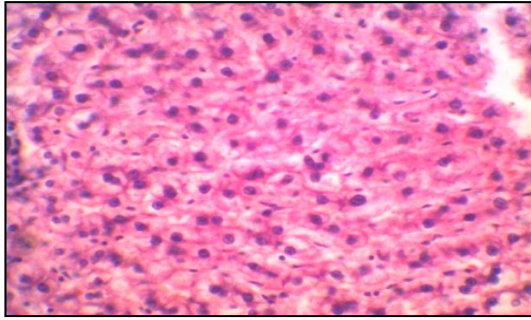


Figure [1]: Section of the liver in normal rats received olive oil orally for 30 days showed swollen hepatocytes and some vacuoles within hepatocytes [H&E x 400].

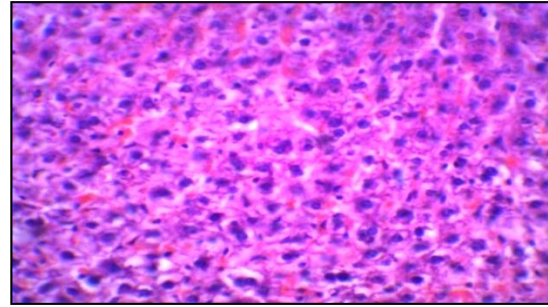


Figure [2]: Section in the liver in rats received Bisphenol A [BPA] dissolved in olive oil orally at a dose of 50 mg/kg/day for 30 days showed few vacuolations of hepatocytes and congested blood vessels [H&E x 400]

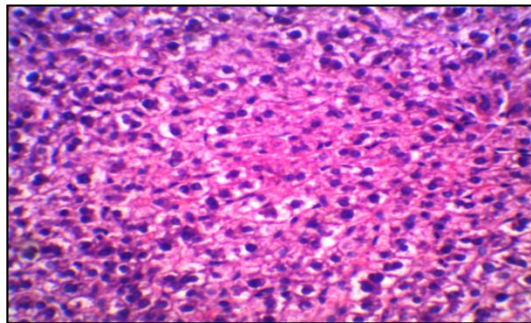


Figure [3]: Section of the liver in rats received Bisphenol A [BPA] dissolved in olive oil orally at a dose of 100 mg/kg/day for 30 days showed moderate vacuolation of hepatocytes [H&E x 400].

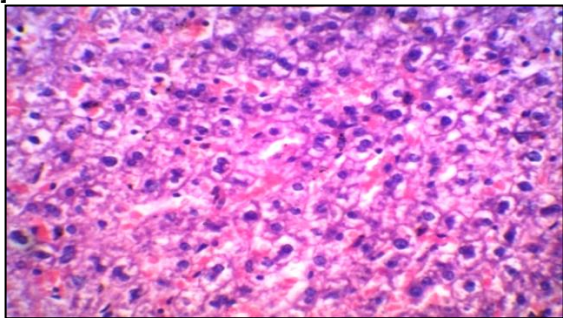


Figure [4]: Section of the liver in rats received Bisphenol A dissolved in olive oil orally at a dose of 150 mg/kg/day for 30 days shows marked vacuolations of hepatocytes and congested blood vessels [H&E x 400]

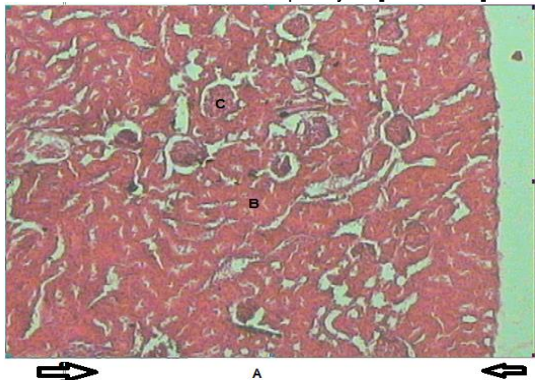


Figure [5]: Section in the kidney of rats received olive oil orally for 30 days showed normal cortex [A], normal tubules [B], and normal glomeruli [C] [H&E x100].

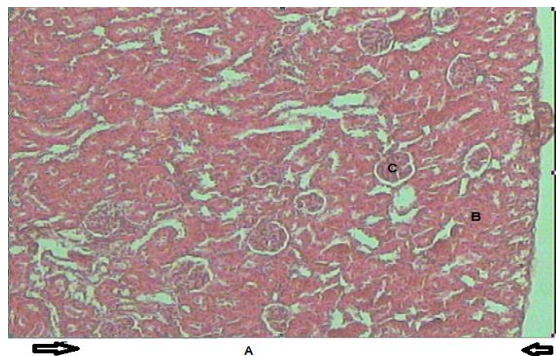


Figure [6]: A photomicrograph of a section in the kidney of rats received Bisphenol A [BPA] dissolved in olive oil orally at a dose of 50 mg/kg/day for 30 days showed mild narrow cortex [A], mildly dilated tubules [B] and mild hypercellular glomeruli [C] [H&Ex 100].

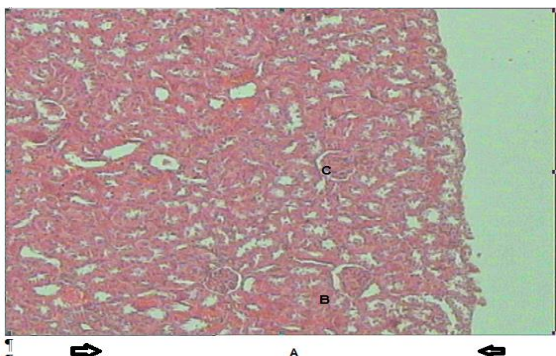


Figure [7]: A photomicrograph of a section in the kidney of rats received Bisphenol A [BPA] dissolved in olive oil orally at a dose of 100 mg/kg/day for 30 days showed moderate narrow cortex [A], mildly dilated tubules [B] and moderate hypercellular glomeruli [C] [H&E x 400].

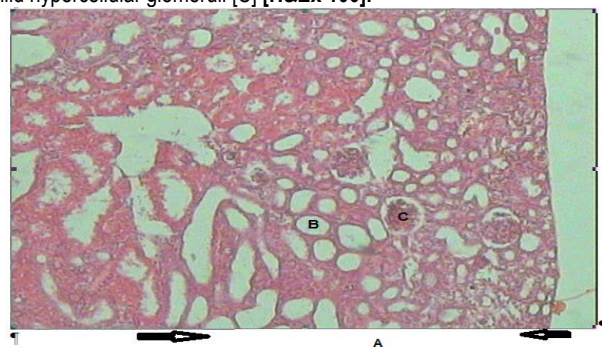


Figure [8]: A photomicrograph of a section in the kidney of rats received Bisphenol A [BPA] dissolved in olive oil orally at a dose of 150 mg/kg/day for 30 days showed marked narrow cortex [A], marked dilated tubules [B] and marked hypercellular glomeruli [C] [H&E x 400].

DISCUSSION

The current work results revealed a significant increase of liver enzymes and histological changes of hepatocytes with exposure to bisphenol A compared to the non-exposed group. Besides, oxidative stress was marked in exposed groups, which could be the mechanism of toxic effects exerted by bisphenol-A.

Liver enzymes are usually elevated with liver diseases and are the most reliable hepatocellular injury or necrosis markers. ALT is considered more specific to liver injury, as it is found in low concentrations, mostly in the liver's cytosol [12].

These enzymes are released into the blood if the liver hepatocytes are damaged, and the significant increase in AST and ALT levels indicates damage to cytosol and mitochondria[13].

In line with the current work, **Poormoosavi et al.**[14] noticed that the increase in AST and ALT activity due to BPA administration. The cellular leakage is associated with high levels of these indicators.

By increasing oxidative stress in the liver, BPA could cause hepatic damage and mitochondrial disorders[15]. The present study was compatible with the results of **Neha et al.**[16] who reported a significant increase in AST and ALT levels in mice treated with BPA [50 mg/kg] for 30 days.

The study of **Walaa et al.**[17] revealed a significant increase in serum ALT and AST group treated with BPA compared to control groups.

Eweda et al.[18] showed comparable results due to increased hepatic damage and reduced cell membrane integrity, leading to leakage of hepatic cytoplasmic enzymes[19]. Further studies have shown that BPA exposure to high and low-dose leads to genomic damage and changes in liver enzyme levels [20-21].

Renal function in the current work revealed that the oral administration of bisphenol A [BPA] in rats resulted in a significant increase in urea and creatinine's mean value. These results agree with **Pal et al.**[22] who observed that the serum creatinine values were significantly increased. The increased serum creatinine levels may be caused by a reduced kidney ability to eliminate toxic metabolites.

Sangai et al.[23] and **Ezeonu et al.**[24] have reported a significant increase in creatinine level and the effect was dose-dependent. **You et al.** [25] have reported a significant increase in urinary creatinine excretion. **Murmu and Shrivastava**[26] reported that bis-phenol-A increased the creatinine level after 15, 30, and 60 days of administration in freshwater fish [Cirrhinusmrigala] as compared to control.

The nephrotoxic effects are explained by the accumulation of BPA-toxic metabolites and kidney failure[23].

Several toxic substances that induce nephrotoxicity may alter the glomerular basement membrane and affect the glomerular filtration rate [27].

The high urea and creatinine levels in BPA have been recorded by **Morgan et al.**[28]. BPA toxic metabolites were accumulated, and the renal capacity for these toxic agents' excretion was reduced [29].

The current study revealed a significant reduction of SOD, GPX, and CAT with oral administration of BPA. These results are in line with the study of **Hassan et al.**[30] who found a significant reduction of hepatic glutathione [GSH] and glutathione peroxidase [GSHPX] levels with BPA-treatment [25 mg / kg / day] for 30 days. This imbalance caused oxidative stress and leads to organ damage. These results indicate that the oxidative stress mechanism could mediate liver and renal damage caused by BPA.

In hemodialysis patients with polysulfone dialyzers containing BPA, relations between high serum BPA levels and increased oxidative stress markers were also reported[31].

The interaction of lipid, protein, and DNA molecules with ROS reduces the damage caused by antioxidants. No matter what the antioxidant system is, several clinical disorders may result from over or unbalanced ROS production utilizing chemicals. By distributing the redox status in cells, BPA can cause oxidative stress[32].

Oxidative stress constitutes an imbalance between reactive oxygen species production and antioxidant protection, which results in oxidative damage[33]. **Kobroob et al.**[34] demonstrated that

exposure to BPA reduces the antioxidant GSH. This disruption led to renal oxidative stress and renal damage.

The dose of 50, 100, and 150 mg/kg oral BPA in rats for five weeks exhibited renal mitochondrial dysfunction by increasing mitochondrial ROS, reduced potential of the mitochondrial membrane, and induction of mitochondrial swelling. With the increased BPA dose, the magnitude of these changes was increased. Most importantly, when BPA was applied directly to the isolated mitochondria, a dose-dependency reduction in mitochondrial function was reported. BPA can directly act to worsen the kidney mitochondria' function^[35]. In the liver sections, bisphenol-A oral administration was associated with hepatocyte vacuolations and blood vessel congestion. There was dilatation of blood sinusoids and slight blood engorgement in the kidney. **Poormoosavi et al.**^[14] showed that the use of BPA led to necrotic changes in central veins, congested and dilated hepatocytes, increased proliferation of Kupffer cells, lymphocytic infiltration, and mild inflammatory regions.

Apoptosis and cell damage can be explained by the capacity of BPA to induce Adenylate Kinase activations, tumor necrosis alpha [TNF]-alpha gene expression, Ca²⁺ homeostasis dysregulation, and ROS production^[36].

Wei et al.^[37] asserted that during the in vitro studies, when isolated mitochondria in neonatal rats were treated with BPA at a temperature of 30°C for 55 minutes, there was induced mitochondrial swelling, alteration of mitochondrial ultra-structure, due to transition to permeability, and released proteins that lead to the activation of apoptosis

The renal histopathology of our study is in line with **Walaa et al.**^[17] who revealed that atrophy of renal corpuscles with retraction of the glomerular tuft, widening of urinary spaces, degenerative renal tubules changes, and mononuclear cell infiltration. The ability of BPA to produce ROS can explain this and can therefore lead to injuries of mitochondria that play a major role in apoptosis^[38].

Olea-Herreroet et al.^[39] found that, for 5 weeks at a dose of 50 mg/Kg, intraperitoneal bisphenol A injections induced enlargement of the cytoplasm and foot processes of podocytes and enhanced the presence of condensed chromatin. **Walaa et al.**^[17]

revealed that BPA exposure is associated with induced thickening of Bowman's capsule's basement membrane's capsule confirmed by strong Periodic acid Schiff [PAS] stain.

Several toxic substances induced nephron-toxicity may alter the glomerular basement membrane and affect the glomerular filtration^[27].

In short, adult male rats' exposure to BPA causes oxidative stress in the liver. Hepatotoxicity and nephrotoxicity were caused by BPA through oxidant/antioxidant imbalance and demonstrated by biochemical & histopathological modifications. Thus, exposure to BPA must be avoided. More studies are still needed to demonstrate BPA exposure and clarify the relationship between BPA toxicity on the kidney and liver.

Financial and Non-Financial Relationships and Activities of Interest:

None

REFERENCES

- 1-Ribeiro E, Ladeira C, Viegas S.** Occupational Exposure to Bisphenol A [BPA]: a reality that still needs to be vvalid. *Toxics*. **2017**; 5[3]: 22-27. [DOI: 10.1089/ars.2016.6665].
- 2-Rubin BS.** Bisphenol A: an endocrine disruptor with widespread exposure and multiple effects. *J Steroid Biochem Mol Biol*. **2011**; 127[1]: 27-34. [DOI: 10.1016/j.jsbmb.2011.05.002].
- 3-Asimakopoulos AG, Thomaidis NS, Koupparis MA.** Recent trends in biomonitoring of bisphenol A, 4-t-octylphenol, and 4-nonylphenol. *Toxicol Lett*. **2012**; 210: 141-154. [DOI: 10.1016/j.toxlet.2011.07.032].
- 4-Errico S, Bianco M, Mita L.** Migration of bisphenol A into canned tomatoes produced in Italy: dependence on temperature and storage conditions. *Food Chem*. **2014**; 160: 157-164. [DOI: 10.1016/j.foodchem.2014.03.085].
- 5-Erdem Y, Acar F.** Migration of Bisphenol-A into the natural spring water packaged in polycarbonate carboys. *Int J Applied Sci Technol*. **2012**; 2[1]: 152-157.
- 6- Elsokkary MB, Samaha SR, Abbas MA.** Effect of melatonin on hypertension and diabetes induced experimentally in adult male albino rats. *Al-Azhar Med J*. **2018**; 47 [1]: 73-87. doi: 10.12816/0047698
- 7- Huang X, Choi Y, Hyung-Soon I, Yarimaga O, Yoon E, Hak-Sung K.** Aspartate Aminotransferase [AST/GOT] and Alanine Aminotransferase [ALT/GPT] detection techniques. *Sensors [Basel]*. **2006**; 6[7]: 756-782. PMID: PMC3894536.

- 8-Chaney A, Marbach E.** Modified reagents for determination of urea and ammonia. *Clin Chem.* **1962**; 8:130-132. doi: 10.1093/clinchem/8.2.130.
- 9-Moore JF, Sharer JD.** Methods for Quantitative Creatinine Determination. *Curr Protocols in Human Genetics.* **2017**; 93[1]: 30-37. doi: 10.1002/cphg.38.
- 10-Weydert CJ, Cullen JJ.** Measurement of superoxide dismutase, catalase and glutathione peroxidase in cultured cells and tissue. *Nat Protoc.* **2010**; 5[1]:51-66. doi: 10.1038/nprot.2009.197.
- 11-Mannervik B, Alin P, Guthenberg C, Jensson H, Warholm M.** Identification of three classes of cytosolic glutathione transferase common to several mammalian species: correlation between structural data and enzymatic properties. *Proc Natl Acad Sci USA.* **1985**; 82 [21]: 7202–7206. doi: 10.1073/pnas.82.21.7202.
- 12-McGill MR.** The past and present of serum aminotransferases and the future of liver injury biomarkers. *EXCLI J.* **2016**; 15: 817–828. doi: 10.17179/excli2016-800.
- 13-Contreras-Zentella ML, Hernández-Muñoz R.** Is Liver Enzyme Release Really Associated with Cell Necrosis Induced by Oxidant Stress? *Oxid Med Cell Longev.* **2016**; 16: 3529149. doi: 10.1155/2016/3529149.
- 14-Poormoosavi SM, Najafzadehvarzi H, Behmanesh M, Amirgholami R.** Protective effects of Asparagus officinalis extract against Bisphenol A- induced toxicity in Wistar rats. *Toxicol Rep.* **2018**; 5: 427–433. doi: 10.1016/j.toxrep.2018.02.010.
- 15-Hussein RM, Eid JI.** Pathological mechanisms of liver injury caused by oral administration of bisphenol A. *Life Science* **2013**; 10[1]: 663-673.
- 16-Neha P, Sangat J, Ramtej J, Verma A.** Quercetin ameliorates bisphenol A induced toxicity in mice. *Acta Poloniae Pharmaceutica-Drug Res.* **2012**; 69 [3]: 557- 563. PMID: 22594271.
- 17-Walaa MS, Ahmed A, Moselhy AW, Nabil TM.** Bisphenol-A toxicity in adult male rats: Hematological, biochemical and histopathological approach. *Global Veterinaria* **2015**; 14 [2]: 228-238. doi: 10.5829/idosi.gv.2015.14.02.9332.
- 18-Eweda SM, Newairy AA, Abdou HM, Gaber AS.** Bisphenol A-induced oxidative damage in the hepatic and cardiac tissues of rats: The modulatory role of sesame lignans. *Exp Ther Med.* **2020**; 19 [1]: 33–44. doi: 10.3892/etm.2019.8193.
- 19-Gad Alla A, Gad Alla AM.** Effect of vitamin C and thymoquinone on experimentally bisphenol A induced hepato-renal toxicity in adult male albino rats. *AMJ* **2017**; 46[3]: 643-656. doi: 10.12816/0040352.
- 20-Moustafa GG, Ahmed AA.** Impact of prenatal and postnatal exposure to bisphenol A on female rats in a two generational study: Genotoxic and immunohisto-chemical implications. *Toxicol Rep.* **2016**; 3: 685–695. doi: 10.1016/j.toxrep.2016.08.008.
- 21-Kim S, Mun GI, Choi E, Kim M, Jeong JS, Kang KW, et al.** Submicromolar bisphenol A induces proliferation and DNA damage in human hepato-cyte cell lines in vitro and in juvenile rats in vivo. *Food Chem Toxicol.* **2018**; 111: 125–132. doi: 10.1016/j.fct.2017.11.010.
- 22-Pal S, Sarkar K, Nath PP, Mondal M, Khatun A, Paul G.** Bisphenol S impairs blood functions and induces cardiovascular risks in rats. *Toxicol Rep.* **2017**; 4: 560–565. doi: 10.1016/j.toxrep.2017.10.006.
- 23-Sangai NP, Verma RJ, Trivedi MH.** Testing the efficacy of quercetin in mitigating bisphenol A toxicity in liver and kidney of mice. *Toxicol Ind Health* **2012**; 30: 581-597. doi: 10.1177/0748233712457438.
- 24-Ezeonu FC, Oguazu CE, Ubaaji KI, Anajekwu B.** Bisphenol A Causes Blood Electrolyte Imbalance and Upsets Kidney Functions in Albino Wistar Rats. *J Pharm Sci Bioscientific Res.* **2015**; 5[6]: 547-550.
- 25-You L, Zhu X, Shrubsole MJ, Fan H, Chen J, Dong J.** Renal function, bisphenol A, and alkylphenols: results from the National Health and Nutrition Examination Survey [NHANES 2003–2006]. *Environ Health Perspect.* **2011**; 119:527–533. doi: 10.1289/ehp.1002572.
- 26-Murmu S, Shrivastava VK:** Role of Vitamin C as antidote against Bisphenol A toxicity in kidney of fresh water fish *Cirrhinus mrigala* [Ham]. *Int J Environm Sci.* **2014**; 6 [3]: 499-503. doi: 10.21608/eajbsz.2014.13497.
- 27-Manikkam M, Tracey R, Guerrero-Bosagna C, Skinner M.** Plastics derived endocrine disruptors [BPA, DEHP and DBP] induce epigenetic trans-generational inheritance of obesity, reproductive disease and sperm epimutations. *PLoS ONE*, **2013**; 8 [1]: 88-92. doi: 10.1371/journal.pone.0055387.
- 28-Morgan AM, El-Ballal S, El-Bialy B, EL-Borai N.** studies on the potential protective effect of cinnamon against bisphenol A- and octylphenol-induced oxidative stress in male albino rats. *Toxicol Reports* **2014**; 1: 92–101. doi: 10.1016/j.toxrep.2014.04.003.
- 29-Yildiz N, Barlas N.** Hepatic and renal functions in growing male rats after bisphenol A and octylphenol exposure. *Hum Exp Toxicol.* **2013**; 32 [7]: 675-686. doi: 10.1177/0960327112464796.
- 30-Hassan Z, Elobeid M, Virk B, Omer S, ElAmin M, Daghestani M, et al.** Bisphenol A induced hepato-toxicity through oxidative stress in rat model. *Oxid Med Cell Longev.* **2012**; 12: 192829. doi: 10.1155/2012/194829.

- 31-Bosch-Panadero E, Mas S, Sanchez-Ospina D.** The choice of hemodialysis membrane affects bisphenol-A levels in blood. *J Am Soc Nephrol.* **2016**; 27[5]: 1566–1574. doi: 10.1681/ASN.2015030312.
- 32-Khalaf AA, Ahmed WM, Moselhy WA, Abdel-Halim BR.** Protective effects of selenium and nano-selenium on bisphenol- induced reproductive toxicity in male rats. *Int J Mol Biol.* **2019**; 38 [4]: 112-118. doi: 10.1177/0960327118816134.
- 33-Ratliff BB, Abdulmahdi W, Pawar R, Wolin M.** Oxidant mechanisms in renal injury and disease. *Antioxidants and Redox Signaling* **2016**; 25 [3]: 119–146. doi: 10.1089/ars.2016.6665.
- 34-Kobroob A, Peerapanyasut W, Chattipakorn N, Wongmekiat O.** Damaging Effects of Bisphenol A on the Kidney and the Protection by Melatonin: Emerging Evidences from in Vivo and in Vitro Studies. *Hindawi Oxid Med Cell Long.* **2018**; 18: 1-15. doi: 10.1155/2018/3082438.
- 35-Khan S, Beigh S, Chaudhari B.** Mitochondrial dysfunction induced by bisphenol A is a factor of its hepatotoxicity in rats. *Environmen Toxicol.* **2016**; 31 [12]: 1922–1934. doi: 10.1002/tox.22193.
- 36-Kourouma A, Quan C, Duan P, Qi S, Tingting Y, Yinan W, et al.** Bisphenol A Induces Apoptosis in Liver Cells through Induction of ROS. *Adv Toxicol.* **2015**; 15:1-10. doi: 10.1155/2015/901983.
- 37-Wei X, Ying J, Yuanyuan L, Yanjian W, Juan L, Yue M, et al.** Early-Life Exposure to Bisphenol-A Induces Liver Injury in Rats Involvement of Mitochondria Mediated Apoptosis. *PLoS One.* **2014**; 9[2]: 90443. doi: 10.1371/journal.pone.0090443.
- 38-AI-Shobaili H, AI-Robae A, Alzolibani H, Rasheed Z.** Immunological studies of reactive oxygen species damaged catalase in patients with systemic lupus erythmatosis correlation with disease activity index. *Immunol Invest.* **2013**; 42: 191-203. doi: 10.3109/08820139.2012.751396.
- 39-Olea-Herrero N, Arenas MI, Muñoz-Moreno C.** Bisphenol-A induces podocytopathy with proteinuria in mice. *J Cellular Physiol.* **2014**; 229 [12]: 2057–2066. doi: 10.1002/jcp.24665.

International Journal

<https://ijma.journals.ekb.eg/>

Print ISSN: 2636-4174

Online ISSN: 2682-3780

of Medical Arts