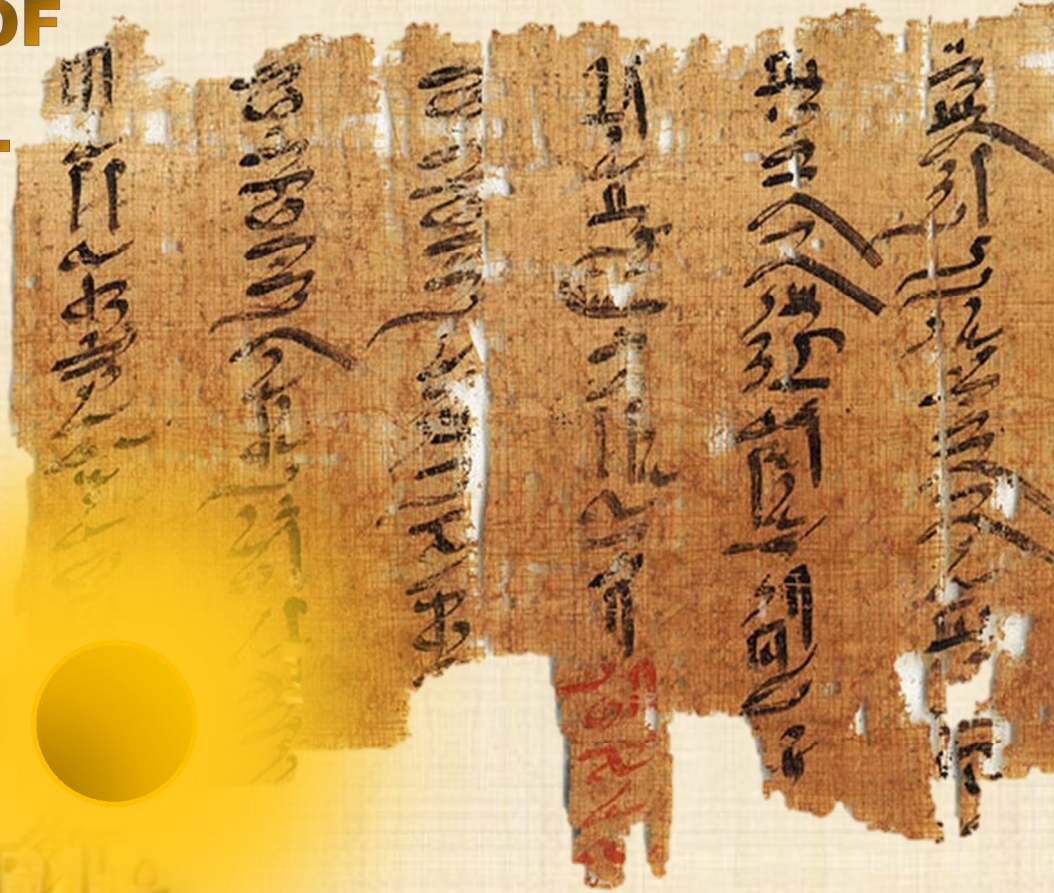


# IJMA

# INTERNATIONAL JOURNAL OF MEDICAL ARTS



VOLUME 2, ISSUE 4, AUTUMN 2020)



<http://ijma.journals.ekb.eg/>

**Print ISSN: 2636 - 4174**

**Online ISSN: 2682 - 3780**



Available online at Journal Website  
<https://ijma.journals.ekb.eg/>  
Main subject [Surgery]\*



## Original article

### Mini-transverse Incision using Swivel Knife for Treatment of Carpal Tunnel Syndrome: An innovative Idea and Preliminary Report "Amin's Technique"

Mahmoud Ahmed Amin<sup>[a]</sup>; Sherief Mahmoud Al-Shazly<sup>[b]</sup>

Department of Plastic Surgery, Damietta Faculty of Medicine, Al-Azhar University, Egypt <sup>[a]</sup>.

Department of Neurology, Damietta Faculty of Medicine, Al-Azhar University, Egypt <sup>[b]</sup>.

#### Corresponding author

Mahmoud Ahmed Amin

Email: mahmoudplastic1968@gmail.com

Received at: July 19, 2020; Revised at: September 14, 2020; Accepted at: September 16, 2020

DOI: [10.21608/ijma.2020.36429.1149](https://doi.org/10.21608/ijma.2020.36429.1149)

#### ABSTRACT

**Background:** Carpal tunnel syndrome [CTS] is the commonest entrapment neuropathy of the upper limb. Different treatment modalities [conservative and surgical] are present. Each has its advantages and disadvantages. No consensus is found about the ideal surgical treatment modality.

**Aim of the work:** To introduce an innovative use of swivel knife with mini-transverse incision in median nerve release. Also to compare the study results' to the conventional approach.

**Patients and methods:** Seventy patients included in the study. All had confirmed diagnosis of CTS and scheduled for surgical treatment. The new technique using the Swivel Knife has operated on 35 patients [study group] and the traditional technique was done for 35 patients [control group]. All patients have been assessed clinically and by neuro-physiological studies [preoperatively, and at 3 months postoperatively]. Both groups were compared regarding patient demographics and all preoperative data.

**Results:** Significant postoperative findings were superior in the study group. Results in the study group showed a reduction of operative time, incision length, Levine score and pain score at 3 months [ $0.23 \pm 0.43$  vs  $0.89 \pm 1.21$  respectively,  $p < 0.05$ ]. In addition, study group was associated with higher safety and patient satisfaction.

**Conclusion:** Introduction of swivel knife with mini-transverse incision just proximal to distal wrist crease is an effective and safe. This technique could be promising alternative option for surgical treatment of CTS.

**Keywords:** Swivel Knife; Mini-transverse; Median Nerve; Carpal Tunnel Syndrome; Neurophysiological.

This is an open access article registered under the Creative Commons, ShareAlike 4.0 International license [CC BY-SA 4.0] [<https://creativecommons.org/licenses/by-sa/4.0/legalcode>]

Please cite this article as: Amin MA, Al-Shazly SM. Mini-transverse Incision using Swivel Knife for Treatment of Carpal Tunnel Syndrome: An innovative Idea and Preliminary Report "Amin's Technique". IJMA 2020; 2[4]:690-697. DOI: [10.21608/ijma.2020.36429.1149](https://doi.org/10.21608/ijma.2020.36429.1149)

\* Main subject and any subcategories have been classified according to research topic.

## INTRODUCTION

Carpal tunnel syndrome [CTS], defined as “the compression of the median nerve at the level of the transverse carpal ligament”<sup>[1]</sup>, is the commonest compressive neuropathy, with a prevalence rate between 6% and 10%. It usually affects elderly populations with an average age of 54 years, with female sex predominance [female to male ratio is 2: 1]<sup>[2,3]</sup>.

CTS could be treated conservatively [early in the disease]. However, with more frequent or persistent symptoms [e.g., muscular weakness, reduced handgrip or drooping], surgical treatment may be needed. About 20% of people with CTS need surgical treatment<sup>[4]</sup>.

Surgical treatment could be in the form of standard open surgery with a 3–5 cm long incision that produces carpal tunnel release. However, wound complications [such as wound infection, wound dehiscence or painful scare] are more frequent than with minimally invasive surgery. Unfortunately, minimally invasive surgery had its specific complications [such as recurrent incidents and incomplete release]<sup>[5]</sup>, with high cost of endoscopic when compared to traditional open surgery<sup>[6,7]</sup>.

Open surgery on the other side had many advantages of lower risk of blood vessels injury, complete nerve release, and the ability to perform parallel interventional treatments on other problems in the carpal tunnel, and different methods were tried to decrease associated complications either with open or minimally invasive techniques<sup>[8]</sup>.

We propose that, mini-transverse palmar incision with the use of swivel knife could be associated with reduction of complications associated with traditional open surgical treatment of carpal tunnel syndrome. In addition, the rapid, guided and safe dissection could lead to shortening of operative time.

## AIM OF THE WORK

The aim of the present work was to evaluate the innovative technique of mini-transverse incision with the use of swivel knife for treatment of carpal tunnel syndrome from the clinical and neurophysiological point of view.

## PATIENTS AND METHODS

The present work was conducted at Damietta University Hospital, Al-Azhar University, and Damietta Military hospital, through two years duration [from January 2018 through January 2020]. Thirty-five patients who had presented with carpal tunnel syndrome and failed conservative treatment were included and underwent surgical treatment by the assigned technique and results were compared to results of 35 patients, treated by conventional longitudinal technique [control group]. The CTS diagnosis based on clinical data and confirmed by electrophysiological studies.

**Inclusion and exclusion criteria:** The current study included patients with definitive diagnosis of CTS [according to clinical and electromyography data], who failed medical treatment [had no signs of recovery after 3 months of treatment] with moderate to severe CTS according to American Association of Electro diagnostic Medicine [AAEM]. Otherwise, individuals with a traumatic injury to the MN and pregnant females were excluded from the current work.

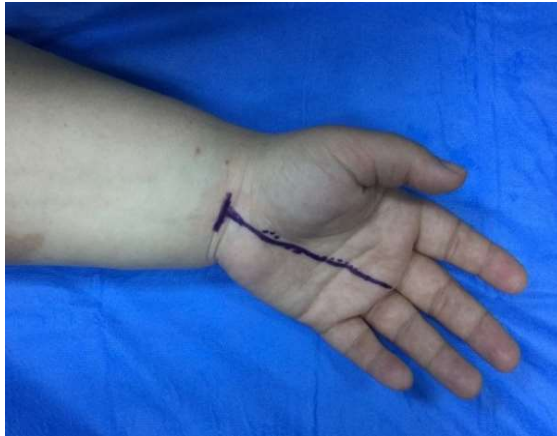The preoperative diagnosis based on one or more the following manifestations: hand pain, muscle weakness, hypoesthesia or paresthesia among median nerve [MN] distribution, atrophy of thenar muscles and positive signs [Tinel's, Phalen's, or Durkan's]<sup>[9]</sup>.

**Electromyography [EMG]:** Preoperative EMG had been performed one week before, and postoperative EMG studies had been performed on the last follow up visit [3 months postoperatively]. The severity of CTS had graded according to The AAEM classification<sup>[10]</sup>. All electromyography studies had completed as described by **Keser et al.**<sup>[9]</sup>.

The following nerve conduction parameters had been measured and documented [1] sensory conduction velocity [SCV] [m/s]; [2] peak distal sensory latency [DSL] [ms]; [3] sensory nerve action potentials amplitude [SNAPa] [mV]; [4] median distal motor latency [DML] in [ms]; and [5] motor compound muscle action potential amplitude [CMAPa] in [mV].

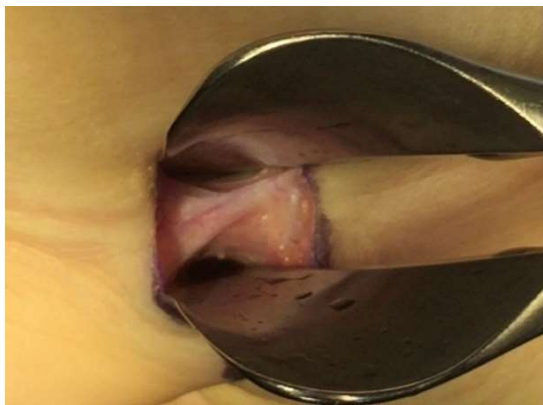**Surgical technique:** Marking of the surface anatomy landmarks had been performed for flexor

carpi radialis, palmaris longus, radial border of the ring finger and proximal wrist crease [Figure 1].



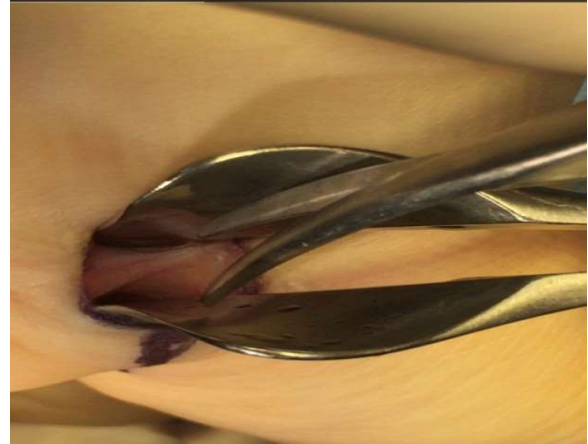**Figure [1]:** surgical marking a] flexor carpi radialis b] palmaris longus c] radial border of the ring finger and d] proximal wrist crease.

The operations had been carried out under general anesthesia with application of arm pneumatic tourniquet. A transverse incision about 1.5 cm had been created at the level of proximal wrist crease between flexor carpi radialis and palmaris longus tendons, followed by retraction of the palmaris tendon, and blunt dissection up to the proximal edge of transverse carpal ligament and the median nerve. The wrist had been hyperextended and the soft tissues superficial and deep to flexor retinaculum had been retracted away by using nasal speculum. This permitted good visualization of the flexor retinaculum between its blades [one blade retract the superficial structure containing the palmer cutaneous branch of median and ulnar nerve with superficial palmar arch. The other blade mainly protect and push the median nerve away from the flexor retinaculum] [Figure 2].



**Figure [2]:** Good visualization of the transverse carpal ligament between 2 blade of nasal speculum.

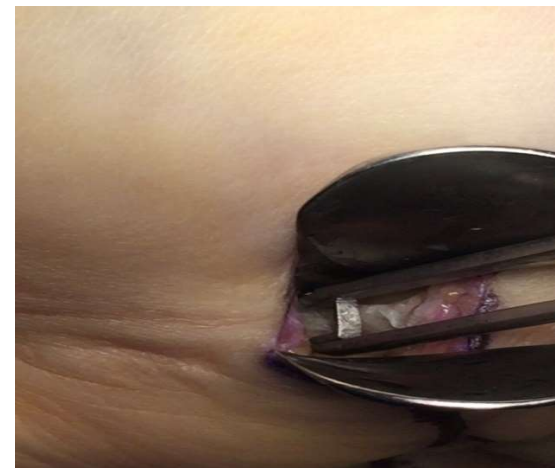
Small snip using the blunt edge surgical scissor had been done for the flexor retinaculum [Figure 3], then the surgical Ballenger swivel knife [Figure 4] applied at the snipped retinaculum and pushed gradually to cut all the flexor retinaculum [Figure 5].



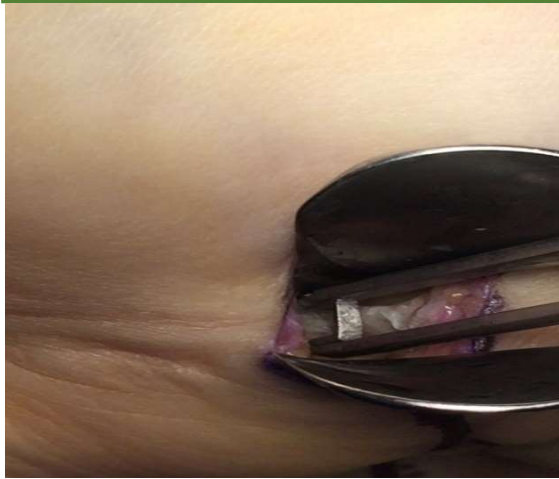**Figure [3]:** Snip of the proximal edge of the transverse carpal ligament using scissor



**Figure [4]:** Ballenger swivel knife

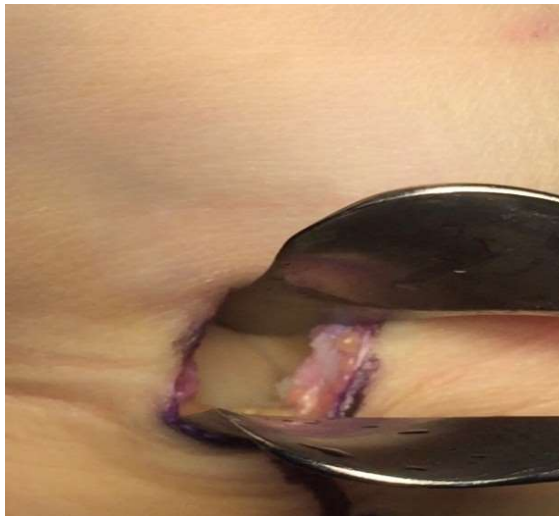

**Figure [5]:** surgical swivel knife applied at the snipped retinaculum and cut all the flexor retinaculum



**Figure [5]:** surgical swivel knife applied at the snipped retinaculum and cut all the flexor retinaculum.

After CTR proper visualization of the median nerve through opened tunnel using nasal speculum, a freer dissector had been completed [Figure 6].



**Figure [6]:** Median nerve after carpal tunnel release

The wound had been closed with single layer closure using 4/0 proline, and a dressing with creep bandage of the wrist had been applied for 10 days. After carpal tunnel release with small incision using nasal instruments, patients were under antibiotic prophylaxis, analgesic and anti-edematous drugs. The suture had been removed on the 10<sup>th</sup> day.

All patients had been returned to work after 10 days postoperatively. Three months after surgery patient's reassessment had been done through wrist range of movements, hand grip, aesthetic appearance, and return to work.

At the last follow up visit, each patient had been asked to rate their satisfaction as "Excellent", "Good", "Fair", or "Poor".

It is a subjective evaluation completely based on patient's opinion. The surgical intervention was confined to one side [unilateral] in patients with bilateral electrophysiological abnormalities

**Data analysis:** For quantitative data, measures of central tendency and dispersion were calculated [mean and standard deviations respectively]. In addition, categorical data represented as relative frequency and percentage from each group. Groups compared by independent samples [t] test and Chi square tests for numerical [quantitative] and qualitative data respectively. P value < 0.05 was considered statistically significant.

## RESULTS

The current work included 70 patients confirmed with diagnosis of carpal tunnel syndrome on the basis of clinical findings and neurophysiological investigations. Their age ranged between 30 to 66 years, with no significant difference between groups [47.60±7.32 vs 46.08±5.32 years among study [group 1] and control [group 2] groups respectively]. In addition, the majority of them were females [60.0% vs 68.6% respectively]. In addition, both groups were comparable regarding operated side, clinical signs and duration of symptoms [months]. The duration extends between 4 to 14 months and the mean duration was 8.42±2.68 and 7.57±2.53 months respectively. Furthermore, study and control groups were comparable as regard to preoperative severity scoring and electrophysiological studies [For detailed results, see **table 1**].

Regarding postoperative data, no significant difference had been reported by study and control groups regarding two-point discrimination, visual analogue scale for pain, DASH score, patients with wound pain and electrophysiological studies. However, there was statistically significant shortening of operative time among study when compared to control group [4.80±0.75 vs 28.37±4.05 minutes respectively]. In addition, the incision length is significantly reduced in study when compared to control group [14.37±2.54 vs 32.57±4.27 mm respectively]. The Levine score for both symptoms and function was significantly

reduced among group 1 when compared to control group. The mean pain score, 3 months postoperative significantly decreased among study when compared to control group [0.23±0.43 vs 0.89±1.21 respectively]. Finally, there was significant difference between study and control groups regarding patient's satisfaction [it was excellent and good among 60.0% and 40.0% respectively in the study group, compared to 40.0% and 28.6% among control group. In addition,

control group had 25.7% with fair outcome and 2.5% with poor outcome] [Detailed results are presented in **table 2**].

In both groups, there was statistically significant difference between pre-and post-operative values of tow point discrimination, pain score, DASH, Levine score and neurophysiological studies, reflecting the favorable outcome among both groups [**Table 3**].

**Table [1]: comparison between groups regarding patient demographics and preoperative data**

Variables		Study [n=35]	Control [n=35]	Test	P
Age [years]		47.60±7.32; 30-66	46.08±5.32; 37-60	0.99	0.33
Sex	Male	14[40.0%]	11[31.4%]	0.56	0.30
	Female	21[60.0%]	24[68.6%]		
Operated Side	Right	19[54.3%]	18[51.4%]	0.06	0.81
	Left	16[45.7%]	17[48.6%]		
Clinical signs	Tinel	31[88.6%]	30[85.7%]	0.12	0.72
	Phalen	35[100.0%]	35[100.0%]		
	Durkan	33[94.3%]	34[97.1%]		
DOS [months]		8.42±2.68; 4-14	7.57±2.53; 5-13	1.37	0.17
Two-points discrimination		8.28±2.58	9.20±2.24	1.58	0.12
VAS		4.08±1.35	3.74±1.03	1.18	0.24
DASH		32.14±5.69	31.11±6.12	0.72	0.47
Levine score	Symptoms	2.64±0.47	2.80±0.38	1.52	0.13
	Function	2.39±0.28	2.38±0.32	0.08	0.93
Electrophysiology [median nerve]	DML	5.60±1.89	5.11±1.82	1.10	0.27
	CMAPa	7.00±2.05	6.31±2.09	1.38	0.17
	DSL	4.49±0.52	4.26±0.55	1.75	0.09
	SNAPa	5.19±1.56	4.99±1.37	0.55	0.58
	SCV	22.42±6.19	21.68±4.88	0.56	0.57

**Table [2]: Comparison between groups regarding postoperative data**

Variables		Study [n=35]	Control [n=35]	Test	P
Operative time [minutes]		4.80±0.75	28.37±4.05	<b>33.76</b>	<b>&lt;0.001*</b>
Incision length [mm]		14.37±2.54	32.57±4.27	<b>21.65</b>	<b>&lt;0.001*</b>
Two-point discrimination		3.68±0.83	3.42±0.78	1.33	0.19
VAS		0.88±0.58	1.08±0.78	1.21	0.29
DASH		8.91±0.91	8.80±1.02	0.49	0.62
Levine score	Symptoms	1.28±0.15	1.37±0.16	<b>2.25</b>	<b>0.028*</b>
	Function	1.19±0.13	1.27±0.15	<b>2.42</b>	<b>0.018*</b>
Wound pain	Positive	0[0.0%]	3[8.6%]	3.13	0.08
	Negative	35[100.0%]	32[91.4%]		
Electrophysiology [median nerve]	DML	4.43±0.48	4.25±0.87	1.04	0.29
	CMAPa	7.89±1.35	7.58±1.31	0.96	0.34
	DSL	3.70±0.68	3.83±0.63	0.68	0.41
	SNAPa	10.32±1.19	9.91±1.08	1.52	0.13
	SCV	37.68±9.50	39.00±8.51	0.60	0.54
Postoperative pain 3 months		0.23±0.43	0.89±1.21	<b>3.04</b>	<b>0.003*</b>
Patient satisfaction	Excellent	21[60.0%]	14[40.0%]	<b>13.06</b>	<b>0.004*</b>
	Good	14[40.0%]	10[28.6%]		
	Fair	0[0.0%]	9[25.7%]		
	Poor	0[0.0%]	2[5.7%]		

**Table [3]: Pre-and post-operative outcome among both groups**

		Study group				Control group			
		Preop.	Postop.	t	p	Preop.	Postop.	t	p
TPD [mm]		8.27±2.58	3.68±0.83	9.98	<0.001*	9.20±2.24	3.42±0.77	14.21	<0.001*
VAS		4.08±1.35	0.88±0.58	12.86	<0.001*	3.74±1.03	1.08±0.78	12.26	<0.001*
DASH		32.14±5.69	8.91±0.91	24.40	<0.001*	31.11±6.12	8.80±1.02	20.40	<0.001*
Levine Score	Symptoms	2.64±0.46	1.28±0.15	16.05	<0.001*	2.80±0.37	1.36±0.15	19.40	<0.001*
	Function	2.39±0.28	1.19±0.13	23.21	<0.001*	2.38±0.31	1.27±0.15	18.76	<0.001*
Neuro-physiology	DML	5.60±1.89	4.42±0.50	4.10	<0.001*	5.11±1.82	4.24±0.88	3.04	<0.001*
	CMAPa	7.00±2.05	7.88±1.35	5.59	<0.001*	6.31±2.09	7.58±1.31	6.14	<0.001*
	DSL	4.48±0.52	3.70±0.68	8.06	<0.001*	4.26±0.55	3.83±0.67	4.43	<0.001*
	SCV	22.42±6.19	37.68±9.50	10.17	<0.001*	21.68±4.88	39.00±8.51	13.33	<0.001*
	SNAPa	5.18±1.56	10.32±1.18	16.56	<0.001*	4.99±1.37	9.90±1.08	16.80	<0.001*

**DISCUSSION**

Among upper limb entrapment neuropathies, carpal tunnel syndrome [CTS] is one of the most prevalent forms worldwide. Its high prevalence and subsequent effects on quality of life mandates the search for effective and cost-effective treatment modality, and this modality must be associated with higher patient satisfaction<sup>[11]</sup>.

The available treatment modalities include non-surgical and surgical techniques. The non-surgical treatment options include wrist splints and/or corticosteroid injection. These methods usually confined to mild to moderate stages. On the other side, surgical interventions are performed for severe stages with persistent clinical manifestation, which not respond to conservative treatment. Various surgical techniques had been described, which include open and mini-incision [transverse or oblique] maneuvers, but the best technique is not yet determined<sup>[12]</sup>.

The advantages of conventional open techniques include the provision of direct visualization of the structures. However, it may be associated with complications [such as painful scar, neurosensory deficits or neuromas, reduction of hand strength and quality of life]. The mini-incision technique- on the other side – is associated with limited visualization, but the available literature certifies that, it is not associated with increased rate of complications when compared to conventional technique [i.e., it is as effective as conventional technique with low or similar rate of complications]<sup>[13]</sup>.

In the current work, authors thinking out of the box, but based on the available evidence. In the current scope, the complications associated with carpal tunnel release usually originated from

mainly mucosal destruction of perineurium during median nerve release. Thus, in the current work to avoid this destruction, the swivel knife was introduced, with its blunt outer surfaces to guard against tissue destruction [the main innovative in the current work]. Also, the use of swivel knife speeds the dissection and release process with marked reduction of operative time. In addition, the transverse mini-incision was used just above the wrist joint [proximal to distal wrist crease] to reduce pain associated with scare contracture, when compared to palmer incision. The transverse nature of the incision permits widening of visual field, and its presence in a mobile area reduced pain due to contracture.

The main results of the current work could be summarized in significant shortening of operative time, less length of incision, significant reduction of postoperative pain, better outcome and patient satisfaction [the functional, aesthetic results and low pain] are responsible for higher patient satisfaction. In addition, on neurophysiological studies, the current procedure is associated with slightly better outcome. However, the difference was not statistically significant [thus, we could say, the introduced technique is at least as effective as open technique with high safety profile].

**Anbarasan et al.**<sup>[14]</sup> advocated the mini-incision technique for management of CTS; They reported that, both symptom severity and functional scores had been reduced and hand grip strength improved 3 months after surgery. All patients were satisfied with aesthetic outcome, although three of them [7.5%] had scar tenderness. They concluded that, mini-open [vertical; different than the current work] blind technique is safe, easily reproducible and had short duration of recovery. In addition, **Keramettin et al.**<sup>[15]</sup> performed open CT release

[73 hands] and mini-incision [56 hands] and showed that, both functional and cosmetic outcome is better with mini-incision technique. **Polat**<sup>[16]</sup> evaluated the feasibility and effectiveness of the mini-open incision method in management of CTS incision made proximal to the distal wrist crease. They concluded that, their procedure is effective and safe, provides less complications and higher patient comfort and satisfaction. However, they used a vertical incision, other than the transverse one used in the current work. **Bai et al.** <sup>[17]</sup> compared mini-incision [1-2 cm long] to traditional open approach and reported that, at the end of first year after surgery, both groups were comparable and all patients achieved good recovery. No significant difference had been reported regarding functional outcome, VAS core, Levine score and the Disabilities of the Arm, Shoulder and Hand [DASH] score [P > 0.05]. They concluded that, mini-incision technique had been associated with satisfactory surgical outcomes, low complications and good appearance.

In an interesting study, **Siow et al.**<sup>[18]</sup> carried a social [general public] survey to search about patient preferences regarding volar incision. 107 responses had been analyzed. The majority of them preferred longitudinal scars. The cause for this preference were: 1] potential damage to wrist structures by transverse incision, 2] better aesthetic outcome, and 3] the transverse scar appear as self-inflicted injury. On the other side, causes to prefer transverse volar incision were: 1] could be easily concealed by accessories, 2] less noticeable, 3] better cosmesis. Interestingly older people had preferred the longitudinal scar [the most common cause was the concern about possible damage of wrist structures], while younger persons preferred transverse one.

Of note, all responders had no volar operations or scar at all [they asked if they will be exposed, what they prefer and why]. Thus, the current position of many incision in the current work could provide wide social acceptance as it is usually hidden in the wrist crease and painless with movement.

The current study had limitation. The first is the small number of studied patients, and the second is short follow up duration [3 months]. Thus, future work studies with high and sufficient number of

patients, with longer follow up duration are warranted.

In conclusion, the introduction of swivel knife with mini-transverse incision just above the wrist joint represents a promising interventional technique for management of carpal tunnel syndrome. Authors encourage all surgeons to adopt the current technique.

**Ethical considerations:** The study protocol had been approved by the local institutional review board, Damietta Faculty of medicine, Al-Azhar University, Egypt. In addition, an informed consent had been signed by all participants. All ethical rights of studied patient had been confirmed and assured.

**Financial and Non-financial Relationships and Activities of Interest:**

Authors declare that, there was no activities of interest [financial or non-financial].

**REFERENCES**

1. **Ostergaard PJ, Meyer MA, Earp BE.** Non-operative Treatment of Carpal Tunnel Syndrome. *Curr Rev Musculoskelet Med.* **2020**; 13[2]:141-14. [DOI: 10.1007/s12178-020-09616-0].
2. **Hermiz SJ, Kalliainen LK.** Evidence-based medicine: current evidence in the diagnosis and management of carpal tunnel syndrome. *Plast Reconstr Surg.* **2017**; 140 [1]: 120–9. [DOI: 10.1097/PRS.0000000000003477].
3. **Padua L, Coraci D, Erra C, Pazzaglia C, Paolasso I, Loreti C, et al.** Carpal tunnel syndrome: clinical features, diagnosis, and management. *Lancet Neurol.* **2016**; 15 [12]: 1273–1284. [DOI: 10.1016/S1474-4422[16]30231-9].
4. **English JH, Gwynne-Jones DP.** Incidence of Carpal Tunnel Syndrome Requiring Surgical Decompression: A 10.5-Year Review of 2,309 Patients. *J Hand Surg Am.* **2015** Dec; 40[12]:2427-34. [DOI: 10.1016/j.jhsa.2015.07.029].
5. **Hansen TB, Majeed HG.** Endoscopic carpal tunnel release. *Hand Clin.* **2014** Feb; 30 [1]:47-53. [DOI: 10.1016/j.hcl.2013.08.018].
6. **Liawrungrueang W, Wongsiri S.** Effectiveness of Surgical Treatment in Carpal Tunnel Syndrome Mini-Incision Using MIS-CTS Kits: A Cadaveric Study. *Adv Orthop.* **2020**; 2020: 8278054. [DOI: 10.1155/2020/8278054].
7. **Thoma A, Wong VH, Sprague S, Duku E.** A cost utility analysis of open and endoscopic carpal tunnel release. *Can J Plast Surg.* **2006** spring; 14[1]:15-20. [DOI: 10.1177/229255030601400101].



8. **Chen Y, Ji W, Li T, Cong X, Chen Z.** The mini-incision technique for carpal tunnel release using nasal instruments in Chinese patients. *Medicine [Baltimore]*. **2017** Aug; 96 [31]: e7677. [DOI: 10.1097/MD.0000000000007677].
9. **Keser N, Dortcan N, Cikla U, Uluc K, Celikoglu E, Is M, Gurer B.** Semivertical Incision: An Aesthetically and Electrophysiologically Effective Mini-Incision Technique for Carpal Tunnel Decompression. *Med Sci Monit*. **2017** Jun 19; 23:2993-3000. [DOI: 10.12659/msm.902343].
10. **Jablecki CK, Andary MT, So YT, Wilkins DE, Williams FH.** Literature review of the usefulness of nerve conduction studies and electromyography for the evaluation of patients with carpal tunnel syndrome. AAEM Quality Assurance Committee. *Muscle Nerve*. **1993** Dec; 16[12]: 1392-414. [DOI: 10.1002/mus.880161220].
11. **van den Broeke LR, Theuvenet WJ, van Wingerden JJ.** Effectiveness of mini-open carpal tunnel release: An outcome study. *Arch Plast Surg*. **2019** Jul; 46[4]:350-358. [DOI: 10.5999/aps.2018.00535].
12. **Khoshnevis J, Layegh H, Yavari N, Eslami G, Afsharfard A, Reza Kalantar-Motamedi SM, Zarrintan S.** Comparing open conventional carpal tunnel release with mini-incision technique in the treatment of carpal tunnel syndrome: A non-randomized clinical trial. *Ann Med Surg [Lond]*. **2020** May 16; 55:119-123. [DOI: 10.1016/j.amsu.2020.05.001].
13. **Isik HS, Bostanci U.** Experience of Carpal Tunnel Syndrome that operated using a limited uni skin incision. *Turk Neurosurg*. **2011**; 21[2]:177-80. [DOI: 10.5137/1019-5149.JTN.3246-10.2].
14. **Anbarasan A, Thevarajah N, Sadagatullah AN.** The Functional Outcome of Mini Carpal Tunnel Release. *J Hand Microsurg*. **2017**;9[1]:6-10.[DOI: 10.1055/s-0037-1598089].
15. **Keramettin A, Cengiz C, Nilgun C, Ayhan B.** Microsurgical open mini uniskin incision technique in the surgical treatment of carpal tunnel syndrome. *Neurol India*. **2006** Mar; 54[1]:64-7. [DOI: 10.4103/0028-3886.24710].
16. **Polat O.** Evaluating of the Outcomes of Median Nerve Decompression with a Mini Incision Proximal to the Distal Wrist Crease. *Turk Neurosurg*. **2019**; 29 [6]:927-932. [DOI: 10.5137/1019-5149.JTN.26462-19.2].
17. **Bai J, Kong L, Zhao H, Yu K, Zhang B, Zhang J, Tian D.** Carpal tunnel release with a new mini-incision approach versus a conventional approach, a retrospective cohort study. *Int J Surg*. **2018** Apr; 52:105-109. [DOI: 10.1016/j.ijsu.2018.02.033].
18. **Siow BRS, Tong CRH, Satku M, Sechachalam S, Yeo CJ.** Transverse or longitudinal? A survey of volar wrist incision preferences. *Singapore Med J*. **2019** Sep 19. [doi: 10.11622/smedj.2020023].

# International Journal

<https://ijma.journals.ekb.eg/>

Print ISSN: 2636-4174

Online ISSN: 2682-3780

# of Medical Arts