

LIVER HYDATID IN YOUNG AGE TREATED PER-CUTANEOUS BY USING PUNCTURE-ASPIRATION-INJECTION-REASPIRATION (PAIR) TECHNIQUE

By

EISSA ABDEL HAMED IBRAHIM^{1*} AND AYMAN T. A. MORSY^{2**}

Consultant of General Surgery¹, Military Medical Academy, Cairo, 11291, and
Consultant of Tropical Medicine and Fever², Ministry of the Interior, Egypt
(Correspondence: *eissa.abdelhameed@gmail.com; Eissa-1961@yahoo.com &
**atossonaly@gmail.com)

Abstract

Human hydatid disease is mainly caused by infection with the larval stage of dog tapeworm *Echinococcus granulosus*. The disease is widely endemic in many sheep and cattle rearing locales such as Australia, Latin America, Africa and Middle Eastern countries, and now worldwide. Hydatidosis is a serious pathogenic, zoonotic and parasitic infection of humans, following ingestion of tapeworm eggs excreted in the feces of infected dogs. Children of all age groups are susceptible from pet dogs (Urban area) or stray dogs (Rural area) and localization of the disease in the lungs is more commonly seen. Multiple liver cysts in the pediatric age group were relatively uncommon. Surgery remains the primary treatment and the only hope for complete cure. PAIR is considered an alternative treatment for cystic echinococcosis (hydatid disease) and is often indicated for patients who do not respond to open surgery or drugs.

Key words: Pediatric cases, Hydatidosis, Diagnosis, PAIR technique, Scolicidal agents, Follow-up.

Introduction

Hydatidosis is a zoonosis caused by *Echinococcus granulosus*, and ingesting eggs released through the feces from infected dogs infects humans of worldwide distribution including Egypt (Ibrahim and Morsy, 2020). The location of the hydatid cysts is mostly hepatic and/or pulmonary, whereas musculoskeletal hydatidosis was very rare (WHO, 2014). When the liver is affected the person may have abdominal pain, weight loss, and turn slightly yellow from jaundice. Lung disease may cause pain in the chest, shortness of breath and coughing (CDC, 2013). The commonest form of treatment is open surgical removal of the cysts combined with chemotherapy using albendazole[®] and/or mebendazole[®] before and after surgery (Eckert and Deplazes, 2004). However, if there were cysts in multiple organs or tissues, or the cysts were in risky locations, surgery became impractical. For such as such, chemotherapy and/or PAIR (puncture-aspiration-injection-reaspiration) became the alternative options of treatment (Gabal *et al*, 2005).

This study aimed to demonstrate ten-pediat-

ric male patients (5 to 15 years) suffered from hepatic hydatidosis and two lung hydatidosis. All were inpatients in Kobry El-Kobba Military Medical Campus and well-treated by the Puncture-Aspiration-Injection-Reaspiration (PAIR) technique.

Material and Methods

The study was carried out up on ten young male patients with liver hydatid cyst caused by *Echinococcus granulosus* in Kobry El-Kobba Military Medical Campus. All patients were male aged between 5 to 15 years. A medical sheet was filled out on each case or from his parents.

The commonest complaints were cough, fever, abdominal pain, nausea vomiting, and hemoptysis as well as chest pain was in patients with lung cyst. But, those without typical symptoms (asymptomatic) suffered from shortness of breath, purulent sputum, weight loss and urticaria.

Single liver hydatid in 8 patients and 2 patients showed liver and lung hydatid; single liver cyst in 7th segment and left lung cysts were found in 2 patients (Tab. 1). Patients' cysts were ten in liver & two in lung (Tab. 2).

Table 1: Patients' ages and cysts in liver & lung

Age/year	Liver	Lung
5	1	1
4-9	5	–
10-11	2	1
12-15	2	–
Number of cyst	10	2

Table 2: Sign and symptoms among patients

Sign and symptoms	Number of patients
Hepatomegaly	5
Abdominal mass	8
Abdominal pain	7
Ascites	–
Fever	4
Weight loss	5
Allergy	3
Dyspnea	2
Splenomegaly	1

The patients may present by one or more of sign and symptoms.

The diagnosis of patient infected by hydatid cyst was established by clinically as shown in (Tab. 2), US and CT “abdomen-pelvic and chest”

Imaging: the US to all patients showed single liver cyst and affected mainly the 7th segment. US was abdomen-pelvic and CT chest complementary for chest hydatid cyst.

Laboratory examination: All patients were subjected to chemical investigation, specially coagulation profile and INR, liver function test renal profile, CBC, blood sugar level and ECG.

Procedure PAIR was done after having informed written consent from the parents of the pediatric patients. Outcome of procedure as size of cyst, type of patients, time of procedure infection rate, hospital stay, recurrent of disease and cost effect.

Operation: Minimally invasive technique, percutaneous draining of liver hydatid cyst PAIR, using hypertonic saline as protoscolicidal agent 23.4% (Fig 1).

All operations were done in the Department of Radiology; the patient was prepared according to pre-operative guideline. Albendazole 10mg/kg/d were given for two days before and one week after operation together with a broad spectrum antibiotic.

Operation done under local anesthesia, general endotracheal anesthesia may be used. The patients divided into 2 groups according to age, and anesthesia used GI included six

male patients aged 5-9 years and G II included four male patients aged 10-15 year.

GI: The six patients were presented clinical sign and symptoms suggestive to be liver hydatid cyst, CT and US were done and revealed all patient having deeply sited hydatid cyst liver and one patient aged 5 years have double lesion – one in liver and other lung “base of left lung (Fig. 2A, B & C).

Under general endotracheal anesthesia in radiological department CT localized site of cyst and insertion of big-tail (Fig. 3A, B & C).

Aspiration of more than ½ of volume of hydatid cysts and injection the same volume of hypertonic saline 23.4% and leave it inside hydatid cysts 15-20 minute and aspiration it and procedure reported 3 time (Fig. 4A, B & C). Second injection and aspiration were shown (Fig. 5 A, B & C).

In the second aspiration showed clear aspiration not bile tinge. At the end of operation cutting injection site of big-tail and connecting big-tail to collecting bag and discharge patient (Fig. 6).

After a week US was done and removal of big-tail, cysts were reduced in size from 24.6 cm to 9.28 cm and floating germinal layer inside cystic cavity (Fig. 7A & B). The follow-up by US showed the disappearance of the floating germinal layer, but still the cystic cavity was pseudo-tumor like (Fig. 8A & B).

Postoperative: Follow-up of patient was by

U.S every month, albendazole 10mg/Kg/day was given for one week, post-operative antibiotic.

GII: The four patients were presented clinical sign and symptoms suggestive to be liver hydatid cyst. CT and US were done and showed liver hydatid cyst and one of the four patients have double lesion, one in liver and other in lung (Fig. 9).

Operation: The operation done under local infiltration anesthesia using xylocaine 2%. Sterilization of skin by povidone iodine and drapes the patient by sterile towel. Insertion of big-tail under US (N16 or 18G or 6 French Catheter) and big-tail connected to collected bag (Fig. 10A & B).

Hydatid fluid came out from the cysts by passive, not active (negative pressure). Some of hydatid fluid remained in cyst and was mixed with hypertonic saline 23.4% to help distribution of the fluid inside cyst cavity (Fig.11), US to ass a cyst. Cavity and hydatid fluid were previously injected with hypertonic saline.

Injection of 80ml or more hypertonic saline 23.4% NaCl inside cystic cavity using US, the operation was done 3 times. First injection, after injection of 80ml or more of hypertonic saline inside the cystic cavity leave it inside cysts 15-20 minute and respiration of this volume (Fig. 12 A, B & C). Second injection started after first injection 20-30 minute by the same technique (F. 13A, B & C)

Post-operative: After 3rd PAIR, US was done 4hr postoperative to show cysts wall as well as cystic cavity content (Fig. 14). One week post discharge from hospital in outpatient clinic US was done and showed floating

of germinal layer, and measure cystic cavity (Fig.15). Also removal of big-teal and follow up one month by US and CT to ass cyst content and measure its volume (Fig. 16 A). Complementary CT was done and showed residual rim of cysts and returned the compressed liver to near normal size (Fig. 16B).

Postoperative patient was given albendazole 10mg/kg/d for one week and US was done every month in the outpatient clinic.

Results

Size of cysts 10 cm in AP diameter x 20 cm as in GII, 24.6 cm in GI became 9.28 cm after aspiration.

All patients young male and divided into two groups, GI, 5 year to 9 year, and GII, 10 to 15 years, based on anesthesia used. *E. granulosus* was the causative agent by histopathological examination of all patients

Recurrent of cysts no recurrent was found in the patients but pseudo-tumor was found at site of cyst and disappeared after 4-6 month during follow up. No secondary infection was found in all patients.

Hospital stay and time of procedure the procedure done in radiological department were about four hours and patients were discharged second day morning.

Complication of scolicial agents: No major complication was found in all patients except, during procedure patient complaining from thirsty its due to hyperosmolarity of hypertonic saline” and disappear after finishing procedure. Neither bleeding nor hematoma occurred in all patients. Cost effective, the procedure was cheap than opened procedure one used hypertonic saline 300 cc, big tell, local anesthesia 5cc and US”(Tab. 3)

Table 3: Comparative between GI & GII

Variants	Group I	Group II
Age	5-9 years	10-15 years
Size of cysts	24.6 CT measure main – 15.5 cm	10 x 20cm CT measure main 15 cm
Recurrent of cyst	No recurrent, pseudo-tumor up to 2 to 4 month	No recurrent, pseudo-tumor up to 4 to 6 month
Infection	No infection was found	No infection was found
Hospital stay	24 hour (one day)	24 h (one day)
time procedure	4 hour	2 hour
Hypertonic saline	No major complication mild thirsty	No major complication severe thirsty

Discussion

Generally speaking, echinococcosis and/or hydatidosis are a worldwide zoonotic para-

sitosis (Schantz, 1982). Hydatid cyst disease is still an important public health problem in Egypt and worldwide as wherever, there is

sheep-dog-man, the risky of hydatidosis do exist (Haridy *et al*, 2000). The larvae ingested by the oral route were transferred from the intestines to the liver by way of the portal vein and the most commonly involved organ was the liver (Gun *et al*, 2017). In children, however, the cyst was observed most commonly in the lungs, because the lungs enable rapid growth of the cyst due to their compressible structure, vascularization, and negative pressure (Garcia, 2010).

Traditionally, *E. granulosus* was diagnosed in dogs by in the post-mortum intestinal washes or after areolae purgation (Varcasia *et al.*, 2004). An enzyme immunoassay based test was developed for sera (Jenkins and Rickard, 1986) or copro-antigen (Allan *et al.*, 1992).

In Egyptian stray dogs, Selim (1967) in Cairo and Giza Governorates (G.) reported 6% *E. granulosus*, Abou-Eisha and Abdel-Aal (1995) in Ismailia G. reported *E. granulosus* in 10.2% of stray dogs, and Abd El-Alim *et al.* (1999) in Alexandria and Beheira Gs. reported 4.6% in stray dogs. Mazyad *et al.* (2007) in Cairo G. reported *E. granulosus* 16% of stray dogs as well as 8/50 policemen hunters of stray dogs. Several factors played a role in egg dispersal from site of fecal deposition to the food of the intermediate hosts as wind, water, birds and non-blood sucking flies, beetles, and cockroaches (Wilson, 1991). *E. granulosus* prenatal transfer did not play a role (Conn, 1994). Besides, *Echinococcus* eggs dropped from an infected dog were found adhered to the dogs' fur, particularly to the hairs around the anus and on the thighs, muzzles, and paws. Thus, the handling of such infected dogs also played an important role in transmission of zoonotic hydatidosis (Eckert *et al*, 2001). Now, is the rate of pediatric infection was low? The answer is of course no, as the incubation period may extend up to ten years or more (Conraths *et al*, 2017). It was detected in the Egyptian childhood when caused complication in a schoolchild affected in the spinal cord (Mazyad *et al*, 1999) or

in another child with hydatidosis in the parotid gland (Madwar *et al*, 1995). Surveillance data is the key to understand the disease epidemiological situation and taking action in the risk areas, and for setting up priorities, which were necessary to monitor the progress of interventions and evaluate the outcomes of control actions (WHO, 2020).

In the present study, liver hydatid was more common, than lung hydatid incidence in liver 80% and lung 20% in all patients right side of liver was infected site and incidence was increased by age in endemic area-prolonged contact close contact farmer sheep and dogs. Hydatid cysts incidence increased with ages and coexisted lung cyst and the liver was first infected and passed infection to lung. This agreed with Miman and Yazar (2012) among Turkish patients.

In the present study, most of patients with liver hydatid were asymptomatic or present with non-specific symptoms and the common symptom and sign, right upper quadrant discomfort, pain right upper quadrant mass and weight loss. The symptoms of hydatid depended on which organs are affected most patients with hydatid cysts are a symptomatic, and the diagnosis is usually made incidentally during clinical or radiological examination for unrelated reasons (Sailly *et al.*, 2015).

In the present study, the growth of liver hydatid which depend not only on immunologic reaction between parasite and human but also on the resistance of enveloping strictures cysts near surface of the liver appear to grow more rapidly than centrally located cysts. The rate of cysts growth varied between 5mm to 7mm/month. Çiçekli and Akgül (2015) reported that hydatid cyst in vastus laterals was a very rare disease. Hydatid cyst should be kept in mind when observing soft tissue mass of the extremities in patients from the endemic area must considered.

Nayman *et al.* (2015) stated that the novel modified PAIR technique may be superior to catheterization by Seldinger technique due to its efficiency, easier application, lower severe complication rate, and lower cost.

In the present study, albendazole was routinely administered prior to intervention procedures with antibiotic. Pre interventional administration of albendazole 10mg/kg/d, 2 days before and continue 1 week after. All patients received oral albendazole post-operatively for 3 to 6 month. This agreed with Koca *et al.* (2016) who reported that all patients received treatment with albendazole and seven patients were successfully treated with puncture-aspiration-injection-re-aspiration (29.2%). In the present procedure 2 days before and 1 week after procedure, injection of scolical agent inside hydatid cysts, 3 time “hypertonic saline” destroy scolices and also the germinal layer, during puncture of cysts spill of sclerosis may occur so 10mg/kg/d albendazole or its principal metabolite. This hypertonic saline was safely and effectively used before (Ibrahim and Morsy, 2020). To minimize the complication of minimal access therapy combination of both P.A.I.R and laparoscopic surgery but not applied to the present patients.

Conclusion

The proposed hydatidosis risk factors are rural background, farming community, low socio-economic status, sheep & cattle rearing, lack of supply of potable water, and boys. Intrinsic defects in the filter mechanism of the liver and lungs, dissemination through enteric lymphatic channels, and patency of the ductus arteriosus in early infancy are the proposed causes of unusual presentation of hydatid disease in children.

The surgeon must decide what to do according to the organ involved, the number and size of the cysts, and complications. In children the liver and lung are commonly involved, but hydatidosis may also present as primary disease in unusual sites like the spleen, spinal cord and brain.

Recommendations

1- Hydatidosis is a serious zoonotic disease, and community-based measures are a must for prevention and disease control. 2- PAIR technique proved to a technique of choice in deep place liver hydatid. Besides, albendazo-

le 10mg/kg/d must be given as prophylaxis during PAIR technique. 3- US proved a good tool in PAIR technique. 4- Both PAIR and laparoscopic procedure are recommended as staging treatment surgery of liver hydatidosis. 5- Owners of pet dog, they must be registered, periodically examined, treated and sanitary deposit of its wastes and garbage are a must. Persons looking after or dealing with carnivorous animals must be routinely screened.

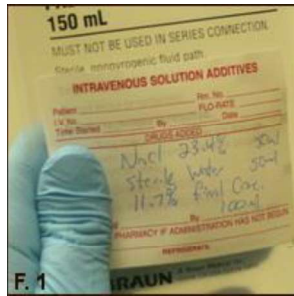
References

- Abdel-Alim, KM, El-Gohary, AH, Samaha, HA, Draz, AA, 1999:** Zoonotic parasitosis among some farm animals. *Zagazig Vet. J.* 27: 103-12.
- Abou-Eisha, AM, Abdel-Aal, AA, 1995:** Prevalence of some zoonotic parasites in dog fecal deposits in Ismailia City. *Assuit Vet. Med. J.*, 33:119-26
- Allan, JC, Craig, PS, Garcia, J, Noval, F, Mecnos, D, et al, 1992:** Coproantigen detection for immunodiagnosis of echinococcosis and taeniasis in dogs and humans. *J. Parasitol.*, 104:347-56.
- CDC, 2013:** Echinococcosis Treatment Information. *Archived* from original on 20 March, 2014.
- Conn, DB, 1994:** Cestode infections of mammary glands and female reproductive organs: potential for vertical transmission? *J. Helminthol. Soc. Washington*, 61:162-8.
- Çiçekli, Ö, Akgül, T, 2015:** An unusual cause of mass localized on vastus lateralis muscle in childhood: **Hydatid cyst**. *Int. J. Surg. Case Rep.* 6:C179-81.
- Conraths, FJ, Probst, C, Possenti, A, Boufana, B, Saulle, R, et al, 2017:** Potential risk factors associated with human alveolar echinococcosis: Systematic review and meta-analysis. *PLoS Negl Trop Dis.* 2017 Jul 17; 11, 7: e0005801.
- Eckert, J, Deplazes, P, 2004:** Biological, epidemiological, and clinical aspects of echinococcosis, a zoonosis of increasing concern. *Clin. Microbiol. Rev.* 17, 1:107–35.
- Eckert, J, Gottstein, B, Heath, D, Liu, FJ, 2001:** Prevention of echinococcosis in humans and safety precautions. In: J, Eckert, MA, Gemmell, FX, Meslin, & ZS, Pawlowski (ed.), *WHO /OIE Manual on echinococcosis in humans and animals: A public health problem of global concern.* WO for Animal Health; Paris, France.

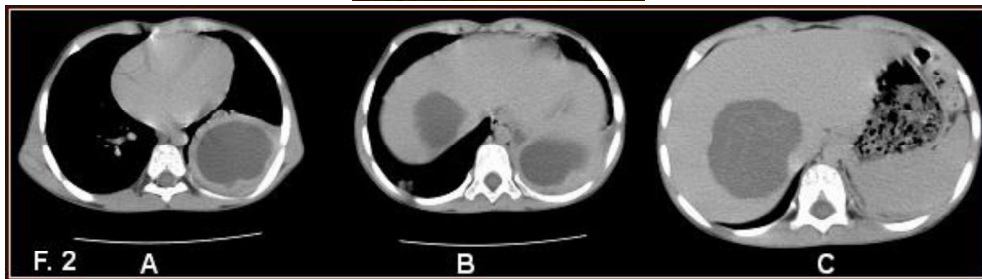
- Gabal, AM, Khawaja, FI, Mohammad, GA, 2005:** Modified PAIR technique for percutaneous treatment of high-risk hydatid cysts. *Cardiovasc. Intervent. Radiol.* 28, 2:200-8.
- Garcia, HH, 2010:** Pulmonary cystic echinococcosis. *Curr. Opin. Pulm. Med.* 16:257-61
- Gun, E, Etit, D, Buyuktalanci, DO, Cakalagaglu, F, 2017:** Unusual locations of hydatid disease: A 10-year experience from a tertiary reference center in Western Turkey. *Ann. Diagn. Pathol.* 29:37-40.
- Haridy, FM, Abou Holw, SA, Hassan, AA, Morsy, TA, 2008:** Cystic hydatidosis: A zoonotic silent health problem. *J. Egypt. Soc. Parasitol.* 38, 2:635-44.
- Haridy, FM, Ibrahim, BB, Morsy, TA, 2000:** Sheep-dog-man: The risk zoonotic cycle in hydatidosis. *J. Egypt. Soc. Parasitol.* 30, 2:423-9.
- Ibrahim, EA, Morsy, TA, 2020:** Tissue sparing technique in liver hydatid diseases: Three-way technique versus hydatid cone technique. *J. Egypt. Soc. Parasitol.* 50, 2:378-89.
- Jenkins, DJ, Rickard, MD, 1986:** Specificity of scolex and oncosphere antigens for the serological diagnosis of taeniid cestode infections in dogs. *Australian Vet. J.* 63:40-2.
- Koca, T, Dereci, S, Gençer, A, Duman, L, Aktaş, AR, et al, 2016:** Cystic echinococcosis in childhood: five-years of experience from a single-center. *Turk. Parazitol. Derg.* 40, 1:26-31
- Madwar, MA, Kamal, SM, El-Gozamy, BR, 1995:** Hydatid cyst of parotid gland. 1st Int. Cong. Zoono. Parasitosis, November 20-23, Cairo, Egypt.
- Mazyad, MAM, Morsy, TA, Habib, KhSM, 1999:** Vertebral unilocular hydatidosis in a shepherd and his wife. *J. Egypt. Soc. Parasitol.*, 29, 2:547-50
- Mazyad, SA, Mahmoud, L, Hegazy, M, 2007:** *Echinococcus granulosus* in stray dogs and Echino-IHAT in the hunters in Cairo, Egypt. *J. Egypt. Soc. Parasitol.* 37, 2:523-32
- Miman, O, Yazar, S, 2012:** Alveolar echinococcosis in Turkey: in the light of the literature *Turk. Parazitol. Derg.* 36, 2:116-20.
- Nayman, A, Guler, I, Keskin, S, Erdem, TB, Borazan, H, et al, 2015:** a novel modified pair technique using a trocar catheter for percutaneous treatment of liver hydatid cysts: A six-year experience. *Diagn. Interv. Radiol.* 22, 1:47-51.
- Sailly, M, Whiteley, R, Read, JW, Giuffre, B, Johnson, A, et al, 2015:** Pubic apophysitis: A previously undescribed clinical entity of groin pain in athletes. *Br J Sports Med.* 49, 12:828-34
- Schantz, PM, 1982:** Echinococcosis. In: *CRC Handbook Series on Zoonoses*. Vol. 1, Boca Raton, Florida: CRC Press, Inc., USA.
- Selim, MK, 1967:** Studies on some helminth parasites infecting dogs in Cairo and Giza, Egypt. *Vet. Med. J.* 17:37-48
- Varcasia, A, Garibba, G, Scala, A, 2004:** Diagnosis of *Echinococcus granulosus* in dogs. *J. Parasitol.* 46:409-12.
- WHO, 2014:** Echinococcosis; archived from the original on 21 February 2014, Switzerland.
- WHO, 2020:** Echinococcosis fact sheet, Geneva, Switzerland
- Wilson, ME, 1991:** *A World Guide to Infections Diseases Distribution, Diagnosis*. New York, Oxford, Oxford University Press.

Explanation of figures

- Fig. 1: Hypertonic saline (23.4%)
- Fig. 2: CT lower chest and upper abdomen showed, A: left basal posterior segment of lung cyst, B- liver and lung lesions (cystic lesion), c- deep site liver hydatid cysts affected segment "7".
- Fig. 3: A: CT localization of hydatid cysts, B. Localization site of insertion of big-tail using CT, C. CT showing big-tail inside cystic cavity
- Fig. 4: A: Aspiration more than ½ of hydatid cysts fluid, B: US after aspiration of more than ½ cysts volume, C: US showed expansion of cysts after injection 80cc hypertonic saline.
- Fig. 5: A: Injection of hypertonic saline 80cc, B: US up on liver hydatid cysts showed expansion of cysts, C: showed aspiration of injected volume.
- Fig.6: Connecting big-tail to collecting bag
- Fig. 7: A: measuring cyst cavity showed reduce size of cysts, B: notice floating of germinal layer.
- Fig. 8: A: disappearance of floating germinal layer, B: still cystic cavity but reduce in its size.
- Fig. 9: CT liver "CT report, abdomen/plevic" there is a large thick walled but there density cysts arising from the right lobe of the liver measuring approximately 10 cm (AP) by 20 cm "transverse" with a thick rim measure 3 mm, middle enlarged retroperitoneal lymph nodes.
- Fig. 10: A: big-tail connected to collected bag and passive drainage of about 1000cc of hydatid fluid in bag, B: fixation of big-tail.
- Fig. 11: US up on hydatid cysts to ass-cyst and hydatid fluid inside.
- Fig. 12 A: First injection of hypertonic saline 80ml. B: Injection of hypertonic saline "first injection" under US to show felling of cystic cavity. C: Aspiration of injected hypertonic saline under US.
- Fig. 13: A: Injection of hypertonic saline "80cc", second. B: US showing cysts cavity felling by hypertonic saline secondary injection. C: Aspiration of hypertonic saline after 15-20 minute from injection under US.
- Fig. 14: US done 4 hour post-operative showing cysts wall and fluid inside cysts.
- Fig. 15: US done 1 week post-operative showing reduction size of cysts and floating germinal layer.
- Fig. 16 A: US marked reduction of cysts volume and near to complete disappearance of germinal layer "small rim of germinal layer"
- B: CT upon cyst one month post-operative.



F. 1

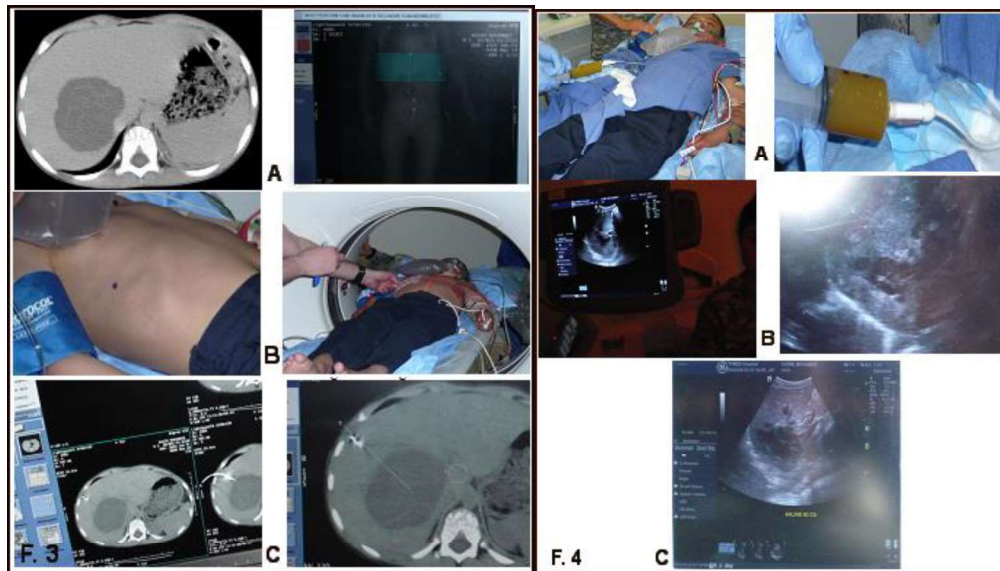


F. 2

A

B

C

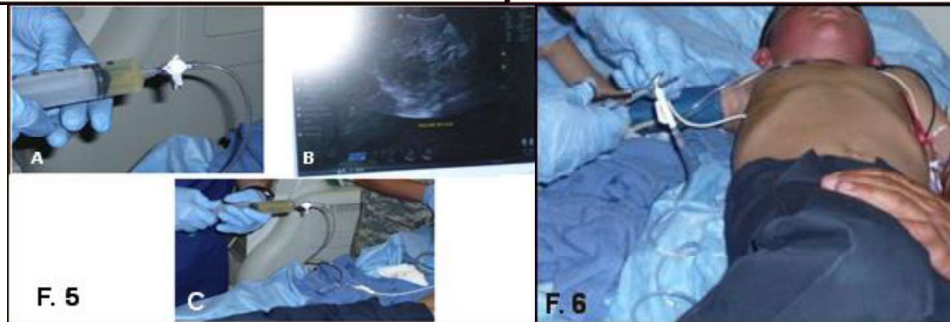


F. 3

F. 4

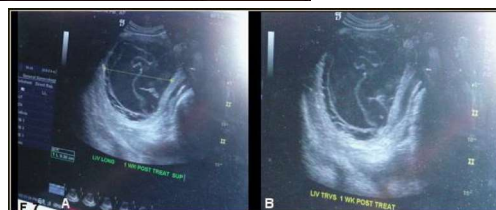F. 5

F. 6



F. 5

F. 6



F. 7

