

## **Anal Abscesses and Different Methods of its Surgical Management**

**Mana Ali Mueidh Al Hajlan, Mohammed Hundur Alasmari, Abdullah Salem Al Haider, Abdulaziz Abdullah Alhazmi, Nasser Naji Mohsen Al harthi, Yaqoub Mubarak Ali Alhamami**

Faculty of Medicine, Najran University, KSA

### **ABSTRACT**

**Background and Objectives:** in this review we discuss background of anal abscess and fistula, as well focused on different surgical approaches for dealing with anal abscess, their effectiveness and difficulties after surgery.

**Patients and Methods:** We conducted narrative review by searching published literatures in the following databases: MEDLINE/PubMed, and Embase, for all studies concerning with types of Anal abscesses and diagnosis in addition to surgical management approaches “June, 2018”.

**Results:** Anorectal abscesses are one of the commonest anorectal problems encountered by surgeons. They are usually cryptoglandular in origin and are associated with an anal fistula in 30% – 70% of cases. When the incriminating gland originates from the posterior midline and traverses the conjoint longitudinal muscle into the deep postanal space, a deep postanal abscess results. Further extension of this infective process into the unilateral or bilateral ischioanal fossa leads to a horseshoe abscess. This type of abscess accounts for about 15% – 20% of anorectal abscesses and its management remains challenging to surgeons.

**Conclusion:** Anorectal abscesses are common anorectal problems, early management is mandatory, almost always require surgical drainage, even if they have spontaneously discharged.

**Keywords:** Anal abscesses, Surgery, perianal abscesses, postanal abscess, surgical management

### **INTRODUCTION**

A perianal abscess is defined as a local gathering of pus in the perianal tissues. It could prolong right into the ischioanal fossa, on one or both sides, ultimately develop a horse-shoe shaped collection, or much less generally track up in the direction of and with the levator musculature<sup>[1], [2]</sup>. It is a usual problem contributing dramatically to the daily surgical work<sup>[3]</sup>. One of the most common aetiology is considered to be glandular infection emerging from the anal crypts<sup>[1]</sup>. This could describe why a proportion of perianal abscesses are connected with fistula-in-ano either from the start or as a later symptom in 26- 37% of the moment<sup>[2,3,4]</sup>. Fistula-in-ano could increase possibility of abscess recurrence which after that requires repeat drainage. Despite having no recurring abscess, more treatments might be required for fistula associated signs and symptoms such as discharge or perianal soreness. For these reasons some surgeons have taken into consideration primary fistula treatment at the time of abscess drainage in order to reduce the demand for further surgery. The downside of this approach is that some fistulae could spontaneously settle with time and would have unnecessarily gone through fistula surgery. Second of all fistula surgery in the presence of inflamed perianal tissues might lead to damages to the anal sphincter and ensuing incontinence. In this review we discussed background of anal abscess and fistula; as well we focused on different surgical approaches for dealing

with anal abscess, their effectiveness and difficulties encountered after surgery.

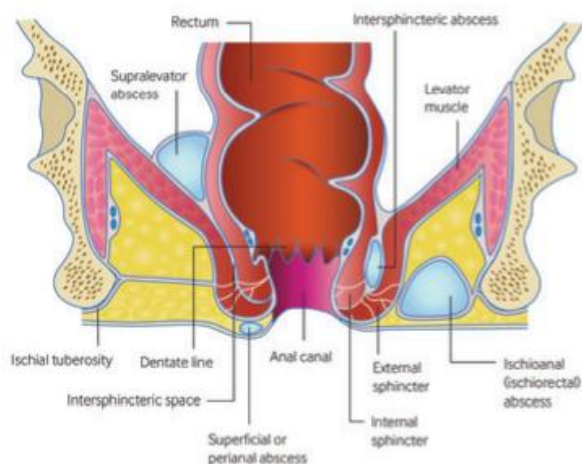
### **PATIENTS AND METHODS**

We conducted narrative review by searching published literature in the following databases: MEDLINE/PubMed, and Embase, for all studies concerning with types of Anal abscesses and diagnosis with surgical management approaches “June, 2018”. Reference lists of other relevant publications were screened to identify additional potentially relevant studies that were not identified by the first method of literatures search. We restricted our search for only English published articles with human subject.

### **DISCUSSION**

In about third of patients, a fistula was discovered either at the time or subsequent to abscess drainage<sup>[10,11]</sup>. Many fistulas develop on the background of a pre-existing abscess<sup>[12]</sup>. They may additionally take place automatically and (less frequently) in the context of inflammatory bowel condition, tuberculosis, trauma, or as a problem of neighborhood operations (such as haemorrhoidectomy or episiotomy). There was no definitive means of avoiding or forecasting fistula occurrence or formation after abscess drainage. It was originally believed that discovery of enteric organisms in the perianal abscess was related to an enhanced danger of succeeding fistula formation<sup>[13]</sup> Nonetheless, a recent situation series of 164

patients found no statistically considerable organization between the visibility of gut-derived microorganisms and the advancement of a fistula (chances ratio 0.48 (95% confidence interval 0.17 to 1.37)) or reoccurrence of perianal abscess (odds proportion 1.66 (0.46 to 6.01))<sup>[14]</sup>. Moreover, a multicentre, double-blinded randomised test showed that antibiotic therapy after abscess drainage offered no security against subsequent fistula development<sup>[15]</sup>.



**Figure (1):** Anal abscesses<sup>[29],[30]</sup>.

Offer very early referral to a surgical group for conversation of incision and drainage, and avoid prescribing tests of antibiotics in the society. The Royal College of Surgeons' guidelines on emergency situation surgery suggested that abscesses are preferably drained within 24 hours<sup>[16]</sup>. A double-blind randomized controlled trial and a prospective scientific trial found that the enhancement of prescription antibiotics to drainage does not boost healing rates or decrease recurrence<sup>[17,18]</sup>. Due to the danger of deep infection, sepsis, and necrotizing soft tissue infection, patients who are immunosuppressed, have diabetes, or have proof of systemic sepsis or cellulitis require immediate drainage on the day of presentation. **Incision and drainage:** Manage those with evidence of sepsis according to the "sepsis six" guidelines,<sup>[19]</sup> and deal with the abscess with drainage of the caught perianal sepsis. If the abscess is clinically evident, imaging is hardly ever needed. Incision and drainage can be performed under general anaesthesia or neighborhood anaesthesia depending upon the intricacy of the case and patient preference. Local anaesthesia is normally less effective in the presence of inflammation but is chosen in superficial abscesses

or in pregnancy. Incision and drainage are performed after infiltration of the location with 1% lidocaine. Ethylene chloride spray can be made use to numb the area immediately prior to seepage. If general anaesthesia is selected, this permits for an in-depth examination under anaesthesia that includes an assessment of the anorectum with a rigid sigmoidoscope and expedition of the abscess cavity. Findings of examination that may find connection and a hidden reason for the abscess such as Crohn's disease include proctitis, abscess, structures, cracks or complex or reoccurring abscess drainage, and fistulas. Dimension of faecal calprotectin might serve, as raised calprotectin suggests swelling within the intestine and might aid with medical diagnosis of Crohn's condition. Hence, if the above examination features are apparent the patient must be provided a faecal calprotectin assay and recommendation to a gastroenterologist for endoscopic evaluation. A lot of abscesses are drained pipes on the surface, however periodically deep internal abscesses are drained into the anal canal. In situations of severe pain without unbiased evidence of an abscess (and in the lack of one more reason such as a rectal crack or a thrombosed haemorrhoid) at exam under anaesthesia, take into consideration magnetic vibration imaging. Endoanal ultrasound is made use of in some centres to examine for perianal fistula, however its duty is limited by discomfort in the acute setup. A retrospective successive series of 500 patients with perianal abscesses discovered a re-operation rate of 7.6% (within 10 days of the operation) and concluded that the commonest factors for these were insufficient drainage, early skin closure, and missed out on loculations (rare in perianal abscesses)<sup>[20]</sup>. In spite of evidence recommending that treating a linked fistula in the acute setup decreases subsequent reoccurrence,<sup>[21]</sup> they wants agreement to sustain surgeons undertaking instant fistula treatment at incision and drainage of perianal abscesses, particularly if they are less experienced. **Intersphincteric method:** This sphincter sparing technique was first explained by Tan et al.<sup>[22]</sup>. It is based upon the concept of the Ligation of Intersphincteric Fistula Tract (LIFT) treatment explained by Rojanasakul<sup>[23]</sup>. It includes getting to the deep post anal room by means of the intersphincteric area and posteriorly over the outside sphincter. The deep post anal space is drained pipes and curetted, the internal

opening of the fistula on the surface area of the interior sphincter is shut, a suction drain is left in the DPA space and the intersphincteric room is then re-apposed. The authors discovered that for patients who mainly had this as a single stage treatment, there was 91.7% success. Nevertheless, those patients that had a prior drainage prior to this strategy had an 80% failure rate. This was connected to the difficulties with dissection in the intersphincteric area and identifying the intersphincteric section of the fistula tract following previous drainage and subsequent fibrosis. Recurrences were effectively managed with repeat drainage, positioning of draining Setons and a subsequent endoanal innovation flap treatment. The writers do not present any kind of data on urinary incontinence rates in their research study **Fistulotomy with incision of perianal abscess-fistula:** The perianal abscess contributes dramatically to emergency situation surgical workload and the multitude of studies around reflects convenience of patient employment. We determined five research studies summed up in Table 1 (n = 408) checking out incision and drainage alone of perianal abscess fistula vs. incision incorporated with fistula surgery [5,6,8,9,25]. The Tang study randomized patients after an interior opening was demonstrated in theatre prior to laceration of the abscess [25]. Hebjorn *et al.* [5] executed laceration of the abscess then patients were randomized on the 1st postoperative day for fistula surgery on the 3rd postoperative day (i.e. on same admission) [5]. The various other 3 studies randomized patients preoperatively however huge numbers (83-88%) were 'found' to have an anal fistula in the fistula surgery arm. As the occurrence of fistula in follow-up after drainage of perianal abscess arrays from 26% to 37% [12] this questions regarding the majority of fistulae found in these studies, i.e., the bulk of the patients allotted to fistula surgery were not destined to have fistulas and thus had unnecessary sphincter department.

**Table (1):** Studies comparing fistula surgery at time of Incision of perianal abscess (n = 5).

Study, Year	n	Recurrence/ further surgery	Minor incontinence	Follow- up	Notes
Hebjorn [5]	41	I&D alone, 3/ 18 (17%) I&D + F, 2/ 20 (10%)	I&D alone, 0/ 18 (0%) I&D + F, 8/20 (10%)*	12 months	Patients randomized next day after I&D and fistulotomy performed on 3rd postoperative day
Schouten[9]	70	I&D alone, 13/34 (41%) I&D + F, 1/ 36 (3%)	I&D alone, 6/ 28 (21.4%) <sup>a</sup> I&D + F, 13/ 33 (39.4%) <sup>b</sup>	42.5 months	32/36 randomized to fistulectomy found to have fistula
Tang [25]	45	I&D alone, 3/ 21 (14%) I&D + F, 0/ 24 (0%)	I&D alone, 1/ 21(4%) I&D + F, 0/24 (0%)	12 months	Sealed envelope randomization in theatre after internal opening was demonstrated
Ho [6]	52	I&D alone, 8/ 28 (29%) I&D + F, 1/ 24 (0%)	I&D alone, 0/ 28 (0%) I&D + F, 0/24 (0%)	15.5 months	21/24 in fistula surgery arm found to have fistula
Oliver[8]	200	I&D alone, 29/100 (29%) I&D + F, 5/ 100 (5%)	I&D alone, 0/ 100 (0%) I&D + F, 6/ 100 (6%)	12 months	83/100 in fistula surgery arm found to have fistula

**Abbreviation:** n, study sample size; I&D, incision and drainage; I&D + F, incision and drainage with fistula surgery.  
\*Includes six patients with flatus incontinence and two with soiling.  
<sup>a</sup> Includes four patients with recurrence who subsequently had fistulectomy.  
<sup>b</sup> Fistula surgery patients underwent incision, drainage and fistulectomy with primary partial internal sphincterectomy.

**Marsupialization after fistulotomy:**

Marsupialization after anal fistula surgery is postulated to leave less raw unepithelialized tissue in the fistulotomy (or fistulectomy) injury consequently leading to much less postoperative blood loss and faster injury healing. Two RCTs have reviewed this area (Table 2). Ho (1998) (n =103) randomized patients to laying open alone Vs. laying open + marsupialization and showed faster healing times (6 weeks vs 10 weeks, P < 0.001) in favour of marsupialization [27]. **Pescatori *et al.*** [26] randomized 46 fistula patients to fistulotomy Vs. fistulotomy + marsupialization. They showed much less blood loss and quicker decrease in postoperative injury size with marsupialization [26]. While data from both studies could not be merged due to distinctions between the participants and outcome steps, taken together both studies give excellent evidence that marsupialization is valuable after fistulotomy.

**Table (2):** Marsupialization at time of fistulotomy/ fistulectomy.

Study, Year	Participants	n	Interventions	Outcome	Follow-up	Notes
Ho [27]	Uncomplicated interior trans-sphincteric fistulae included.	103	Fistulotomy vs fistulotomy with marsupialization	Healing time: 10 weeks vs 6 weeks (P < 0.001) Minor incontinence: 6/52 vs 1/51 (ns) Recurrence: 2/52 vs 1/51 (ns)	9 weeks	High, recurrent, horse-shoe or extrasphincteric fistulae or those with multiple openings excluded
Pescatori [26]	High, recurrent and horse-shoe fistulae included	46	Fistulotomy/ fistulectomy vs fistulotomy/ fistulectomy with marsupialization	Pain scores at 12 h: 3.4 vs 3.5 (ns) Bleeding: 11/24 vs 8/22 (P < 0.05) Wound size: 543 mm <sup>2</sup> vs 217 mm <sup>2</sup> (P < 0.01) Repeat surgery: 3/24 vs 3/22 (ns) Minor Incontinence: 2/24 vs 2/22 (ns)	10 months	Intersphincteric or superficial fistulae excluded

n, study sample size.

**Advancement Flaps and Direct Closure:**

Using development flaps normally involves a two stage treatment. The initial stage requires adequate drainage of the DPAS with Seton positioning and the 2nd phase is the flap procedure to close the fistula. This technique has been made use of to effectively take care of recurrent abscesses adhering to the intersphincteric approach. However, its results depend largely on the competence of the drainage of the DPAS Koehler *et al.* [24] used 4 various methods to close the interior fistula opening in individuals with horseshoe fistulas. 3 of these were improvement flaps - rectal wall advancement flap (RWAF), mucosa-submucosa flap (MSAF), anocutaneous advancement flap (ACAF). The last approach was direct closure of the interior opening. The flaps were built regarding 2 to 3 months complying with abscess drainage and Seton placement in patients that provided with abscesses. Recurrence rates were 35% for RWAF, 25% for MSAF and 25% for ACAF. Traditionally this approached results seen in patients going through primary fistulotomy. The writers report a decrease in continence degrees in concerning 32% of patients. The writers as a result wrapped up that this strategy is

sensible. In choose patients, straight closure of the fistulous system has been found to be a feasible alternative. These endure a really elastic rectal canal. Koehler *et al.* [24] reported lead to 11 patients who underwent straight closure of the inner fistula opening complying with ample abscess drainage and Seton placement. A closure of both the muscular defect and the superior mucosa was done. They noted superb results with this technique. All patients were recovered with 0% reappearance. Abscesses Recurrence rates were 25% for MSAF, 35% for RWAF and 25% for ACAF. This was similar to outcomes historically seen in patients undergoing primary fistulotomy. The authors reported a decrease in continence degrees in about 32% of patients. The writers as a result wrapped up that this approach is practical. In choose patients, straight closure of the fistulous system has been found to be a feasible option. These are patients with a really elastic rectal canal. Koehler *et al.* [24] reported cause 11 patients that went through straight closure of the interior fistula opening following ample abscess drainage and Seton positioning. A closure of both the muscle issue and the overlying mucosa was done. They keep in mind excellent outcomes with this approach. All patients were recovered with 0% recurrence.

**CONCLUSION**

Anorectal abscesses are one of the commonest anorectal problems encountered by surgeons. They are usually cryptoglandular in origin and are associated with an anal fistula about 30% – 70% of the time. When the incriminating gland originates from the posterior midline and traverses the conjoint longitudinal muscle into the deep postanal space, a deep postanal abscess results. Further extension of this infective process into the unilateral or bilateral ischiorectal fossa leads to a horseshoe abscess. This type of abscess accounts for about 15% – 20% of anorectal abscesses and their management remains challenging to surgeons. Perianal abscesses almost always require surgical drainage, even if they have spontaneously discharged. Patients with diabetes, immunosuppression, evidence of systemic sepsis, or substantial local cellulitis require urgent drainage. In uncomplicated cases, offer incision and drainage within 24 hours. Drainage leads to an open cavity that typically takes 3-4 weeks to heal. Persistent failure to heal may indicate an underlying fistula. Fistula surgery at the time of

incision and drainage of a perianal abscess significantly reduces the likelihood of persistent fistula or abscess and the need for repeat surgery. A small number of patients may get transient incontinence following abscess drainage with fistula treatment. The evidence that patients may get minor incontinence for longer following fistula surgery with abscess drainage remains weak.

#### CONFLICTS OF INTEREST

There are no conflicts of interest.

#### REFERENCES

1. **Whiteford MH, Kilkenny J, Hyman N *et al.* (2005):** The Standards Practice Task Force, The American Society of Colon and Rectal Surgeons. Practice parameters for the treatment of perianal abscess and fistula-in-ano (revised). *Dis Colon Rectum*, 48:1337–42
2. **Read DR, Abcarian H (1979):** A prospective survey of 474 patients with anorectal abscess. *Dis Colon Rectum*, 22:566–8.
3. **Nelson R (2002):** Anorectal abscess fistula: what do we know?. *Surg Clin North Am.*, 82:1139–51.
4. **Henrichsen S, Christiansen J (1986):** Incidence of fistula-in-ano complicating anorectal sepsis: a prospective study. *Br J Surg.*, 73:371–2.
5. **Hebjorn M, Olsen O, Haakansson T *et al.* (1987):** A randomized trial of fistulotomy in perianal abscess. *Scan J Gastroenterol.*, 22:174–6.
6. **Ho YH, Tan M, Chui CH *et al.* (1997):** Randomized controlled trial of primary fistulotomy with drainage alone for perianal abscesses. *Dis Colon Rectum*, 40:1435–8.
7. **Li D, Yu B (1997):** Primary curative incision in the treatment of perianorectal abscess. *Chin J Surg.*, 35(9):539–40.
8. **Oliver I, Lacueva FJ, Pérez Vicente F *et al.* (2003):** Randomized clinical trial comparing simple drainage of anorectal abscess with and without fistula track treatment. *Int J Colorectal Dis.*, 18:107–10.
9. **Schouten WR, Van Vroonhoven T (1991):** Treatment of anorectal abscess with or without primary fistulectomy: Results of a prospective randomized trial. *Dis Colon Rectum*, 34:60–3.
10. **Vasilevsky CA, Gordon PH (1984):** The incidence of recurrent abscesses or fistula-in-ano following anorectal suppuration. *Dis Colon Rectum*, 35:126–30.
11. **Henrichsen S, Christiansen J (1986):** Incidence of fistula-in-ano complicating anorectal sepsis: a prospective study. *Br J Surg.*, 35:371–2.
12. **Nelson R (2002):** Anorectal abscess fistula: what do we know? *Surg Clin North Am.*, 35:1139–1151.
13. **Grace RH, Harper IA, Thompson RG (1982):** Anorectal sepsis: microbiology in relation to fistula-in-ano. *Br J Surg.*, 35:401–3.
14. **Xu RW, Tan K-K, Chong C-S (2016):** Bacteriological study in perianal abscess is not useful and not cost-effective. *ANZ J Surg.*, 35:782–784.
15. **Sözener U, Gedik E, Kessaf A *et al.* (2011):** Does adjuvant antibiotic treatment after drainage of anorectal abscess prevent development of anal fistulas? A randomized, placebo-controlled, double-blind, multicenter study. *Dis Colon Rectum*, 35:923–9.
16. **Royal College of Surgeons (2011):** Emergency surgery: standards for unscheduled surgical care. Available at: [www.rcseng.ac.uk/library-and-publications/college-publications/docs/emergency-surgery-standards-for-unscheduled-care/](http://www.rcseng.ac.uk/library-and-publications/college-publications/docs/emergency-surgery-standards-for-unscheduled-care/).
17. **Llera JL, Levy RC (1985):** Treatment of cutaneous abscess: a double-blind clinical study. *Ann Emerg Med.*, 35:15–9.
18. **Macfie J, Harvey J (1977):** The treatment of acute superficial abscesses: a prospective clinical trial. *Br J Surg.*, 35:264–6.

19. **Dellinger RP, Levy MM, Rhodes A *et al.* (2013):** Surviving Sepsis Campaign Guidelines Committee including the Pediatric Subgroup. Surviving Sepsis Campaign: international guidelines for management of severe sepsis and septic shock: 2012. *Crit Care Med.*, 356:580-637.
20. **Onaca N, Hirshberg A, Adar R (2001):** Early reoperation for perirectal abscess: a preventable complication. *Dis Colon Rectum*, 356:1469-73.
21. **Malik AI, Nelson RL, Tou S (2010):** Incision and drainage of perianal abscess with or without treatment of anal fistula. *Cochrane Database Syst Rev.*, (7): CD006827.
22. **Tan KK, Koh DC, Tsang CB (2013):** Managing Deep Postanal Space Sepsis via an Intersphincteric Approach: Our Early Experience. *Ann Coloproctol.*, 29(2):55-9.
23. **Rojanasakul A (2009):** LIFT procedure: a simplified technique for fistula-in-ano. *Tech Coloproctol.*, 13(3):237-40.
24. **Koehler A, Risse-Schaaf A, Athanasiadis S (2004):** Treatment for horseshoe fistulas-in-ano with primary closure of the internal fistula opening: a clinical and manometric study. *Dis Colon Rectum*, 47(11):1874-82.
25. **Tang CL, Chew SP, Seow-Choen F (1996):** Prospective randomized trial of drainage alone vs. drainage and fistulotomy for acute perianal abscesses with proven internal opening. *Dis Colon Rectum*, 39: 1415–7.
26. **Pescatori M, Ayabaca SM, Cafaro D *et al.* (2006):** Marsupialization of fistulotomy and fistulectomy wounds improves healing and decreases bleeding: a randomized controlled trial. *Colorectal Dis.*, 8: 11–4.
27. **Ho YH, Tan M, Leong AF *et al.* (1998):** Marsupialization of fistulotomy wounds improves healing: a randomized controlled trial. *Br J Surg.*, 85: 105–7.