



## Side effects of dexibuprofen have been ameliorated with vitamin E

Gamal El-Din A.M. Shams, Suhair A. Abd El-Latif, Haydi H. El Din Abdallah

Pharmacology Department, Faculty of Veterinary Medicine, Zagazig University, Egypt

### ABSTRACT

The present study was designed to define the effects of daily administration of 100 mg vitamin E/kg on side effects in mice treated with dexibuprofen (7.2 mg/kg, P.O once daily) for 21 consecutive days and its antioxidant scavenging capacity. Blood samples were collected from mice on 1<sup>st</sup>, 2<sup>nd</sup>, 14<sup>th</sup>, 21<sup>st</sup> days post-treatment and tissue samples were collected on 7<sup>th</sup>, 14<sup>th</sup> days post-treatment to assess the protective effects of vitamin E. The results indicated significant increase in antioxidant enzymes Glutathione peroxidase, dismutase *superoxide* dismutase(SOD)&catalase (CAT) together decrease the level of malondialdehyde besides diminished and in portal fibrosis and decrease in congestion of hepatic blood vessels and sinusoids caused by dexibuprofen administration as demonstrated by kidney histopathology Therefore, Vitamin E should be taken with dexibuprofen to decrease its side effects.

**Key words** Antioxidant activity, Dexibuprofen, Histopathology, Vitamin E.

(<http://www.bvmj.bu.edu.eg>)

**BVMJ-36(1): 382-392, 2019)**

## 1. INTRODUCTION

Dexibuprofen is non-steroidal anti-inflammatory drug. It's the active dextrorotatory enantiomer of ibuprofen. Most ibuprofen formulations contain a racemic mixture of both isomers (Hardikar, 2008). Dexibuprofen is the single pharmacologically effective enantiomer of Rac-ibuprofen. Rac-ibuprofen and dexibuprofen differ in their physic-chemical properties, in terms of their pharmacological properties and their metabolic. Dexibuprofen has proven at least comparable efficacy to diclofenac, naproxen and celecoxib and has shown a favorable tolerability (Kaehler et al., 2003). Antiplatelet effect of dexibuprofen (maximal inhibition of aggregation was 48-55% for adenosine diphosphate and 90-95% for collagen and arachidonic acid) was equal to the effect of aspirin. The main difference

between the two drugs was in the degree of recovery of platelet function. The effect of aspirin persisted for 24 h after the last dose (remaining inhibition 50% respect to the pretreatment value), whereas platelet aggregation had returned to baseline pretreatment values within 24 hr. after dexibuprofen was stopped (Gonzalez et al., 2007).

Dexibuprofen has an equal efficacy and comparable safety and tolerability with celecoxib in treatment of osteoarthritis. Dexibuprofen shows excellent tolerability, safety than other low-density lipoprotein like diclofenac sodium, dexibuprofen has stronger pain reducing effect than racemic ibuprofen (Kumaresan, 2010).

Dexibuprofen-antioxidant conjugates were synthesized with the aim to reduce its

## Vit E protection against side effects of dexibuprofen

gastrointestinal effects. The esters analogs of dexibuprofen were obtained by reacting its -COOH group with chloroacetyl derivatives. The in vitro hydrolysis data confirmed that synthesized prodrugs were stable in stomach while undergo significant hydrolysis in 80% human plasma and thus release free dexibuprofen. The minimum reversion was observed at pH 1.2 suggesting that prod rugs are less irritating to stomach than dexibuprofen. The anti-inflammatory activity is more significant than the parent dexibuprofen exhibited that synthesized prodrugs formed stable complexes with the COX-2 protein therefore concluded that the synthesized prodrugs have promising pharmacological activities with reduced gastrointestinal adverse effects than the parent drug (Ashraf et al., 2016).

Dexibuprofen is as effective and tolerable as ibuprofen. A dose of 5 mg kg<sup>-1</sup> and 7 mg kg<sup>-1</sup> dexibuprofen in place of 10 mg kg<sup>-1</sup> ibuprofen would be sufficient to control fever caused by URTI in children (Yoon et al., 2008).

The aryl propionic acid derivative dexibuprofen was the most potent antiplatelet drug, and its pharmacodynamics profile is similar to aspirin (De La Cruz et al., 2010).

Non-steroidal anti-inflammatory drugs including selective cyclo-oxygenase-2 COX-2 inhibitors COXIBs are commonly used to treat acute gout. Published guidelines recommend their use to treat acute attacks, using maximum recommended doses for a short time (Van Durme et al., 2014).

In the lipid phase, tocopherols and carotenes as well as oxy-carotenoids are of interest, as are vitamin A and ubiquinol. In the aqueous phase, there are ascorbate, glutathione and other compounds imbalance between oxidants and antioxidants in favor of the oxidants, potentially leading to damage, is termed 'oxidative stress'. Oxidants are formed as a normal product of aerobic metabolism but can be produced at elevated rates under pathophysiological conditions. Antioxidant defense involves several strategies, both enzymatic and non-enzymatic. In addition to the cytosol, the nuclear and mitochondrial matrices and

extracellular fluids are protected. Overall, these low molecular mass antioxidant molecules add significantly to the defense provided by the enzymes superoxide dismutase, catalase and glutathione peroxidases (Sies., 1997). Defenses against free radical damage include tocopherol vitamin E, ascorbic acid vitamin C beta-carotene, glutathione, uric acid, bilirubin, and several metalloenzymes including glutathione peroxidase (selenium), catalase (iron), and superoxide dismutase (copper, zinc, manganese) and proteins such as ceruloplasmin (copper), superoxide dismutase (copper, zinc, manganese) and superoxide dismutase (copper, zinc, manganese). Ceruloplasmin (copper) superoxide dismutase has powerful anti-inflammatory activity (Mcginness et al., 1978). For example, superoxide dismutase is a highly effective experimental treatment of chronic inflammation in colitis treatment with superoxide dismutase decreases reactive oxygen species generation and oxidative stress and thus inhibits endothelial activation. Therefore, such antioxidants may be important new therapies for the treatment of inflammatory bowel disease (Seguí et al., 2004).

Dexibuprofen was approved that it had nephrotoxicity-hepatotoxicity in rats. Therefore, this study aims to hepato-nephro-protective effects of vitamin E (100 mg/kg, P.O. once daily) against dexibuprofen side effects given for 21 days when vitamin E upon it co-administered with dexibuprofen.

## 2. MATERIALS AND METHODS

### 2.1 Drugs and chemicals

Dexibuprofen was obtained as SERACTIL<sup>R</sup> 500 mg, tablets that was supplied by Gebro pharmaceutical industry). Dexibuprofen was dissolved in normal saline. And given at a dosage of 7,2mg/kg according to Pagets and Barnes (1964) to convert the dose of human to rat. Vitamin E (vitamin E capsule) it was supplied by Pharco Pharmaceutical CO Alex., Egypt. Vitamin E dissolved in corn oil.

### 2.2 Animals

The present study was carried on 80 adult male albino rats weighing 150-200g. Animals were purchased from Laboratory

Animal Farm, Faculty of Veterinary Medicine, Zagazig University. All animals were housed in polypropylene cages with wood-chip bedding and were maintained on 12 hr./dark schedule in a temperature and humidity-controlled room. All animals were given access to food and water ad libitum. The animals were kept under observation for two weeks before using to ensure stabilization.

### 2.3 Experimental design

A parallel study design was adapted as 4 groups. The 1<sup>st</sup> group (control): rats in this group were not medicated and received normal saline, the 2<sup>nd</sup> group (Vitamin E) rats in this group received repeated oral doses of vitamin E (100 mg/kg B. WT.) for successive 21 days as antioxidant, once daily. Rats were classified into 4 groups each contain 20 rats. The 3<sup>rd</sup> group (Dexibuprofen therapeutic dose) rats in this group received repeated oral doses of dexibuprofen (7.2 mg/kg b. wt.) for successive twenty one days, once daily. The 4<sup>th</sup> group (Dexibuprofen and Vitamin E (Dex. + Vit. E)) rats in this group received repeated oral doses of dexibuprofen (7.2 mg/kg b. wt.) for successive 21 days plus vitamin E (100 mg/kg B. WT.) once daily for 21 days.

### 2.4 Preparation of serum and tissue sample

At the end of experiment (24 hrs. after the last dose) rats were sacrificed and blood samples collected in a sterile Wasserman tube without anticoagulant from 5 rats/group at the 1<sup>st</sup>, 7<sup>th</sup>, 14<sup>th</sup>, 21<sup>st</sup> days post treatment and allowed to clot for 30 minutes and serum was separated by centrifugation at 3000 rpm for 15 minutes, and the top yellow layers of serum were pipette off without disturbing the white buffy layer. Serum was stored at 20°C in Eppendorf tubes till the time of the work for determination of serum level of antioxidant enzymes. The liver and the kidney of each rats were collected at 7<sup>th</sup> and 14<sup>th</sup> days post-treatment. They were isolated and kept in 10% phosphate -buffered formalin for histopathological evaluation.

### 2.5 Biochemical markers of antioxidant activity

Determination of malondialdehyde (MDA), glutathione peroxidase activity (GPX), superoxide dismutase activity, catalase activity (CAT) according to the method described formerly (Aebi, 1984; Nishikimi et al., 1972; Paglia and Valentine, 1967, respectively).

### 2.6 Renal and hepatic histopathological evaluation

Kidney and liver tissues were fixed in 10% neutral buffered formalin solutions for 24 hours. Then tissue processing and paraffin blocks preparation were done. Masson, trichrome and hematoxylin-eosin stains were used to evaluate fibrotic areas and necro inflammation activity (Suvarna et al., 2013).

### 2.7 Statistical analysis

Statistical analyses were carried out by the one-way analysis of variance (ANOVA) (Tamhane and Dunlop, 2000).

## 3. RESULTS

### 3.1. Effects of dexibuprofen, Vitamin E and their combination on antioxidant enzymes.

Effect of combination between Dexibuprofen and Vitamin E on Determination of MDA level in the 1<sup>st</sup> day, there was a decrease in amount of MDA ( $15.426 \pm 0.958$  nmol/ml) compared with ( $20.56 + 0.994$  nmol/ml) for dexibuprofen group. On the 7<sup>th</sup> day resulted on a decrease in the amount of MDA ( $10.14 \pm 0.123$  nmol/ml) compared with ( $14.01 + 0.123$  nmol/ml) compared with ( $14.01 \pm 0.751$  nmol/ml) for dexibuprofen group. On the 14<sup>th</sup> day resulted in a decrease in Determination of MDA conc. ( $8.366 \pm 0.389$  nmol/ml) compared with ( $10.49 \pm 0.262$  nmol/ml) for the dexibuprofen group. On the 21<sup>st</sup> day, there was decrease in the level of MDA ( $7.47 \pm 0.068$  nmol/ml) compared with ( $8.10 + 0.184$  nmol/ml) for dexibuprofen group as shown in table (1).

Effect of combination between Dexibuprofen and Vitamin E on GPX. On the 1<sup>st</sup> day resulted in an increase in GPX activity ( $91.59 \pm 1.37$  U/L) compared with ( $78.45 \pm$

## Vit E protection against side effects of dexibuprofen

5.02 U/L) for dexibuprofen group. On the 7<sup>th</sup> day there is an increase in GPX activity ( $103.76 \pm 2.97$  U/L) compared with ( $87.80^c \pm 3.37$  U/L) for dexibuprofen group. On the 14<sup>th</sup> day there is an increase in GPX activity ( $110.07 \pm 0.587$  U/L) compared with ( $100.30 \pm 3.17$  U/L) for dexibuprofen group. On the 21<sup>st</sup> day there is an increase in GPX activity ( $117.59 \pm 2.09$  U/L) compared with ( $110.11 \pm 0.25$  U/L) for the dexibuprofen group.

Effect of combination between Dexibuprofen and Vitamin E on *superoxide* dismutase. In the 1<sup>st</sup> day resulted in a highly significant increase in *superoxide* dismutase activity ( $9.33 \pm 0.674$  U/ml) compared with ( $6.39 \pm 0.472$  U/ml) for dexibuprofen group. In the 7<sup>th</sup> day resulted in an increase in *superoxide* dismutase activity ( $15.00 \pm 0.663$  U/ml) compared with ( $9.92 \pm 0.569$  U/ml) for dexibuprofen group. In the 14<sup>th</sup> day resulted in an increase in *superoxide* dismutase

activity ( $18.26 \pm 0.524$  U/ml) compared with ( $15.84 \pm 0.776$  U/ml) for dexibuprofen group. In the 21<sup>st</sup> day resulted in an increase in *superoxide* dismutase activity ( $21.23 \pm 0.484$  U/ml) compared with ( $19.16 \pm 0.626$  U/ml) for dexibuprofen group.

Effect of combination between Dexibuprofen and Vitamin E on CAT. In the 1<sup>st</sup> day there was an increase catalase activity ( $191.85 \pm 1.64$  U/L) compared with ( $175.55 \pm 5.12$  U/L) for dexibuprofen group. In the 7<sup>th</sup> day a significant increase in catalase activity ( $204.06 \pm 4.08$  U/L) compared with ( $186.23 \pm 4.17$  U/L) for dexibuprofen group. In the 14<sup>th</sup> day resulted in an increase in catalase activity ( $214.07 \pm 3.04$  U/L) compared with ( $197.26 \pm 4.44$  U/L) for dexibuprofen group. In the 21<sup>st</sup> day resulted in an increase in catalase activity ( $227.39 \pm 2.52$  U/L) compared with ( $205.59 \pm 3.10$  U/L) for dexibuprofen group

Table (1): The effect of Vitamin E (100 mg/kg, P.O. once daily), dexibuprofen (7.2 mg/kg, P.O. once daily), and their combination for 21 consecutive days on serum antioxidant markers activities of rats at 1<sup>st</sup>, 7<sup>th</sup>, 14<sup>th</sup> and 21<sup>st</sup> days of drugs withdrawal

Time	Groups	CAT ( $\mu$ /L)	SOD ( $\mu$ /ml)	GPX ( $\mu$ /L)	MDA (nmol/ml)
1 <sup>st</sup> Day	Control	241.39 <sup>a</sup> $\pm$ 3.49	22.54 <sup>a</sup> $\pm$ 1.69	112.93 <sup>a</sup> $\pm$ 1.92	7.04 <sup>c</sup> $\pm$ 0.141
	Vitamin E	247.28 <sup>a</sup> $\pm$ 5.12	23.90 <sup>a</sup> $\pm$ 2.05	111.40 <sup>a</sup> $\pm$ 3.30	6.75 <sup>c</sup> $\pm$ 0.506
	Dexibuprofen	175.55 <sup>c</sup> $\pm$ 2.96	6.39 <sup>b</sup> $\pm$ 0.472	78.45 <sup>c</sup> $\pm$ 5.02	20.56 <sup>a</sup> $\pm$ 0.994
	Dex. + Vit. E:	191.85 <sup>b</sup> $\pm$ 1.64	9.33 <sup>b</sup> $\pm$ 0.674	91.59 <sup>b</sup> $\pm$ 1.37	15.42 <sup>b</sup> $\pm$ 0.958
7 <sup>th</sup> Day	Control	233.77 <sup>a</sup> $\pm$ 2.47	20.91 <sup>a</sup> $\pm$ 1.19	116.04 <sup>a</sup> $\pm$ 3.99	7.11 <sup>c</sup> $\pm$ 0.522
	Vitamin E	235.01 <sup>a</sup> $\pm$ 4.91	22.58 <sup>a</sup> $\pm$ 0.854	113.51 <sup>a</sup> $\pm$ 1.457	7.52 <sup>c</sup> $\pm$ 0.343
	Dexibuprofen	186.23 <sup>c</sup> $\pm$ 4.17	9.92 <sup>c</sup> $\pm$ 0.569	87.80 <sup>c</sup> $\pm$ 3.37	14.01 <sup>a</sup> $\pm$ 0.751
	Dex. + Vit. E:	204.06 <sup>b</sup> $\pm$ 4.08	15.00 <sup>b</sup> $\pm$ 0.663	103.76 <sup>b</sup> $\pm$ 2.97	10.14 <sup>b</sup> $\pm$ 0.123
14 <sup>th</sup> Day	Control	228.78 <sup>b</sup> $\pm$ 8.22	20.04 <sup>a</sup> $\pm$ 0.626	116.04 <sup>a</sup> $\pm$ 3.99	7.05 <sup>b</sup> $\pm$ 0.533
	Vitamin E	224.14 <sup>b</sup> $\pm$ 8.02	21.59 <sup>a</sup> $\pm$ 0.994	111.25 <sup>a</sup> $\pm$ 5.83	7.64 <sup>b</sup> $\pm$ 0.142
	Dexibuprofen	197.26 <sup>a</sup> $\pm$ 4.44	15.84 <sup>b</sup> $\pm$ 0.776	100.30 <sup>b</sup> $\pm$ 3.17	10.49 <sup>a</sup> $\pm$ 0.262
	Dex. + Vit. E:	214.07 <sup>ab</sup> $\pm$ 3.04	18.26 <sup>ab</sup> $\pm$ 0.524	110.07 <sup>a</sup> $\pm$ 0.587	8.36 <sup>b</sup> $\pm$ 0.389
21 <sup>st</sup> Day	Control	229.669 <sup>a</sup> $\pm$ 5.25	21.58 <sup>a</sup> $\pm$ 0.928	118.48 <sup>a</sup> $\pm$ 2.75	7.43 <sup>a</sup> $\pm$ 0.076
	Vitamin E	227.58 <sup>a</sup> $\pm$ 5.06	21.78 <sup>a</sup> $\pm$ 0.401	114.60 <sup>a</sup> $\pm$ 4.82	7.66 <sup>a</sup> $\pm$ 0.163
	Dexibuprofen	205.59 <sup>b</sup> $\pm$ 3.10	19.16 <sup>a</sup> $\pm$ 0.626	110.11 <sup>a</sup> $\pm$ 3.25	8.10 <sup>a</sup> $\pm$ 0.184
	Dex. + Vit. E:	227.39 <sup>a</sup> $\pm$ 2.52	21.23 <sup>a</sup> $\pm$ 0.484	117.59 <sup>a</sup> $\pm$ 2.09	7.47 <sup>a</sup> $\pm$ 0.068

Dex. + Vit. E: Dexibuprofen plus Vitamin E. (n = 5, mean  $\pm$  SE). Means with different superscripts within the same column per one time point were significantly different at P < 0.05.

### 3.2. Histopathological Changes

#### 3.2.1. Dexibuprofen 7<sup>th</sup> day

Liver section revealed moderate congestion of hepatic blood vessels and sinusoids, portal

(mild) biliary proliferation and round cells aggregation, focal disorganization of some hepatocytes with degenerative changes and early necrotic changes. In some sections, the portal triads showed moderate aggregation of round cells and eosinophil's. The same cells were also interstitially aggregated. Portal edema was also seen (Figure 1).

The renal blood vessels were moderately congested with a wide spread perivascular edema. The renal pelvis sections revealed congested blood vessels, edema, degenerative changes in the surrounding tubules and focal sloughing of the epithelium characteristic multifocal myxoid changes in the renal stroma at different location with presence of bluish myxoid secretory materials were seen. The glomeruli were sporadically shrunk or lobulated, sometimes with massive periglomerular round cells aggregates and epithelial crescent formation. Multifocal interstitial round cells aggregation were seen. Most of the renal tubules showed degenerative changes mainly hydropic, sometime with early necrotic changes. Large number of the tubules in both

cortex and medulla were cystically dilated sometime with hyaline casts inside some of them (Figure 2).

### 3.2.2. Dexibuprofen 14<sup>th</sup> day

3.2.2.1. *Liver*: Section showed moderate congestion of hepatic blood vessels, portal (mild) biliary proliferation with fibroplasia and round cells infiltration, focal interstitial aggregation of round cells and focal centrilobular and periportal degenerative changes of the hepatocytes mainly hydropic degeneration and fatty change beside some apoptotic changes in a few hepatocytes

3.2.2.2. *Kidney*: Sections showed characteristic congestion of the renal blood vessels and perivascular edema. Some of the renal tubules were degenerated (cloudy swelling and hydropic) with early necrotic changes. Moderate number of the renal tubules particularly in the medulla were cystically dilated. A few number of the glomeruli were shrunk or lobulated in addition to periglomerular round cells infiltration (Figure 3).

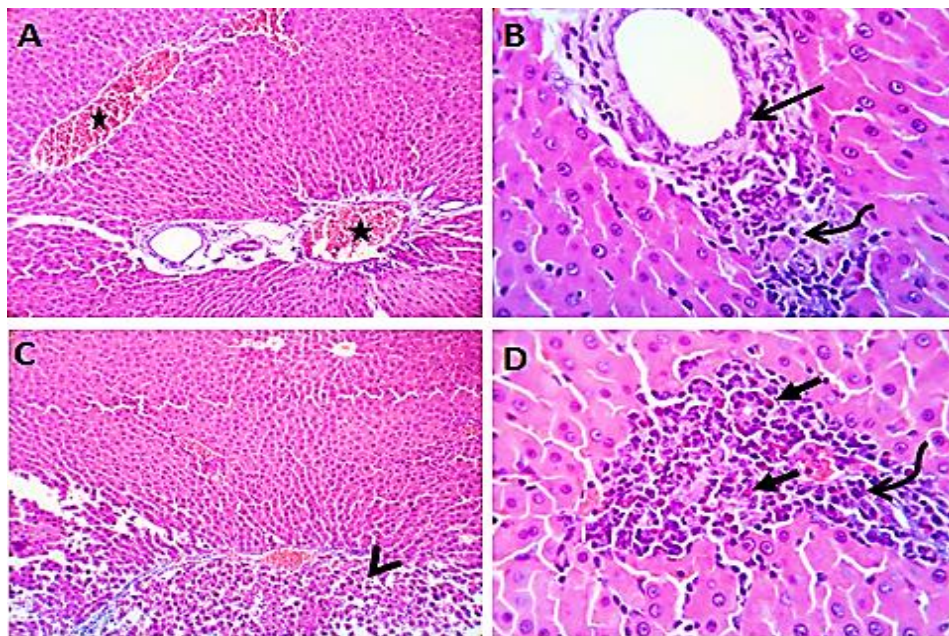


Figure (1): Photomicrograph of Liver showing moderate congestion of hepatic blood vessels (stars), portal mild biliary proliferation (arrow) and round cells aggregation (curved arrow), focal disorganization of some hepatocytes (arrowhead). In some cases, the portal triads showing moderate aggregation of round cells (curved arrow) and eosinophil's (closed arrow). H & E X 100 (A, C), 400 (B, D)

## Vit E protection against side effects of dexibuprofen

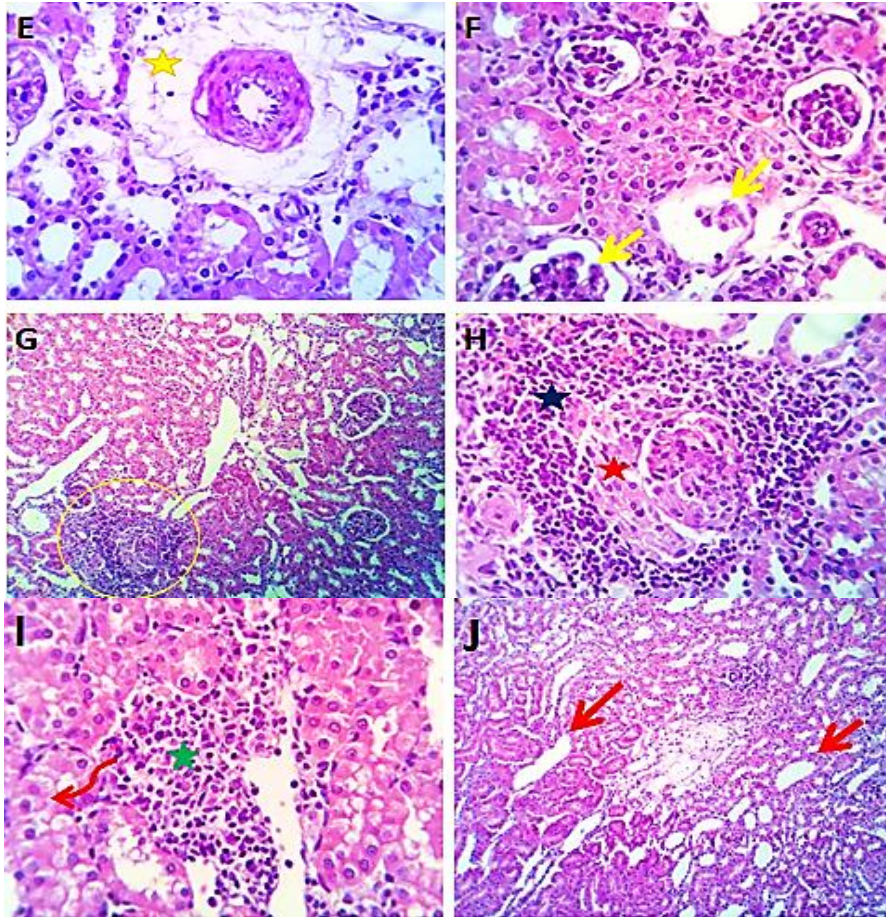


Figure (2): Photomicrograph of kidney showing congestion of renal blood vessels with perivascular edema (yellow star), shrunk or lobulated glomeruli (yellow arrows), with massive periglomerular round cells aggregates (blue star) and epithelial crescent formation (red star). Multifocal interstitial round cells aggregations (green star) beside degenerative changes mainly hydropic (red curved arrow) in some renal tubular epithelium and cystically dilated renal tubules (red arrow) H & E X 100 (G, J), 400 (E, F, H, I)

### 3.2.3. Dexi-ibuprofen + Vitamin E 7<sup>th</sup> day

3.2.3.1. *Liver*: Sections showed normal hepatic parenchyma with residual portal fibrosis and biliary hyperplasia. Minute interstitial leucocytic aggregation and mild focal centrilobular degenerative changes mainly hydropic degeneration and fatty change were seen. The Kupffer cells were prominently enlarged. The hepatic blood vessels and sinusoids were mildly congested (Figure 4).

3.2.3.2. *Kidney*: Sections revealed apparently normal nephron units in most parts of the kidney with preserved renal papillae and renal pelvis, the latter in some cases revealed mildly edematous stroma with healthy normal lining epithelium. Some of the renal

tubules in both cortex and medulla were cystically dilated.

### 3.2.4. Dexibuprofen + Vitamin E 14<sup>th</sup> day

3.2.4.1. *Liver*: Sections from liver showed apparently normal hepatic parenchyma with residual fibrosis in the portal area, mild biliary proliferation and scanty minute interstitial leucocytic aggregations. The fibrotic areas and the previously degenerated or necrotic hepatocytes were ameliorated and appeared partially surrounded by regenerating hepatocytes.

3.2.4.2. *Kidney*: Sections Showed apparently normal nephron units, renal papillae and renal pelvis. Some of the cortical tubules were mildly dilated.

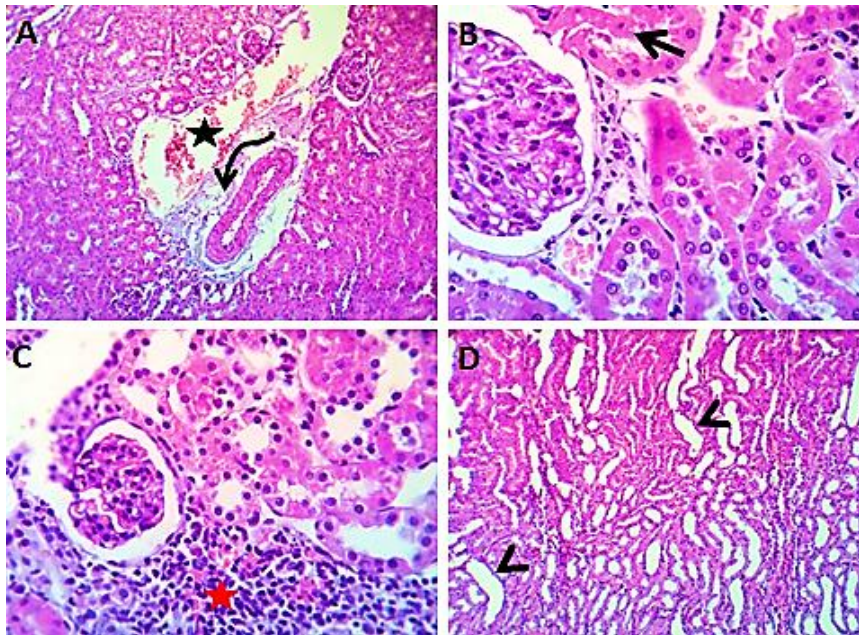


Figure (3): Photomicrograph of kidney showing congestion of the renal blood vessels (star) with perivascular edema (curved arrow) beside degenerative and necrotic changes in some renal tubular epithelium (arrow), cystically dilated medullary renal tubules (arrow heads) in addition to periglomerular round cells infiltration (red star) H & E X 100 (A, D), 400 (B, C)

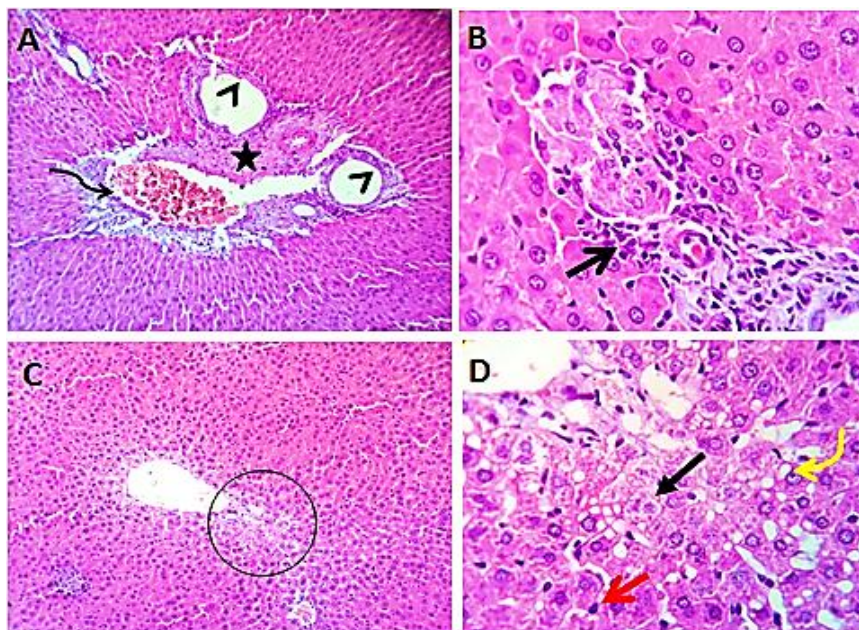


Figure (4): Photomicrograph of Liver showing congestion of hepatic blood vessels (curved arrow), residual portal fibrosis (star) and biliary hyperplasia (arrow heads), minute interstitial leukocytic aggregation (arrow) and mild focal centrilobular degenerative changes (circle) mainly hydropic (closed arrow) and fatty change (curved yellow arrow) with hypertrophied Kupffer cells (red arrow) H & E X 100 (A, C), 400 (B, D)

#### 4. DISCUSSION

Imbalance between oxidants and antioxidants in favor of the oxidants, potentially leading to

## Vit E protection against side effects of dexibuprofen

damage, is termed (oxidative stress) (Sies, 1997). The oxidative stress is thought to contribute to the initiation and progression of atherosclerosis. Free radicals catalyze lipid peroxidation so can cause damage to cellular and intracellular structures, so administration of anti-oxidants prevent oxidation of fatty acid in the cell (Droke and Loerch, 1989). Vitamin E act as a peroxy radical scavenger, disabling the production of damaging free radicals in tissues, by reacting with them to form a tocopherol radical, which will then be reduced by a hydrogen donor (such as vitamin C) and thus return to its reduced state (Traber *et al.*, 2011) Vitamin E is thought to have a role in preventing atherosclerosis by inhibiting the oxidation of low-density lipoprotein (Fuller *et al.*, 1998).

Vitamin E is a potent naturally occurring lipid soluble antioxidant possesses the ability to directly quench free radicals and function as a membrane stabilizer. It protects critical cellular structures against the damage from oxygen free radicals and reactive products of lipid peroxidation (Goldfarb *et al.*, 1996). Superoxide dismutase as an enzyme that alternately catalyzes the dismutation of the superoxide radical into either ordinary molecular oxygen or hydrogen peroxide was defined by (Hayyan *et al.*, 2016). Catalase is a common enzyme found in nearly all living organisms exposed to oxygen (such as bacteria, plants, and animals). It catalyzes the decomposition of hydrogen peroxide to water and oxygen (Chelikani *et al.*, 2004). Vitamin E can protect against acute Liver necrosis induced by carbon tetrachloride (Maurizio *et al.*, 1992). Vitamin E is known to act by breaking the antioxidant chain that prevent ROS-produced cell membrane damage (Factor *et al.*, 2000).

In the present study it was observed that vitamin E administration to rats produced an appreciable improvement in the histopathological changes that occur in kidney and liver which associated with administration of Dexibuprofen, also Vitamin E normalized levels of MDA, catalase, glutathione peroxidase and superoxide dismutase The possible pathway can be explained through structure of vitamin

E. The group of eight compounds that include four tocopherols and four tocotrienols. All eight feature a chromane double ring, with a hydroxyl group that can donate a hydrogen atom to reduce free radicals, and a hydrophobic side chain which allow penetration into biological membranes. The antioxidant activity of vitamin E during the peroxidation of unsaturated lipids has been reviewed based on its reaction products.

Vitamin E used in a dose (100 mg/kg, P.O. once daily) for 21 days to clarify the hepatic nephroprotective effects on rats. We found a significant changes in antioxidants markers (SOD, CAT, GPX and MDA levels).

Histopathological results in liver at 7<sup>th</sup> day for dexibuprofen showed moderate congestion of hepatic blood vessels and sinusoids, mild biliary proliferation and round cells aggregation. On the 14<sup>th</sup> day showed moderate congestion of hepatic blood vessels, mild biliary proliferation with fibroplasias and round cells infiltration. On 7<sup>th</sup> day for Dexibuprofen + Vitamin E showed normal hepatic parenchyma with residual portal fibrosis and biliary hyperplasia Kidney for Dexibuprofen only on 7<sup>th</sup> day showed the renal pelvis revealed congested blood vessels, edema, degenerative changes in the surrounding tubules and focal sloughing of the epithelium. On 14<sup>th</sup> day showed characteristic congestion of the renal blood vessels and perivascular edema. In the 7<sup>th</sup> day for Dexibuprofen + Vitamin E the kidney sections showed revealed apparently normal nephron units in most parts of kidney with preserved renal papillae and renal pelvis. On the 14<sup>th</sup> day kidney sections showed apparently normal nephron units, renal papillae and renal pelvis.

Vitamin E is well accepted as nature's most effective lipid-soluble, chain-breaking antioxidant, protecting cell membrane from peroxidative damage (Kaehler *et al.*, 2003). Antioxidant Vitamin E retard hepatic fibrosis in biliary obstructed rats (Parola *et al.*, 1992). Vitamin E is known to act by breaking the antioxidant chain that prevent ROS-produced cell membrane. It decreases lipid peroxidation and protects against liver injury. It decrease liver fibrosis, tumor necrosis



factors, inflammation and hepatic porphyrin (Bradford et al., 2003). The increased level of antioxidant enzymes CAT, GPX, and *superoxide* dismutase resulted from administration of vitamin E might normalized the lipid peroxidation reaction and related biochemical changes which in turn protects the cells from the increase risk of peroxidative damage as result of administration of cytotoxic drugs was reported by (Beytut et al., 2003).

Dexibuprofen can produce several adverse effects as oxidative damage, it produce a significant lipid peroxidation (Khan et al., 2014).

Oxygen free radicals probably derived via action of xanthine oxidase, the decrease in super oxide dismutase activity and depletion of mucosal glutathione contribute to the pathogenesis of dexibuprofen induced ulceration (Burak Cimen et al., 2003).

Oxygen free radicals probably derived via the action of xanthine oxidase during use of non-steroidal anti-inflammatory drug that lead to decrease in superoxide dismutase activity and depletion of mucosal glutathione (Ivillegas et al., 2000).

## 5. CONCLUSIONS

It could be concluded that Dexibuprofen has hepatic and renal disturbance in rats; Vit. E has a protective effect against renal and hepatic disturbance, which may attribute to decrease the harmful effects of Dexibuprofen by inhibiting free radical formation and by restoration of the antioxidant systems. The combination of vitamin E and Dexibuprofen showed better results than Dexibuprofen alone.

## 6. REFERENCES

- Aebi H. (1984): Colourimetric determination of Catalase activity. *Methods Enzymol*, 105: 121 – 126.
- Ashraf Z, A, Rasool R, H M, Ahsan H, Afzal S, Afzal K, C H ,and Kim SJ. (2016): Synthesis, Bio evaluation and Molecular Dynamic Simulation Studies of Dexibuprofen-Antioxidant Mutual Prodrugs. *Int. J. Mol. Sci.*; 21; 17 (12).
- Beytut E, Erisir M, Ahsakal M. (2003): Effects of additional, Vitamin E and selenium supply on antioxidative defense mechanisms in the kidney of rats treated with high dose of glucocorticoid. *Cell Biochem. Fun.*; 22: 59 – 65.
- Bradford A, Atkinson J, Fuller N, and Rand RP. (2003): The effect of vitamin E on the structure membrane lipid assemblies. *J. Lipid Res.*; 44: 1940 – 1945.
- Burak Cimen MY, Ozlem B, G, Eskandari, Gunsahsahin, Canan, Erdogan, Ugar Atik. (2003): Drug and Chemical Toxicology; 26 (3): 169 - 176.
- Chandrasekaran, K. (2010): S + ibuprofen (dexibuprofen): the superior non-steroidal anti-inflammatory agents for development of pharmaceuticals *International Journal of Current Pharmaceutical Research* 2 (3).
- Chelikani P, Fita I and , Loewen PC. (2004): Diversity of structures and properties among catalases. *Cellular and Molecular Life Sciences*; 61 (2): 192 – 208.
- De La Cruz JP, Reyes JJ, Ruiz-Moreno MI, Lopez-Villodres JA, Jebrouni N, Gonzalez-Correa J. (2010): Differences in the In Vitro Antiplatelet Effect of Dexibuprofen, Ibuprofen, and Flurbiprofen in Human Blood. *Cardiovascular Anesthesiology: Research Reports*; 111 (6): 1341 – 1346.
- Droke E, Loerch S. (1989): Effect of parental selenium and vitamin E on performance health and humoral response of stress new to feed lot environment. *J. Anim. Sci.*; 6150 -159.
- Factor V, Laskowska D, Jensen M, Woitach J, Popescu N, Thorgeirsson S, (2000): Vitamin E reduces chromosomal damage and inhibit hepatic tumor formation in a transgenic mouse

## Vit E protection against side effects of dexibuprofen

- model. *Med Sci.* 2000; 97: 2196 – 2201.
- Fuller CJ, Huet BA, Jilal I. (1998): Effects of increasing doses of alpha –tocopherol in providing protection of low- density lipoprotein from oxidation *Am J. Cardiol.*; 81 (2): 231 – 3.
- Goldfarb AH, McIntosh MK, Boyer BT. (1996): Vitamin E attenuates myocardial oxidative stress induced by DHEA in rested and exercised rats. *J. Appl. Physiol.*; 80: 486 – 490.
- Gonzalez C, Jose A, Arrebola Maria, Monsalud MD, Martin-Salido E, Munoz-Marin, Javier MD, Cuesta FS, De La Cruz JP. (2007): Effects of Dexibuprofen on Platelet Function in Humans: Comparison with Low-dose Aspirin. *Anesthesiology*; 106 (2): 218 – 225.
- Hardikar MS (2008): Chiral non-steroidal anti-inflammatory drugs--a review. *J Indian Med Assoc.* 106 (9): 615–8, 622, 624.
- Hayyan M, Hashim MA, Al Nashef IM. (2016): Superoxide Ion: Generation and Chemical Implications. *Chem. Rev.*; 116 (5): 3029 – 3085.
- Ivillegas M, Martin C, Lacasa V, Motilva C, Alorcon de la Lastra. (2000): Effects of meloxicam on oxygen radical generation in rat gastric mucosa inflammation. *Research*; 49 (7): 361 - 366.
- Kaehler ST, Phleps W, Hesse E. (2003): Dexibuprofen: pharmacology, therapeutic uses and safety. *Inflammopharmacology*; 11 (4-5-6): 371 - 383
- Khan, AblMehry, Rampal, Satyavan. (2014): *Journal of American Association for laboratory Animal Science*, 53: 399 - 405.
- Maurizio P, Gabriella L, Fiorella B, Emanuele A, Maria E, Giuseppe P, Mario P. (1992): Vitamin E dietary supplementation protects against carbon tetrachloride –induced chronic liver damage and cirrhosis. *Hepatology.*; (16): 4 – 6.
- Mcginness JE, Proctor PH, Demopoulos HB, Hokanson JA, Kirkpatrick DS, (1978): Amelioration of cis-platinum nephrotoxicity by orgotein (superoxide dismutase)". *Physiological Chemistry and Physics.*; 10 (3): 267 – 77.
- Nishikimi M, Roa NA, Yogik. (1972): Measurement of superoxide dismutase. *Bioch. Btoph. Res. Commun.*; 46: 849 – 85.
- Paget GE, Barnes JM. (1964): Evaluation of drug activities: pharmacometric, Laurence and Bacharach, Voll1, Academic press, New York. Pp 133 - 166.
- Paglia DE, Valentine WN. (1967): Studies on quantitative and qualitative characterization of erythrocyte glutathione peroxidase. *J. Lab. Clin. Med.*; 70 (1): 158 – 169.
- Parola M, Leonarduzzi G, Biasi F, Albano E, Biocca ME, Poli GA, Dianzani MU. (1992): Vitamin E dietary supplementation protects against carbon tetrachloride-induced chronic liver damage and cirrhosis. *Hepatology*; 16: 1014 – 1021.
- Seguí J, Gironella M, Sans M, Granell S, Gil F, Gimeno M, Coronel P, Piqué Jm, Panés J. (2004): Superoxide dismutase ameliorates TNBS-induced colitis by reducing oxidative stress, adhesion molecule expression, and leukocyte recruitment into the inflamed intestine. *J Leukoc Biol.*;76(3):537-44.
- Sies H. (1997): Oxidative stress: oxidants and antioxidants. *experimental physiology.* J.; 82 (2): 291 – 295.
- Suvarna Kim S, Christopher Layton and Bancroft John D. (2013): *Bancroft "s Theory and Practice of Histopathological Techniques*, 7<sup>th</sup> Ed.
- Traber MG, Stevens JF, Stevens. (2011): Free Radical Biology and Medicine – Vitamins C and E: Beneficial effects from a mechanistic perspective. *Free Radical Biology and Medicine*; 51 (5): 1000 – 13.
- Van Durme CM, Wechalekar MD, Buchbinder R, Schlesinger N, Van Der Heijde D, Landewé RB.

(2014): Non-steroidal anti-inflammatory drugs for acute gout. Cochrane Database Syst Rev.; 16 (9): CD010120.

Yoon JS, Oh JW, Lee KY, Lee HS, Koh YY, Kim JT, Kang JH, Lee J.S. (2008): The effects and safety of dexibuprofen

compared with ibuprofen in febrile children caused by upper respiratory tract infection. British Journal of Clinical Pharmacology; 66 (6): 854 – 860.