

Results of Percutaneous Fixation of Acute Scaphoid Fractures by Herbert Screw

Mohamed Ahmed Saleh Gad*, El-Sayed Abd Elmoaty AL-sherbiny,
Hossam Fathi Mahmoud, Mohamed Ismail Abd El-Rahman Kotb

Department of Orthopedic Surgery, Faculty of Medicine, Zagazig University, Zagazig, Egypt

*Corresponding author: Mohamed Ahmed Saleh Gad, Mobile: (+20) 01026455885, E-Mail: mohsaleh20@yahoo.com

ABSTRACT

Background: The Scaphoid bone is the most commonly fractured carpal bone. Proper clinical examination and radiological imaging is essential for early diagnosis and management. The management of scaphoid fractures varies from cast immobilization to open reduction and internal fixation. This paper explores the outcome of using headless cannulated screws in minimally displaced scaphoid fractures.

Objective: Aim of this study is to assess the functional and clinical outcome of using cannulated headless screws in management of acute scaphoid fractures. **Methods:** A prospective study held between February 2019 and January 2020, where eighteen patients included with acute scaphoid fractures of Herbert B1, B2 and B3 classification. Fixation was done using both volar and dorsal percutaneous technique. Patients were evaluated postoperatively clinically using modified Mayo wrist score (MMWS). **Results:** Of mean age 34.5 ± 8.37 years, the majority were with excellent final outcome (83.3%), good (5.6%), fair one case (5.6%) and only one poor (5.6%) and mean time of union was 9.66 ± 1.9 months. **Conclusion:** All active young individuals with acute non-displaced or minimally displaced scaphoid fractures should be offered percutaneous internal fixation, for the sake of earlier gain of motion of the wrist, earlier time to union, quicker return to activity of daily living, and a lower complication rate.

Keywords; Scaphoid, Acute fractures, Percutaneous fixation.

INTRODUCTION

The scaphoid is a boat shaped bone, crosses both proximal and distal carpal rows⁽¹⁾. The main blood supply to the scaphoid enters through the dorsal ridge at the waist via a dorsal branch of the radial artery that accounts for 80% of its blood supply, also a volar branch enters through the volar tubercle that accounts for 20–30% of the scaphoid's blood supply, mainly to the distal portion. The proximal pole of the scaphoid relies entirely on intramedullary blood flow in a retrograde manner renders it susceptible to avascular necrosis after a fracture through waist⁽²⁾.

The scaphoid bone is the most commonly fractured carpal bone, accounting for over 60% of carpal fractures. Treatment of scaphoid fractures continue to be a great challenge due to the different types and methods of fixation⁽³⁾.

Although there are several treatment modalities for scaphoid fractures like cast immobilization and surgical either open or percutaneous fixation, displaced fractures and proximal pole fractures are clear indications for surgical intervention⁽⁴⁾. However, controversy exists in the treatment of undisplaced or minimally displaced scaphoid waist fractures due to good union rate reported using either nonsurgical management or percutaneous screw fixation⁽⁵⁾.

Conservative management is not free of complication as the majority of the cases are young men and immobilization in this group has a significant economic burden due to the time off work⁽⁴⁾.

Hence there is a recent orthopedic trend toward percutaneous fixation of an acute nondisplaced scaphoid that have traditionally been treated conservatively to shorten the postoperative immobilization period resulting in early functional recovery and early return to work⁽⁵⁾.

Aim of this study is to assess the functional and clinical outcome of using cannulated headless screws in management of acute scaphoid fractures.

PATIENTS AND METHODS

Research design:

A prospective clinical trial conducted during the period of February 2019 to January 2020.

Sample size:

18 patients with recent scaphoid fractures were admitted and operated upon in the Casualty Unit of the Orthopedic Department of Zagazig University Hospitals. According to the Herbert classification of scaphoid fractures, 11 patients had complete waist fractures, 5 patients had distal pole fractures, while 2 patients had proximal pole fractures. The follow up period of the cases ranged from 6 -12 months.

Study population:

Inclusion criteria:

- 1) Patients of skeletal maturity.
- 2) Patients with acute scaphoid fractures less than 3 weeks duration.
- 3) Surgically fit patients

Exclusion criteria:

- 1) Scaphoid fractures more than 3 weeks.
- 2) Proximal fifth fractures not amenable for screw fixation.



This article is an open access article distributed under the terms and conditions of the Creative Commons Attribution (CC BY-SA) license (<http://creativecommons.org/licenses/by/4.0/>)

- 3) Severely displaced scaphoid fractures.
- 4) Patient with symptoms and/or signs of infection.
- 5) Patients with insufficient follow-up data or lost.

Ethical approval:

Study was approved by the Local Patient Protection Committee of Zagazig University and the study was registered. All patients were included after signed consent.

Methods:

The clinical data of the patients fulfilling the inclusion criteria were evaluated as follows:

A) Clinical data:

Careful history taking was done for all patients with special care was given to the mechanism of injury, time of trauma, hand dominance, occupation, and any previous surgery involving the scaphoid bone. Examination was done to detect, any associated injuries, abrasions and any deformity of the wrist.

B) Radiographic evaluation:

The patients had the following radiological examinations:

1)-Plain X-ray:

Include four views of the wrist,

- Posteroanterior view.
- Lateral view.
- Semipronated oblique view.
- Scaphoid view with the wrist pronation and ulnar deviation

2)-Computed tomography (CT scan).

C) Laboratory investigations:

The patients had the following preoperative routine lab investigations: complete blood count, random blood glucose level, bleeding profile, liver and kidney function tests.

D) Surgical technique:

a- Volar percutaneous technique:

- 1) 15 patients in the study were managed using general anesthesia, while 3 patients using regional supraclavicular block anesthesia, prophylactic broad spectrum antibiotic was taken before induction of anesthesia and tourniquet insufflation by about one hour.
- 2) The patient was placed in the supine position with the affected hand placed on radiolucent table for clear visualization by the image intensifier, fluoroscopic AP and lateral views were performed before draping to confirm adequate visualization and accurately identify the anatomic landmarks and fracture fragments.
- 3) The entire upper limb was prepped and draped.
- 4) Longitudinal traction of the thumb is usually sufficient to reduce the fracture, however if it is not adequately reduced, 1.5 mm KW was used as joystick to aid the reduction.
- 5) Once the reduction was confirmed by fluoroscopy, 1.1 mm guidewire was inserted through the scaphoid tubercle toward the center of the proximal pole.

- 6) The length of the screw was determined by a depth gauge, and was 4–5 mm shorter to achieve the correct measurement.
- 7) Longitudinal 0.5 cm incision was made around the guidewire.
- 8) 2.7 mm cannulated drill was passed till 2 mm from the articular surface of the proximal pole. The 3.5 mm countersink cannulated drill was used for reaming the distal pole only.
- 9) A headless cannulated compression screw was passed through the guidewire till adequate position under image guidance.
- 10) The incised wound was closed.

b- Dorsal percutaneous technique:

- 1) The patient was placed supine with the affected upper limb abducted 90° and the operated-on hand on a radiolucent arm board. The wrist was pronated and flexed at 45 degrees or more then the proximal pole was identified by the depression between scaphoid and lunate.
- 2) 1.1 mm guidewire was inserted through the proximal pole from dorsal to volar in an antegrade fashion. To avoid backing out of the guidewire after reaming, the wire might be advanced to exit at the base of the thumb.
- 3) 5 mm incision was made around the guide wire, then depth gauge or a second guide of the same length was used to determine the screw length which was usually 4 mm smaller than the measured length.
- 4) 2.7 mm cannulated drill was passed till 2 mm from the articular surface of the distal pole, then 3.5 mm cannulated drill was used for reaming the proximal pole only.
- 5) A headless cannulated compression screw was passed through the guidewire till adequate position under image guidance
- 6) The incised wound was closed.

Follow up and rehabilitation program:

A rigid orthosis was applied immediately postoperatively for 3 weeks or below elbow cast for patients associated with ipsilateral distal radius fractures. Active wrist motion was begun and was accompanied by hand grip exercises with load restriction. Hand physiotherapy at 2 to 3 times per week started 2 weeks postoperatively with gentle range of motion activities followed by progressive strengthening thereafter. Progression to full weight-bearing exercise was permitted once patient's x-rays demonstrated radiographic evidence of osseous union as well as symptomatic improvement. All patients were followed up for at least 6 months. Functional evaluation of the patients was done using modified Mayo wrist score ⁽⁶⁾

Statistical analysis

Recorded data were analyzed using the statistical package for social sciences, version 22.0 (SPSS Inc., Chicago, Illinois, USA). Quantitative data were expressed as

mean± standard deviation (SD). Qualitative data were expressed as frequency and percentage. Independent-samples t-test of significance was used when comparing between two means. Chi-square (x²) test of significance was used in order to compare proportions between two qualitative parameters. The confidence interval was set to 95% and the margin of error accepted was set to 5%. The p-value was considered significant as the following: P-value <0.05 was considered significant. P-value <0.001 was considered as highly significant. P-value >0.05 was considered insignificant.

RESULTS

The mean age of participants was 34.5±8.37 years, male prevalence was observed in 66.7% and female 33.3% with dominant right side prevalence of 88.9 %. All cases were of recent fractures with less than 3 weeks duration. The mechanism of trauma was a fall on the wrist in 12 cases (66.7%), direct blow in one case (5.6

%), and a traffic accident in 5 cases (27.8 %) of the total fractures, 11 cases were of the scaphoid waist (61.1 %) and 2 were of the proximal pole (11.1%), and 5 cases were of distal pole (27.8%). Consolidation was observed in 17 cases, with a mean time of 9.66±1.9 weeks postoperatively. These cases presented full range of motion, and had no complaints of loss of strength or residual pain. Regarding functional evaluation of the patients using modified Mayo wrist score, the majority were with excellent final outcome (15 cases 83.3%), good (1 case 5.6%), fair one case (1case 5.6%) and only one poor (5.6%).

As regard complications, two patients presented with prominent screw (11.2%), one case of non-union (5.6%), and a reported intraoperative complication of broken guidewire, that was managed by expanding the incision about one cm to facilitate the removal of the fragment.

Table (1): Modified Mayo wrist score distribution and final outcome and relation with outcome

			Favorable	Unfavorable	t/ X ²	P
Age			34.00±8.45	38.5±9.19	-0.75	> 0.05
Time to union			9.56±1.92	10.5±2.12	-0.64	> 0.05
Final score			92.81±4.81	62.5±3.53	8.54	0.01**
Sex	F	N	6	0		
		%	37.5%	0.0%		
	M	N	10	2	1.12	> 0.05
		%	62.5%	100.0%		
Side	Lt	N	4	0		
		%	25.0%	0.0%		
	Rt	N	12	2	0.64	> 0.05
		%	75.0%	100.0%		
Dominant side	-	N	2	0		
		%	12.5%	0.0%		
	+	N	14	2	0.28	> 0.05
		%	87.5%	100.0%		
Herbert type	B1	N	5	0		
		%	31.2%	0.0%		
	B2	N	9	2	1.43	> 0.05
		%	56.2%	100.0%		
	B3	N	2	0		
		%	12.5%	0.0%		
Associated injury	Associated	N	6	1		
		%	37.5%	50.0%		
	isolated	N	10	1	0.11	> 0.05
		%	62.5%	50.0%		
Mechanism injury	Direct blow	N	1	0		
		%	6.2%	0.0%		
	Fall on outstretched hand	N	10	2	1.12	> 0.05
		%	62.5%	100.0%		
	RTA	N	5	0		
		%	31.2%	0.0%		
Interval before surgery	1st	N	2	0		
		%	12.5%	0.0%		
	2nd	N	14	2	0.28	> 0.05
		%	87.5%	100.0%		
Total	N	16	2			
	%	100.0%	100.0%			

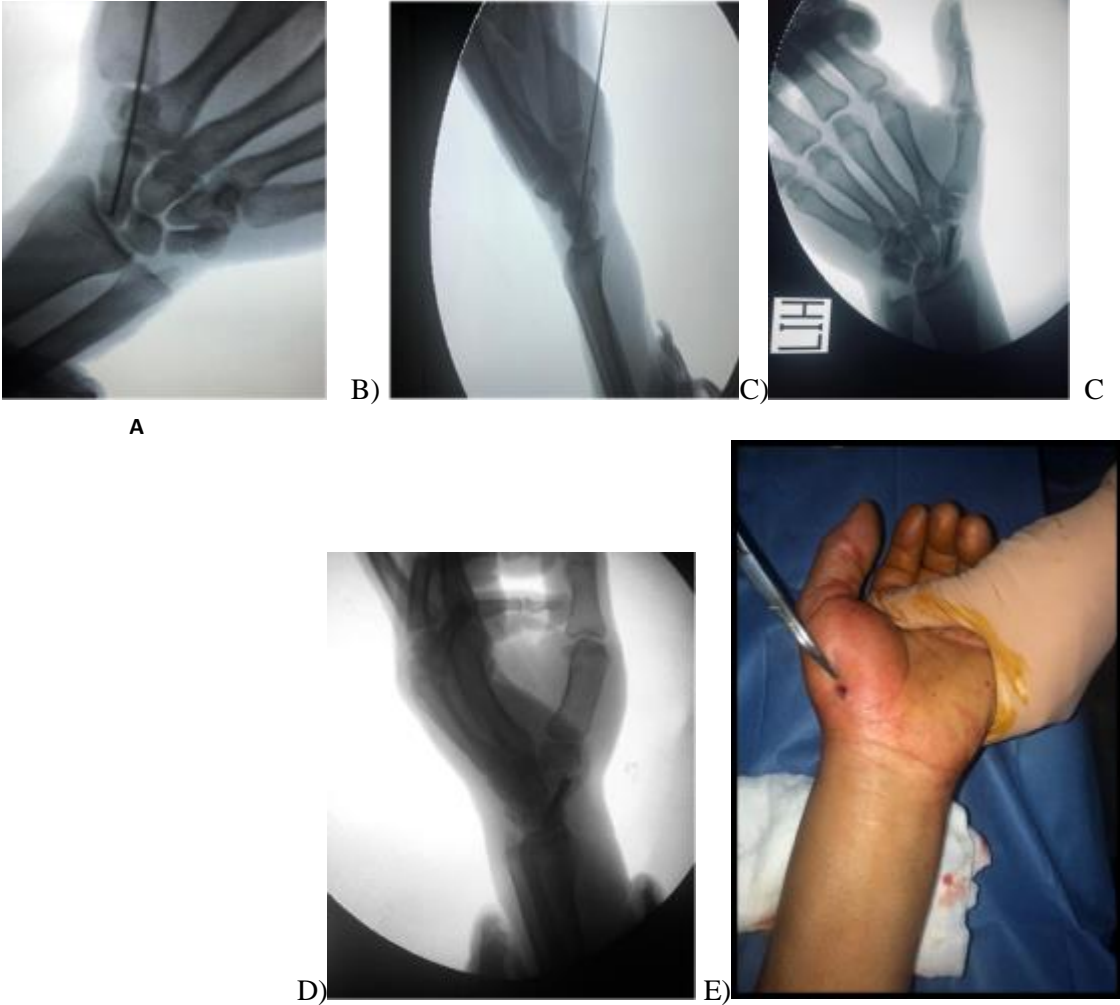
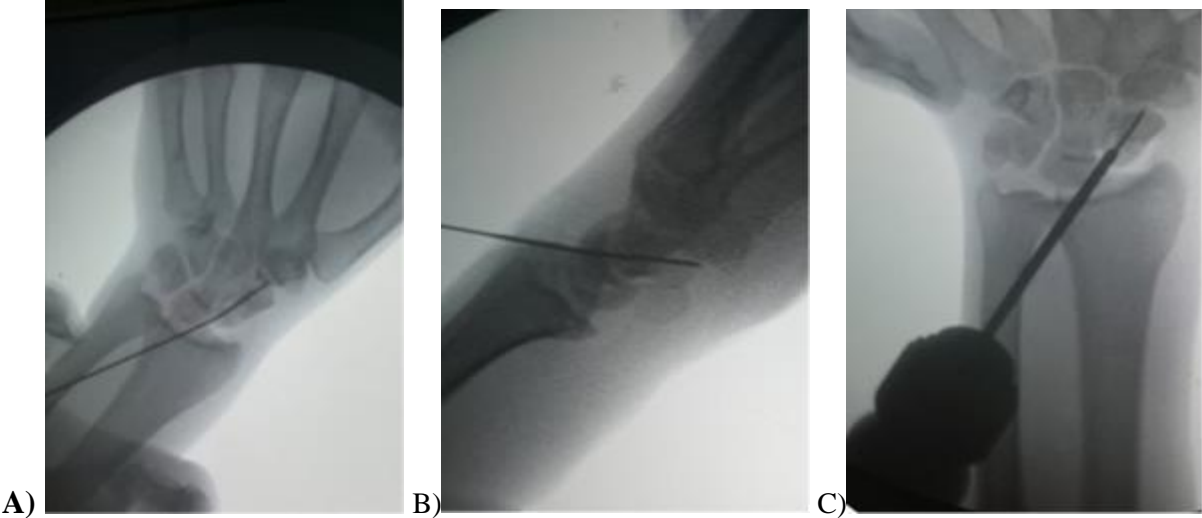


Figure (1): Showing (A-B) guidewire position, (C-D) final screw position. (E) surgical wound



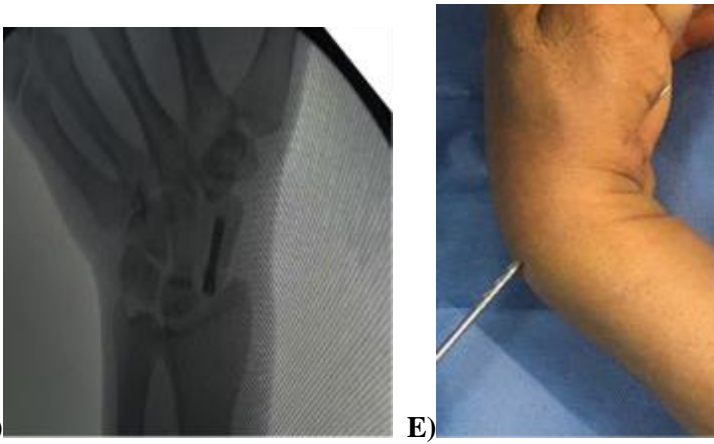


Figure (2): Showing (A-B) guidewire position, C) reaming proximal pole, D) screw position, E) clinical photo of reaming prox pole.

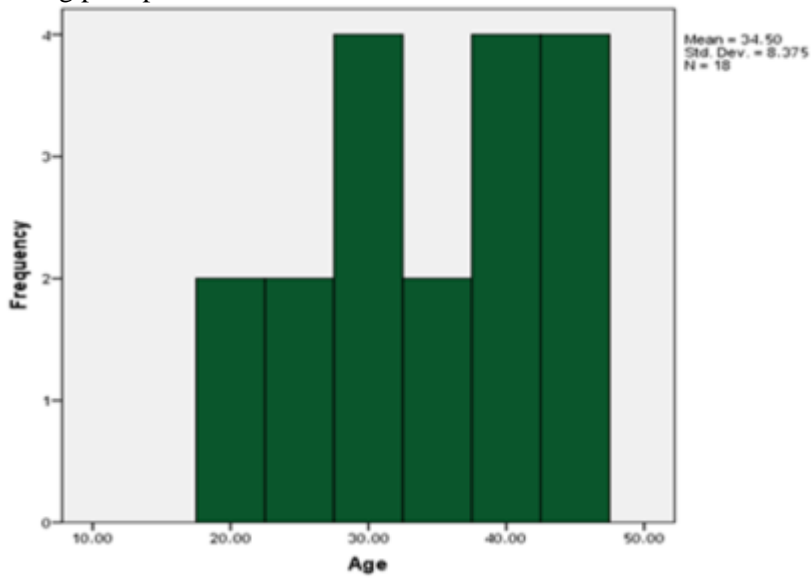


Figure (3): Showing Age distribution among studied group

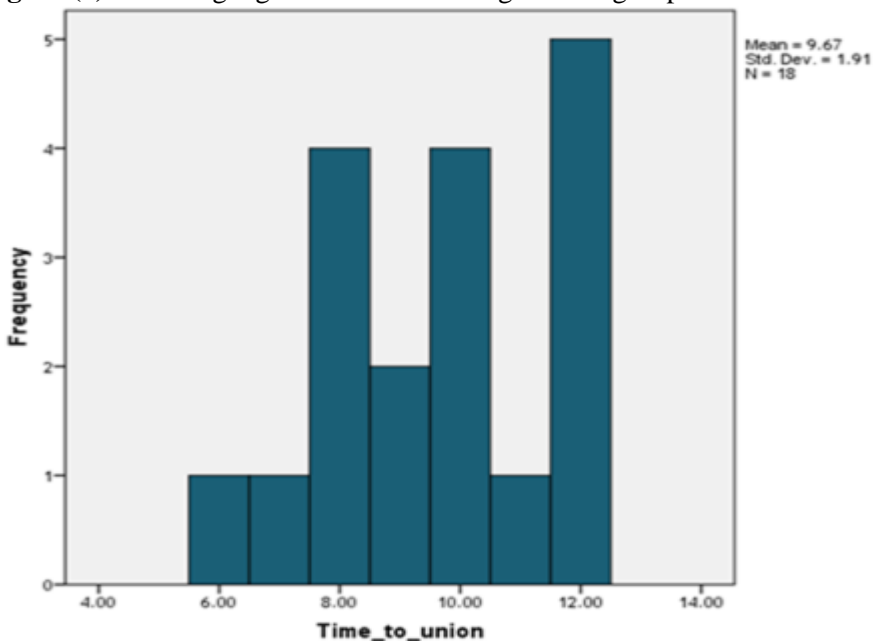


Figure (4): Showing time of union distribution.

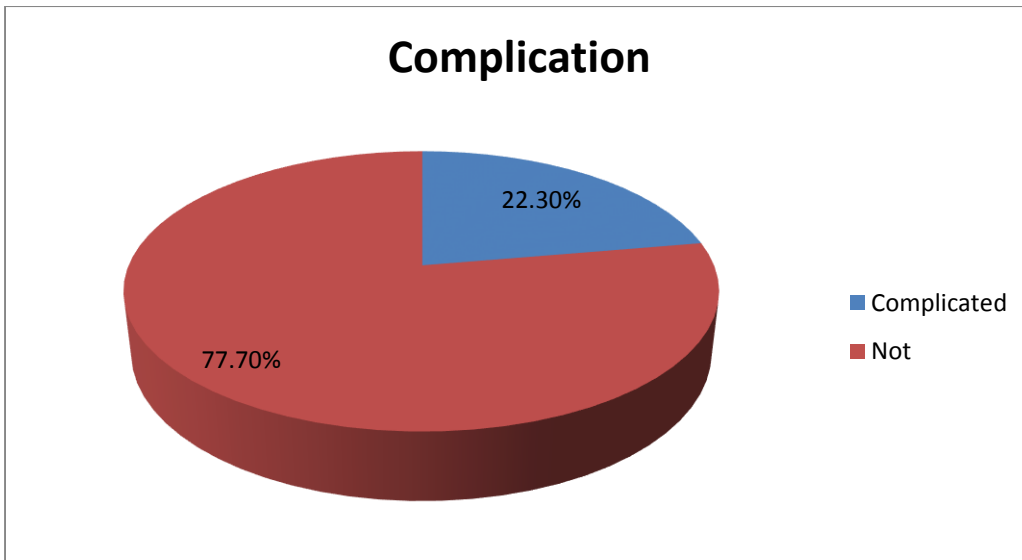


Figure (5): Showing complication distribution among studied groups.

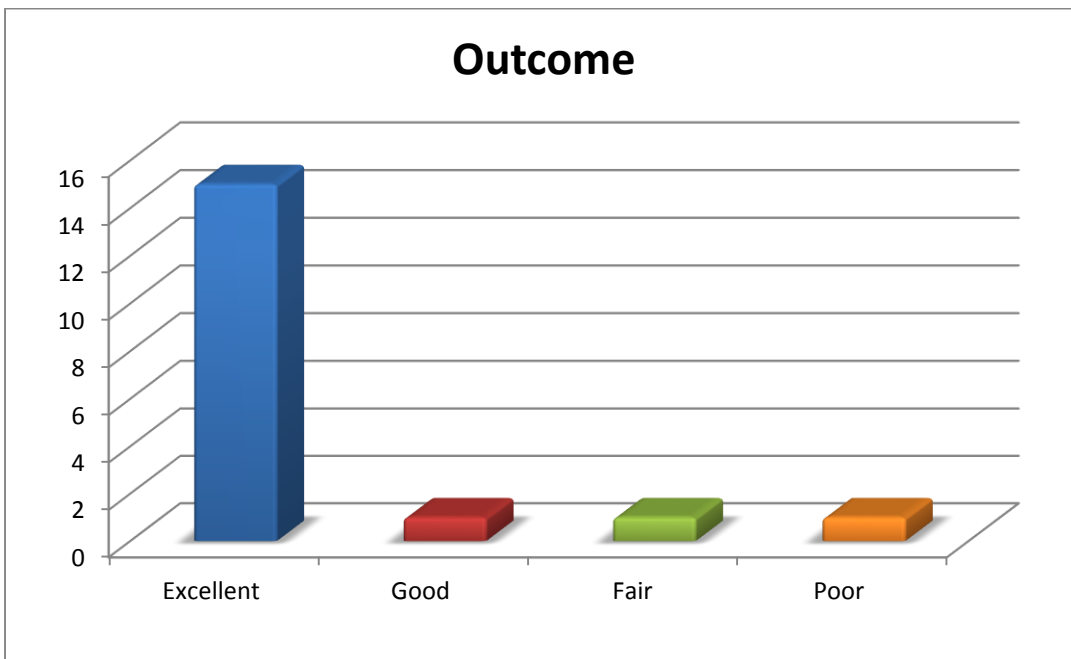


Figure (6): Showing the final outcome.

DISCUSSION

In this study, 18 patients with recent scaphoid fractures were treated at Zagazig University Hospital by percutaneous headless cannulated screw.

Regarding epidemiology, the mean age of participants was 34.5 ± 8.37 . the majority of cases were male (67%) with right side prevalence (78%) and fall on outstretched hand was the major cause (67%). These results are similar to that reported by **Severo *et al.***⁽⁷⁾, who performed percutaneous treatment for 28 patients in which the mean age was 30.5 years, male prevalence was 89.2% with no prevalence of the dominant side and fall on the wrist was the main cause (78.5%).

Severo *et al.*⁽⁷⁾, included only patients with isolated scaphoid fractures with longer time of

presentation 4.16 weeks (range 1–8 weeks). On the contrary, in our study the time of presentation was less than 3 ws range from (0.2-3 weeks) and presence of an associated injuries was not considered an exclusion factor.

In our current study, we used both volar and dorsal approach. 16 cases were managed using the volar one and 2 cases with the dorsal one. **Polsky *et al.***⁽⁸⁾ reported that, there is no statistically significant difference in clinical outcomes and union times between patients treated with the dorsal versus the volar approach.

In the current study consolidation was observed in 17 cases (94.4%). This (94.4%) consolidation rate observed in the present study is in agreement with the results reported by **Folberg *et al.***⁽⁹⁾ and **Brutus *et al.***

⁽¹⁰⁾, who observed a consolidation rate of 93.7% and 90% respectively.

While some authors reported 100% consolidation with the use of percutaneous fixation like **Jeon et al.** ⁽¹¹⁾, our study has a comparable union rate (94.9%). Moreover it is better than many reported series like **Wozasek and Moser** ⁽¹²⁾ who reported union rate of 89%.

Regarding postoperative complications only 2 patients presented with prominent screw and one case with nonunion, and there was one intraoperative complication representing an overall rate of 22.3%. This 22.3% complication rate is similar to those observed in recent literature like **Adolfsson et al.** ⁽¹³⁾ and **Schädel-Höpfner et al.** ⁽¹⁴⁾, who observed a complication rate of 22% and 21% respectively. Moreover it is better than many reported series like **Dias et al.** ⁽¹⁵⁾ and **Bushnell et al.** ⁽¹⁶⁾, who noticed a complication rate of 30% and 29% respectively.

Bushnell et al. ⁽¹⁶⁾, reported a higher incidence of complication as they involved patient with late presentation till 10 weeks and patients with other associated injuries like distal radius fractures that might worsen the outcome

There was no radiological signs of avascular necrosis of the proximal pole, infection, tendon rupture or nerve injury noted in any of our cases during the period of follow-up.

Regarding rehabilitation, an excellent degree of patient satisfaction and quality was obtained in the current study. The average postoperative modified Mayo score was 90.2±9.0 (range 60-100). Majority were with excellent final outcome (15 cases 83.3%), good (1 case 5.6%), fair (1 case 5.6%) and only one poor (5.6%)

These results are in line with the studies by **Severo et al.** ⁽⁷⁾ who reported 92.80% excellent outcome, good (0%), fair (0%), and (7.20%) Poor result.

Our study has a few limitations worth noting, the major one is the small number of patients that limited the power of the study for more in-depth statistical analysis. Also, the functional assessment of grip strength and range of motion outcomes was done by the operating physician himself making it vulnerable to observer bias because of the unblinded nature of the study design.

CONCLUSION

Percutaneous fixation of acute non-displaced or minimally displaced scaphoid fractures specially in young active individuals in whom prolonged immobilization can be a significant burden, provides excellent results regarding functional outcome, earlier

gain of motion of the wrist, earlier time to union, quicker return to activity of daily living, and a lower complication rate.

Conflict of interest: None of the authors declare that they have any conflict of interest related to this work.

Funding: No funding was received for this study.

REFERENCES

1. **Short W, Werner F, Green J et al. (2007):** Biomechanical evaluation of the ligamentous stabilizers of the scaphoid and lunate: part III. *The Journal of hand surgery*, 32(3): 297-e1.
2. **Gaebler C, McQueen M (2010):** Carpus fractures and dislocations. Bucholz RW, Court-Brown CM, Heckman JD, Tornetta P, eds. *Rockwood and Green's fractures in adults*. Seventh ed. Philadelphia: Lippincott Williams & Wilkins, Pp. 781-828.
3. **Bond C, Shin A, McBride M et al. (2001):** Percutaneous screw fixation or cast immobilization for nondisplaced scaphoid fractures. *JBJS.*, 83(4): 483.
4. **Gutow A (2007):** Percutaneous fixation of scaphoid fractures. *JAAOS-Journal of the American Academy of Orthopaedic Surgeons*, 15(8): 474-485.
5. **Ibrahim T, Qureshi A, Sutton A et al. (2011):** Surgical versus nonsurgical treatment of acute minimally displaced and undisplaced scaphoid waist fractures: pairwise and network meta-analyses of randomized controlled trials. *The Journal of Hand Surgery*, 36(11): 1759-1768.
6. **Cooney W, Bussey R, Dobyns J et al. (1987):** Difficult wrist fractures. Perilunate fracture-dislocations of the wrist. *Clinical Orthopaedics and Related Research*, 214: 136-147.
7. **Severo A, Cattani R, Schmid F et al. (2018):** Percutaneous treatment for waist and proximal pole scaphoid fractures. *Revista Brasileira de Ortopedia (English Edition)*, 53(3): 267-275.
8. **Polsky M, Kozin S, Porter S et al. (2002):** Scaphoid fractures: dorsal versus volar approach. *Orthopedics*, 25(8): 817-819.
9. **Folberg C, Ruschel P, Pignataro M et al. (2004):** Fixação percutânea das fraturas de terço médio de escafoide. *Rev Bras Ortop.*, 39(7): 363-70.
10. **Brutus J, Baeten Y, Chahidi N et al. (2002):** Percutaneous Herbert screw fixation for fractures of the scaphoid: review of 30 cases. *Chirurgie de la Main*, 21(6): 350-354.
11. **Jeon I, Oh C, Park B et al. (2003):** Minimal invasive percutaneous Herbert screw fixation in acute unstable scaphoid fracture. *Hand Surgery*, 8(02): 213-218.
12. **Wozasek G, Moser K (1991):** Percutaneous screw fixation for fractures of the scaphoid. *The Journal of Bone and Joint Surgery*, 73(1): 138-142.
13. **Adolfsson L, Lindau T, Arner M (2001):** Acutrak screw fixation versus cast immobilisation for undisplaced scaphoid waist fractures. *Journal of Hand Surgery*, 26(3): 192-195.
14. **Schädel-Höpfner M, Marent-Huber M, Gazyakan E et al. (2010):** Acute non-displaced fractures of the scaphoid: earlier return to activities after operative treatment. A controlled multicenter cohort study. *Archives of Orthopaedic and Trauma Surgery*, 130(9): 1117-1127.
15. **Dias J, Wildin C, Bhowal B et al. (2005):** Should acute scaphoid fractures be fixed?: a randomized controlled trial. *JBJS.*, 87(10): 2160-2168.
16. **Bushnell B, McWilliams A, Messer T (2007):** Complications in dorsal percutaneous cannulated screw fixation of nondisplaced scaphoid waist fractures. *The Journal of Hand Surgery*, 32(6): 827-833.