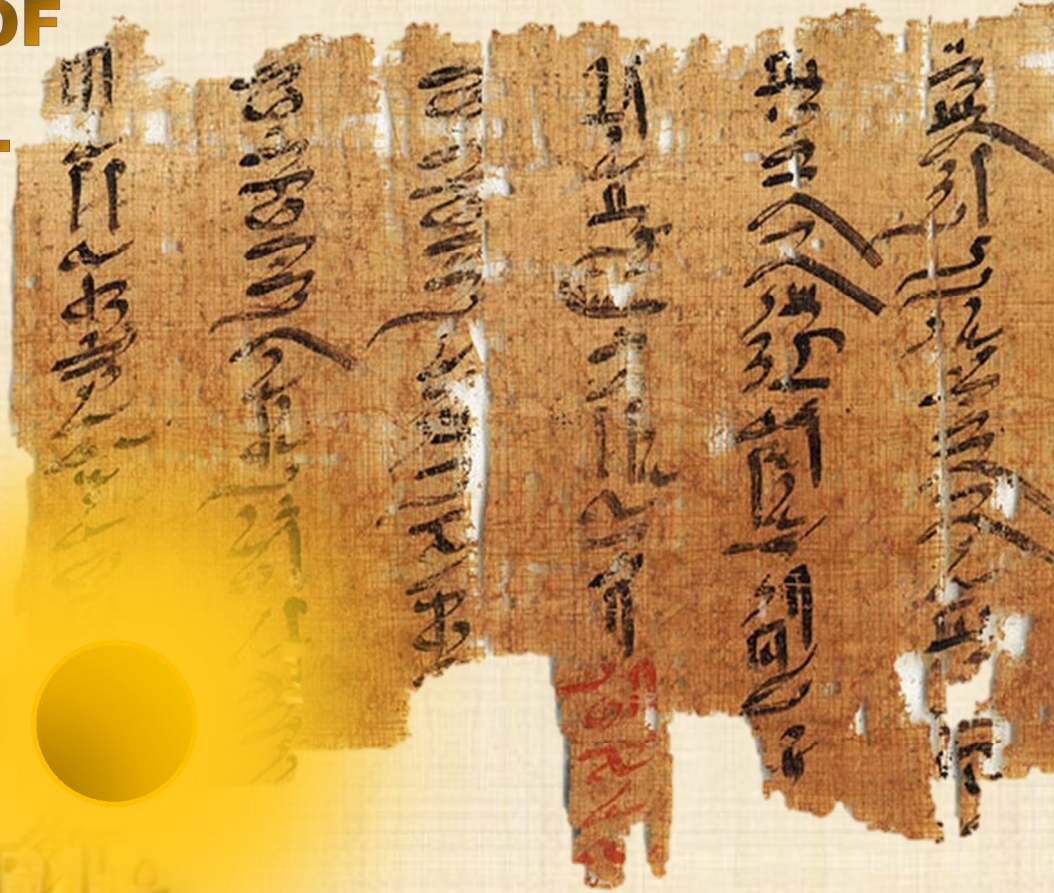


IJMA

INTERNATIONAL JOURNAL OF MEDICAL ARTS



VOLUME 2, ISSUE 4, AUTUMN 2020)



<http://ijma.journals.ekb.eg/>

Print ISSN: 2636 - 4174

Online ISSN: 2682 - 3780



Available online at Journal Website
<https://ijma.journals.ekb.eg/>
Main subjects [Medicine, Radiology]*



Original article

Comparison Study between Chest Ultrasonography and High Resolution CT in Diagnosis and Assessment of Interstitial Lung Diseases

Mohamed Gamal Mohamed Elmansy^[a], Ramadan Shawki Abdelaziz^[a], Mostafa Mohamed Mostafa Shaqueer^[b],
Eisa Ibrahim Afify^[c]

Department of Chest Diseases, Damietta Faculty of Medicine, Al-Azhar University, Egypt^[a].

Department of Radiology, Damietta Faculty of Medicine, Al-Azhar University, Egypt^[b].

Department of Chest Diseases, Damietta Faculty of Medicine, Al-Azhar University, Egypt^[c].

Corresponding author: Eisa Ibrahim Afify

Email: eisaafify61@gmail.com

Received at: August 29, 2020; Revised at: 25-9-2020; Accepted at: September 29, 2020

DOI: [10.21608/ijma.2020.116073](https://doi.org/10.21608/ijma.2020.116073)

ABSTRACT

Background: Chest high-resolution computed tomography [HRCT] is considered the “gold” standard for radiological diagnosis of interstitial lung disease [ILD]. However, it is not available in all health care facilities and its high cost is a limitation for its wide use. Ultrasound could provide a suitable alternative.

Aim of the work: To detect the role of transthoracic lung ultrasonography [LUS] in diagnosis and assessment of ILD and to correlate it with HRCT as a gold-standard diagnostic modality.

Methods: This included fifty patients who were admitted with clinical features suggestive of ILD. All were clinically evaluated [by full history and physical examination], submitted to pulmonary functions, arterial blood gases, lung ultrasound and HRCT.

Results: The total sum of B-lines was 72.64 ± 39.45 and the total positive chest areas [> 3 B-lines] 6.47 ± 2.35 . The most common ultrasound finding was thick pleural line. Finally, there was positive [proportional], moderate, significant correlation between Warrick's score [HRCT] and B-lines distance [LUS]. However, Warrick score correlated negatively with each of six-minute walk test, partial arterial oxygen tension and forced vital capacity.

Conclusions: Lung ultrasound as a diagnostic modality for ILD revealed that, it is a useful tool, as there was good correlation between LUS and HRCT. LUS is cheap, accessible and radiation-free diagnostic tool. It could play a stand alone or a complementary role in the diagnosis and monitoring of ILD.

Keywords: Lung Ultrasound; High-Resolution; Computed Tomography; Interstitial Lung Disease; B-line.

This is an open access article registered under the Creative Commons, ShareAlike 4.0 International license [CC BY-SA 4.0] [<https://creativecommons.org/licenses/by-sa/4.0/legalcode>]

Please cite this article as: Elmansy MGM, Abdelaziz RS, Shaqueer MMM, Afify EI. Comparison Study between Chest Ultrasonography and High Resolution CT in Diagnosis and Assessment of Interstitial Lung Diseases. IJMA 2020; 2 [4]: 860-865. DOI: [10.21608/ijma.2020.116073](https://doi.org/10.21608/ijma.2020.116073)

* Main subject and any subcategories have been classified according to research topic.

INTRODUCTION

Interstitial lung disease [ILD] is defined as a thickening of the pulmonary interstitium [best described by the spaces between the alveolar epithelium and capillary endothelium] with consequent impairment of gas exchange. The process usually developed due to diverse etiologies^[1].

ILD is not a single disease, but it includes a group of disorders that are characterized by varying combinations of inflammation and fibrosis may be idiopathic or caused by exposure to organic and inorganic substances [i.e pneumonitis and pneumoconiosis], medical conditions [i.e., connective tissue diseases [CTDs], multisystem diseases, drugs, infection and radiation therapy ^[2].

Evaluation of ILD is usually made based on combination of clinical, functional, radiological and histological data ^[3].

High resolution CT of the chest [HRCT] is the gold standard tool for the diagnosis of ILD ^[4]. However, lung ultrasound [LUS] had recently become more and more important in evaluating a lot of thoracic conditions and pleural effusions ^[5].

Data about the use of LUS is few, either its use to monitor patients with any lung pathology or as a screening modality to assess patients with a lung disease^[6].

The main finding is LUS is B-lines. It can be described as unifocal or multi-focal with variable arrangement ^[7].

The presence of ≥ 3 B-lines between two ribs in same scan is a sign for the diagnosis of interstitial syndrome^[8].

Overall B-lines, consolidation and pleural irregularities discovered by LUS are indicative of lung pathology^[8].

Being a relatively cheap, portable and safe diagnostic modality, there is increasing concern about the use of LUS in diagnosis of different chest diseases [the era of LUS]. However, its diagnostic efficacy must be addressed in the line of standard available tools.

AIM OF THE WORK

To detect the role of transthoracic LUS in diagnosis and assessment of ILD and to correlate

it with HRCT as a gold-standard diagnostic modality.

PATIENTS AND METHODS

This study was prospective controlled study that had been conducted in the department of chest diseases, Al-Azhar University Hospital- Damietta. A total of [50] patient admitted with radiological features of ILD.

Patients with ILD, either on clinical, laboratory or radiological, who accept to participate in the study were included in the current study. On the other side, patients with left side heart failure, bronchiectasis, aspiration pneumonia and chronic kidney disease were excluded from the study.

The study protocol was investigated by the local research and ethics congress of Damietta Faculty of Medicine and an approval was obtained. In addition, an informed consent was signed by each participant. Patient rights were guaranteed. Collected data were used only for the purpose of research and patient identity did not breached.

All participants were evaluated clinically through history taking and physical examination.

All patients answered a questionnaire about their personal data, medical history, environmental and drug exposure, symptoms [Borg test dyspnea score and Borg test for fatigue pre- and post-effort]; and all performed a six-minute walking test to assess distance versus significant desaturation [more than 3%]. Then all under chest ultrasound and HRCT. They were categorized according to Warrick's score into mild, moderate and severe groups, describing the severity of ILD.

After diagnostic exam and HRCT, all patients underwent LUS in 10 intercostal spaces as described previously^[9].

Assessments of distribution and pattern of B-lines was performed, with recording of total number, and the sum of total B-lines in all lung areas represented the total score. Then, this score was change to a simplified score as the sum of positive chest areas. The positive chest area is the area where ≥ 3 B-lines were discovered, in the predefined site^[9,10,16].

We used the two scores [total and simplified] and correlated them with HRCT score [Warrick's score].

For respiratory functions, the standard spirometry was done by Viasys Master Screen Spirometer Body/DFF [Viasys Healthcare GmbH, Höchberg, Germany]. In addition, arterial blood gases determined by Opti CCA-TS2 blood gas analyzer.

Data management and Statistical Analysis: Collected data were recorded then presented and analyzed statistically by computer using SPSS version 22 [SPSS Inc. Chicago, IL, U.S.A]. Data were handled using appropriate statistical tests of significance such as: Shapiro-Wilk’s W-test was applied for checking the normality assumption of continuous variables. Chi-square test and Fisher’s exact test, wherever appropriate, were used for categorical data analysis. Independent two-sample t -tests or Mann-Whitney-U tests were applied to compare the continuous variables between the two groups, and one way analysis of variance for more than two groups. Different parameters were assessed with Spearman’s correlation, and **P** value equal to or less than 0.05 was considered statistically significant.

RESULTS

Patient ages in the current study ranged between 19 to 84 years and the mean age was 52.14±17.16 years. In addition, males represented

52% and females represented 48%. Other detailed results of patient weight, height and body mass index [BMI] were presented in table [1].

Results of chest ultrasound and high resolution CT presented in table [2]. The pleural line was thick in 24%, smooth in 46.0% and irregular in 30.0%. however, CT revealed ground glass opacity [GCO] in 44%, reticular interstitial pattern in 38%, honeycombing in 14%, crazy paving in 10.0% and consolidation in 20.0%.

Detailed ultrasound findings are presented in table [3]. According to Warrick score, there were 23 [46.0%] with mild disease, 22[44.0%] with moderate disease and 5[10.0%] with severe disease. The mean Warrick score was 16.86 ± 6.82.

There was significant difference between mild, moderate and severe groups as regard to Warrick score, six-minutes walk tests, B-lines distance, PaO2 and FVC [Table 4]. In the current work, there was positive [proportional], moderate, significant correlation between Warrick’s score [HRCT] and B-lines distance [LUS]. However, Warrick score correlated negatively with each of six-minute walk test, partial arterial oxygen tension and forced vital capacity [Table 5].

Table [1]: Table [1]: Demographic data of the studied patients

| Variable | | Patients [n=50] |
|--|--------|------------------------------|
| Age [years] Mean ± SD [Range] | | 52.14 ± 17.16 [19 - 84] |
| Sex | Male | 26 [52%] |
| | Female | 24 [48 %] |
| Weight [kg] Mean ± SD [Range] | | 88.4 ±18.35 [53 – 137] |
| Height [m] Mean ± SD [Range] | | 1.77 ± 0.0956 [1.53 – 1.92] |
| BMI [kg/m ²] Mean ± SD [Range] | | 25.08 ± 4.54 [17.87 – 35.13] |

Table [2]: Chest ultrasound and high-resolution CT findings of the studied patients

| | | | Patients [n=50] |
|--------------------|--------------------------------------|-----------|-----------------|
| Chest ultrasound | Total B-lines | | 72.64 ± 39.45 |
| | Positive Chest areas [≥ 3 B-lines] | | 6.47 ± 2.35 |
| | Pleural line | Thickened | 12 [24%] |
| | | Smooth | 23 [46%] |
| Irregular | | 15 [30%] | |
| High-resolution CT | GGO | | 22 [44.00%] |
| | Reticulonodular interstitial pattern | | 19 [38.0%] |
| | Honeycombing | | 7 [14.0%] |
| | Crazy paving | | 5 [10.0%] |
| | Consolidation | | 10 [20.0%] |

Table [3]: Distribution of the studied cases according to US [n = 50]

| US | Right | | Left | |
|----------------|-------|------|------|------|
| | No. | % | No. | % |
| Area 4 | | | | |
| B. lines < 5 | 4 | 8.0 | 11 | 22.0 |
| B. lines 5-15 | 25 | 50.0 | 23 | 46.0 |
| B. lines 16-30 | 19 | 38.0 | 13 | 26.0 |
| B. lines > 30 | 2 | 4.0 | 2 | 4.0 |
| Area 3 | | | | |
| B. lines < 5 | 3 | 6.0 | 10 | 20.0 |
| B. lines 5-15 | 31 | 62.0 | 21 | 42.0 |
| B. lines 16-30 | 16 | 32.0 | 16 | 32.0 |
| B. lines > 30 | 0 | 0.0 | 3 | 6.0 |
| Area 2 | | | | |
| B. lines < 5 | 23 | 46.0 | 16 | 32.0 |
| B. lines 5-15 | 23 | 46.0 | 30 | 60.0 |
| B. lines 16-30 | 4 | 8.0 | 4 | 8.0 |
| Area 1 | | | | |
| B. lines < 5 | 17 | 34.0 | 19 | 38.0 |
| B. lines 5-15 | 28 | 56.0 | 25 | 50.0 |
| B. lines 16-30 | 5 | 10.0 | 5 | 10.0 |
| B. lines > 30 | 0 | 0.0 | 1 | 2.0 |

Table [4]: Different data according to Warrick score among the studied patients

| Parameters | Mild[n=23] | Moderate[n=22] | Severe[n=5] | p |
|-------------------------|---------------|----------------|---------------|--------|
| Warrick score | 11.12 ± 3.41 | 20.18 ± 3.26 | 29.2 ± 0.936 | <0.001 |
| 6-min walk test | 454.5 ± 107.1 | 431.8 ± 82.37 | 218.1 ± 34.21 | <0.001 |
| B-lines distance | 4.82 ± 1.33 | 5.29 ± 1.34 | 5.46 ± 1.31 | 0.002 |
| PaO₂ | 69.21 ± 6.55 | 67.09 ± 6.83 | 64.43 ± 7.39 | 0.003 |
| FVC | 62.13 ± 7.04 | 59.36 ± 5.73 | 56.45 ± 8.61 | 0.001 |

PaO₂: Partial arterial oxygen tension; FVC: forced vital capacity.

Table [5]: Correlation between Warrick score and different parameters among the studied patients

| | Warrick score | |
|--------------------------|---------------|------------------|
| | r | p |
| Six-min walk test | -0.540 | <0.001 |
| B-lines distance | 0.595 | <0.001 |
| PaO₂ | -0.487 | 0.001* |
| FVC | -0.463 | 0.001* |

PaO₂: Partial arterial oxygen tension; FVC: forced vital capacity.

DISCUSSION

ILD is a group of heterogeneous disorders of different causes, clinical and radiological patterns. It affects the parenchyma of the lungs and its diagnosis is a challenge^[9]. This was prospective controlled study that was being conducted in the department of chest diseases, Al-Azhar University Hospital- Damietta.

Results of the current study regarding patient characteristics agree with **Man et al.**^[10]; in which 58 patients were included, 58.6% males and 41.4% females, with an average age of 58.97± 15.59

years. **Cömert et al.**^[11] reported a mean age of 59.2±14.2 years.

Chest high-resolution CT findings in the current work come in agreement with **Man et al.**^[10] who reported that, HRCT score was 21.66 ± 7.79 and a total number of B-lines score was 78.72 ± 44.3, and average positive chest areas score was 7.5. They concluded that, LUS can represented an appreciated diagnostic toll for the assessment of the chest, being a bedside procedure, widely available, and inexpensive^[12].

The present study also revealed a significant correlation between B-lines score and HRCT scores. **Man et al.** [10] demonstrated comparable results. They reported a good correlation between scores of both modalities, and their data sustained the value of LUS use as a diagnostic modality for the diagnosis and staging of ILD when compared to HRCT. **Gargani et al.**[13] in ILD associated with systemic sclerosis, for the first time calculated the B-line score and considered the test positive when the total B-lines in all scanning sites was more than 10. Additionally, **Gutierrez et al.**[14] computed two different LUS scores reported a statistically significant correlation between the two scores.

The Warrick score was used to assess disease severity [parenchymal extent of pathology]. It starts by alveolitis and reaching up to fibrosis. The score vary between 0 [minimum] to 30 [maximum] and higher score indicates severe disease, with high degree of change on radiological study[15].

In the present study, 46% had mild, 44% had moderate and 10% had severe disease according to Warrick score. **Sarac et al.**[15] reported a lower Warrick score, and their patients had mild to moderate disease. In **Farag et al.**[16] revealed no association between B-lines scores and different grades of disease severity discovered by HRCT.

We found that Warrick score is significantly and inversely correlated with total B-line number and positively correlated with B-line distance between each two adjacent B-lines. These results are in accordance with **Hasan and Makhlof** [17] as they reported that the distance between each two adjacent B-lines positively correlated with Warrick score [r=0.693]. Moreover **Cogliati et al.**[18] reported that, B-line score was significantly correlated with HRCT score [r=0.806]. Similar results were reported by **Mohammadi et al.** [19]. Also, we found that there is a significant positive correlation between Warrick score and B-lines distance, while there is a significant negative correlation between Warrick score and 6-min walk test, PaO₂ & FVC.

El-Fatah et al.[20] reported a significant positive correlation between Warrick score and the distance between B-lines, and negative correlation between Warrick score and the number of B-lines, PaO₂, 6 minutes walk test, forced vital capacity, and pleural line thickness.

Conclusion: To date, no imaging modalities are able to provide all the information yielded by chest HRCT, which remains the gold standard modality to assess pulmonary fibrosis. In addition, it is the single imaging modality which permits the evaluation of the whole lung. However, the use of LUS in ILD can be a useful, cheap, accessible, and radiation-free investigative tool. The current work confirmed the possible role of LUS as a significant stand alone or adjuvant assessment tool for diagnosis and/or monitoring of ILD patients, but future studies are mandatory to generalize these results.

Financial and Non-financial Relationships and Activities of Interest

None.

REFERENCES

1. **Alfaro TM, Afonso M, Torrisi SE.** Highlights from the 2018 European Respiratory Society Congress presentations on interstitial lung diseases. *J Thorac Dis.* **2018**; 10 [Suppl 25]: S3024-S3028. doi: 10.21037/jtd.2018.08.101.
2. **Chan C, Ryerson CJ, Dunne JV, Wilcox PG.** Demographic and clinical predictors of progression and mortality in connective tissue disease-associated interstitial lung disease: a retrospective cohort study. *BMC Pulm Med.* **2019** Oct 31; 19[1]: 192. doi: 10.1186/s12890-019-0943-2.
3. **Desai SR, Prosch H, Galvin JR.** Plain film and HRCT diagnosis of interstitial lung disease. 2019 Feb 20. In: Hodler J, Kubik-Huch RA, von Schulthess GK, editors. *Diseases of the Chest, Breast, Heart and Vessels 2019-2022: Diagnostic and Interventional Imaging* [Internet]. Cham [CH]: Springer; **2019**. Chapter 4. PMID: 32096944.
4. **Sayed SS, Agmy GM, Said AF, Kasem AH.** Assessment of transthoracic sonography in patients with interstitial lung diseases. *Egy J Bronchol.* **2016**; 10.2: 105. doi: 10.4103/1687-8426.184375
5. **Wang L, Guan X, Chen M, Chen J, Si X, Jiang Z, et al.** [Clinical value of lung ultrasound in the late goal-directed fluid removal in critically ill patients underwent fluid resuscitation]. *Zhonghua Yi Xue Za Zhi.* **2016**; 96 [17]: 1359-63. Chinese. doi: 10.3760/cma.j.issn.0376-2491.2016.17.012.
6. **Falcetta A, Leccardi S, Testa E, Fenoglio L, Melchio R.** The role of lung ultra-sound in the diagnosis of interstitial lung disease. *Shanghai Chest* **2018**; 2[5]: 41-51. doi: 10.21037/shc.2018.04.10
7. **Soldati G, Demi M.** The use of lung ultrasound images for the differential diagnosis of pulmonary and cardiac interstitial pathology. *J Ultrasound.* **2017** Apr 7; 20 [2]: 91-96. doi: 10.1007/s40477-017-0244-7.

8. **Radzina M, Biederer J.** Ultrasonography of the Lung. *Rofo.* **2019** Oct; 191 [10]: 909-923. English. doi: 10.1055/a-0881-3179.
9. **Dhooria S, Agarwal R, Sehgal IS, Prasad KT, Garg M, Bal A, Aggarwal AN, Behera D.** Spectrum of interstitial lung diseases at a tertiary center in a developing country: A study of 803 subjects. *PLoS One.* **2018**; 13 [2]: e0191938. doi: 10.1371/journal.pone.0191938.
10. **Man MA, Elena D, Bianca H, Cosmina B, Alina R, Adriana P, et al.** Correlation between transthoracic lung ultrasound score and HRCT features in patients with interstitial lung disease. *J Clin Med* **2019**; 8, 1199; doi: 10.3390/jcm8081199.
11. **Cömert SS, Benan Ç, Coskun D, Elif P, Ali F, Banu S, et al.** Ultrasound in the assessment of interstitial lung diseases: Correlation with high-resolution computed tomography and lung functions, *Eur Respir J.* **2015**; 46: PA3841; doi: 10.1183/13993003.congress-2015.PA3841.
12. **Delle Sedie A, Doveri M, Frassi F, Gargani L, D'Errico G, Pepe P, et al.** Ultrasound lung comets in systemic sclerosis: a useful tool to detect lung interstitial fibrosis. *Clin Exp Rheumatol.* **2010**; 28 [5] [Suppl 62]: S54. PMID: 21050546.
13. **Gargani L, Doveri M, D'Errico L, Frassi F, Bazzichi ML, Delle Sedie A, et al.** Ultrasound lung comets in systemic sclerosis: a chest sonography hallmark of pulmonary interstitial fibrosis. *Rheumatology [Oxford].* **2009**; 48 [11]: 1382-7. doi: 10.1093/rheumatology/kep263.
14. **Gutierrez M, Salaffi F, Carotti M, Tardella M, Pineda C, Bertolazzi C, et al.** Utility of a simplified ultrasound assessment to assess interstitial pulmonary fibrosis in connective tissue disorders--preliminary results. *Arthritis Res Ther.* **2011**; 13 [4]: R134. doi: 10.1186/ar3446.
15. **Sarac S, Kavas M, Sahin M, Aras G, Afsar GC, Tezel YB.** Relation of Warrick Score and Polysomnographic Parameters in Patients with Interstitial Lung Disease. *Med Sci Monit.* **2019**; 25:2087-2095. doi: 10.12659/MSM.914905.
16. **Farag TS, Adawy ZR, Sakr LK, Abdellateef HS.** Transthoracic US features of diffuse parenchymal lung diseases. *Egypt J Bronchol* **2017**; 11:179-87. doi: 10.4103/ejb.ejb_3_17.
17. **Ghanem MK, Makhlof HA, Hasan AA, Alkarn AA.** Acute pulmonary thromboembolism in emergency room: gray-scale versus color Doppler ultrasound evaluation. *Clin Respir J.* **2018**; 12[2]:474-482. doi: 10.1111/crj.12547.
18. **Cogliati C, Antivalle M, Torzillo D, Birocchi S, Norsa A, Bianco R, et al.** Standard and pocket-size lung ultrasound devices can detect interstitial lung disease in rheumatoid arthritis patients. *Rheumatology [Oxford].* **2014**; 53 [8]: 1497-503. doi: 10.1093/rheumatology/keu033.
19. **Mohammadi A, Oshnoei S, Ghasemi-rad M.** Comparison of a new, modified lung ultrasonography technique with high-resolution CT in the diagnosis of the alveolo-interstitial syndrome of systemic scleroderma. *Med Ultrason.* **2014** Mar; 16 [1]: 27-31. doi: 10.11152/mu.2014.2066.161.am1so2.
20. **El-Fatah S, Radwa A, Randa I.** Fayoum experience in ultrasonographic evaluation of diffuse parenchymal lung disease. *Egypt J Bronchol.* **2019**; 13 [2]: 204-2013. doi: 10.4103/ejb.ejb_54_18

International Journal

<https://ijma.journals.ekb.eg/>

Print ISSN: 2636-4174

Online ISSN: 2682-3780

of Medical Arts