

Role of MRI Assessment of the Patellar Instability

Mariana Fikry Nashed, Mohammed Amin Nassef, Amir Louis Louka

Radiology Department, Faculty of Medicine, Ain-Shams University

Corresponding author: Mariana Fikry Nashed, Mobile: +201221584200, E-mail: marianafikrynashed@gmail.com

ABSTRACT

Background: Patello-femoral stability is principally influenced by anatomic factors. Understanding the anatomy and biomechanics of the patello-femoral joint provides insight on the etiology and management of patellar instability. Magnetic resonance imaging (MRI) has emerged as an auxiliary method for investigating patello-femoral instability, particularly for detecting osteochondral lesions and for evaluating the medial patello-femoral ligament (MPFL).

Objective: descriptive study including analysis of MRI knee done for patients with patellar instability suspected clinically with or without history of trauma.

Patients and Methods: thirty patients were included in this study, all with suspicious patellar instability from Ain-Shams University, orthopedic clinic and other private clinics. A cross-sectional study was held where all the patients under-went MRI routine knee protocol. MRI knee images were interpreted for identification of different pathologies contributing to patellar instability.

Results: sixty percent of the patients included in our study had MPFL injury, 43% showed patella alta, 83% showed trochlear dysplasia (by different measurements) and 43% showed lateral displacement of TT.

Conclusion: MRI the modality of choice in diagnosing different pathologies of patellar instability, for its value in assessing soft tissue structures, detailed imaging of the cartilage and applying all measurement required.

Keywords: medial patello-femoral ligament (MPFL), tibial tubercle to trochlear groove distance (TT-TG distance), vastus medialis obliquus (VMO), quadriceps angle (Q-angle).

INTRODUCTION

The patello-femoral joint (PFJ) enhances our ability of knee flexion and extension and it is assumed to have evolved through men's ability of having adopted a bipedal gait. This articulation between patella and femur is relatively complex and displays a complicated biomechanical behavior⁽¹⁾.

The biomechanical characteristics of the patello-femoral joint are the result of a complex interplay of components. The statics and dynamics of this articulation involve the geometries of the patella and the trochlea, the passive soft tissue restraints of capsule and retinaculum, and the coordination of the quadriceps. Additionally, angular and rotational limb alignment can affect patello-femoral mechanics and kinematics. Bottom line, it is all about the balance of the extensor mechanism of the knee⁽²⁾. The etiologies of patello-femoral disorders may be intra-articular (trochlear dysplasia, patellar dysplasia), peri-articular (hypoplasia of vastus medialis, patella alta, increased external rotation of the proximal tibia with lateralization of the patellar tendon insertion) and extra-articular (increased valgus positioning of the distal femur, sometimes in combination with genu recurvatum and increased anterior torsion of the femoral neck⁽³⁾). Magnetic resonance imaging (MRI), providing thinner and

higher-resolution scans, allows a more accurate study of the patello-femoral joint cartilage surface than CT does. Furthermore, it does not involve the use of ionizing radiation and allows measurements to be taken at the level of the cartilage rather than only at that of the sub - chondral bone as in conventional radiology⁽⁴⁾.

Routine MR imaging protocols are sufficient for most pathology related to the extensor mechanism. The proton density fat suppression sequence, which is universally included in routine knee protocols, is sensitive for tendon, bone and articular cartilage pathology. The sagittal and axial planes are the most useful for assessing patello-femoral dysplasia⁽⁵⁾.

Increased patellar height (Patella alta) is a key factor causing patellar instability and is present in 30% of patients with recurrent patellar dislocation. The importance of increased patellar height in the study of patello-femoral (PF) disorders lies on the reduced "engagement" between the two articulating bones: the patella and the femoral trochlea, which is necessary to provide to the patella the required mechanical stability throughout the range of motion, normally the ratio between the patellar tendon length and the maximal diagonal measurement of the patella is between 0.76 and 1.49⁽⁶⁾.

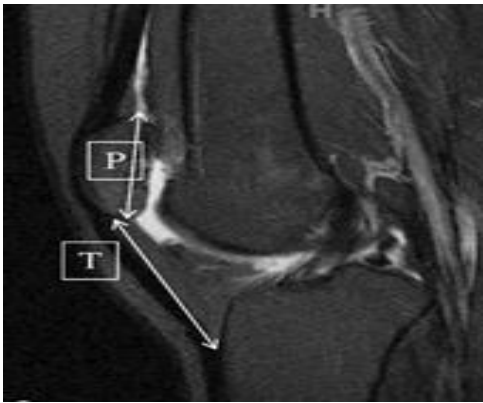


Figure 1: sagittal T2Wi image showing an abnormal insall–salvati ratio of 1.5 (patellar length P to patellar tendon; T ratio) in a 19-year-old woman with antero-lateral knee pain.

Patellar tilt and subluxation refers to the abnormal position of the patella in relation to the trochlear groove. Whereas, a tilt refers to increased lateral inclination of the transverse diameter of the patella, subluxation refers primarily to abnormal medio-lateral displacement of the patella in relation to the trochlea ⁽⁷⁾.

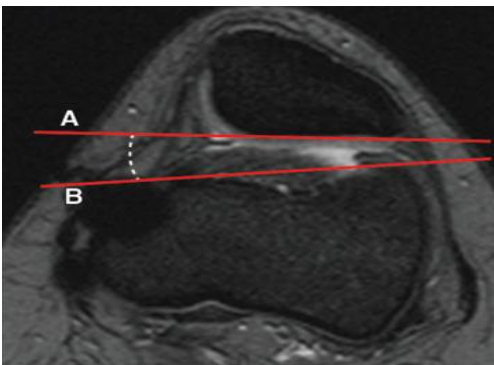


Figure 2: lateral patello-femoral angle assessed on an axial T2-weighted fat-saturated MR image showing patellar tilt caused by rupture of medial ligaments in an 18-year-old woman. The patello-femoral angle (dashed line) is demonstrated as the angle between a line drawn along the lateral joint surface of the patella (line A) and a line drawn along the anterior aspect of the condyles (line B). A patello-femoral angle opening laterally is considered normal. An angle opening medially indicates patellar tilt.

Trochlear dysplasia is an important bony abnormality causing patellar instability. Also, it is known that the lack of bony constraint in cases of trochlear dysplasia can put the ligaments at risk for repeated failure because of structural deficiency, decreasing the native medial tether ⁽⁸⁾.

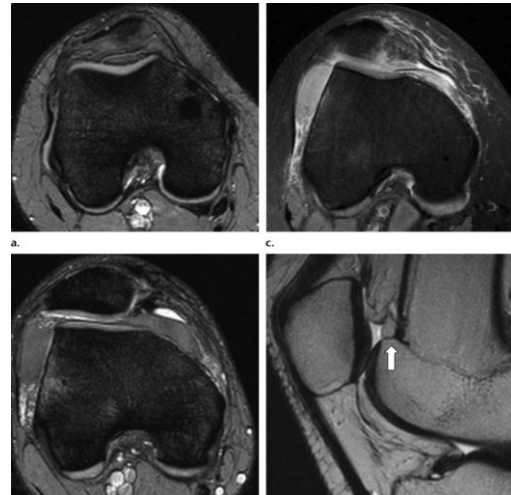


Figure 3: four types of trochlear dysplasia, according to the classification of **Dejour et al.** ⁽⁹⁾ on fat-saturated T2-weighted MR images. **A** - Axial image shows type A dysplasia: trochlear morphologic structures are preserved, but the sulcus is shallow. **b**- Axial image shows type B dysplasia: flat, horizontally oriented trochlear joint surface. **c**- Axial image shows type C dysplasia: flat, obliquely oriented trochlear joint surface with facet asymmetry. **d**- Sagittal image shows type D dysplasia: same as type C but with a prominent bone protrusion (arrow) on the para-sagittal view (cliff pattern).

For instance, a sulcus angle of more than 150° has been defined as indicating pathologic flattening of the joint surface on axial projections. Investigators correlating measurements of this angle obtained with conventional radiography and with MR imaging found substantial differences and showed that measurements with conventional radiographs underestimate the angle and are subject to other pitfalls that may lead to misinterpretation ⁽¹⁰⁾.

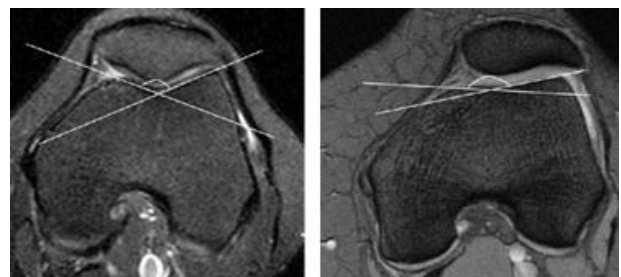


Figure 4: trochlear dysplasia.

a- Normal trochlear groove in a SPIR T2-weighted section in the axial plane (groove angle, <150°) and **b**- hypoplastic trochlear groove in a fat-suppressed SE T2-weighted section in the axial plane (groove angle, >150°) are observed drawn tangent to the posterior femoral condyle is

measured. It was reported that this angle was $\geq 10^\circ$ in patients with a distinct patellar tilt in physical examination. The tibial tuberosity-trochlear groove distance (TT-TG distance) is the distance in mm between the tibial tuberosity and the deepest point of the trochlear groove. It expresses, as a linear measurement, the Q angle. For years, a TT-TG of 15 mm was considered the threshold limit. Today, a TT-TG greater than 20 mm is considered pathological and therefore to warrant correction⁽⁸⁾.

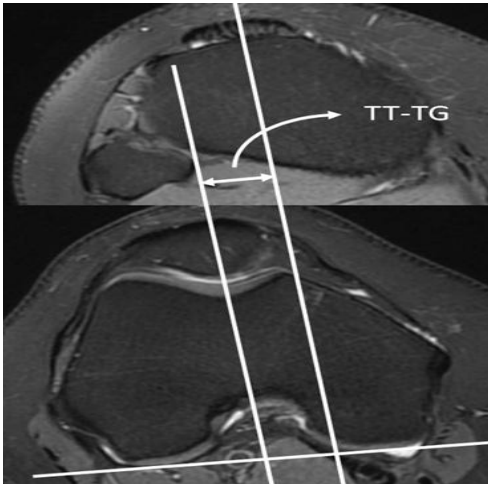


Figure 5: TT-TG measurement. On axial PD FS images the TT-TG measurement represents the distance between parallel lines through the trochlear groove and center of the tibial tubercle, using the posterior margins of the femoral condyles as a baseline.

Medial patello-femoral ligament (MPFL) acts as the major ligamentous restraint accounting for 50% to 60% of the total restraining force against lateral patellar dislocation. MPFL is frequently injured in acute patellar dislocation and primary (first-time) traumatic patellar dislocation results in total or partial MPFL disruption. MPFL injury can be diagnosed using magnetic resonance imaging (MRI)⁽¹²⁾.

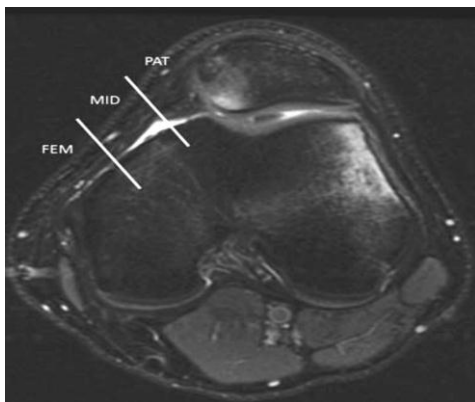


Figure 6: T2-weighted axial magnetic resonance image illustrating how the medial patello-femoral ligament (MPFL) was divided into

3 regions—the femoral origin (FEM), mid-substance (MID), and patellar insertion (PAT)—according to **Balcarek *et al.***⁽¹¹⁾ The fibers of the MPFL at the femoral and patellar insertion sites were defined as normal, partially disrupted, or completely disrupted. This image shows no injury to the MPFL but demonstrates medial patellar facet and lateral femoral condyle contusions.

The MPFL injuries were divided into partial and complete tears. The manifestations of the partial MPFL tear were defined as thickening and irregularity of the contour, including discontinuity of normal fibres and intra-ligamentous or extensive peri-ligamentous edema. The manifestations of the complete MPFL tear were defined as fibres in the expected region of the MPFL being completely discontinuous or appearing absent, with extensive surrounding edema⁽¹³⁾.

The partial or complete disruption of the MPFL was evaluated in three locations: at its patellar insertion (PAT), its mid-substance (MID) and its femoral attachment (FEM), including avulsion-type fracture at PAT or femoral origin. Injuries occurred simultaneously in more than one location of the MPFL were classified as combined injury⁽¹³⁾.

This study aimed to evaluate the role of MRI in the detection of predisposing factors that may contribute to the development of patello-femoral instability.

PATIENTS AND METHODS

This study was conducted on patients with patellar instability suspected clinically. The patients were referred from the Department of Orthopedics, Ain Shams University Hospitals and from other private clinics. The patients were investigated using magnetic resonance imaging (MRI).

- **Study place:** Ain Shams University Hospitals -Cairo-Egypt.
- **Sample size:** 30 patients
- **Equipment used:** a 1.5 Tesla Philips (Acheiva) MRI machine.

Inclusion criteria

- a. Age group: Any age.
- b. Both sexes are included.
- c. Patellar instability suspected clinically.

Exclusion criteria

Patients with contraindication to MR imaging (e.g. pacemaker, metallic implant and severe claustrophobia).

Method: MRI knee (routine protocol) will be obtained using 1.5 tesla MRI machines.

The patients were subjected to:

1. Consent taking.
2. History taking.
3. Clinical evaluation.
4. Checking for contraindication to MRI imaging (e.g. pacemaker, metallic implant, and severe claustrophobia).
5. Patients will lie supine.
6. Patients are asked to breathe quietly and not to move for the duration of the scan.

MRI protocol including the following:

1. MR images of the knee will be acquired by using a 1.5-T system with the manufacturer's knee coil.
2. Patient position: the patient will lie supine, feet first, position the knee in the knee coil and immobilize with cushions.
3. The images of the selected patients will be obtained in axial and sagittal planes acquiring T1, T2, STIR and PD weighted images.
4. Total imaging time: 15–20 minutes.

Complications and how to deal with:

No definite risk of complications.

Image Interpretation

MRI images were reviewed by radiologists in our department using the different sequences and planes to assess the factors contributing to patellar instability including: measurements for patellar height, patella tilt and subluxation, the trochlea of the femur for dysplasia, the medial and lateral patellar stabilizers, measurements for TT-TG distance and other associated injuries.

This study was approved by the Ethics Board of Ain Shams University.

STATISTICAL ANALYSIS

The analysis of data was done using IBM SPSS statistics (V. 24.0, IBM Corp., USA, 2016).the results were descriptive including study MRI knee studies of 30 patients suspected to have patellar instability clinically and were interpreted for presence of contributing pathologies, their pattern and their suggested type. Percentages of affected and normal studies were calculated, percentages of each pathology and relation to knee traumas was interpreted.

RESULTS

The studied population included 30 patients, 18 females (60%) and 12 males (40%). The mean

age group was 30 years with 9 patients under the age of 20 years old (30%), 12 patients between the ages of 20 to 30 years old (40%), 3 patients between the ages of 30 to 40 years old (10%), 3 patients between the age of 40 to 50 years old (10%) and 3 patients above the age of 50 years old (10%).

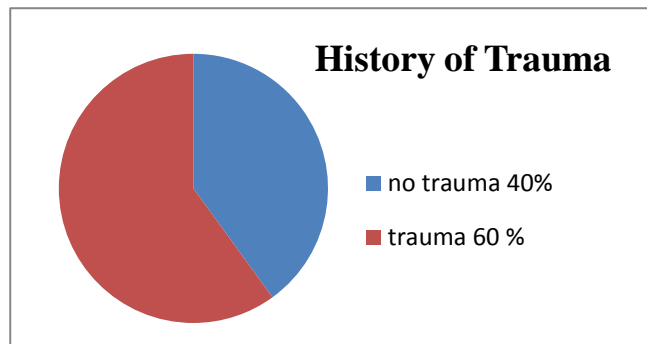


Figure 7: illustration of the percentage of patients with and without history of trauma

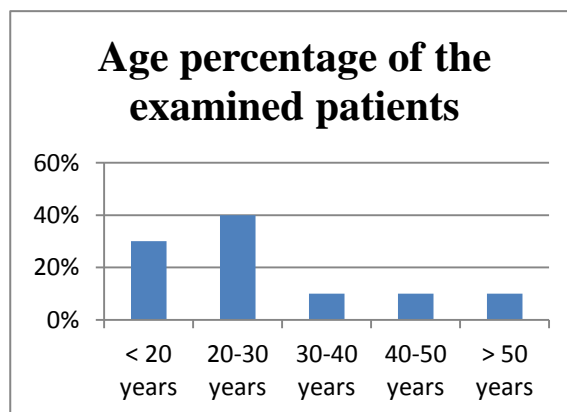


Figure 8: illustration of the percentage of patient's ages, the highest incidence was in patients between 20-30 years old.

From the 30 cases, 18 had symptoms on the right side (60%), 12 on the left side (40%). All cases (100%) complained of knee pain whereas 18 cases (60%) have a history of trauma to the knee (twisting the knee, fall or major trauma).

MRI images of the patient 30 examined showed: 18 cases (60%) had MPFL injury, 25 cases (83%) of them showed patellar subluxation, 24 cases (80%) showed patellar tilt, 13 cases (43%) showed patella alta, 25 cases (83%) showed trochlear dysplasia (by different measurements) and 13 cases (43%) showed lateral displacement of tibial tubercle (TT).

Table 1: shows the percentage of each pathological MRI finding contributing to patellar instability

MRI finding	Frequency	Percentage
MPFL injury	18	60%
Patellar subluxation	25	83%
Patellar tilt	24	80%
Patella alta	13	43%
Increased TT-TG distance	13	43%
Trochlear dysplasia	25	83%

DISCUSSION

Magnetic resonance imaging (MRI) has emerged as an auxiliary method for investigating patello-femoral instability, particularly for detecting osteochondral lesions and for evaluating the medial patello-femoral ligament (MPFL). Furthermore, many authors have perceived that MRI also makes it possible to detect predisposing factors and to make a variety of measurements with the same accuracy as CT scans, thus making this the preferred imaging method for evaluating patello-femoral instability⁽¹⁴⁾.

The current study was done to highlight the diagnostic value of MRI in the detection of different pathologies contributing to patellar instability with the advantage of the MRI over CT and X-ray in assessing the cartilage and soft tissue structures. We used a 1.5 Tesla Philips (Acheiva) MRI machine. We tested 30 patients of all age groups and both sexes with patella instability suspected clinically or with known history of knee trauma.

In our study, the MR images of the knee were acquired by using a 1.5-T system with the manufacturer's knee coils. The images were obtained in axial, sagittal and coronal planes acquiring T1, T2, STIR and PD weighted images. Total imaging time was about 15–20 minutes.

MRI images were reviewed by radiologists in our department. Patellar instability was diagnosed by assessment of multiple factors including: measurements for patellar height, patella tilt and subluxation, the trochlea of the femur for dysplasia, the medial and lateral patellar stabilizers, measurements for TT-TG distance and other associated injuries.

From the 30 cases we examined, 18 cases (60%) were exposed to trauma and showed tear of the MPFL at its femoral attachment in the axial planes, some showed partial tear and it was defined as thickening and irregularity of the

contour, including discontinuity of normal fibres, and intra-ligamentous or extensive peri-ligamentous edema and other showed complete tear: completely discontinuous or appearing absent MPFL, with extensive surrounding edema. In most cases, MPFL injury was associated with patella subluxation, the distance between two parallel lines (one is passing by the most lateral part of the patella and the other one by the most anterior part of the lateral femoral condyle) should not be more than 2mm.

The **Insall–Salvati (IS) ratio (TL/PL)** was used to assess the patellar height, it is the ratio of the patellar tendon length (TL) to the maximal diagonal length of the patella (PL) is calculated, with normal values ranging from to 0.74 to 1.50⁽¹⁵⁾.

In this study, and by evaluating the measurements of 30 knees by the Insall- Salvati ratio, patella alta was diagnosed in 13 cases (43%), in the sagittal plane, using the insall -salvati ratio, dividing the patellar tendon length over the maximum patellar diameter, the knees getting a ratio equal 1.5 or more were considered as patella alta.

In our study, patellar tilt was diagnosed in the axial plane in 24 cases (80%), by measuring the lateral patello-femoral angle; normally it measures 8° or more and opens laterally. Angles less than 8° or angles that open medially confirm patellar tilt.

MR imaging has been shown to allow highly accurate and reproducible measurements of the trochlear depth and femoral sulcus angle from both the subchondral bone and the articular cartilage; measurement from the articular cartilage may be more relevant because it constitutes the actual joint surface. Techniques for quantifying the degree of dysplasia have been standardized for MR imaging⁽¹⁰⁾.

In the current study, trochlear dysplasia was diagnosed in 25 cases (83%). Sulcus angle and trochlear depth have been measured in the axial planes to assess flattening of the trochlea, where sulcus angles > 150° or trochlear depth 3 mm or less, considered abnormal. Lateral inclination angle is another method of assessing the trochlear dysplasia; normally it measures 11°, less than that is an indicator for dysplasia.

TT-TG is a simple way to measure the valgus (lateralizing) forces acting on the patella. This distance was able to quantify the coronal alignment of the extensor mechanism, or what is called in clinical evaluation the “Q-angle.” TT-TG is the distance from the bottom of the most proximal part of the trochlear groove to the proximal part of the tibial tubercle, measured with

two CT/MRI superimposed cuts and expressed in millimeters ⁽⁷⁾.

In our study, 13 (43%) cases had increased TT-TG distance (lateralization of tibial tubercle), evaluated by using two axial cuts, the first one is through the proximal trochlea and the second cut goes through the proximal part of the tibial tubercle. These two cuts are then superimposed. The deepest point of the trochlear groove and the central point of the tibial tubercle are projected on a line tangential to the posterior femoral condyles. The distance between both points is measured, it is considered abnormal if it measures >2 cm.

CONCLUSION

-MRI is a beneficial tool in the evaluation different pathologies related to the patellar instability.

-The advantage of assessing the soft tissue structures of the knee increases the value of MR imaging over CT and conventional x ray.

LIMITATIONS OF THE STUDY

-Relatively small number of the studied population.

-Studies were evaluated by one radiologist without confirmation of inter-observer agreement.

REFERENCES

- Oliver S, Schindie R and Norman S (2011):** Basic kinematics and biomechanics of the patello-femoral joint. *Acta Orthop. Belg.*, 77: 421-431.
- Andrish J (2015):** Biomechanics of the patello-femoral Joint. *Oper. Tech. Sports Med.*, 23(2): 62–67.
- Arendt E, Dahm D, Dejour D and Fithian D (2004):** Patello-femoral joint: from instability to arthritis. *Instr. Course Lect.*, 63:355–368.
- Massimo B, Paolo F, Giulia C, Francesco U and Luca G (2013):** Section of Knee Surgery. *Joints*, 1(2):7-13.
- Ostlere S (2013):** The Extensor Mechanism of the Knee. *Radiol. Clin. N. Am.*, 51: 393–411.
- Monk AP, Doll HA, Gibbons CL, Ostlere S, Beard DJ and Gill HS (2011):** The patho-anatomy of patello-femoral subluxation. *J. Bone Joint Surg.Br.*, 93(10):1341—1347.
- Saggin PR, Saggin JI and Dejour D (2012):** Imaging in Patello-femoral Instability: An Abnormality-based Approach. *Sports Med. Arthrosc. Rev.*, 20:145–151
- Nelitz M, Theile M, Dornacher D, Wolfle J, Reichel H and Lippacher S (2012):** Analysis of failed surgery for patellar instability in children with open growth plates. *Knee Surg. Sports Traumatol. Arthrosc.*, 20:822-828.
- Dajour D, Renato P, Saggin JI (2013):** Imaging in Patello-femoral Instability: trochlear abnormalities. *Sports Med Arthrosc Rev.*, 20:145–151.
- Diederichs G, Issever AS, Scheffler S (2010):** MR Imaging of Patellar Instability: Injury Patterns and Assessment of Risk Factors. *Radio-Graphics*, 30:961–981.
- Sillanpää PJ, Salonen E, Pihlajamäki H and Mäenpää HM (2014):** Medial patello-femoral ligament avulsion injury at the patella: classification and clinical outcome. *Knee Surg. Sports Traumatol. Arthrosc.*, 22:2414–2418
- Balcarek P, Ammon J, Frosch S et al. (2010):** Magnetic Resonance Imaging Characteristics of the Medial Patello-femoral Ligament Lesion in Acute Lateral Patellar Dislocations Considering Trochlear Dysplasia, Patella Alta, and Tibial Tuberosity–Trochlear Groove Distance. *Arthroscopy: The Journal of Arthroscopic and Related Surgery*, 26:926-935.
- Zhang J and Lee CH (2015):** Clinics in diagnostic imaging. *Singapore Med. J.*, 56(10): 542-548.
- Sariah K, Dennis EK, Yi-Meng Y and Benton EH (2015):** Evaluation and management of patellar instability in pediatric and adolescent. *Athletes Sports Health*, 7(2):115-123.
- Chhabra A, Subhawong TK and Carrino JA (2011):** A systematized MRI approach to evaluating the patello-femoral joint. *Skeletal Radiol.*, 40(4): 375–387.