



Official Journal Issued by
Faculty of
Veterinary Medicine

Benha Veterinary Medical Journal

Journal homepage: <https://bvmj.journals.ekb.eg/>



Since 1990

Original Paper

Ultrasonographic Examination of Abdominal Wall Swellings in Cattle and Buffalo (*Bubalus bubalis*)

Elham Shaaban A. ^{1,*}, Al-Akraa A.M. ¹, Atef Abd Al-Galil ², Khalil A. H. ¹, El-Kassapy A. H. ¹, El-Maghraby H. M. ¹

¹Surgery, Anesthesiology and Radiology Department, Faculty of Veterinary Medicine, Benha University, Egypt

² Surgery, Anesthesiology and Radiology Department, Faculty of Veterinary Medicine, Monofia University, Egypt

ARTICLE INFO

Keywords

Abdominal wall

Buffalo, cattle

Swelling

Ultrasonography.

Received 20/07/2020

Accepted 26/07/2020

Available On-Line

01/10/2020

ABSTRACT

A total number of 114 clinical cases (63 cattle and 51 buffaloes) were included in the current study. These cases were suffering from different varieties of abdominal wall swellings (46 abscesses; 49 hernias and 19 hematomas) and they were subjected to ultrasonographic examination. From the aforementioned cases the unripened abscess appeared ultrasonographically as a circumscribed echogenic structure with mild distal acoustic enhancement while the ripened abscess appeared as anechoic to hypoechoic structure representing watery to creamy pus contents. The ripened abscess with chronic fibrotic omphalitis revealed a hyperechogenic band with an evident acoustic shadowing. Recent hematomas appeared as anechoic area (blood content) divided by a thin echogenic septum into small chambers toward its center, while old hematoma revealed anechoic to hypoechoic appearance divided by a thick echogenic septum. Reducible hernias revealed disruption of the abdominal wall continuity with intestinal loops and its characteristic peristaltic movement and anechoic, hypoechoic to echogenic contents while irreducible hernias characterized by an evident anechoic inflammatory exudates; reduced peristaltic movement and thick hernial sac with echogenic fibrous adhesions between the sac and the abdominal wall. In conclusion, ultrasonography provides an accurate, non-invasive and fast diagnostic tool for different abdominal wall swellings in cattle and buffalo.

1. INTRODUCTION

Abscesses, hematomas and hernias are the most common abdominal wall swellings (Magda and Abd El-Hakiem, 2012). Routine clinical examination provides some information about the location, associated pain, consistency as well as the reducibility of such swellings (Abouelnasr et al., 2016). However, differential diagnosis of such swellings is difficult in absence of ultrasound tools as different types of swellings shared similar clinical signs like abscess and irreducible hernia or abscess and incomplete organized hematoma (Cribb and Arroyo, 2018). Additionally, ultrasonography provides accurate details regarding the content, size, demarcation lining of the examined swelling and the suitable time for interference (Magda and Abd El-Hakiem, 2012). Fine needle aspiration of contents or biopsies also could be achieved through ultrasonographic guidance (Cribb & Arroyo, 2018). Depending on interfaces-echogenicity association, ultrasonography can discriminate most space occupying soft tissue masses from the surrounding structures, when other clinical examinations are inadequate (Buczinski, et al., 2010). The main objectives

of this study aim to describe the ultrasonographic findings for different varieties of abdominal wall swellings in cattle and buffalo.

2. MATERIAL AND METHODS

The study protocol was approved by the committee of animal welfare and ethics, Faculty of Veterinary Medicine, Benha University.

2.1. Animals and design of the study:

The present study was carried out on one hundred and fourteen clinical cases of cattle and buffalo (103 calves and 11 adult). Their ages ranged from 3-months up to 10-years old while their body weight were ranged from 70-500 kg/b wt. Based on clinical and physical examination, all animals were suffering from different varieties of external abdominal wall swelling. This study was conducted in the department of surgery, Anesthesiology and Radiology and Teaching Veterinary Hospital, Faculty of Veterinary Medicine, Benha University.

* Corresponding author: elhamshaban010@gmail.com

2.2. Ultrasonographic Examination

The ultrasonographic examination was performed on a sedated (Xylaject, Xylazine HCL 2% - Adwia co. – Egypt, in dose rate of 0.05 mg/kg b wt.), standing animal using a portable ultrasound machine (Chison ECO3 Expert, Medical EXPO, China) with an adjusted 2-6 MHz curvilinear or linear transducer (Barr and Gaschen, 2011). The area of examination was prepared by clipping and shaving of the hair, followed by application of coupling amount of gel. Probe maneuvered in transverse and sagittal planes starting from the healthy surroundings towards the center of the swelling. Ultrasonographic images of the swellings were evaluated objectively regarding the echogenicity of the contents, size, capsule thickness and duration.

3. RESULTS

Based on Ultrasonographic, clinical and physical examination as well as ultrasonographic guided biopsies; the abscess represents 40.35% of examined cases (46 cases; 10 unripened, 27 ripened and 9 ripened abscess with chronic omphalitis), while the abdominal wall hematomas represent 16.67% of examined cases (19 cases; 10 recent and 9 organized). In the main time, the abdominal hernias represent 42.98% of examined cases (49 cases; 28 reducible and 21 irreducible). Ultrasonographic examination of each swelling was described, classified and

recorded according to the stage of inflammatory condition; elapsed and echogenicity of the contents.

The echogenicity of abscess contents varied according to the natural of its contents and time elapsed. unripened abscess was recorded in 10 animals (7 cattle and 3 buffalo) at umbilical region (5 cases), ventral abdominal wall (3 cases) and lateral abdominal wall (2 cases). The characteristic ultrasonographic appearance of unripened abscess is a circumscribed structure with mixed echogenicity and mild evidence of acoustic enhancement underneath the swelling (Fig. 1). Abscess lancing in these cases was delayed until complete maturation.

Ripened abscess was observed in twenty-seven animals (12 cattle and 15 buffalo), thirteen cases of them at the umbilical region, 8 cases at the ventral abdominal wall and the other 6 cases at the lateral abdominal wall.

Ultrasonographically, the center of the ripened abscess appeared as anechoic to hypoechoic mass (Fig. 2). Ultrasonographic-guided needle aspiration for confirmatory diagnosis resulting in watery to creamy pus. In such a condition, a decision for lancing was occurred.

Ripened abscesses with chronic fibrotic omphalitis were observed in nine calves (4 cattle and 5 buffalo). In these cases, the ultrasonographic examination appeared as circumscribed structure with mixed echogenicity and hyperechoic band with an evident acoustic shadowing representing the fibrotic omphalitis (Fig. 3).

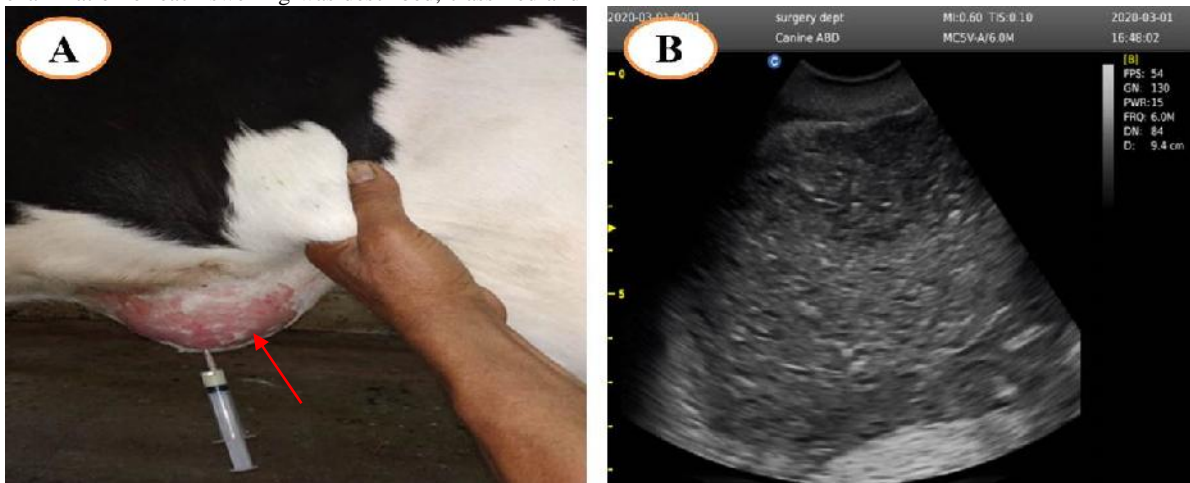


Figure (1) Showed unripened ventral abdominal wall abscess in cattle calf (red arrow) (A) with corresponding ultrasonographic examination showing circumscribed structure with mixed echogenicity and some hyperechoic dots represented the necrotic tissue and unripen foci (B). vure (1): showing unripened ventral abdominal wall abscess in cattle calf (A) with corresponding ultrasonographic examination showing circumscribed structure with mixed echogenicity and some hyperechoic dots represented the necrotic tissue and unripen foci (B).

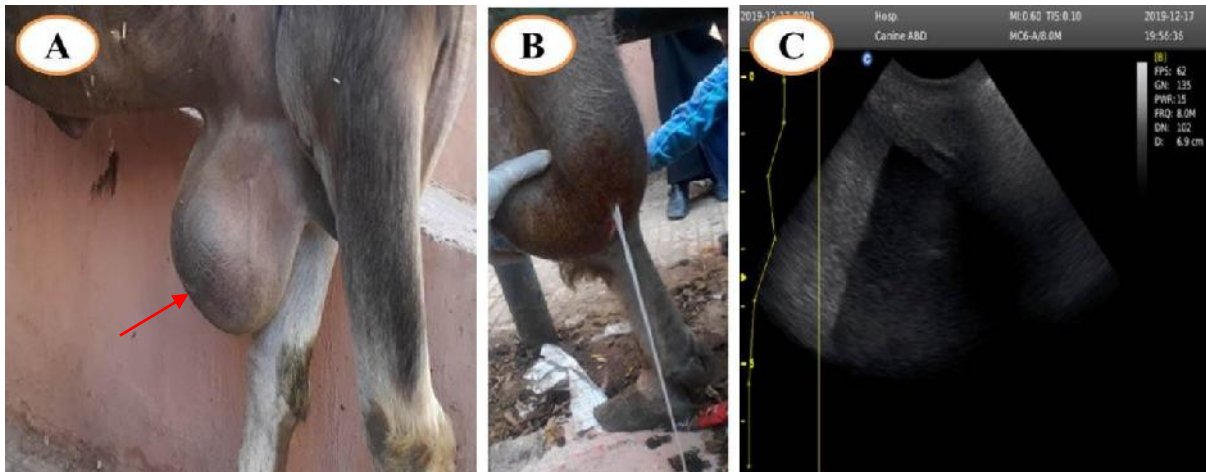

Figure (2): showing ripened abscess at the cranio-ventral abdominal wall in a buffalo (red arrow) (A) with corresponding ultrasonographic examination showing anechoic area (white arrow) (C) represented watery pus (B).

Reducible hernias were diagnosed in twenty-eight animals (17 cattle and 11 buffaloes). Nineteen cases of them at the umbilical region (19 cases), seven cases at the ventral abdominal wall and the other two cases at the lateral abdominal wall. Ultrasonographic appearance of reducible hernia characterized by disruption of the abdominal wall continuity at the site of hernia with transverse and longitudinal intestinal loops within hernial sac with their characteristic peristaltic movement and anechoic, hypoechoic to echogenic contents representing the intestinal contents (Fig. 4).

Irreducible hernias were diagnosed in twenty-one cases (12 cattle and 9 buffalo). Thirteen cases of them at the umbilical region, 4 cases at the ventral abdominal wall and the other 4 cases at the lateral abdominal wall. The distinguishing feature of irreducible hernias was evident anechoic inflammatory exudates; the entire reduced peristaltic movement and the thick hernial sac with echogenic fibrous adhesions between the sac and the abdominal wall (Fig. 5). Recent hematomas were diagnosed in ten cases (5 cattle and 5 buffaloes). Six cases of them at the ventral abdominal wall and four cases at the lateral abdominal wall. Ultrasonographic appearance of recent hematoma revealed anechoic area (blood content) divided by thin echogenic septa into small chambers toward its center (Fig. 6). Depending on the history of

recent trauma and the previous ultrasonographic profile surgical intervention was suspended until complete organization occurred.

Old hematomas were diagnosed in nine animals (4 cattle and 5 buffaloes). Six cases of them at the ventral abdominal wall and three cases at the lateral abdominal wall (3 cases). Ultrasonographic appearance of old hematoma revealed anechoic to hypoechoic appearance which represent blood content with heterogeneous hypoechoic content in distal part of hematoma which represented the clotted blood or revealed anechoic area divided by thick echogenic septa (Fig. 7). Depending on the history of old trauma and the previous ultrasonographic profile the time was suitable for surgical intervention.

4. DISCUSSION

Early and accurate diagnoses of external abdominal wall swellings in farm animals are crucial for successful management in suitable time (McAuliffe, 2004). Ultrasonography provides accurate details regarding the extent and character of the swellings being examined; it is able to distinguish fluid from solid accumulations and to guide fine needle aspiration or biopsies (Cribb and Arroyo, 2018).

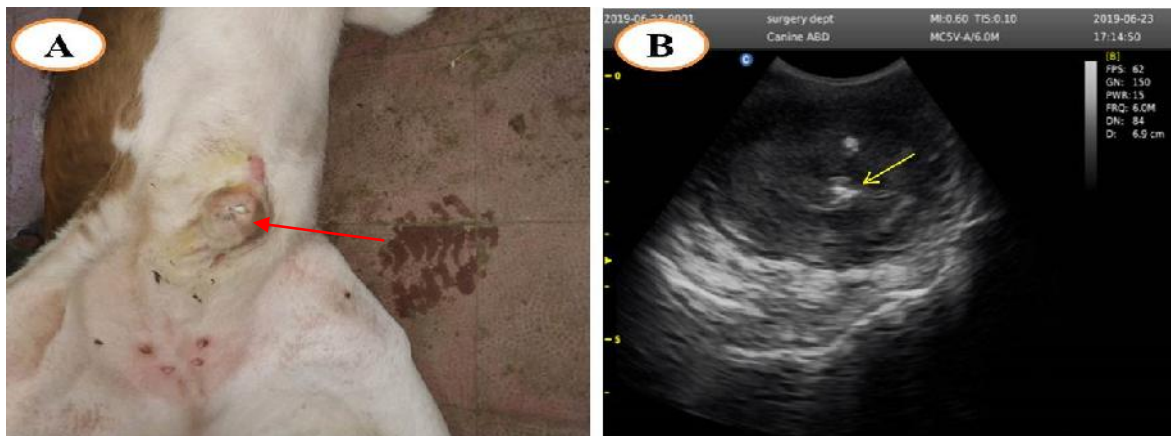

Figure 3 Showed ripened abscess with chronic fibrotic omphalitis (red arrow) (A) with corresponding ultrasonographic examination (B) showing circumscribed structure with mixed echogenicity and hyperechoic band (yellow arrow) with evident acoustic shadowing representing the fibrotic omphalitis.

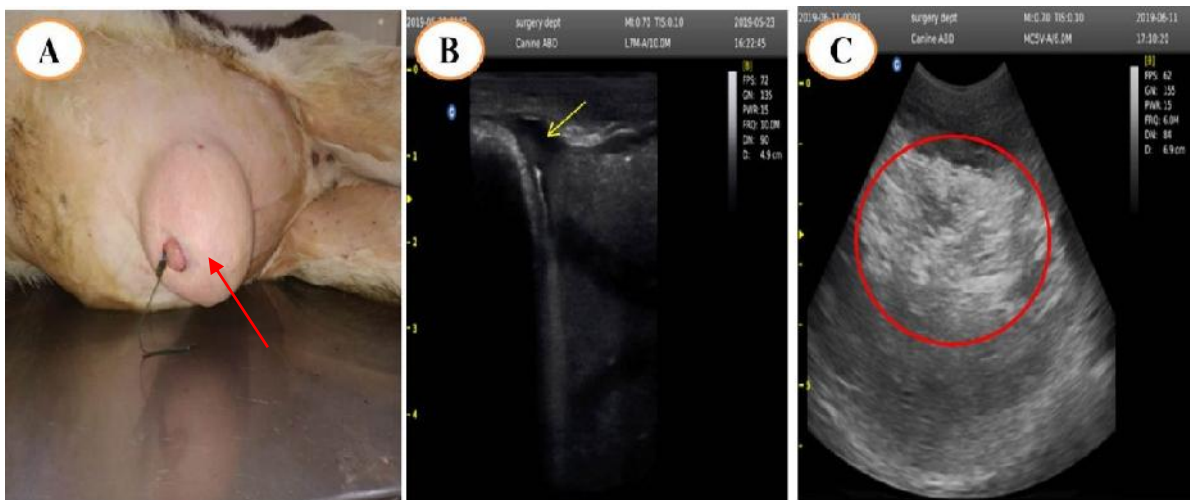


Figure 4 Showed umbilical reducible hernia in cattle calf (red arrow) (A) with corresponding ultrasonographic examination (B&C) revealed anechoic defect in continuity of body wall (yellow arrow) and anechoic, hypoechoic to hyperechoic structure represent intestinal loops and their contents (water, ingesta and gases).

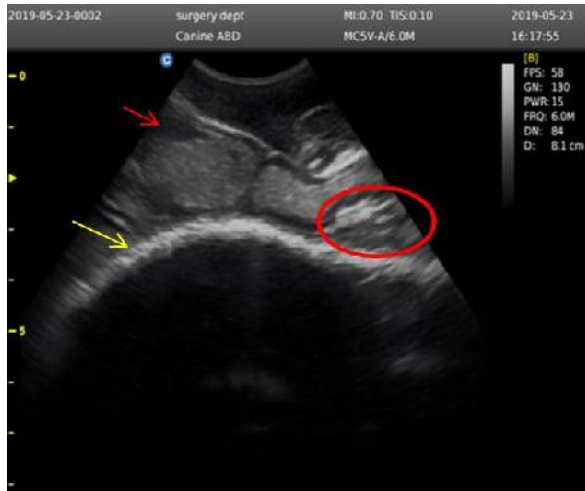


Figure (5): showing ultrasonographic examination of umbilical irreducible hernia revealed evident anechoic inflammatory exudates (red arrow); echogenic fibrous adhesions between the sac and the abdominal wall (red circle) and thick fibrous echogenic hernial sac (yellow arrow).

Diagnostic ultrasonography of swellings allowed differential diagnosis and preoperative planning for surgical interference and provided an accurate prognosis (Abouelnasr et al., 2016). The technique is unique for soft tissue imaging and provides a noninvasive, safe, simple, rapid, dynamic and reliable diagnosis and differential

diagnosis with a variety of different types of external swellings, when physical examinations are inadequate (Buczinski et al., 2010). In the current study, ultrasonographic echogenicity assists the ability to grade maturation stage of the abscess. This result agreed with; Mohamed, and Oikawa (2007) and Abouelnasr et al. (2016) who reported that degree of abscess maturation could not be assessed by palpation alone, especially in buffalo due to thick cutis and leading to misdiagnosis. Ultrasonographic examination of ripened abscess appeared as circumscribed mass with anechoic contents represented watery or creamy pus surrounded by hypoechoic external areas. This result was coincided with Abd El-Galil (2007) and Khalil (2012) in domestic animals and Magda and Abd El-Hakiem (2012) and Abouelnasr et al. (2016) in buffalos. While unripened abscess appeared ultrasonographically as circumscribed structure with mixed echogenicity and some hyperechoic dots represented the unripened foci. These observations agreed with that reported by Baxter G.M. (2004) and Abd El-Galil (2007) in domestic animals and Abouelnasr et al. (2016) in buffalo. Likewise, the result reported by Magda and Abd El-Hakiem (2012); ripened abscess with chronic fibrotic omphalitis appeared ultrasonographically as circumscribed structure with mixed echogenicity and hyperechogenic band with evident acoustic shadowing representing the fibrotic omphalitis.

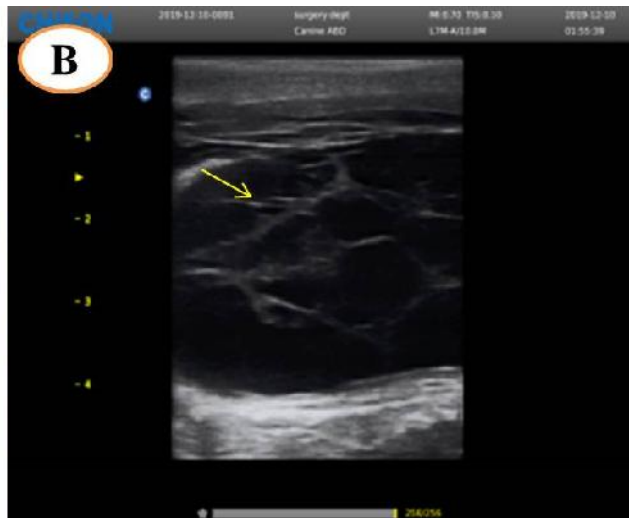


Figure (6) A six months buffalo calves suffered from recent ventral hematoma (red arrow) (A) and corresponding ultrasonographic examination revealed anechoic area (blood) divided by fine hypoechoic septa (yellow arrow) (B).

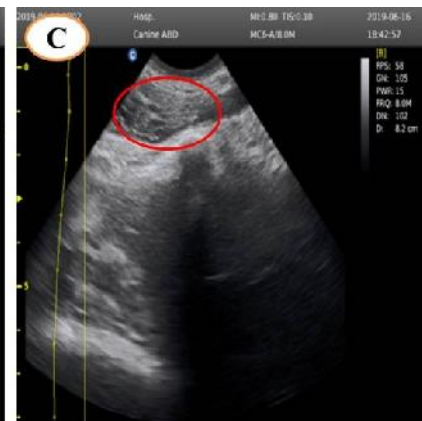
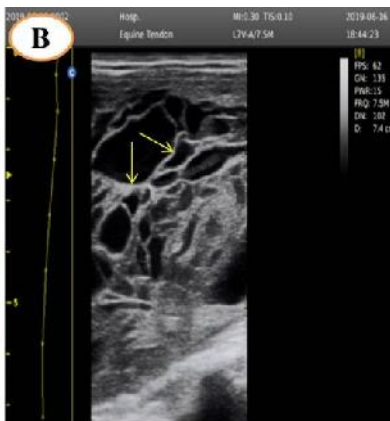

Figure (7) A four months buffalo calves suffered from old ventral hematoma (red arrow) (A) and corresponding ultrasonographic examination revealed anechoic to hypoechoic area divided by thick echogenic septa (yellow arrow) (B) and anechoic to hypoechoic area with heterogeneous hypoechoic content (red circle) (C).

In the present study, the recent hematoma appeared sonographically as anechoic area which attributed to blood content and divided by thin echogenic septa into small chambers toward its center. While, old hematoma appeared with heterogeneous echogenicity and interspersed between thick echogenic septa. Similar findings were asserted by El-Maghraby (2002) in goats, and Abouelnasr et al. (2016) in buffaloes.

Differential diagnosis between abscess and hematoma is echogenicity dependent; the echogenicity of abscess' contents is hypoechoic to anechoic with fine or no hypoechoic septa; while hematomas' contents are more echogenic combined with the presence of some echogenic shreds. Additionally, recent hematomas are differentiated from old organized ones by their fluid content; recent hematomas have hypoechoic to anechoic fluid content that becomes more echogenic with thick septa as they become more organized. This result agreed with that described by El-Maghraby (2002).

In the present study, hernial ring appeared ultrasonographically as anechoic defect in the continuity of echogenic abdominal wall. This ultrasonographic profile is characteristic and diagnostic for hernia in addition to the intestinal peristalsis and the hyperechoic circular fold of omentum. These findings were observed also by Abu-Seida (2002) in calves; El-Maghraby (2002) in goats and Baxter (2004) in ruminants.

The vitality and degree of intestinal peristaltic movement, thickness of the hernial sac and echogenic signals of fibrous adhesion is a differentiating feature between reducible and irreducible hernia. This result was similar to that reported by Mohamed and Oikawa (2007) and Hashefi (2009).

5. CONCLUSION

Ultrasonography is considered to be the most useful, safest diagnostic and prognostic tool in cases of some abdominal wall swelling and add in determine the suitable time for intervention to guarantee rapid complete recovery.

6. REFERENCES

1. Abd El-Galil, A. S., 2007. Stated on surgical affection of the natural body orifices and its related structures in domestic animals. Ph. D. Theses. Fac. Vet. Med., Benha univ.
2. Abouelnasr, K., El-Shafaey, E. S., Mosbah , E., and El-Khodery, S., 2016. Utility of ultrasonography for diagnosis of superficial swellings in buffalo (*Bubalus bubalis*). *Journal of Veterinary Medical Science*, 78(8), 1303-1309.
3. Abu-Seida, A. M., Fouad, K. A., Gohar, H. M., and El-Mahdi, M. M., 2002. Prevalent surgical affections among calves with special references to ultrasonographic examination. Ph.D. Thesis, Fac. Vet. Med., Cairo Univ.
4. Barr, F., & Gaschen, L. (2011). *BSAVA manual of Canine and Feline Ultrasonography*. British Small Animal Veterinary Association
5. Baxter, G.M., 2004. *Hernia / Umbilicus 14,3 in farm animal surgery by fubini, S.L. and Ducharme ,N. G. Saunders, Elsevier(USA)*. 185, 477-484.
6. Buczinski, S., Bourel, C. and Bélanger, A. M., 2010. Ultrasonographic determination of body wall thickness at standing left laparotomy site in dairy cows. *Vet. Rec.* 166, 204–205.
7. Cribb, N. C., and Arroyo, L. G., 2018. Techniques and accuracy of abdominal ultrasound in gastrointestinal diseases of horses and foals. *Veterinary Clinics: Equine Practice*, 34(1), 25-38.
8. El-Maghraby, H.M., 2002. ultrasonographic diagnosis and surgical management of some swelling around the udder in cattle, sheep and goat, *Mansoura, Vet. Med. J.* 123, 59-73.
9. Hashefi, M., 2009. *Ultrasound in the Diagnosis of Non-inflammatory Musculoskeletal Conditions*. *Annals of the New York Academy of Sciences*. 1154, 171-203.
10. Khalil , A.H., 2012. *Diagnostic imaging of the Uro-Genital system in sheep and goat*. M. V. Sc. Thesis. Fac. Vet. Med. Benha Univ.
11. Magda, M. A. and Abd El-Hakiem, M. H., 2012. Ultrasonographic differential diagnosis of superficial swellings in farm animals. *J. Advan. Vet. Res.* 2, 292–298.
12. McAuliffe, S. B., 2004. *Abdominal Ultrasonography of the Foal*. *Clin. Tech. Equi. Pract.* 3, 308–316.
13. Mohamed, T. and Oikawa, S., 2007. Ultrasonographic characteristics of abdominal and thoracic abscesses in cattle and buffaloes. *J. Vet. Med. A Physiol. Pathol. Clin. Med.* 54, 512–517.