

# Magnetic Resonance Spectroscopy in Evaluation of Multiple Sclerosis

Mustafa Al Hassan Abdou Heidar, Iman Soliman Metwally, Tougan Taha

Department of Radio Diagnosis, Faculty of Medicine, Ain Shams University

## ABSTRACT

MS is a diffuse immune-mediated inflammatory disease that evolves over time; it's characterized by the presence of CNS lesions disseminated in space and time. Plaques of inflammatory demyelination within the CNS are the pathologic hallmark of MS. <sup>1</sup>H-MRS is a noninvasive imaging technique that's promising as diagnostic technique for MS as well as a good marker for immune-modulatory therapy response and as a predictor for clinical disability in MS. **Aim of the Study:** To highlight the value of MR spectroscopy in evaluation & monitoring patients with multiple sclerosis and how MR spectroscopy can add valuable information to conventional MR.

**Keywords:** Multiple sclerosis, MR, MS, <sup>1</sup>H-MRS.

## INTRODUCTION

Multiple sclerosis (MS) is a complex autoimmune disease with a heterogeneous presentation and diverse disease course.

Recent studies indicated a rising prevalence of MS in the Middle East, MS affects individuals during the most productive time of their lives, and directly limits their work capacity, leading to major social and economic consequences; The mean age at MS onset is 26.61±7.82 years, With female dominance. With (female: Male) ratios of (2.14:1) <sup>(1)</sup>. Multiple sclerosis (MS) is characterized by loss of motor and sensory function that results from immune-mediated inflammation, demyelination and subsequent axonal damage. MS is one of the most common causes of neurological disability in young adults <sup>(2)</sup>.

Magnetic resonance imaging (MRI) has revolutionized the diagnosis and management of patients with multiple sclerosis (MS). Metrics derived from conventional MRI are now routinely used to detect therapeutic effects and extend clinical observations. Conventional MRI measures have insufficient sensitivity and specificity to reveal the true degree of pathologic changes occurring in MS. T2-weighted and T1-weighted imaging cannot distinguish between inflammation, edema, demyelination, Wallerian degeneration, and axonal loss.

Nonconventional MRI techniques are now emerging and proving to be more related with the most disabling features of MS. Advanced MRI techniques provide a better understanding of the pathologic processes that most likely are related to disease activity and clinical progression. Such metrics are able to reveal a range of tissue changes that include demyelination, axonal loss, iron deposition, and neurodegeneration and they provide the evidence that important occult pathology is occurring in the normal appearing white and gray matter <sup>(3)</sup>.

<sup>1</sup>H-MRS permits the in-vivo study of certain cerebral metabolites thus it offers the possibility of greater pathological specificity in lesional areas of MS as well as in normal appearing white matter and even in the gray matter <sup>(4)</sup>.

The <sup>1</sup>H-MRSI sequence allows an in- vivo evaluation of different cerebral metabolites associated with cellular and functional processes. Among the metabolites determined with this technique are the following: (1) N-acetylaspartate (NAA), which is synthesized in the neuronal mitochondria and is considered a marker of neuronal body and axonal integrity depending on transient (mitochondrial dysfunction) or permanent reduction of NAA (irreversible neuronal and/or axonal injury) <sup>(5)</sup>.

The extended use of <sup>1</sup>H-MRS in clinical settings has been hampered by its technical demands. However, because of its ability to assist in simultaneous evaluation of different events involved in MS pathogenesis that cannot be determined by cMRI, <sup>1</sup>H-MRS could become an important tool to decipher the sequence of the immunologic cascade and to evaluate the response to new disease-modifying agents, including neuroprotectants. The use of the abovementioned nonconventional MRI biomarkers could lead to a better understanding of different aspects of the disease process and play a key role in early diagnosis and prognosis of the disease, assessment of therapeutic response, and the understanding of different MS phenotypes <sup>(6)</sup>.

The study was approved by the Ethics Board of Ain Shams University.

## PATHOGENESIS OF MULTIPLE SCLEROSIS

Multiple sclerosis (MS) is an inflammatory demyelinating CNS disease frequently starting in young adulthood. It expresses itself in four clinical

forms: relapsing remitting MS (RRMS), secondary progressive MS (SPMS), primary progressive MS (PPMS), and progressive relapsing MS (PRMS). Approximately 87% of patients present with RRMS, characterized by acute attacks (relapses) followed by partial or full recovery (remission) <sup>(7)</sup>.

### Pathologic characterization of MS lesions

Plaques of inflammatory demyelination within the CNS are the pathologic hallmark of MS <sup>(8)</sup>. Frohman *et al.* & Greenfield *et al.* <sup>(8,9)</sup> had agreed that myelin destruction is an essential element of the plaque. Yet the MS plaque is not simply a static entity of myelin loss in isolation; rather, lesions are comprised of a wide variation of immunologic and pathologic features. These features have been categorized in an effort to understand the neural-immune mechanisms underlying MS. Constructing a framework around which myelin loss and neuronal/axonal injury occur entails a close examination of the cellular and molecular constituents, timing of damage, and repair processes. Thus, the various features of plaques provide a platform on which hypotheses regarding pathogenic mechanisms underlying MS have been formulated for over a century. Traditionally, MS plaque classification has been based on temporal progression, or stages, of inflammatory destruction. Accordingly, acute, chronic active and chronic silent lesions are thought to occur along a continuous timeline, eventually producing the scarred and hardened areas within the CNS that can be appreciated grossly. The acute MS plaque represents the earliest stage of lesion formation. It is typified by robust inflammatory infiltration combined with demyelination distributed throughout the lesion <sup>(8,9)</sup>. Typical features of the acute plaque include ill-defined margins of myelin loss, infiltration of immune cells and parenchymal edema <sup>(8)</sup>.

The degree of oligodendrocyte loss within active lesions can be variable. In spite of the relative degree of axonal sparing, axonal injury can be extensive in acute lesions. Glial reactivity throughout the lesion is noted, particularly hypertrophic astrocytes. However, dense glial scarring is not typical of the acute plaque.

The chronic plaque is characterized by a region of hypocellularity with loss of myelin and glial scarring. On gross examination of post-mortem tissue, the hardened and discolored appearance of chronic plaques is often appreciable in frequently targeted areas of the CNS (e.g. the corpus callosum). Histologically, the lesion borders of chronic plaques are more distinct than those of acute plaques. A division into two forms of

chronic plaque is made to signify temporal evolution from active destruction at the edge of the lesion (chronic active plaque) to an entirely “burned out” lesion devoid of active inflammatory destruction (chronic silent plaque). In chronic active lesions, inflammation continues along the outer border with the histologic appearance comparable to acute lesions <sup>(9)</sup>.

Four distinct patterns of immunologic and pathologic features of actively demyelinating lesions were discerned, patterns II and III being the most common:

- Pattern I is characterized by the predominance of T cell and macrophage inflammatory content.
- Pattern II is characterized by T cell and macrophage infiltration, along with accentuated immunoglobulin deposition and myelin degradation products within macrophages.
- Pattern III is distinguished by pronounced oligodendrocyte loss at the active edge of the lesion and preferential loss of myelin-associated glycoprotein (MAG).
- Pattern IV is characterized by oligodendrocyte dystrophy and the absence of remyelination or shadow plaques.

Importantly, these distinct patterns were consistently observed within samples from the same patient, but varied between patients. The authors, based on the results from one open-label clinical trial in patients who had brain biopsies, hypothesized that deficit recovery after plasma exchange was indicative of the individual pattern of MS pathology. Plasma exchange was effective in patients with biopsy-proven pattern II (with prominent antibody and complement involvement) but not for patients with pattern I or III lesions <sup>(10)</sup>.

### Normal appearing white matter

There has been a long-standing interest in early white matter changes in MS, with some of the earliest studies on myelin examining tissue outside of plaque regions that appears grossly unaffected. More recently, investigation into normal appearing white matter (NAWM) defined on conventional MRI sequences has been explored extensively using a variety of novel neuro-imaging techniques that show abnormalities in these areas suggestive of decreased myelin integrity and diminished axonal density within non-lesional regions <sup>(11)</sup>.

Histo-pathologic examinations of NAWM in patients with MS also support the concept that areas outside of plaques have immuno-pathologic changes.

Microglial activation, T cell infiltration and perivascular cuffing have been reported in NAWM<sup>(12)</sup>.

### Gray matter involvement

Almost all of the gray matter nuclei within the CNS can be affected, as observed in a cohort of mostly progressive MS patients, but out of several regions of the CNS, including motor cortex, the spinal cord and cerebellum are particularly vulnerable, resulting in demyelination in up to 28.8% of the gray matter on average<sup>(13)</sup>. Purely cortical gray matter lesions have also been described as lacking complement deposition and blood-brain barrier breakdown<sup>(14)</sup>. Whether gray matter plaques arise from distinct immunologic mechanisms is unclear at this time. In an attempt to more carefully evaluate the processes involved, cortical lesions have been separated into several categories based on the depth of penetration from the surface into the brain.

Type I lesions include discernable injury to both white and gray matter; Type II lesions have perivascular areas of demyelination isolated to the cortex; and Type III lesions demonstrate cortical demyelination below the pial surface that often cover several gyri and stop at cortical layers three or four<sup>(15)</sup>. Type III and IV lesions are the most extensive and difficult to visualize. Although scarce inflammatory cells are found within these lesions, the meninges overlying them contain inflammatory cells that collect in structures resembling ectopic B-cell follicles. In support of a role for lymphoid neo-genesis in the pathogenesis of these lesions is that patients with ectopic B-cell follicles (41% of secondary progressive MS patients) had a more rapid disease progression<sup>(16)</sup>.

Lesions type:

Type 1 lesions (A) extend through both white and gray matter.

Type 2 lesions (B) are intracortical, having no contact with white matter or with the surface of the brain.

Type 3 lesions (C) extend inward from the surface of the brain.

Type 4 lesions (D) extend through the whole width of the cortex without reaching into white matter. A small area of probable remyelination is observed (arrowhead)<sup>(17)</sup>.

### Prevalence of MS in Egypt

In Egypt, an observational, retrospective study on 1,581 patients was done in 2016 by *Hamdy et al.*, showed that there's a rising prevalence of MS in the Middle East, MS affects individuals during the most productive time of their lives, and directly limits their work capacity, leading to major social and economic consequences; The mean age at MS onset is 26.61±7.82

years, With female dominance. With (female: Male) ratios of (2.14:1)<sup>(1)</sup>.

### DIAGNOSIS OF MULTIPLE SCLEROSIS

The diagnosis of MS is primarily clinical and relies on the demonstration of symptoms and signs attributable to whitematter lesions that are dissemination in time and space, along with the exclusion of other condition that may mimic MS.

There is no single laboratory test diagnostic for MS; however, several tests may support the clinical diagnosis as CSF analysis that shows increase in immunoglobulin concentrations and 2 or more oligoclonal bands (OCBs) in more than 90% of the patients. Delayed latencies of the visual, somatosensory and auditory evoked potentials on electrophysiological studies, as well as prolonged central motor conduction times, are characteristic of demyelination, and may point to clinically silent lesions. Blood tests are usually used to rule out other diseases which can mimic MS<sup>(18)</sup>.

### Diagnostic criteria of MS

All existing diagnostic criteria for RRMS, including those of Schumacher *et al.* and Poser *et al.*<sup>(19)</sup> as well as McDonald *et al.*<sup>(20)</sup>, require two or more distinct events separated in time (generally by more than a month) in addition to involvement of at least two distinct areas of the CNS (the so-called criteria of dissemination in time and space).

**Poser's criteria for the diagnosis of multiple sclerosis (MS)<sup>(19)</sup>.**

#### Clinically definite MS (CDMS):

- 1) 2 Attacks + 2 lesions on neurologic examination
- 2) 2 Attacks + 1 lesion on examination + 1 paraclinical lesion

#### Laboratory-supported definite MS (LSDMS):

- 1) 2 Attacks + 1 lesion on examination *or* 1 paraclinical lesion + abnormal CSF.
- 2) 1 Attack + 2 lesions on neurologic examination + abnormal CSF.
- 3) 1 Attack + 1 lesion on examination + 1 paraclinical lesion + abnormal CSF.

#### Clinically probable MS

- 1) 2 Attacks + 1 lesion on examination.
- 2) 1 Attack + 2 lesions on neurologic examination.
- 3) 1 Attack + 1 lesion on neurologic examination + 1 paraclinical lesion.

#### Laboratory-supported probable MS

- 1) 2 Attacks + abnormal CSF.
- Where the two attacks must involve different parts of the CNS, must be separated by a period of at

least one month, and must each last a minimum of 24 hours.

- Abnormal CSF consists of demonstration of IgG oligoclonal bands in CSF or increased CNS synthesis of IgG, oligoclonal bands must not be present in the patient's serum, and the serum IgG level must be normal. This assumes that other conditions causing

CSF changes, such as syphilis, subacute sclerosingpanencephalitis, sarcoidosis, collagen vascular disease, and similar disorders, have been ruled out.

- Paraclinical lesions include lesions detected by MRI or evoked potentials<sup>(19)</sup>.

**Table 1: The 2010 McDonald Criteria for Diagnosis of MS<sup>(20)</sup>**

Clinical presentation	Additional Data needed for MS diagnosis
≥ 2 attacks + objective clinical evidence of ≥ 2 lesions or objective clinical evidence of 1 lesion with reasonable historical evidence of a prior attack.	<ul style="list-style-type: none"> <li>None</li> </ul> <p>No additional tests are required. However, it is desirable that any diagnosis of MS be made with access to imaging based on these Criteria. If imaging or other tests (for instance, CSF) are undertaken and are negative, extreme caution needs to be taken before making a diagnosis of MS, and alternative diagnoses must be considered. There must be no better explanation for the clinical presentation, and objective evidence must be present to support a diagnosis of MS.</p>
≥ 2 attacks + objective clinical evidence of 1 lesion.	<ul style="list-style-type: none"> <li>Dissemination in space demonstrated by:                             <ul style="list-style-type: none"> <li>≥ 1 T2 lesion in at least 2 of 4 MS-typical regions of the CNS (periventricular, juxtacortical, infratentorial or spinal cord)</li> </ul> </li> <li>Or Await a further clinical attack implicating a different CNS site.</li> </ul>
1 attack + objective clinical evidence of ≥ 2 lesions	<ul style="list-style-type: none"> <li><b>Dissemination in time, demonstrated by:</b> <ul style="list-style-type: none"> <li>➤ Simultaneous presence of asymptomatic gadolinium-enhancing and non-enhancing lesions at any time</li> </ul> </li> <li>Or A new T2 and/or gadolinium-enhancing lesion(s) on follow-up MRI, irrespective of its timing with reference to a baseline scan.</li> <li>Or Await a second clinical attack</li> </ul>
1 attack + objective clinical evidence of 1 lesion (clinically isolated syndrome)	<ul style="list-style-type: none"> <li><b>Dissemination in space and time, demonstrated by:</b> <ul style="list-style-type: none"> <li>➤ <b>For Dissemination in space:</b> <ul style="list-style-type: none"> <li>❖ ≥ 1 T2 lesion in at least 2 of 4 MS-typical regions of the CNS (periventricular, juxtacortical, infratentorial, or spinal cord).</li> </ul> </li> </ul> </li> <li>Or                             <ul style="list-style-type: none"> <li>❖ Await a second clinical attack implicating a different CNS site.</li> <li>➤ <b>For Dissemination in time:</b> <ul style="list-style-type: none"> <li>❖ Simultaneous presence of asymptomatic gadolinium-enhancing and non-enhancing lesions at any time</li> </ul> </li> </ul> </li> <li>Or A new T2 and/or gadolinium-enhancing lesion(s) on follow-up MRI, irrespective of its timing with reference to a baseline scan;</li> <li>Or Await a second clinical attack</li> </ul>
Insidious neurologic progression suggestive of MS (PPMS)	<ul style="list-style-type: none"> <li>1 year of disease progression (retrospectively or prospectively determined)</li> <li>2 of 3 of the following criteria:                             <ol style="list-style-type: none"> <li>Evidence for DIS in the brain based on ≥ 1 T2 lesions in the MS-characteristic (periventricular, juxtacortical, or infratentorial) regions</li> <li>Evidence for DIS in the spinal cord based on ≥ 2 T2 lesions in the cord</li> <li>Positive CSF (isoelectric focusing evidence of oligoclonal bands and/or elevated IgG index)</li> </ol> </li> </ul>

## ROLE OF <sup>1</sup>H MRS IN EVALUATION OF MULTIPLE SCLEROSIS

Conventional magnetic resonance (c-MR) imaging techniques, such as T2-weighted sequences and gadolinium-enhanced T1-weighted sequences, are highly sensitive for detecting MS plaques and can provide quantitative assessment of inflammatory activity and lesion load. These conventional MR imaging-derived metrics have become established as the most important paraclinical tool in the diagnosis of MS<sup>(21)</sup>. Proton MR spectroscopy (<sup>1</sup>H-MRS) is the first nonconventional MR technique used in MS and has proved to be particularly informative by revealing metabolic abnormalities related to the 2 primary pathologic processes of the disease; These are active inflammatory demyelination and neuronal/axonal injury in both T2-visible lesions and in brain regions that are not associated with evident structural abnormalities on conventional MR imaging, the so-called normal-appearing brain tissue (NABT)<sup>(22)</sup>.

<sup>1</sup>H MRS of water of the brain in patients has provided a potentially useful quantitative tool to assess and determine the altered composition of gray matter and white matter lesions when compared with normal brain tissue as well to assess the evolution of the plaques. When examining the plaques, the acute stage is associated with elevated peaks of LA, Cr, glutamate and Cho and slight increase in ml.

MS is a diffuse, dynamic disease that evolves over time. Thus, to summarize the <sup>1</sup>H-MRS features of the brain in this condition; it is useful to divide the metabolic patterns into 2 groups:

- Those observed in T2-visible lesions, including both active and chronic lesions.
- Those in normal appearing brain tissue (NABT), which is known to be affected in MS.

<sup>1</sup>H-MRS is particularly useful to provide evidence of neurodegeneration even from the earliest stages of the disease based on the resonance intensity of NAA, a marker of neuronal integrity, and other metabolites, such as choline containing compounds (Cho) and myo-inositol (mIns), which are affected by damage and repair of non-neuronal brain cells<sup>(22)</sup>.

This clinical-radiological paradox may be partially explained by the following several limitations of conventional MR imaging:

1. Limited specificity for the various pathologic substrates of MS, which contribute differently to the development of permanent disability.
2. Inability to quantify the extent of damage in normal-appearing white matter.

3. Inability to detect and quantify the extent of gray matter damage.
4. Variability in the clinical expression of MS plaques in different anatomic locations (e.g., the spinal cord and optic nerve).
5. Inability to assess the effectiveness of reparative mechanisms in MS, such as cortical adaptive reorganization.

Magnetic resonance spectroscopy (MRS) has contributed to understanding the pathogenesis and natural history of MS as the metabolic abnormalities in patients with MS are not restricted to lesion sites but are more diffuse in nature<sup>(5)</sup>. On the other hand, <sup>1</sup>H-MRS has an important limitation in terms of acquisition time and size of the volume of interest because of the low sensitivity of the technique. To obtain a useful spectrum in a reasonable time, the minimum volume of interest is typically about 1 cm<sup>3</sup> but most MS lesions are smaller, and this can lead to partial volume effects that should be taken into account when interpreting the results. Absolute quantitation is highly desirable but not easy; therefore, relative quantitation is generally used in clinical practice. The most common relative method is the use of ratios between metabolites, with NAA usually expressed relative to creatine/phosphocreatine (Cr), assuming that this metabolite is kept constant. Although this approach may be doubtful in MS, where the Cr concentration may be affected by MS pathology, NAA/Cr ratio is a practical compromise to acquiring surrogate measures of neuroaxonal integrity<sup>(22)</sup>.

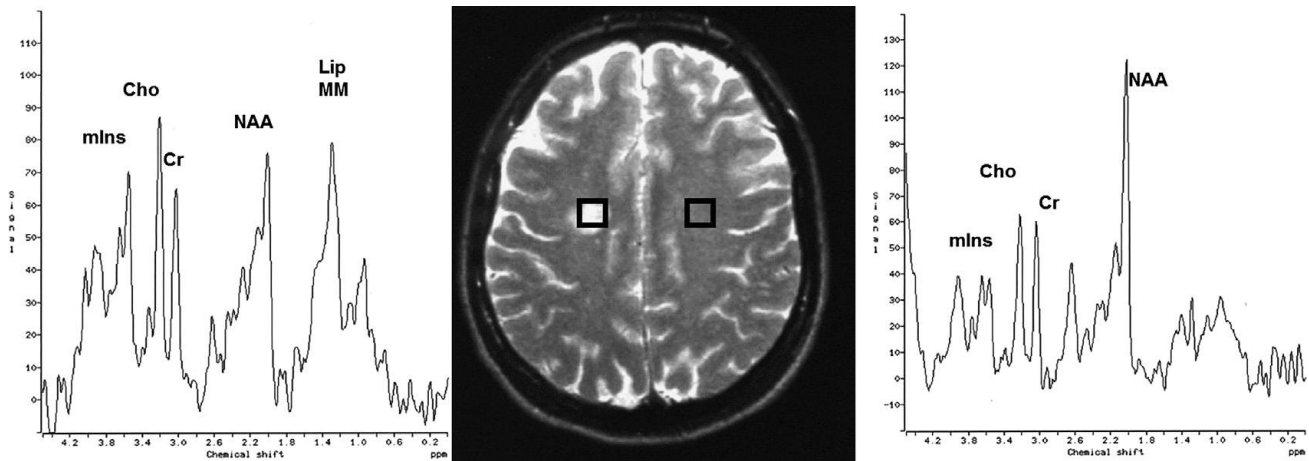
### The value of <sup>1</sup>H-MRS in focal brain lesions:

The presence of CNS lesions disseminated in space and time is one of the main features of MS, and the aim of the first <sup>1</sup>H-MRS studies was characterization of MS lesions in their different stages. This initial NAA decrease may persist over time, indicating irreversible neuroaxonal injury, or show partial recovery starting a few weeks after the onset of lesion development and continuing for several months. The discordant relation of NAA with markers of structural damage and its partial recovery over time after an acute inflammatory lesion in the brain and cord, suggest that NAA might have the unique property of reflecting neuronal energy metabolism<sup>(5)</sup>. The behavior of Cr has a particular relevance in MS plaques, Cr is a metabolite present in both neurons and glial cells, with higher concentrations in glia than neurons. Cr, which commonly remains stable, can show significant increases in some plaques or decreases. These

changes may be related to varying amounts of neuroaxonal loss oligodendroglial loss, and astrocytic proliferation<sup>(23)</sup>. Short echo time spectra provide evidence of transient increases in visible lipids in some lesions, probably released during myelin breakdown. These observations suggest that demyelination can occur months before acute inflammatory changes become evident. Other nonconventional MR techniques, such as magnetization transfer imaging, diffusion, and dynamic susceptibility weighted sequences have also shown abnormalities in this pre-lesional stage, further supporting the presence of subtle progressive alterations in tissue integrity before focal leakage of the blood-brain barrier as part of plaque formation in MS<sup>(24)</sup>. Application of metabolite-nulling techniques that differentiate between macromolecular resonances and metabolites have shown elevated macromolecule resonances in the range of 0.9 to 1.3 ppm in acute lesions, whereas in chronic lesions, the values are similar to those of healthy controls. These macromolecules do not fit the spectral pattern of lipids,

and may be interpreted as markers of myelin fragments<sup>(22)</sup>. **(Fig. 1)**

The longitudinal study demonstrates lactate disappearance at 3 months, persistent low levels of NAA, a progressive Cho increase during the first weeks followed by partial recovery, and relatively stable Cr at all time points<sup>(22)</sup>. Acute MS plaques usually evolve to chronic irreversible plaques (with varying degrees of neuronal/ axonal loss) as inflammatory activity abates, edema resolves, and reparative mechanisms, such as remyelination, become active. These pathologic changes are reflected on conventional MR imaging, which usually shows cessation of contrast uptake after several weeks, associated with a T2 lesion size decrease. A percentage of active lesions become irreversibly hypointense on T1-weighted imaging (chronic black holes), which correlates pathologically with permanent demyelination and severe axonal loss. These pathologic changes also can be assessed using <sup>1</sup>H-MRS as changes in the spectral pattern of the lesions<sup>(23)</sup>.



**Figure 1:** Stimulated echo acquisition mode spectra recorded at an echo time of 20 ms obtained from an acute MS lesion (left) and the contralateral NAWM (right). The lesion spectrum shows a moderate decrease in NAA, and an increase in Cho and mIns. There is also elevation of the lipid peak (Lip) and macromolecules (MM).

**Table 2:** Summary of the changes in the main metabolites of the proton magnetic resonance spectrum that may be present in multiple sclerosis brain lesions:<sup>(22)</sup>

Metabolite	Acute Stage	Evolution	Chronic
Macromolecules	↑	Tendency to ↓	Not present
Lipid	↑	Tendency to ↓	↓ or not present
Lactate	↑	Tendency to ↓	Not present
N-acetylaspartate	↓	Further ↓, Partial ↑	↓
Glutamic/Glutamine	↑	Tendency to ↓	
Creatine/Phosphocreatine	↑, Stable or ↓	Further ↑, Partial ↓	↑
Choline compounds	↑	Further ↑, Partial ↓	↑
Myo-inositol	↑	Stable or further ↑	↑

Furthermore, MRS was supposed to discriminate between MS plaques and other white matter lesions. A study by Kapeller and colleagues was performed in 2005 to evaluate the metabolite pattern in MS plaques and other white matter lesions, it included 15 MS patients, 14 elderly individuals with WML and 16 controls were investigated by conventional MRI and short echo quantitative <sup>1</sup>H-MRS, they concluded that MS plaques and WML showed a significant decrease in the concentration of t-NAA confirming pre-described histopathological evidence of neuronal damage. In addition MS plaques were significantly elevated in their *myo*-Ins concentration. This is most likely due to the development of astrogliosis in MS. Yet a larger sample of patients is needed to test the diagnostic value of increased *myo*-Ins for differentiation between MS plaques and WML<sup>(25)</sup>.

**<sup>1</sup>H-MRS of normal appearing brain tissue (NABT):**

NABT can be furtherly classified into Normal Appearing White Matter (NAWM) and Normal Appearing Gray Matter (NAGM). Diffuse global injury outside the focal MS lesions in NABT is also found in the brains of patients with MS. These abnormalities include diffuse astrocytic hyperplasia, patchy edema, and perivascular cellular infiltration, as well as axonal damage, myelin loss and microscopic focal lesions. There is clear evidence of evolving gray matter volume loss from the first clinical event in relapse onset MS. Dalton and colleagues observed progressive gray matter but not white matter volume loss in people who developed MS within three years, with only a minority of gray matter atrophy seemingly related to white matter lesion<sup>(26)</sup>.

**Gray matter involvement in multiple sclerosis:**

By the start of the 21<sup>st</sup> century, the focus within MS research slowly shifted back from WM to GM. In 2003, when new immune-histochemical staining techniques that improved the detection of gray matter damage in post mortem specimens had become available, the presence and extent of gray matter demyelination was described in detail and pathophysiological processes causing gray matter damage, as well as its visualization with modern magnetic resonance imaging (MRI) techniques, became vital issues in MS research.

Immuno-histochemical analysis did not only reveal extensive demyelination of the neocortex, but also of archicortical structures (such as the hippocampus) and of deep gray matter structures like the thalamus, putamen, globus pallidus, caudate, claustrum,

hypothalamus, substantia nigra, amygdala and of the cerebellum and spinal cord<sup>(27)</sup>.

Unfortunately, currently available MR imaging techniques are not optimal for detecting cortical lesions because of poor contrast resolution between normal-appearing gray matter (NAGM) and the plaques in question, and because of the partial volume effects of the subarachnoid spaces and cerebrospinal fluid surrounding the cortex. New MR techniques such as double inversion recovery (DIR) sequences, which selectively suppress the white matter signal and cerebrospinal fluid and phase sensitive inversion recovery sequences, which generate a high signal-to-noise ratio image, significantly increase the sensitivity for detecting cortical MS lesions, although most purely intracortical lesions remain invisible. <sup>1</sup>H-MRS offers detection of diffuse gray matter involvement, and several studies have demonstrated an NAA decrease in the cortical and subcortical NAGM of patients with MS<sup>(28)</sup>.

<sup>1</sup>H-MRS of cortical gray matter is technically challenging because of its proximity to CSF and partial volume averaging from white matter. In addition, many of the MRS studies that employ outer volume suppression bands for minimizing contributions from non-neural tissues make it difficult to acquire MRS from the cortical gray matter that is close to outer surface of the brain. In spite of these limitations, MRS studies of cortical gray matter have been reported by a few groups. For example, Sharma *et al.*, by combining a double inversion recovery sequence, in which both CSF and white matter were suppressed, demonstrated abnormalities in the cortical gray matter close to the midline fissure in MS patients using <sup>1</sup>H MRS imaging (Multi-voxel MRS). By combining <sup>1</sup>H MRS imaging with image segmentation, this study has minimized contributions from white matter and CSF to the VOI and showed in 52 RRMS patients marked lipid peaks arising from the normal appearing gray matter, consistent with the presence of active demyelination/remyelination. However, no significant changes in major metabolite concentrations were observed compared to controls, suggesting no significant neuronal loss<sup>(29)</sup>.

The lack of significant changes of metabolites in cortical gray matter is consistent with another more recent report. Using short TE MRSI in 16 RRMS patients with short disease duration (mean disease duration of 1.8 years; range 0.6-2.8 years), Kapellar *et al.*<sup>(25)</sup> reported lower NAA and mI in the cortical gray matter relative to controls. The reduced NAA in cortical gray matter suggested mild, but widespread,

neuronal dysfunction or loss early in the course of the disease<sup>(25)</sup>.

The levels of metabolites in the very early stage of the disease appear to be dependent on lesion activity. In CIS suggestive of MS, Au Duong *et al.*<sup>(30)</sup> reported that the metabolite levels in gray matter are associated with the presence of enhancing lesions; when absent, there was no statistically significant difference in the GM metabolite levels between patients and controls; when present, a relative decrease in NAA level and an increase in Cho level were observed. This suggests that metabolite alterations seen in the gray matter in the early phase of the disease may be secondary to the inflammatory process, rather than to 'primary' neuronal dysfunction. MS also affects deep gray matter structures<sup>(30)</sup>.

#### **MRS in normal appearing white matter (NAWM):**

The NAA decreases found in the normal-appearing white matter (NAWM) are usually attributed to axonal damage and, although can be present at early disease stages, are more pronounced in advanced disease stages<sup>(31)</sup>.

The extent of this NAA reduction decreases with the distance from the core of a lesion and is consistent with the notion that the diffuse changes are at least in part related to dying back of axons transected within plaques. However, decreased levels of NAA also occur without obvious relation to T2-visible lesions<sup>(32)</sup>.

It must be stressed that, in lesions & NAWM regions, the presence of intense gliosis may also cause increases in mI and Cr. The latter should be taken into account when decreases in NAA are reported as ratio to Cr. Glutamate also may be increased in NAWM, suggesting a role for excitotoxicity.

In addition, <sup>1</sup>H MRS data had sometime shown abnormal signals from lipids or Cho. in regions that only later develop new T2-hyperintense lesions. This interesting finding adds to previous MR data suggesting that focal myelin pathology may antedate the development of acute, severe inflammation<sup>(22)</sup>.

In a study done in 2017 by Sun and colleagues in China, it demonstrated that metabolic changes in the NAWM are associated with demyelination process within MS patients. MRS could provide important information in metabolic changes in the NAWM. The study showed that NAA/Cr ratio is significantly reduced in the NAWM of patients with MS compared to healthy controls, also Cho/NAA ratio significantly increased in the NAWM within MS patients. Moreover, the study demonstrated that the abnormal metabolic changes in the frontal, parietal,

and parietal-occipital NAWM in the patients group, separately.

Furthermore, the NAWM region closest to the parietal lobe was found to have the highest degree for NAA/Cr alterations. The multivoxel MRS imaging approach has the potential to play a critical role in diagnosing of MS and assessing the therapeutic efficacy of MS patients<sup>(31)</sup>.

#### **CONCLUSION**

- <sup>1</sup>H-MRS has a significant role in solving the clinical-radiological paradox in MS with conventional MR techniques, since it proved the subtle changes in NABT including NAWM & NAGM in MS before appearance of lesions in conventional MRI.
- In- vivo <sup>1</sup>H MRS has a promising opportunity to have an important role as a biomarker for MS diagnosis, as well as prediction for disease activity and treatment follow up. Also studies revealed that NAA can be a good potential marker for neuronal function in NAWM, NAGM in patients with different clinical forms of MS. Thus with the emerging improvements in MRS imaging providing shorter acquisition times will continue on providing a more pivotal role for <sup>1</sup>H MRS in diagnosis and follow up of MS.

#### **REFERENCES**

1. **Hamdy SM, Abdel-Naseer M, Shalaby NM, Alaa N Elmazny, AlNemr AA, Hassan A, Hegazy MI, Mourad HS, Kishk NA, Nada MA, Abdelalim A, Fouad AM and Shehata HS (2017):** Characteristics and predictors of progression in an Egyptian multiple sclerosis cohort: A multicenter registry study. *Neuropsychiatric Disease and Treatment*, 13 ; 1895–1903.
2. **Karussis D (2014):** The diagnosis of multiple sclerosis and the various related demyelinating syndromes: a critical review. *Journal of autoimmunity*, 48-49:134-42.
3. **Poloni G, Minagar A, Haacke EM, Zivadinov R (2011):** Recent Developments in Imaging of Multiple Sclerosis. *Neurologist*, 17 (4) : 185–204
4. **Narayana PA(2005):** Magnetic resonance spectroscopy in the monitoring of multiple sclerosis. *Journal of Neuroimaging*, 15(4) :46S-57S.
5. **Ciccarelli O, Barkhof F, Bodini B et al. (2014):** Pathogenesis of multiple sclerosis: insights from molecular and metabolic Imaging. *Lancet Neurology*, 13:807–822.
6. **Comabella M and Montalban X (2014):** Body fluid biomarkers in multiple sclerosis. **Lancet Neurology**, **13:113–126**



7. **Weiner HL A (2008):** shift from adaptive to innate immunity: a potential mechanism of disease progression in multiple sclerosis. *Journal of Neurology*, 255, 3-11.
8. **Frohman EM, Racke MK, Raine CS (2006):** Multiple sclerosis; the plaque and its pathogenesis. *The New England Journal of Medicine*, 354:942.
9. **Greenfieldn JG, Love S, Louism DN *et al.* (2008):** Greenfield's neuropathology. Hodder Arnold; 2008
10. **Keegan M, Konig F, McClelland R *et al.* (2005):** Relation between humoral pathological changes in multiple sclerosis and response to therapeutic plasma exchange. *Lancet*, 366:579.
11. **Zivadinov R, Stosic M, Cox JL *et al.* (2008):** The place of conventional MRI and newly emerging MRI techniques in monitoring different aspects of treatment outcome. *Journal of Neurology*, 255 (1): 61.
12. **Allen IV, McQuaid S, Mirakhur M *et al.* (2001):** Pathological abnormalities in the normal-appearing white matter in multiple sclerosis. *Neurological Sciences*, 22:141.
13. **Gilmore CP, Donaldson I, Bo L *et al.* (2009):** Regional variations in the extent and pattern of grey matter demyelination in multiple sclerosis: a comparison between the cerebral cortex, cerebellar cortex, deep grey matter nuclei and the spinal cord. *Journal of Neurology, Neurosurgery, and Psychiatry*, 80:182.
14. **Van Horssen J, Brink BP, de Vries HE *et al.* (2007):** The blood-brain barrier in cortical multiple sclerosis lesions. *Journal of Neuropathology & Experimental Neurology*, 66:321.
15. **Peterson JW, Bo L, Mork S *et al.* (2001):** Transected neurites, apoptotic neurons, and reduced inflammation in cortical multiple sclerosis lesions. *Annals of Neurology*, 50:389.
16. **Magliozzi R, Howell O, Vora A, Serafini B, Nicholas R, Puopolo M, Reynolds R and Aloisi, F (2007):** Meningeal B-cell follicles in secondary progressive multiple sclerosis associate with early onset of disease and severe cortical pathology. *Brain*, 130, 1089- 1104.
17. **Bo L, Vedeler CA, Nyland HI, Trapp BD, Mørk SJ (2003):** Subpial demyelination in the cerebral cortex of multiple sclerosis patients. *Journal of Neuropathology and Experimental Neurology*, 62; 723-732.
18. **Miller AE and Coyle PK** Clinical features of multiple.Sclerosis.Continuum. Lifelong learning in Neurology, 2004, 10: 38-73.
19. **Poser CM, Paty PW, Scheinberg L, McDonald WI, Davis FA, Ebers GC, Johnson K.P., Sibley WA, Silberberg, DH and Tourtellottee WW (1983):** New diagnostic criteria for multiple sclerosis: guidelines for research protocols. *Annals of Neurology.*, 13: 227-231
20. **McDonald WI and Ron MA (1999):** Multiple sclerosis: the disease and its manifestations. *Philosophical Transactions of the Royal Society*, 354: 1615-1620.
21. **Tintore´ M, Rovira A, Martí´nez MJ *et al.* (2000):** Isolated demyelinating syndromes: comparison of different MR imaging criteria to predict conversion to clinically definite multiple sclerosis. *American Journal Of Neuroradiology*, 21:702–6
22. **Rovira A & Alonso JH (2013):** magnetic resonance spectroscopy in multiple sclerosis and related disorders. *Neuroimaging Clinics of North America*, 23:459–474.
23. **Zaaraoui W, Rico A, Audoin B *et al.* (2010):** Unfolding the long-term pathophysiological processes following an acute inflammatory demyelinating lesion of multiple sclerosis.Magnetic resonance imaging., 28:477–86
24. **Wuerfel J, Bellmann-Strobl J, Brunecker P *et al.* (2004):** Changes in cerebral perfusion precede plaque formation in multiple sclerosis: a longitudinal perfusion MRI study. *Brain*, 127:111–119
25. **Kapeller P, Ropele S, Enzinger C, Lahousen T, Strasser-Fuchs S, Schmidt R., and Fazekas F (2005):** Discrimination of white matter lesions and multiple sclerosis plaques by short echo quantitative <sup>1</sup>H-MRS. *Journal of Neurology*, 252: 1229–1234
26. **Hartel M, Kluczevska E, Pierzchala K, Adamczyk-Sowa M and Karpe J (2016):** What you cannot get from routine MRI of MS patient and why – The growing need for atrophy assessment and seeing beyond the plaque. *Neurologiai Neurochirurgia Polska*, 50 (2):123-130.
27. **Klaver R, De Vries HE, Schenk GJ and Geurts JG (2013):** Grey matter damage in multiple sclerosis: A pathology perspective *Prion*, 71:66–75.
28. **Caramanos Z, DiMaio S, Narayanan S *et al.* (2009):** <sup>1</sup>H-MRSI evidence for cortical gray matter pathology that is independent of cerebral white matter lesion load in patients with secondary progressive multiple sclerosis. *Journal of Neurological sciences*, 282: 72–79.
29. **Calabrese & Castellaro (2017):** Cortical Gray Matter MR Imaging in Multiple Sclerosis. *NeuroimagClin N Am.*, 27:301–312.
30. **Van Au Duong M, Audoin B, Le Fur Y *et al.* (2007):** Relationships between gray matter metabolic abnormalities and white matter inflammation in patients at the very early stage of MS: a MRSI study. *Journal of Neurology*, 254(7):914–923.
31. **Sun J, Song H, Yang Y, Zhang K, Gao X, Li X, Ni L, Lin P, Niu C (2017):** Metabolic changes in normal appearing white matter in multiple sclerosis patients using multivoxel magnetic resonance spectroscopy imaging. *Medicine*, 96: 1-7.
32. **Arnold DL (2005):** Changes observed in multiple sclerosis using magnetic resonance imaging reflect a focal pathology distributed along axonal pathways. *Journal of Neurology*, 252(5):v25-v29.