

## The Role of Diffusion-Weighted MRI in the Characterization of Musculoskeletal Soft Tissue Tumors

Mohamed A. Nassif, Susan A. Abdul Rahim, Rana Z. Hussien

Department of Radio-diagnosis, Faculty of Medicine, Ain Shams University

Corresponding author: Rana Zahim Hussein, Mobile: 01006639731, Email: ranazahim2010@gmail.com

### ABSTRACT

**Background:** magnetic resonance imaging (MRI) has an important role in characterization of soft tissue tumors, yet, it lacks specificity for differentiation between the benign and malignant lesions. **Aim of the Work:** this study aimed to evaluate the ability of DW MRI in detection and characterization of the musculoskeletal soft tissue tumors. **Patients and methods:** this prospective study included 30 patients (20 females and 10 males) referred to MRI unit Ain shams University Hospital for MRI evaluation of musculoskeletal soft tissue tumors. **Results:** from 30 cases, 12 cases were benign (40%), 18 cases malignant (60%). From 12 cases of the benign, 8 cases were  $\leq 40$  years and 4 cases were  $> 40$ . From 18 cases of the malignant, 7 cases were  $\leq 40$  and 11 cases  $> 40$ . Ranging of ADC value of benign tumors (1.72-2.58); mean ADC ( $2.21 \times 10^{-3} \text{ mm}^2/\text{sec}$ ). Ranging of ADC value of malignant tumors was 0.52-1.82. Mean ADC value was  $0.90 \times 10^{-3} \text{ mm}^2/\text{sec}$ . Cut-off ADC value  $\leq 1.14$  less than 1.14 was benign and more than 1.14 was malignant; sensitivity 94.4% and specificity 91.7%. **Conclusion:** DWI with ADC mapping and measurement of ADC value proved to be a valuable non-invasive tool in differentiating between benign and malignant musculoskeletal soft tissue tumors. **Recommendations:** a larger population for future studies is needed. Thus, histopathologic work up is required for reliable characterization of soft tissue tumors <sup>(4)</sup>. **Keywords:** diffusion-weighted MRI, musculoskeletal, soft issue, tumor.

### INTRODUCTION

Musculoskeletal soft-tissue tumors are arising from ectodermal and mesodermal layers <sup>(1)</sup>. They can generally be classified into two main categories, that is, soft-tissue sarcomas and benign tumors, and these tumors can occur at any age and present at any site <sup>(1,2)</sup>.

MRI is indispensable in the evaluation of soft tissue tumors and become modality of choice. It offers improved soft tissue contrast when compared to other modalities <sup>(3)</sup>.

There are some findings on MRI which are indicative for malignancy, such as infiltration of adjacent tissue destruction of bones and tendons and the size of mass. There are no criteria available to clearly distinguish benign mass from malignant, some very aggressive tumors present as encapsulated mass without surrounding edema and only minimal enhancement which are in general indicative for benign process. Thus, histopathological work up is required for reliable characterization of soft tissue tumors <sup>(4)</sup>. The DWI now is used in association with conventional MRI with the objective of improving diagnostic accuracy and treatment evaluation. DWI allows quantitative and qualitative analysis of tissue cellularity and cell membrane integrity and has been widely used for tumor detection and characterization to monitor treatment response <sup>(5)</sup>. The tissue contrast using diffusion weighted image (DWI) is different from that attained using conventional MR technique. The DWI involves the diffusion motion of water protons in tissue, which produces different contrast in different kinds of tissues, because of this procedure provides different information about the diseased tissue <sup>(6)</sup>.

DWI has the potential to differentiate benign from malignant soft tissue tumors because malignant tumors have greater cellularity with more restricted diffusion than benign tumors <sup>(7)</sup>.

This study aimed to evaluate the ability of DW MRI in detection and characterization of the musculoskeletal soft tissue tumors.

### PATIENTS AND METHODS

This was a prospective study which included 30 patients (20 females and 10 males) referred to MRI Unit, Ain shams University Hospital for MRI evaluation of musculoskeletal soft tissue tumors.

This study included clinically suspected or previously diagnosed musculoskeletal soft tissue tumors by other modalities with no age or sex predilection. Patients with contraindication to MRI (e.g.: patients who have heart pacemaker, metallic foreign body and metallic device) and patients with severe claustrophobia were excluded.

An informed consent from all patients was taken before the MRI examination.

#### MRI technique

Patients were examined using 1.5 T closed MRI machine (MR system Intra, PHILIPS) using the most optimal surface coil accommodates each lesion. The predetermined examination protocol was applied to all patients that included the following:

- 1) T1-WI (TR/TE=400-700/14-30,fov,20-35) and T2-WI (TR/TE=2800-4500/80-120,FOV20-35) in axial, coronal and /or sagittal.

- 2) At least one fat saturated sequence or short inversion recovery (STIR) sequence (TR/TE=4000-5600/18-40,FOV,20-35)
- 3) Post IV contrast sequence (in most cases including axial in addition to sagittal and coronal) using gadolinium DTPA with calculated dose 0.1 mmol/Kg body weight.
- 4) Diffusion weighted MRI were acquired in axial plane by single shot, spine echo EPI sequence. The strength of MPG defined by the gradient factor b. The b-values used in this study were 0,400and 800s/mm<sup>2</sup>.

Body parts were examined and immobilized to prevent motion artifacts, slice thickness ranged from 4mm to 10 mm, interslice gap of 2-3mm, the matrix will be used for all sequence 512\*512 except the DWI 128\*64.

Quantitative analysis was obtained by mathematically calculating the apparent diffusion image (ADC). ADC map was automatically generated by the work station based on three b values according to the formula.  $ADC = (S_0/S_1)/(B_1 - B_0)$ , where  $s_0$  and  $s_1$  are the signal intensity b before and after application of diffusion gradient, and  $b_1$  and  $b_0$  are the different b values applied. The ADC is numerical value calculated by manually placing a region of interest (ROI) over the solid portion of tumor. The MR imaging results were correlated with the histopathological examination and statistical analysis of the collected data.

The study was approved by the Ethics Board of **Ain Shams** University.

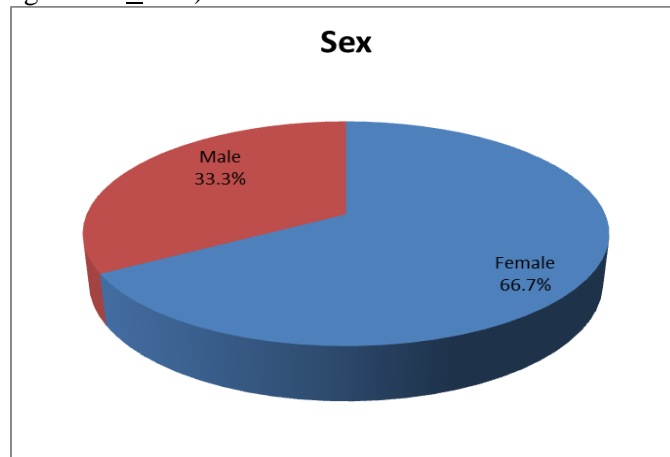
### Statistical analysis

Data were analyzed using Statistical Program for Social Science (SPSS) version 20.0. Quantitative data were expressed as mean ±

standard deviation (SD). Qualitative data were expressed as frequency and percentage.

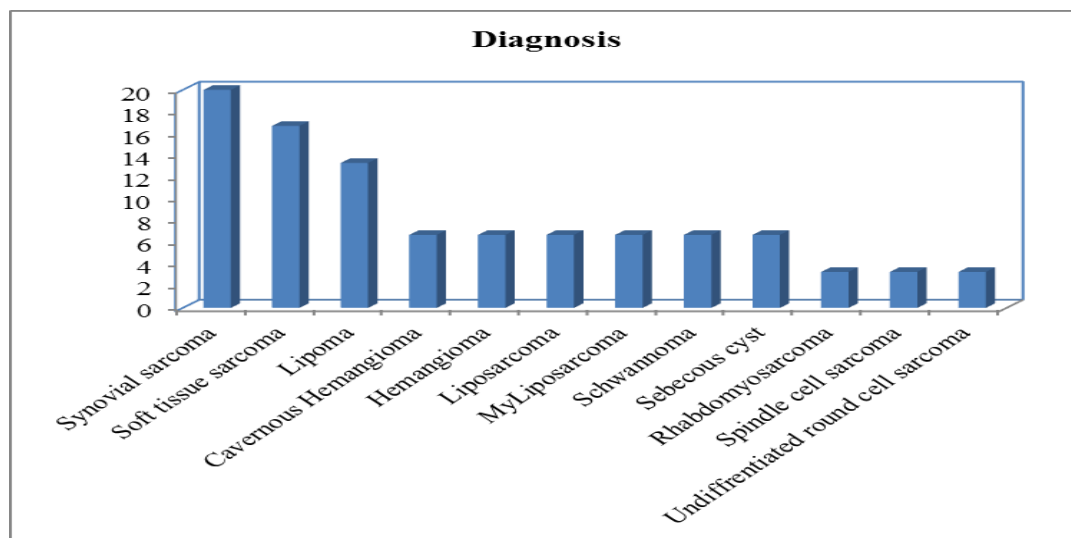
### RESULTS

This study included 30 patients 20 female (66.7%) and 10 male (33.3%) **Fig: (1)**, regarding in age between 7 and 74 years (mean age:  $43.07 \pm 17.7$ ).



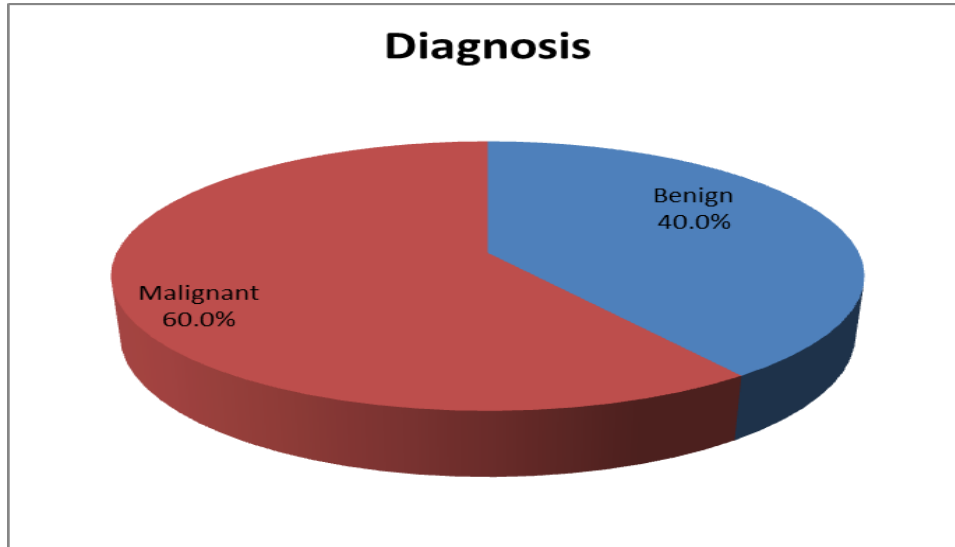
**Figure 1:** sex distribution of the study group.

The diagnosis was confirmed after the MRI examination by the histologic biopsy according to standard histopathological procedures in all cases. From the 30 soft tissue mass lesions, 6 cases were synovial sarcoma (20.0%), 5 cases were soft tissue sarcoma (16.7%), 4 cases were lipoma (13.3%), 2 cases were cavernous Hemangioma (6.7%), 2 cases were hemangioma (6.7%), 2 cases were liposarcoma (6.7%), 2 cases were myliposarcoma (6.7%), 2 cases were schwannoma (6.7%), 2 cases were sebaceous cyst (6.7%), 1 cases was rhabdomyosarcoma (3.3%), 1 cases was spindle cell sarcoma (3.3%) and 1 cases was undifferentiated round cell sarcoma (3.3%) (**Fig. 2**).



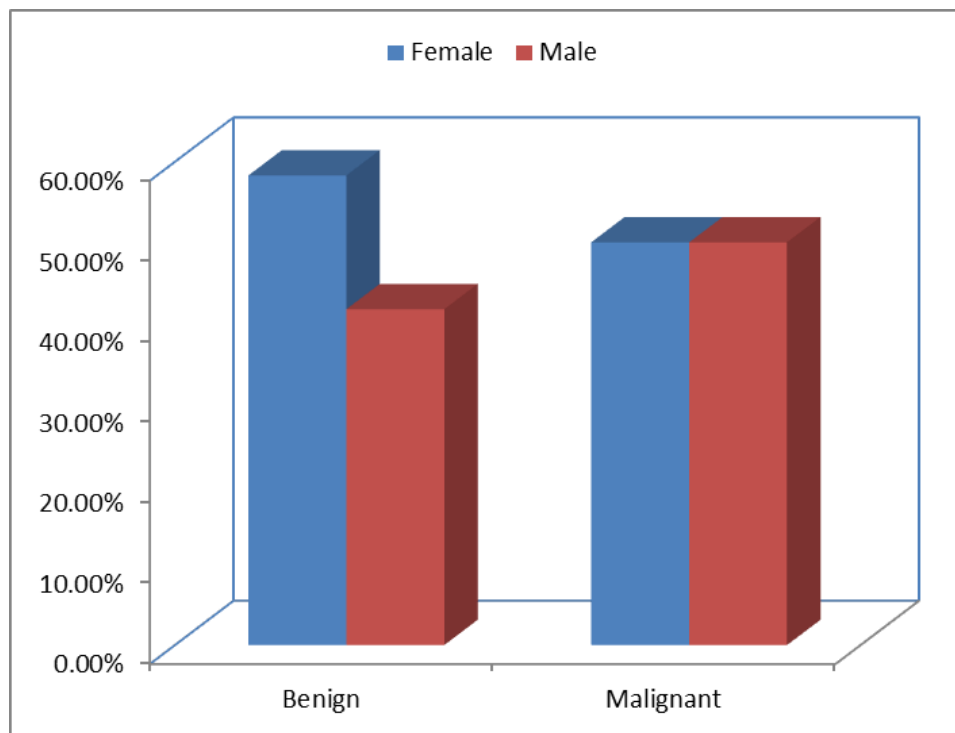
**Figure 2:** diagnosis distribution of the study group.

Out of 30 cases, 12 cases were benign (40.0%) and 18 cases were malignant (60.0%) (**Fig. 3**).



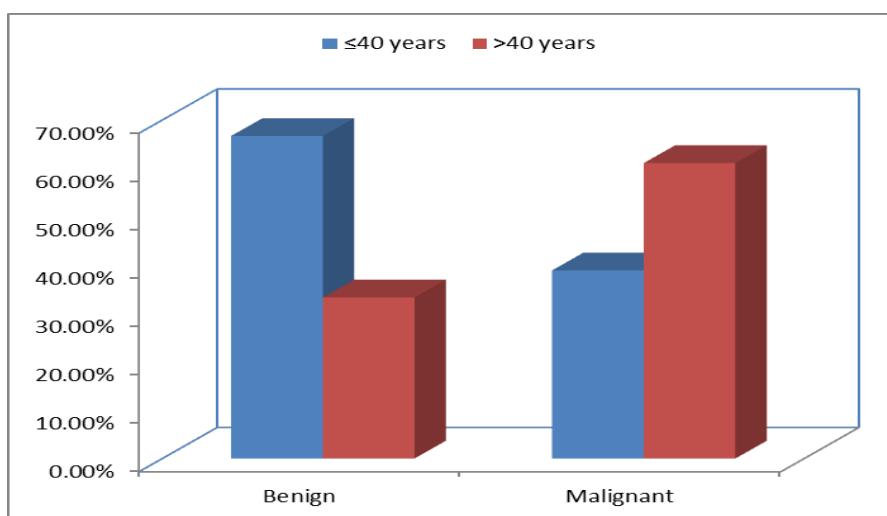
**Figure 3: diagnosis distribution of the study group**

This study shows no statistically significant difference between benign and malignant according to sex (P value 0.374). From 12 cases of benign masses, 7 cases were female (58.3%) & 5 cases were male (41.7%). From 18 cases of malignant masses, 9 cases were female (50%) & 9 cases were male (50%) (Fig. 4).



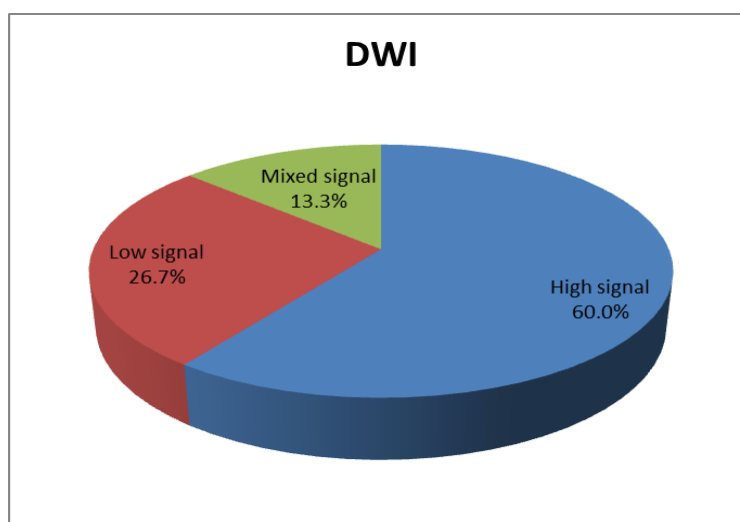
**Figure 4: bar chart between benign and malignant according to sex**

This study showed no statistically significant difference between the benign and malignant masses according to age (P value 0.136). From 12 cases of benign, 8 cases were  $\leq 40$  years (66.7%) & 4 cases were  $> 40$  years (33.3%). From 18 cases of malignant, 7 cases were  $\leq 40$  years (38.9%) & 11 cases were  $> 40$  years (61.1%) (Fig. 5).



**Figure 5: differences between benign and malignant according to age (years).**

In our study 60% of cases showed high signal intensity on DWI, 26.7% of cases showed low signal intensity and 13.3% of cases show mixed signal intensity **Fig (6)**.

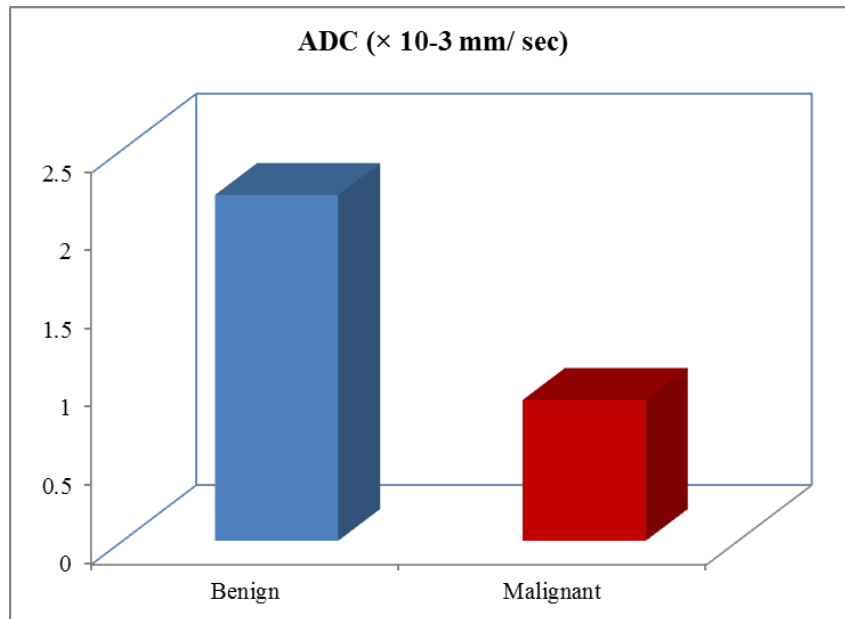


**Figure 6: DWI distribution of the study group**

High statistically significant differences between the benign and malignant masses according to ADC value was found. The mean ADC value of benign masses was (2.21) with minimum value (1.72) & maximum value (2.58) while the mean ADC value of malignant masses (0.90) with minimum value (0.52) and maximum value (1.82) (**Table 1 and Fig. 7**).

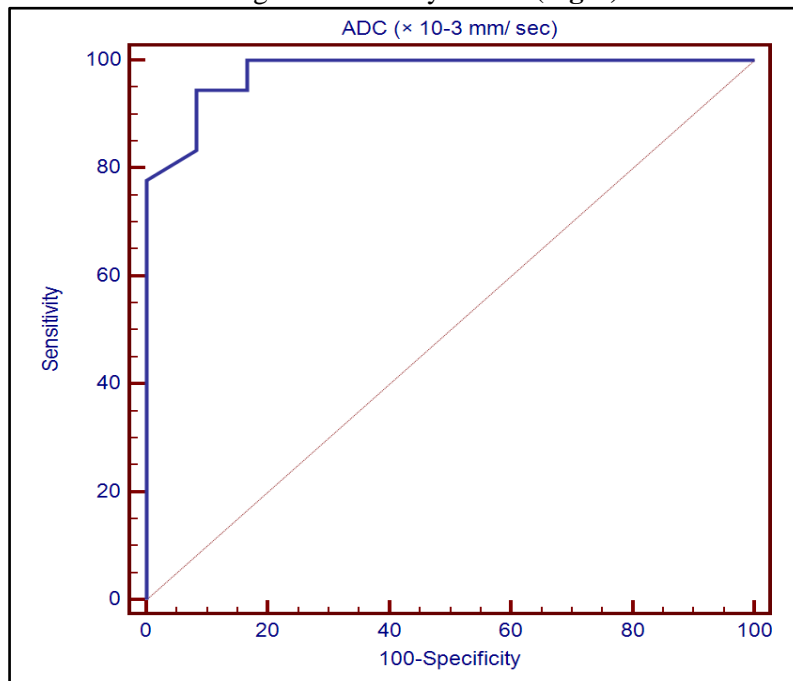
**Table 1:** comparison between the benign and malignant according to ADC ( $\times 10^{-3}$  mm/sec).

Diagnosis	ADC ( $\times 10^{-3}$ mm/ sec)				t-test	
	Mean	$\pm$ SD	Min.	Max.	T	p-value
Benign	2.21	0.27	1.72	2.58	15.543	<0.001
Malignant	0.90	0.32	0.52	1.82		
Total ADC value	1.42	0.71	0.52	2.58		



**Figure 7: differences between benign and malignant according to mean ADC value**

The cut-off ADC value was  $<1.14$ . masses with ADC value  $<1.14$  were malignant & masses  $>1.14$  were benign. With ADC value ( $<1.14$ ) with sensitivity of 94.4% specificity of 91.7% positive predictive value of 94.4%, negative predictive value of 91.7% with diagnostic accuracy of 97.9 (Fig. 8).



**Figure 8: receiver-operating characteristic (ROC) curve for prediction of malignant using the lamellar body count (LBC).**

## DISCUSSION

Magnetic resonance imaging (MRI) imaging has an important role in characterization of soft tissue tumors, yet, it lacks specificity for differentiation between benign and malignant lesions<sup>(8)</sup>. Diffusion-weighted imaging (DWI) is a noninvasive method for investigation of tumor histological content and used for differentiation between benign and malignant masses. Increased apparent diffusion coefficient (ADC) values represent an increase in extracellular water or loss of cell membrane integrity whereas decreased

ADC values reflect decrease in extracellular water content or increase in cell number or size<sup>(9)</sup>.

Our study included 30 patients (20 females and 10 males) which matched the study made by **Einarsdóttir et al.**<sup>(10)</sup> that included 32 patients and that of **Pekcevik et al.**<sup>(9)</sup> which included 25 patients. From 30 cases, 12 cases were benign masses included lipoma, schwannoma, hemangioma and sebaceous cyst and 18 cases were malignant included synovial sarcoma, liposarcoma,

myoliposarcoma, rhabdomyosarcoma, spindle cell sarcoma and undifferentiated round cell sarcoma.

In our study, the result revealed that the ADC value of benign tumors was ranged between  $2.21\pm 2.58 \times 10^{-3} \text{mm}^2/\text{sec}$  and it was significantly higher than that of malignant soft tissue tumors which ranged between  $0.90\pm 1.82 \times 10^{-3} \text{mm}^2/\text{sec}$ , where the mean the mean ADC value of all benign soft tissue tumors was  $2.21\pm 0.27 \times 10^{-3} \text{mm}^2/\text{sec}$ , while the mean ADC value all malignant soft tissue tumors was  $0.90\pm 0.32 \times 10^{-3} \text{mm}^2/\text{sec}$  with statistically significant difference ( $p < 0.001$ ). This result matched with those of **Pekcevik *et al.***<sup>(9)</sup> in which the mean ADC value of benign masses was  $2.31\pm 1.29 \times 10^{-3} \text{mm}^2/\text{sec}$  and mean ADC value of malignant masses was  $0.90\pm 0.70 \times 10^{-3} \text{mm}^2/\text{sec}$  with statistically significant difference ( $p < 0.001$ ).

Also, **Razek *et al.***<sup>(11)</sup> reported that malignant tumors tend to exhibit a lower mean ADC value than benign soft-tissue tumors and proposed using a threshold mean ADC value of  $1.34 \times 10^{-3} \text{mm}^2/\text{sec}$  to help distinguishing of benignity from malignancy.

Our results also matched with **Zou *et al.***<sup>(12)</sup> who reported that the mean ADC value in patients with malignant soft-tissue tumor decreased significantly in comparison with the ADC values obtained in patients with benign soft-tissue tumor ( $P < 0.001$ ). Mean ADC value of benign soft tissue tumors was  $1.37 \times 10^{-3} \text{mm}^2/\text{sec}$ , while mean ADC value of malignant soft tissue tumors was  $0.8 \times 10^{-3} \text{mm}^2/\text{sec}$ .

The specificity of ADC value is dependent on the threshold value that determines the differentiation between benign and malignant tumors. In our study we obtained threshold value  $1.14 \times 10^{-3} \text{mm}^2/\text{sec}$  with 94.4% sensitivity and 91.7% specificity and diagnostic accuracy of 97.9%, where there was highly significant difference between the benign and malignant soft tissue tumors ( $p < 0.001$ ). This was higher than the result of **Nagata *et al.***<sup>(6)</sup> who found the sensitivity and specificity of 76.3% and 76.7% respectively, were achieved when an ADC value threshold greater than 1,  $35 \times 10^{-3} \text{mm}^2/\text{sec}$  was used. However, these results are matched with those of **Razek *et al.***<sup>(11)</sup> who found sensitivity of 94%, specificity of 88% and an overall accuracy of 91%.

**Limitations in our study were:** lacking of some histological musculoskeletal tumors which make it difficult to know if our results are matching to all tumors or not and also the difficulty in comparison of our results with those of others due to differences in imaging sequences and differences in b-value.

**So we recommended** that a larger population for future studies with more varieties of histopathological studies on the musculoskeletal soft tissue are needed

## CONCLUSION

This study concluded that DWI with ADC mapping and measurement of ADC value proved to be a valuable non-invasive tool in differentiating benign and malignant musculoskeletal soft tissue tumors.

## REFERENCES

1. **David D, Rajappan LM, Balachandran K *et al.* (2011):** Prognostic significance of STAT3 and phosphorylated STAT3 in human soft tissue tumors—A clinicopathological analysis. *Exp. Clin. Cancer Res.*, 30:56-66.
2. **Pencavel T, Strauss DC, Thomas JM *et al.* (2010):** The surgical management of soft tissue tumours arising in the abdominal wall. *Eur. J. Surg. Oncol.*, 36:489-495.
3. **Goldblum JR, Weiss SW and Folpe AL. (2013):** Enzinger and Weiss's Soft Tissue Tumors. Elsevier Health Sciences, London. pp:14-15.
4. **Andreas MH, Ringl H, Memarsadeghi M *et al.* (2007):** Diffusion weighted imaging in osteoradiology *Top Magn. Reson. Imaging*, 18:203-212.
5. **Koh DM and Collins DJ (2007):** Diffusion-weighted MRI in the body: applications and challenges in oncology. *Am. J. Roentgenol.*, 188(6):1622-1635.
6. **Nagata S, Nishimura H, Uchida M *et al.* (2008):** Diffusion-weighted imaging of soft tissue tumors: usefulness of the apparent diffusion coefficient for differential diagnosis. *Radiant. Med.*, 26:287-295.
7. **Maeda M, Matsumine A, Kato H *et al.* (2007):** Soft tissue tumors evaluated by line-scan diffusion-weighted imaging: influence of myxoid matrix on the apparent diffusion coefficient. *J. Magn. Reson. Imag.*, 25:1199-1204.
8. **Subhawong TK, Wang X, Durand DJ, Carrino J *et al.* (2012):** Musculoskeletal lesions. *Am. J. Roentgenol.*, 198(1):162-172.
9. **Pekcevik Y, Kahya MO and Kaya A. (2015):** Characterization of soft tissue tumors by diffusion-weighted imaging. *Iranian Journal of Radiology*, 12(3)- 1-3.
10. **Einarsdóttir H, Karlsson M, Wejde J *et al.* (2004):** Diffusion-weighted MRI of soft tissue tumours. *European Radiology*, 14(6):959-963.
11. **Razek A, Nada N, Ghaniem M and Elkhamary S (2012):** Assessment of soft tissue tumors of the extremities with diffusion echoplanar MR imaging. *Radiol. Med. (Torino)*, 117(1):96-101.
12. **Zou Y, Wang QD, Zong M (2016):** Apparent diffusion coefficient measurements with diffusion-weighted imaging for differential diagnosis of soft-tissue tumor. *Journal of cancer research and therapeutics*, 12(2):864-872.