



Clinical, Pathological and Molecular Study of Marek's Disease in the *Gallus glus Domesticus* and *Brahma* Chickens of Basra Province, Iraq



CrossMark

Isam A. Khaleefah and Harith A. Najem*

Department of Pathology and Poultry Diseases, collage of Veterinary Medicine, University of Basra, Basra, Iraq.

THE current study was conducted to diagnose the Marek's disease in naturally infected *Gallus glusdomesticus* chickens and *Brahma* chickens in Basrah province , Iraq, on the basis of clinicopathological findings and by Polymerase chain reaction (PCR) . Suspected samples were collected randomly from different areas in Basrah province, (poultry houses, veterinary clinics, markets and Consulting clinic of the veterinary medicine college of Basrah university). The results of this study showed that some birds had significant clinical signs of Marek's Disease, like paralysis of the legs and wings. Post mortem inspection showed different lesions according to chickens species in the *Gallus gallusdomesticus* which were severely affected in sciatic nerve inferred by enlargement of sciatic nerve, splenomegaly & hepatomegaly with nodular tumor as well as lesions in the other organs. In *Brahma* chickens there were mild gross lesions in viscera and only showed enlargement of sciatic nerve. Histopathological examination showed changes in the spleen (necrosis in the white pulp and hyperplasia in the central arteriole of the white pulp) . Sciatic nerve showed edematous fluid in the nerve parenchyma and infiltration of mononuclear inflammatory cells mainly lymphocytes in the nerves parenchyma. The feather follicles showed marked vacuolation of the epithelial layer as well as infiltration of inflammatory cells in the follicular lining. The confirmation was done by PCR which showed that the total positive samples for avian Marek's Disease serotype-1 were nine samples, three positive samples of spleens and two positive samples of feather follicles as well as three positive samples of sciatic nerve and one positive sample of liver . Based on these results , MDV was concluded to be the etiology for this pathological condition in Iraqi backyard flocks. This is the first report of the presence of the MDV in *Gallusgallus* and *Brahma* breed in Iraq. Accordingly, the commercial poultry population in Iraq is not far from the threat of the MDV, and surveillance for MDV is needed.

Keywords: Chickens Marek's disease virus. Clinical, Pathological and Molecular characterization.

Introduction

Marek's disease (MD) is a lymphoproliferative disease of chickens caused by cell-associated MD herpesvirus (MDV) (*Gallidherpesvirus* (GaHV)-2). MD is characterized by diffuse or nodular tumor in viscera, muscle, and skin as well as lesions in peripheral nervous tissues [1]. MD is a lymphomatous and neuropathic disease

commonly of the domestic chicken and less commonly of turkey and quail. In 1907 Jozsef Marek, published his observations of a paralytic disease affecting four cocks. In 1967, the cause of MD was identified as a herpes virus [2]. The first successful vaccine against a herpes viral disease was developed in 1969 [3]. MD occurs in chickens of 3-4 weeks of age or older but

the most common in chickens between 12 to 30 weeks of age [4]. Birds get infection by horizontal transmission, direct or indirect contact between birds, inhalation of infected dust containing contaminated dander [5]. There are several diagnostic methods for MD, clinical signs, post mortem changes, histopathological changes and the use of polymerase chain reaction (PCR) [6]. MD is a major economic risk for poultry farms as it occurs in almost all commercial chicken farms and causes significant economic loss with an estimated annual loss up to the US \$2 billion worldwide [7]. Due to the unpredictability of outbreaks and the possibility of vaccination failure as a consequence of the evolution of more virulent strains of MDV, MD remains a major concern for the poultry industry [8]. In Iraq, the poultry industry has a significant economic contribution and involves different species of chicken. There limited studies on this disease in Iraq. The disease remains one of the problems in poultry farms and there are limited studies about the incidence and type of virus. The aim of this study is to investigate the occurrence rate and characteristics of Marek's disease in different avian species in local farms .

Materials and Methods

Clinical history, gross lesions, and histopathologic examination

The study focused on clinical signs, postmortem lesions, histopathological changes and PCR for confirmation laboratory diagnosis. The duration of the present study was from September 2019 to march 2020. The samples of domestic birds were collected randomly from different areas from Basra province, (poultry houses, veterinary clinics, markets and Consulting clinic of veterinary medicine collage of Basra university) according to the primary clinical suspected diagnosis as MD, then all samples were presented to the department of veterinary Pathology and poultry diseases at the University of Basra for necropsy examination. Chickens that were showing clinical signs were euthanized. All cases were examined for gross lesions in viscera The preparation of postmortem lesions, was processed according to the following steps[9]: Tissue samples from internal organs including (liver, brain, sciatic nerve, feather follicle, spleen and intestine) were collected and preserved in 10% formalin solution for histopathological examination according to Luna [10].

Egypt. J. Vet. Sci. Vol. 52, No.1 (2021)

Extraction of DNA and PCR

DNA was extracted from the viscera that were suspected for MDV following the gSYNC™ DNA Extraction kit quick protocol (Geneaid, Korea).

Polymerase chain reaction (PCR)

All the extracted DNA samples were examined by Nano drop instrument in order to determine the concentration and purity of viral DNA. The extracted DNA samples were tested by PCR. The PCR technique used to detect the *meg* gene of MDV (approximately 318 bp) using the forward primer (5'-GGAT CGCCACACGATTACTACC-3') and reverse primer (5'-ACTGCCTCACACAACCTCATCTCC-3') as described previously [11]. The primers were synthesized by VBC Biotech and purified by reverse phase high performance liquid chromatography (Vienna, Austria). PCR reactions were conducted by using AccuPower® PCR PreMix Kit (Bioneer, South Korea).

Result

Clinical history, gross lesions, and histopathologic examination

In this study a total of 20 chickens were clinically examined. The focus was on two different types of chickens species *Gallus gallus domesticus* chickens and *Brahma* chickens. Some of birds were showing significant clinical signs for MD, that were fan shape, one leg pushed forward and the other posterior as a result of unilateral paralysis of the leg as in (Fig.1).

Other clinical symptoms observed were paralysis of right leg, Paralysis of wing (Fig. 2) weight loss is usually the result of paralysis, rendering the birds unable to reach food and water and depression .The clinical signs mostly appeared in chickens with 8 to 16 weeks of age .

Post mortem inspection showed different lesions according to chickens species. In the *Gallus gallus domesticus*, which were Severely affected in peripheral nerves (sciatic nerve), the signs characterized by enlargement of sciatic nerve, loss of cross-striations, yellow discoloration, and edematous appearance as shown in (Fig.3), Splenomegaly & hepatomegaly with nodular tumor as shown in (Fig.4) as well as lesions in the other organs such as heart intestine and enlargement of feather follicles. While in *Brahma* chickens no gross lesions in viscera were noted except enlargement of sciatic nerve .



Fig.1. Chicken suspected of MDV infection paralysis of leg.



Fig. 2. Clinically diseased chickens suspected of MDV infection paralysis of wing .

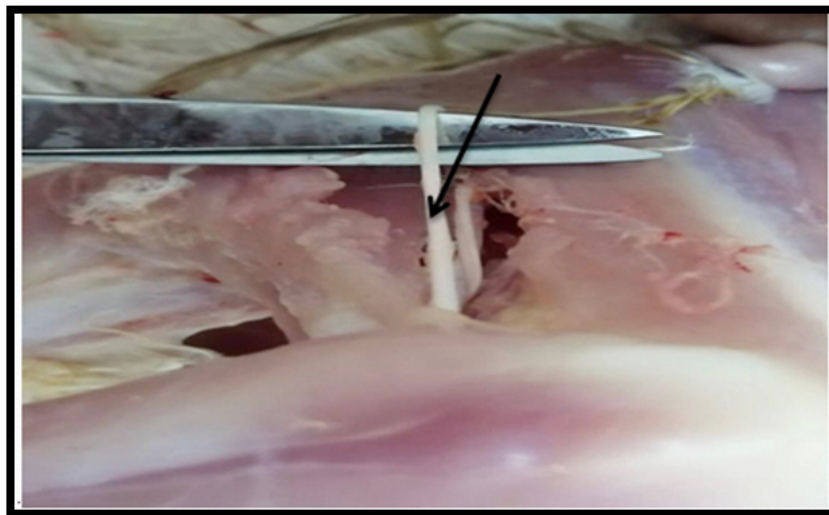


Fig. 3. Enlargement of sciatic nerve .

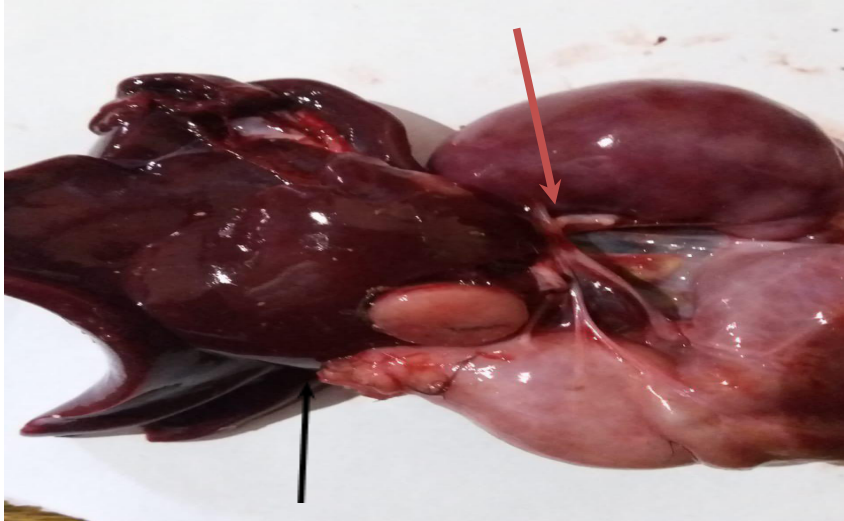


Fig. 4. Splenomegaly with nodular tumor (red arrow). & hepatomegaly with nodular tumor (black arrow).

Histopathological lesions, after staining of hematoxylin eosin of the tumor tissues, showed changes in the spleen of infected birds and area of necrosis in the white pulp (Fig. 5) and hyperplasia in the central arteriole of the white pulp. Changes of sciatic nerve of infected chickens with MDV included edematous fluid in the nerve parenchyma as well as infiltration of mononuclear inflammatory cells mainly lymphocytes in the nerves parenchyma as shown in (Fig. 6). Feather follicle of infected chickens showed marked vaculation of epithelial layer as shown in (Fig. 7) as well as infiltration of inflammatory cells in the follicular lining .

Detection of DNA virus by PCR

PCR amplification for *meg* gene of MDV, from the virus DNA extracted from samples, was conducted by using the forward primer and reverse primer. Sixteen total samples that were examined by PCR technique ((Figures 8 and 9). After running on agarose gel, DNA bands (approximately 318bp long) were noted. Nine samples showed the correct size DNA bands: Three positive samples of spleens and two positive samples of feather follicles as well as three positive samples of sciatic nerve and one positive sample of liver. Total negative samples by PCR were seven samples.

Discussion

MD is one of the most economically devastating infectious diseases of poultry usually characterized by oncogenic transformation of T cells that infiltrates lymphoid tissues, internal

organs and peripheral nerves, resulting in difficult pathogenesis that usually leads to the death of the affected birds[12]. There were no previous scientific documents about MDV in Iraq and especially in Basra governorate . In the present study the identification of MDV in two types of chickens (*Gallus gllusdomesticus* chickens and brahma chickens) which reared under different production system. The diagnosis of MDV was reached by using recommended diagnostic techniques by clinical signs, postmortem changes , histopathological changes and polymerase chain reaction [12]. The clinical signs appeared mostly in 10 weeks old chickens which is in agreement with [13].

The clinical monitoring showed leg and wing paralysis, weight loss and depression which are in consistent with those mentioned by Liu et al. [14] and Demeke et al. [15]. The change of feather follicles tumor in Braham chickens was not observed in this study which disagree with Liu et al. [14]. These agree with those mentioned by Gall et al. [16] the differences of results may be duo to different the types of birds or the Braham birds may be vaccinated.

Gross lesions in different internal organs like splenomegaly , tumor of intestine , hepatomegaly as well as enlargement of feather follicles and enlargement of sciatic nerve, which are symptomatic of lymphoid tumors , were observed in *Gallus gllusdomesticus* chickens in this study which are agree with many authors [4,14,17] .

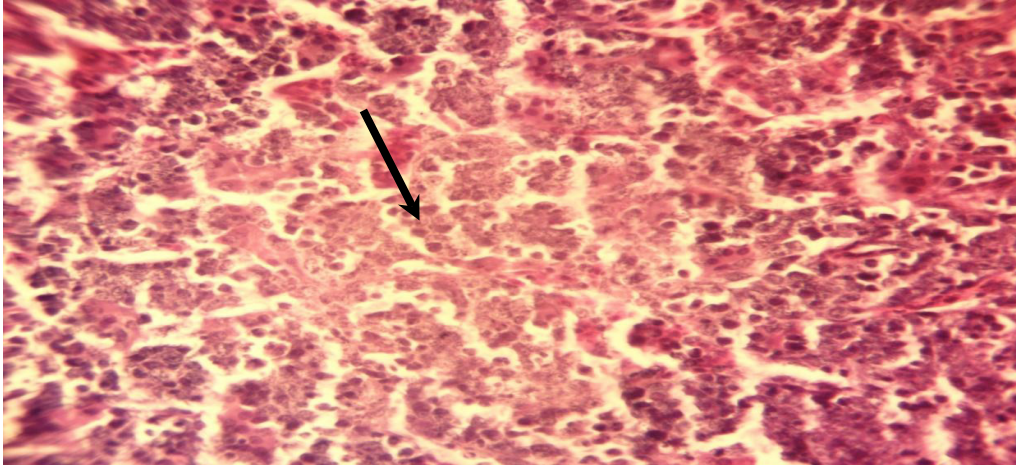


Fig. 5. Histological section in the spleen of infected group showed area of necrosis in the white pulp (black arrow). H & E stain. 100X.

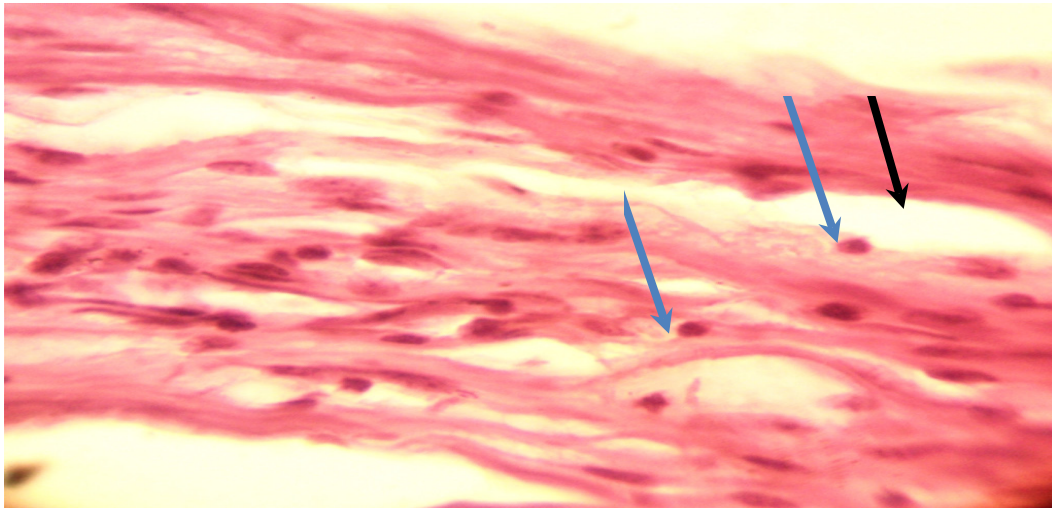


Fig. 6. Histological section of sciatic nerve of infected chickens with MDV showed edematous fluid in the nerve parenchyma (black arrow), as well to infiltration of mononuclear inflammatory cells mainly lymphocytes in the nerves parenchyma (blue arrow).H&E stain. 40 X.

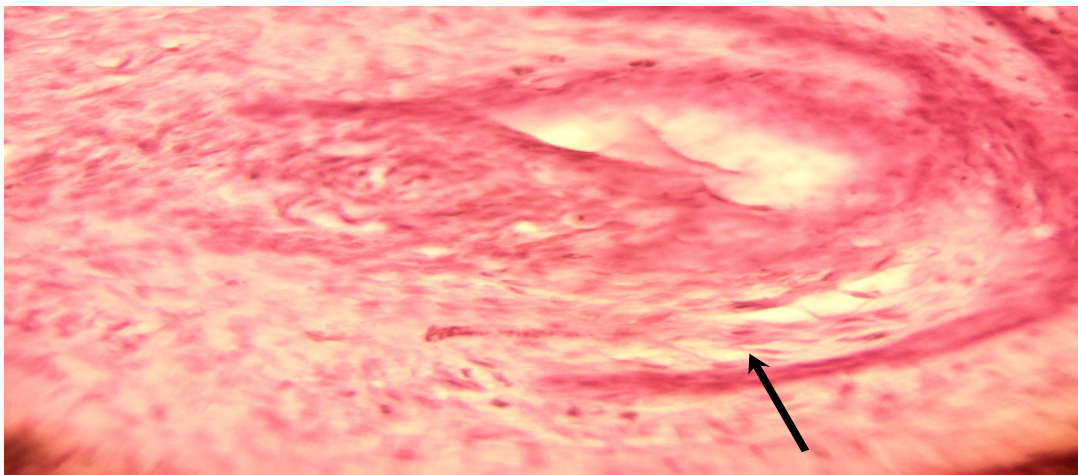


Fig. 7. Histological section of feather follicle of infected chickens showed marked vacuolation of epithelial layer (black arrow). H & E stain. 40 X.

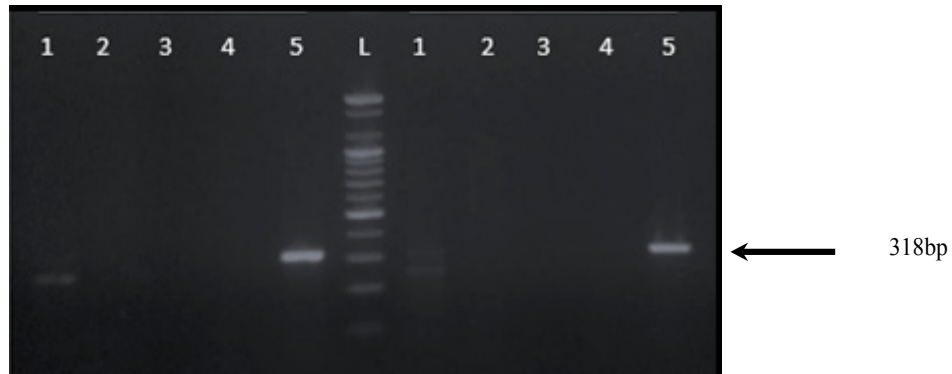


Fig. 8. Agarose gel electrophoresis design of MDV partial meg gene PCR produces (approximately 318bp). 1 & 5: Field samples were positive.

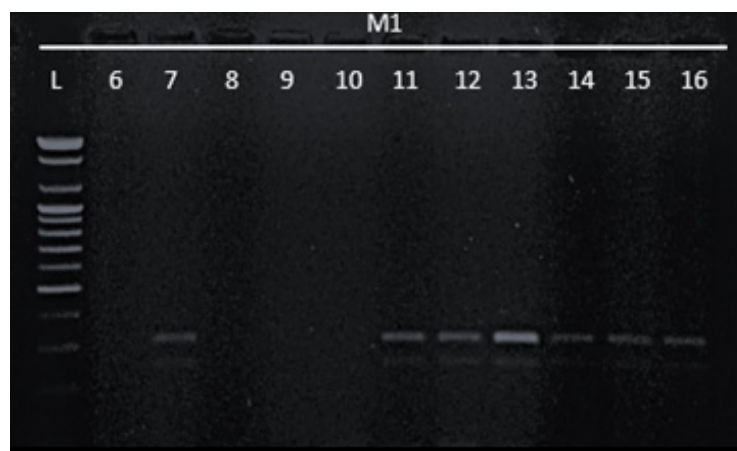


Fig. 9. Agarose gel electrophoresis design of MDV partial meg gene PCR produces (approximately 318bp). 7 & 11-16: Field samples were positive .

Gross lesions in Braham chickens were not observed except enlargement of sciatic nerve which disagree with some researchers [14,18]. This result agrees with Gall et al. [16]. The differences are probably due to differences of environment condition or different types of birds or the birds may be vaccinated.

Histopathological changes associated with MDV in the euthanized chickens were shown in the spleen of infected chickens hyperplasia in the central arteriole of the white pulp. These agree with Balachandran et al. [19]. Sciatic nerve of infected chickens with MDV showed edematous fluid in the nerve parenchyma as well to infiltration of mononuclear inflammatory cells mainly lymphocytes in the nerves parenchyma. These results are in agreement with some investigators [16,20].

Feather follicle of infected chickens with MDV showed vaculation of epithelial layer as

well as infiltration of inflammatory cells in the follicular lining which agree with Heidari et al. [21].

Studies also performed the use of PCR as an aid in diagnosing chickens MDV[5]. PCR amplification can be performed directly from tissues for detecting tissue virus, since this test detects the virus even in a very small amount, as the method allows direct detection of virus in tissue samples[4].

In this study 16 chickens tissues samples of sciatic nerve, liver and spleen were used to molecular analysis to confirm the presence of MDV .infected chickens gave a strong bands on agarose gel . This result agreed with the results obtained by many authors [22-25] .

Conclusions

The study identified DMV for the first time in Iraq\ Basrah Governorate from *Gallus gallus*

domesticus chickens and brahma chickens. Also results of present study revealed that some cases of MDV showed significant clinical signs, histopathological changes and identified the virus but it did not find the presence of visceral tumor. It seems that the commercial poultry population in Iraq is not far from the threat of the infection, and surveillance for MDV is needed. Furthermore, it is essential that the biosecurity on poultry flocks should be improved to prevent the introduction and dissemination of MDV. We believe that the presence of MDV in this region represents a serious threat to many avian species due to its wide spectrum of target hosts and may include not only commercial birds but also ornamental birds, pets, and free-living birds. Due to the absence of a vaccine or treatment against MDV, it is very important to ascertain its origin through monitoring so that measures for eradication and prevention must be taken. In addition, Marek's disease is associated with large economic losses in poultry and can be supplied with pathogenic viruses from the backyard chicken flocks as the presented strain.

Finally, the importance of this study highlights the MDV detection into this region and provide molecular clues for future research about these viruses.

Acknowledgments

The authors would like to acknowledge from the staff of department of Veterinary Pathology and poultry diseases, University of Basrah for providing the support and facility for carrying out the research work.

Funds statement

This work was financial supported by the College of Veterinary Medicine, University of Basrah, Ministry of Higher Education and Scientific Researches, Republic of Iraq.

Ethical consideration

This study was carried out in accordance to the ethical rules for samples handling and animal's managements and researches, College of Veterinary Medicine, University of Basrah, Ministry of Higher Education and Scientific Researches, Republic of Iraq.

Conflict of interest

The authors declare that they have no competing interests.

References

1. Guy, J.S., Bagust, T.J., Saif, Y.M., Barnes, H.J., Fadly, A.M., Glisson, J.R., and Swayne, D.E. Laryngotracheitis in Diseases of poultry. Iowa State University Press: Ames, IA, 121-134(2003).
2. Churchill, A.E., and Biggs, P.M. Agent of Marek's disease in tissue culture. *Nature*, **215**, 510-528(1967).
3. Churchill, A.E., Payne, L.N., and Chubb, R.C. Immunization against Marek's disease using a live attenuated virus. *Nature*, **221**(5182), 744-747(1969).
4. Othman, I., and Aklilu, E. Marek's disease herpesvirus serotype 1 in broiler breeder and layer chickens in Malaysia, *Veterinary World*, **12**(3), 472-476(2019).
5. Baigent, S.J., and Davison, F. Marek's disease virus: biology and life cycle. In *Marek's Disease* (pp. 62-ii). Academic Press (2004).
6. Davidson, I., Borovskaya, A., Perl, S., and Malkinson, M. Use of the polymerase chain reaction for the diagnosis of natural infection of chickens and turkeys with Marek's disease virus and reticuloendotheliosis virus. *Avian Pathology*, **24**(1), 69-94(1995).
7. Lawhale, N.S., Singh, A., Deka, D., Singh, R., and Verma, R. Detection of Marek's disease virus meq gene in feather follicle by loop-mediated isothermal amplification. *IOSR J. Agric. Vet. Sci.*, **7**(3), 19-24(2014).
8. Gimeno, I.M. Marek's disease vaccines: a solution for today but a worry for tomorrow?. *Vaccine*, **26**, C31-C41(2008).
9. Davis, M.F., and Morishita, T.Y. Poultry necropsy basics. Columbus: Ohio State University Extension Factsheet(2001).
10. Luna, L.G. Manual of histologic staining methods of the Armed Forces Institute of Pathology(1968).
11. Handberg, K.J., Nielsen, O.L., and Jorgensen, P. H. The use of serotype 1-and serotype 3-specific polymerase chain reaction for the detection of Marek's disease virus in chickens. *Avian Pathology*, **30**(3), 243-249(2001).
12. OIE. Marek's Disease. OIE Manual of diagnostic tests and vaccines of terrestrial animals. Office International des Epizootics (OIE), Paris, France. pp. 1-11(2010).

13. Abdul-Careem, M.F., Read, L.R., Parvizi, P., Thanthrige-Don, N., and Sharif, S. Marek's disease virus-induced expression of cytokine genes in feathers of genetically defined chickens. *Developmental & Comparative Immunology*, **33**(4), 618-623(2009)..
14. Liu, L., Qu, Y., Wang, T., Wang, G., Wang, F., and Liu, S. Skin involvement in lymphomas caused by Marek's disease virus infection in Silkie chickens. *Journal of Veterinary Diagnostic Investigation*, **26**(2), 302-307(2014)..
15. Demeke, B., Jenberie, S., Tesfaye, B., Ayelet, G., Yami, M., Lamien, C.E., and Gelaye, E. Investigation of Marek's disease virus from chickens in central Ethiopia. *Tropical Animal Health and Production*, **49**(2), 403-408(2017).
16. Gall, S., Körösi, L., Cortes, A.L., Delvecchio, A., Prandini, F., Mitsch, P., and Gimeno, I.M. Use of real-time PCR to rule out Marek's disease in the diagnosis of peripheral neuropathy. *Avian Pathology*, **47**(4), 427-433(2018)..
17. Doosti, A., and Golshan, M. Molecular study for detection of Marek's disease virus (MDV) in southwest of Iran. *Scientific Research and Essays*, **6**(12), 2560-2563(2011)..
18. Biggs, P.M., and Nair, V. The long view: 40 years of Marek's disease research and Avian Pathology. *Avian Pathology*, **41**(1), 3-9(2012)..
19. Balachandran, C., Pazhanivel, N., Vairamuthu, S., and MuraliManohar, B. Marek's disease and lymphoid leucosis in chicken—a histopathological survey. *Tamilnadu J. Vet. Anim. Sci.*, **5**(4), 167-170(2009).
20. Gimeno, I.M., Witter, R.L., Hunt, H.D., Lee, L.F., Reddy, S. M., and Neumann, U. Marek's disease virus infection in the brain: virus replication, cellular infiltration, and major histocompatibility complex antigen expression. *Veterinary Pathology*, **38**(5), 491-503(2001).
21. Heidari, M., Fitzgerald, S.D., Zhang, H.M., Silva, R.F., Lee, L.F., and Dunn, J.R. Marek's disease virus-induced skin leukosis in scaleless chickens: tumor development in the absence of feather follicles. *Avian Diseases*, **51**(3), 713-718(2007).
22. Cui, N., Su, S., Sun, P., Zhang, Y., Han, N., and Cui, Z. Isolation and pathogenic analysis of virulent Marek's disease virus field strain in China. *Poultry Science*, **95**(7), 1521-1528(2016).
23. Raja, A., Dhinakar, R.G., Bhuvaneswari, P., Balachandran, C., and Kumanan, K. Detection of virulent Marek's disease virus in poultry in India. *Actavirologica*, **53**(4), ID:255(2009).
24. Cao, W., Mays, J., Dunn, J., Fulton, R., Silva, R., and Fadly, A. Use of polymerase chain reaction in detection of Marek's disease and reticuloendotheliosis viruses in formalin-fixed, paraffin-embedded tumorous tissues. *Avian Diseases*, **57**(4), 785-789(2013).
25. Jarosinski, K.W., Margulis, N.G., Kamil, J.P., Spatz, S.J., Nair, V.K., and Osterrieder, N. Horizontal transmission of Marek's disease virus requires US2, the UL13 protein kinase, and gC. *Journal of Virology*, **81**(19), 10575-10587(2007).

دراسة سريرية ومرضية وجزيئية لمرض مارك في الدجاج المحلي ودجاج براهما في محافظة البصرة ، العراق.

عصام عزيز خليفة وحاتم عبدالله نجم

قسم الامراض وامراض الدواجن - كلية الطب البيطري - جامعة البصرة - العراق.

أجريت الدراسة الحالية لرصد الإصابة بمرض مارك في دجاج *Gallus gllus* الداجنة ودجاج *Brahma* في مناطق مختلفة من محافظة البصرة ، العراق ، كانت الدراسة الحالية تعتمد على الفحص السريري ، التشريح المرضي بعد الوفاة، والدراسة النسيجية المرضية وتفاعل سلسلة البلمرة (PCR). حيث سجلت نتائج الدراسة الحالية المرض في الدجاج المحلي (*Gallus gallus*) ودجاج البراهما (*Brahma chickens*). تم رصد الإصابة بمرض مارك في مناطق مختلفة من محافظة البصرة (العيادات البيطرية والأسواق والعيادة الاستشارية للطب البيطري بجامعة البصرة). أظهرت الحالة السريرية الموجبة في بعض الطيور التي ظهرت عليها علامات سريرية كبيرة للاشتباه بمرض مارك (MD) ، حيث كان الطير على شكل المروحة. أظهر الفحص للتشريح المرضي بعد الوفاة آفات مختلفة وفقاً لأنواع الدجاج. في الدجاج المحلي ، كانت التغيرات العيانية في العصب الوركي تتميز بتضخم العصب الوركي. كما لوحظ تضخم الطحال وتضخم الكبد مع العقيدات بالإضافة إلى تضخم حويصلات الريش. في دجاج البراهما لا توجد آفات واضحة في الأعضاء الحشوية بينما تظهر تضخم العصب الوركي فقط. حيث كانت التغيرات النسيجية في الطحال مثل النخر وتضخم في الشريين المركزي لللب الأبيض. كذلك اظهرت التغيرات المعوية هي ارتشاح الخلايا أحادية النواة في الزغابات وتقرش البطانة الظهارية للزغابات. في الدماغ لوحظ وذمة حول العصب (محيط العصب) وتوسع ملحوظ في الأوعية الدموية العصبية. أظهر العصب الوركي سائلاً ودمياً في متن العصب وارتشاح الخلايا الالتهابية أحادية النواة بشكل رئيسي الخلايا الليمفاوية في متن الأعصاب (النسيج الحشوي) ولوحظ في حويصلة الريش تشكل الفجوات ملحوظ للطبقة الظهارية وكذلك ارتشاح الخلايا الالتهابية في بطانة البصيلات. التشخيص المؤكد كان عن طريق اختبار PCR. حيث أظهرت نتائج تفاعل البوليمر المتسلسل (PCR) أن العينات الموجبة الكلية لطيور (MDV-1) بواسطة تفاعل سلسلة البلمرة (PCR) كانت تسع عينات في المرة الأولى التي سجلت في البصرة. كانت أربع عينات موجبة من الطحال وعينة موجبة من بصيلات الريش وكذلك أربع عينات موجبة من العصب الوركي، تم التوصل إلى أن MDV هو المسبب لهذه الحالة المرضية في قطعان الدواجن العراقية. هذا هو أول تقرير عن وجود MDV في *Brahma* و *Gallus gllus* في العراق. وعليه ، فإن الطيور الداجنة التجارية في العراق ليست بعيدة عن تهديد MDV ، وهناك حاجة إلى مراقبة MDV.