

The Utility of P53, P63, P57 and Ki67 Immunohistochemistry in the Differentiation between Hydropic Abortion and Molar Pregnancy (Immunohistochemical Study)

Salah-el-din Sayed Semaary¹, Al-Sayed A. Abd-Elrahman², Mhammed Hafez Mohammed³

1. Department of Pathology, Faculty of Medicine, Al-Azhar University, Damietta.

2. Department of Anatomy and Embryology, Faculty of Medicine, Port Said University, Egypt.

3. Department of Obstetrics and Gynecology, Faculty of Medicine, Port Said University, Egypt.

*Corresponding Author: Salah-el-din Sayed Semaary, E-mail: drsalahsemaary@yahoo.com

ABSTRACT

Background: The classification of molar pregnancies into complete and partial hydatidiform moles and the differentiation from hydropic abortions are usually accomplished by histomorphologic features alone, but sometimes may be inaccurate or inconclusive. Immunohistochemical (IHC) staining techniques have been reported as a good diagnostic method complementary to the histologic diagnosis. One of the advantages of the IHC techniques is the ability to apply it retrospectively to sections of formalin fixed/paraffin embedded tissue and therefore, there is no need for expensive or sophisticated techniques. **Aim of the Work:** This study aimed to determine if immunohistochemical expression of p53, p63, p57 and Ki67 could aid in differentiating molar from non molar pregnancies on one hand and partial mole from complete mole on the other hand. **Materials and Methods:** A total of 180 placental specimens were enrolled in this study including 60 non molar placental specimens with hydropic changes (HA) and 120 molar specimens (60 complete hydatidiform moles (CHMs) and 60 partial hydatidiform moles (PHMs). The studied cases were examined histologically and immunohistochemically for expression of p53, p63, p57 and Ki67. **Results:** There was a significant difference in p57 expression between HA and PHM (P value < 0.05), HA and CHM (P value < 0.0001) and also between PHM and CHM (P value < 0.003). There was a significant difference in Ki67 expression between HA and PHM (P value < 0.03), PHM and CHM (P value < 0.01) and between HA and CHM (P value < 0.009). There was no significant difference in P63 expression between HA and PHM (P value > 0.8), PHM and CHM (P value > 0.5), and also between HA and CHM (P value > 0.2). A significant difference in p53 expression between HA and CHM (P value < 0.005) was noted and also between PHM and CHM (P value < 0.007), while no significant difference between HA and PHM in expression of p53 (P value > 0.8).

Keywords: Hydropic abortion, Molar pregnancy, Immunohistochemistry.

INTRODUCTION

Although morphologic features are often adequate to differentiate hydropic abortions from molar gestations, early hydropic abortions may exhibit atypical trophoblastic proliferation and pronounced hydropic swelling that can be occasionally confusing, leading to an erroneous diagnosis of hydatidiform mole (HM) ⁽¹⁾. Furthermore, the most reliable feature of molar gestation, the presence of macroscopically identifiable large hydropic vesicles, is only seen in the second trimester of gestation ⁽²⁾. The recent trend toward ultrasonography in early pregnancy has resulted in evacuation of hydatidiform moles at earlier stages before development of the usually recognized diagnostic criteria, i.e., trophoblastic hyperplasia and cistern formation ⁽³⁾. Even very experienced pathologists have problems in differentiating some PHM from CHM because the degree of trophoblastic proliferation and the proportion of hydropic villi vary in both conditions ⁽⁴⁾. Because hydropic degeneration occurs in 15% to 40% of nonmolar spontaneous abortion, some of

these conceptuses could be confused with PHM ⁽⁵⁾. About 8% to 30% of patients with complete hydatidiform mole need chemotherapy after evacuation for persistent trophoblastic disease and 0.6% - 1.5% of patients will have a recurrent molar pregnancy ⁽⁶⁾. With partial molar pregnancy, the risk of persistent trophoblastic disease is much lower than in cases of a complete mole and only about 5% of patients with partial mole require chemotherapy after evacuation ⁽⁷⁾. The risk of choriocarcinoma in complete hydatidiform mole is about 10%-30% and in partial hydatidiform mole is about 0.5%-5% ⁽⁸⁾. Several immunohistochemical markers have been studied for this differential diagnosis and one of these markers is p57 gene, which is a cyclin-dependent kinase inhibitor located on chromosome 11p15.5 ⁽⁹⁾. It is strongly paternally imprinted and expressed predominantly from maternal allele in most tissues ⁽¹⁰⁾. P57 expression is markedly reduced or absent in CHM compared to strong expression in both PHM and HA, so, it is diagnostic of CHM but helpless in differentiation between PHM and HA ⁽¹¹⁾. Ki-67 labeling index in cytotrophoblastic cells could be helpful in differentiation between abortion and

molar pregnancy. Furthermore, immunohistochemical analysis of p53 and p63 expressions has been proposed as a potential diagnostic tool to discriminate between HA and hydatidiform moles (12).

AIM OF THE WORK

This study was aimed to determine if immunohistochemical expression of p53, p63, p57 and Ki67 could aid in differentiating molar from non molar pregnancies on one hand and partial mole from complete mole on the other.

PATIENTS AND METHODS

A total of 180 cases (60 complete moles, 60 partial moles and 60 hydropic non molar placentas) were enrolled in this study and examined histologically and immunohistochemically for expression of p53, p63, p57 and Ki67. These cases were obtained from the Department of Pathology and Hospitals of Al Azhar University during the period from January 2017 to April 2018. These cases were both retrospective (150 cases) and prospective (30 cases). The cases were either obtained by evacuation (130 specimens) or hysterectomy (50 specimens). The clinical data and pathological records were retrieved from the files of the patients. **The study was approved by the Ethics Board of Al-Azhar University.** 4 micron thick sections were cut from formalin fixed/paraffin embedded blocks of all specimens and stained with hematoxylin and eosin (H&E) and histologically evaluated. Paraffin sections that showed abundant decidual tissue, blood clots or abundant necrotic tissue were omitted. The diagnosis of molar pregnancy was based on the pathologic criteria of **Buza and Hui** (9). The criteria for a diagnosis of CHM were as follows: total hydatidiform change from edema to central cistern formation, absence of embryo and conspicuous trophoblastic hyperplasia. The criteria for a diagnosis of PHM were as follows: partial villous involvement (normal and edematous villi), presence of embryo or fetus, focal moderate trophoblastic hyperplasia and trophoblastic inclusion or prominent villous scalloping. The histologic criteria of hydropic abortion (HA) including villous oedema with minimal to no cistern formation and mild trophoblastic hyperplasia, villi may be a vascular or fibrosed or showed residual vessels and contained nucleated fetal RBC, intermediate trophoblastic clumps and fibrin were common. Lack of cisterns larger than 3mm and presence of polar trophoblast

were essential features in differentiating PHM from simple hydropic abortion. **Immunohistochemical Technique:** Immunohistochemical staining was performed in all cases using p57 (clone 57P06 at 1:100 dilution; NeoMarkers, Fremont, CA), P63 (rabbit polyclonal at 1:50 dilution; NeoMarkers, Fremont, CA), p53 (clone DO-1 at 1:100 dilution; NeoMarkers, Fremont, CA) and Ki67 (rabbit polyclonal at 1:100 dilution; NeoMarkers, Fremont, CA). Positive control for P57 was normal human placenta, while normal prostatic tissue served as an external positive control for P63, squamous cell carcinoma for p53 and sections from a tonsil known to be positive for Ki-67 served as positive controls for Ki-67 protein staining. All the negative controls (omitting of primary antibody step) were included in each run of staining. For immunohistochemical assay, four sets of 4 µm thick sections were taken on four sialinized slides (positive charged, Optiplus, BioGenex, Ca, USA), incubated overnight at 55°C, dewaxed in xylene and rehydrated in graded alcohols. Antigen retrieval was achieved by heating slides at 95°C for 10-20 minutes in 0.1 mol/L citrate buffer (pH 6) using water bath. After cooling the sections at room temperature, endogenous peroxidases were quenched with 0.3 % H₂O₂ in water. From each case, 4 slides were obtained and the antibodies p57, ki67, p63, p53 (as previously mentioned) were added to them overnight. Standard avidin-biotin-horseradish peroxidase complex was used to detect antigen-antibody reactions. Positive staining was seen with 0.3 % 3,3-diaminobenzidine. **Interpretation of Immunohistochemical Results:** A colored precipitate at sites of specific cellular antigen localization indicated a positive reaction. DAB gave positive immunostaining which appeared as brownish coloration. The results were interpreted in light of the appropriate staining of all positive and negative controls, compared to H&E-stained slides. All p57, p63, p53 and ki67 positivity were nuclear, while cytoplasmic staining considered non-specific. **Scoring of Immunostaining:** Each antibody was scored independently. According to **Gupta et al.** (13), p57 immunopositivity was interpreted as negative and satisfactory when maternal decidua / intermediate trophoblastic cells exhibited nuclear expression of p57 (serving as internal positive control), but villous stromal cells and cytotrophoblast were either entirely negative or demonstrated only limited expression (nuclear staining in <10% of these cell types). The p57 immunoreactivity was interpreted as positive

when the extent of staining is extensive or diffuse in these cell types. The staining of p63 was quantitatively assessed according to Masood *et al.* (14) as negative (no nuclear staining seen), 1+ (<10% positive nuclear staining), 2+ (10 - 50% nuclear staining) and 3+ (>50% nuclear staining). According to Erol *et al.* (15), the distribution of p53 immunoreactivity were quantitatively assessed as -ve ($\leq 10\%$ are positive cells) and +ve ($>10\%$ are positive cells) and the positive cases were graded as: + (10 - 20% positive cells), ++ (20-50%), and +++ (> 50% positive cells). Immunoreexpression of ki67 was analyzed according to Khooei *et al.* (16) for villous cytotrophoblasts and stromal cells, commenced from the field with most staining. Positive immunoreactivity was graded as weakly positive (1+) - (< 20%), moderately positive (2+) - (21-50%) and strongly positive (3+) - (>50%). **Statistical Analysis:** the data of this study were evaluated and summarized as frequency and percentage (qualitative data) or as mean \pm standard deviation (SD) (numerical data). Statistical analysis was done using SPSS V22. Chi-square test (Fisher's test) was used to examine relationship between qualitative variables, while for quantitative data not normally distributed. Mann-Whitney test was used. P-value of <0.05 was considered statistically significant.

RESULTS

The mean age of the patients was 29.2 years with a minimum of 17 years and a maximum of 51 years. As regard to the incidence of molar gestations in this study, the age distribution of molar pregnancies was 17-51 years with most of the patients were found to be above 40 years age group (48%) and the second commonest age group was between 17-21 years (32%), while the remaining 20% of molar pregnancies was found in 25-32 years age group. After evaluation of the histological features, 60 patients (33.3%) were considered to have hydropic abortion (Figs. 1, 2), 60 cases of partial molar pregnancy (33.3%) (Fig. 3) and 60 cases with complete mole (33.3%) (Figs. 4, 5). **Results of p57 immunostaining:** All the cases were evaluated for expression of p57 immunostaining. Among 60 cases of HA, 58 cases (96.7%) showed a positive expression for p57 (Fig. 7) while 2 cases showed immunonegativity (3.3%). Among 60 cases of PHM, 52 cases (86.7%) showed immunopositivity (Fig. 8), while 8 cases (13.3%) were negative. The majority of cases diagnosed as

CHM (58/60) were negative for p57 (96.7%) (Fig. 6) and only 2 cases were positive for p57. There was a statistically significant difference in p57 expression between HA and PHM (P value < 0.05), HA and CHM (P value < 0.0001) and also between PHM and CHM (P value < 0.003).

Table 1: Results of P57 immunoreactivity in the studied groups

	% of positive cells	HA		PHM		CHM	
		60 cases		60 cases		60 cases	
		No.	%	No.	%	No.	%
Negative	<10%	2	3.3%	8	13.3%	58	96.7%
Positive	$\geq 10\%$	58	96.7%	52	86.7%	2	3.3%
Total		60	100%	60	100%	60	100%

Results of Ki67 immunostaining: All the cases were evaluated for expression of Ki67 immunostaining and assessment of nuclear staining was performed in an area of maximal intensity of staining and then in contiguous fields. All cases (100%) of HA showed weak positive expression (of score 1+) for ki67. In PHM, 24 cases (40%) out of 60 cases showed weak positivity (1+ score) (Fig. 9), while the remaining 36 cases (60%) showed a moderate reactivity (2+ score). The expression of ki67 in the 60 cases of CHM showed weak positivity (1+ score) in 4 cases (6.7%), moderate positivity (2+ score) in 24 cases (40%) and marked positivity (3+) in 32 cases (53.3%) (Fig.10). There was a statistically significant difference in Ki67 expression between HA and CHM (P value < 0.009), PHM and CHM (P value < 0.01), and between HA and PHM (P value < 0.03).

Table 2: Results of Ki 67 immunoexpression in the studied groups

	% of positive cells	HA		PHM		CHM	
		60 cases		60 cases		60 cases	
		No.	%	No.	%	No.	%
Negative	0%	0	0%	0	0%	0	0%
Weak positivity (+)	<20	60	100%	24	40%	4	6.7%
Moderate positivity (++)	21-50%	0	0%	36	60%	24	40%
Marked positivity (+++)	>50%	0	0%	0	0.00%	32	53.3%
Total		60	100%	60	100%	60	100%

Results of P63 immunostaining: The expression of P63 immunostaining was assessed in all cases. P63 immunoreactivity was only seen in

cytotrophoblast cells. The syncytiotrophoblast cells were negative for p63. Among the 60 cases of HA, 10 cases (16.7%) showed a mild positive expression for p63, 44 cases (73.3%) showed moderate reactivity (Figs. 11, 12) and the remaining 6 cases (10%) showed marked reactivity. In PHM, 4 cases (6.7%) out of 60 cases showed mild reactivity, 52 cases (86.6%) showed a moderate reactivity (Fig. 13) and the remaining 4 cases (6.7%) showed marked reactivity. Among the 60 cases of CHM, the expression of p63 showed mild reactivity in 6 cases (10%), moderate reactivity in 40 cases (66.7%) and marked reactivity in 14 cases (23.3%) (Fig. 14). There was no significant difference in P63 expression between HA and PHM (P value > 0.8), HA and CHM (P value > 0.2) and also between PHM and CHM (P value > 0.5) (Table 3).

Table 3: Results of P63 immunorexpression in the studied groups

Reactivity	% of positive cells	HA		PHM		CHM	
		No.	%	No.	%	No.	%
Negative	0%	0	0%	0	0%	0	0%
Mild: (+)	<10	10	16.6%	4	6.7%	6	10%
Moderate: (++)	10-50%	44	73.3%	52	86.6%	40	66.7%
Marked: (+++)	>50%	6	10%	4	6.7%	14	23.3%
Total		60	100%	60	100%	60	100%

Results of P53 immunostaining: All the studied cases were assessed for expression of P53 immunostaining. P53 immunoreactivity was found in the nucleus of villous cytotrophoblasts, whereas villous intermediate trophoblasts and villous syncytiotrophoblasts showed negative immunostaining. The majority of cases of HA (58 cases & 96.6%) showed negative expression for p53 (Fig. 15), while only 2 cases (3.3%) showed mild expression. Among the 60 cases of PHM, 54 cases (90%) were negative for p53 (Fig. 16), while the remaining 6 cases (10%) showed a mild reactivity (Fig. 17). Out of the 60 cases of CHM, 6 cases (10%) showed immunonegativity for P53, 6 cases (10%) showed mild immunoreactivity, 12 cases (20%) showed moderate reactivity and the remaining 36 cases (60%) showed marked immunoreactivity (Fig. 18). There was a statistically significant difference in p53 expression between HA and CHM (P value < 0.005) and also between PHM and CHM (P value < 0.007), while

no significant difference was observed between HA and PHM (P value > 0.8).

Table 4: Results of P 53 immunorexpression in the studied groups:

Reactivity	% of positive cells	HA		PHM		CHM	
		No.	%	No.	%	No.	%
Negative	<5 %	58	96.6%	54	90 %	6	10 %
Mild: (+)	5-25	2	3.3%	6	30 %	6	10%
Moderate: (++)	26-50%	0	0%	0	0%	12	20 %
Marked: (+++)	>50%	0	0%	0	0%	36	60%
Total		60	100%	60	100%	60	100%

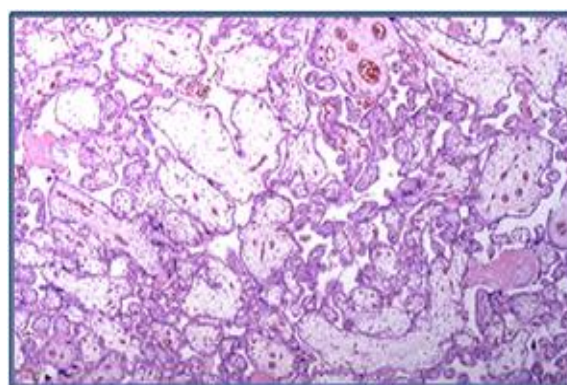


Figure 1: Section from a case of hydropic abortion showing mild enlargement and edema of some chorionic villi with no evidence of trophoblastic hyperplasia (H&E X 100).

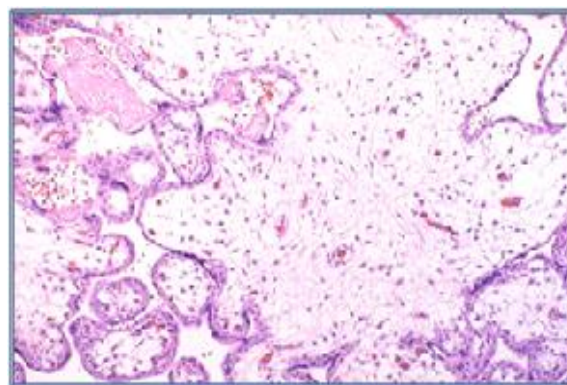


Figure 2: Section from hydropic abortion showing enlargement of the chorionic villi with abundant edematous stroma covered by bilayered trophoblastic cells and showing vessels within the chorionic villi (H&E X 200).

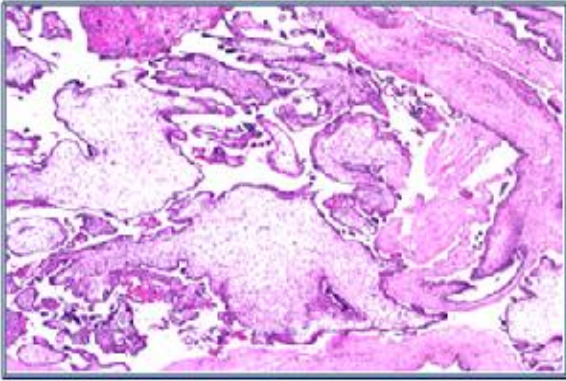


Figure 3: Section from a case of partial mole showing an admixture of normal-appearing and vesicular villi with irregular, scalloped outline (H&E X 200).

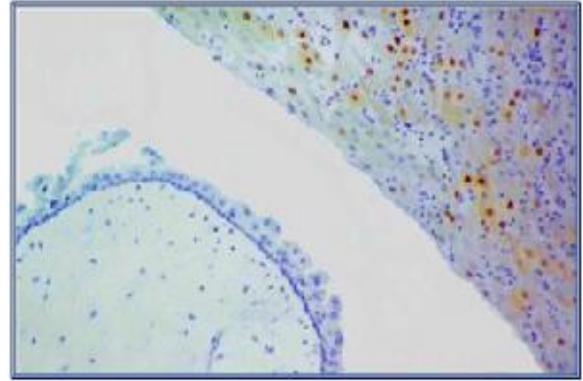


Figure 6: A case of complete vesicular mole showing immunonegativity to P57 antibody in the villous cytotrophoblasts and stromal cells, but decidual cells showing immunopositivity (DAB, original magnification x200 & counterstained with Hx.).

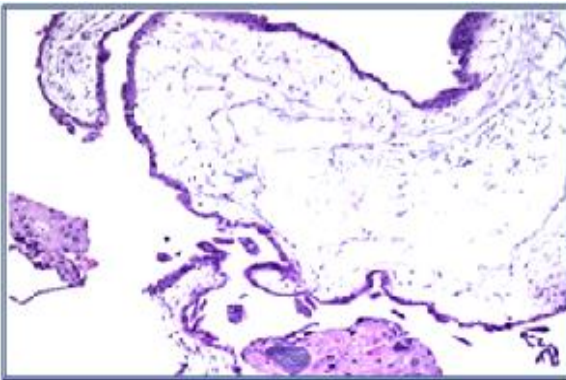


Figure 4: Section from a case of complete mole showing a large edematous villus with formation of a cistern and focal trophoblastic proliferation (H&E X 200).




Figure 7: A case of hydropic abortion showing diffuse, strongly positive nuclear immunoreactivity to P57 antibody in the villous cytotrophoblasts (DAB, original magnification x 400 & counterstained with Hx.).

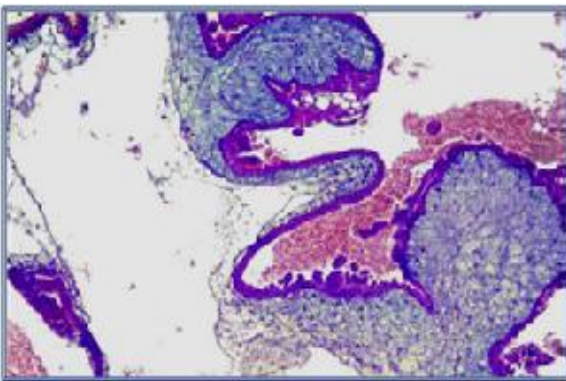


Figure 5: A case of complete vesicular mole showing markedly enlarged villous with extensive edema and cisternae formation. (H&E with alcian blue x150).

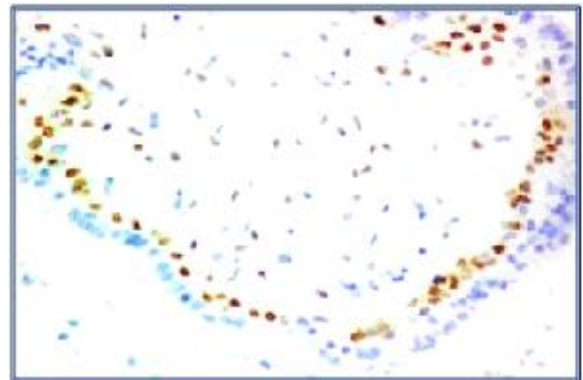


Figure 8: A case of partial vesicular mole showing diffuse and moderate immunopositivity for P57 in the villous cytotrophoblasts (DAB, original magnification x 400 & counterstained with Hx.).

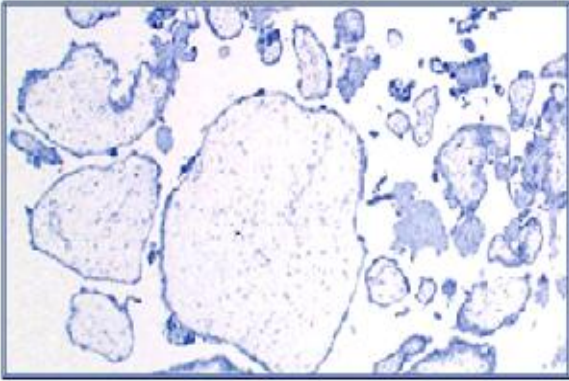


Figure 9: Section from a case of partial hydatidiform mole showing focal weak Ki-67 immunoreactivity (DAB x 200 & counterstained with Hx.).

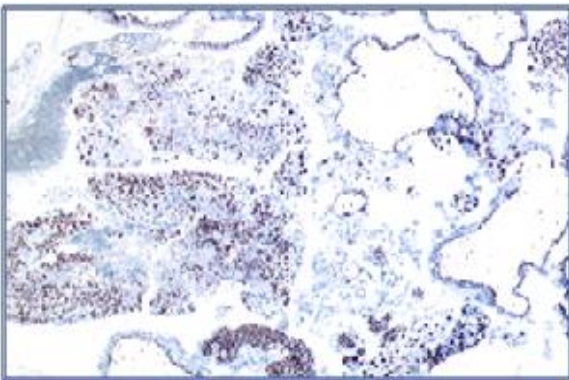


Figure 10: Section from a case of complete hydatidiform mole showing diffuse and marked Ki-67 immunoreactivity (DAB, original magnification x 100 & counterstained with Hx.).

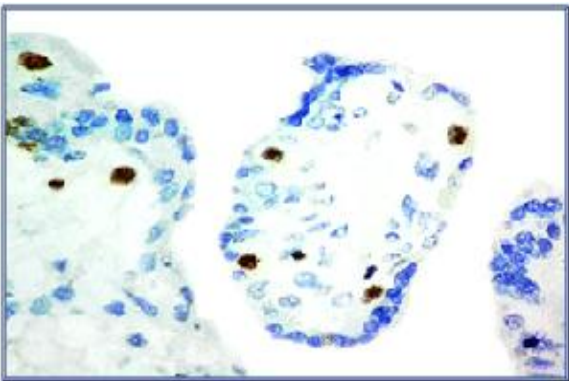


Figure 11: A case of hydropic abortion showing focal and moderate nuclear immunopositivity for P63 antibody in villous cytotrophoblasts and stromal cells (DAB, original magnification x 400 & Counterstained with Hx.).

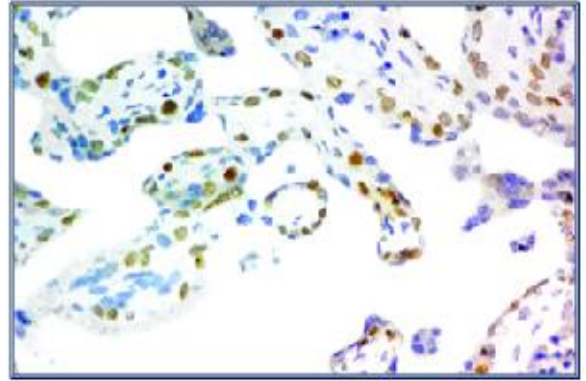


Figure 12: A case of hydropic abortion showing diffuse and moderate nuclear immunopositivity to P63 antibody in the villous cytotrophoblasts and stromal cells (DAB, x 400 & counterstained with Hx.).

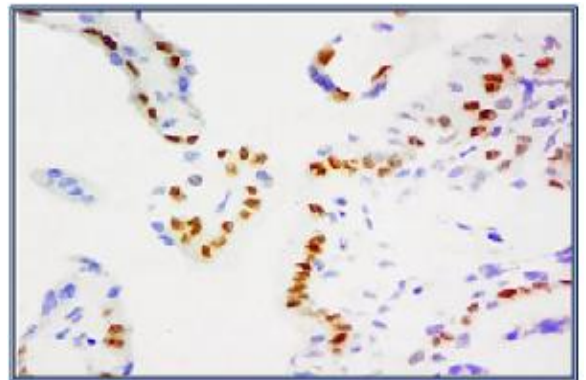


Figure 13: A case of partial vesicular mole showing diffuse and moderate nuclear immunopositivity to P63 antibody in the villous cytotrophoblasts (DAB, original magnification x 400 & counterstained with Hx.).

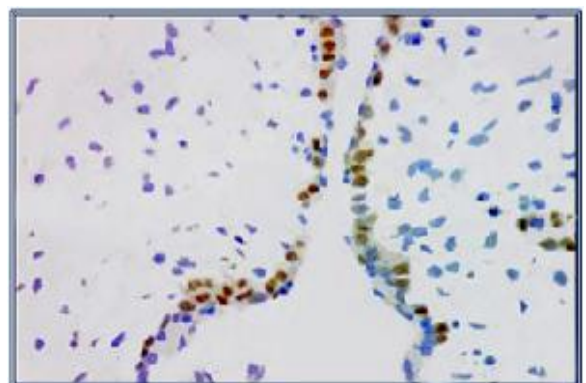


Figure 14: A case of complete vesicular mole showing strong and diffuse nuclear immunopositivity to P63 antibody in the villous cytotrophoblasts and scattered stromal cells (DAB, original magnification x 400 & counterstained with Hx.).

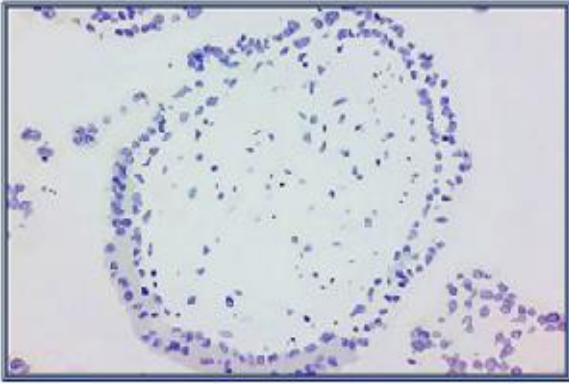


Figure 15: A case of hydropic abortion showing immunonegativity to P53 antibody in all villous cell components (DAB, original magnification x 200 & counterstained with Hx.).

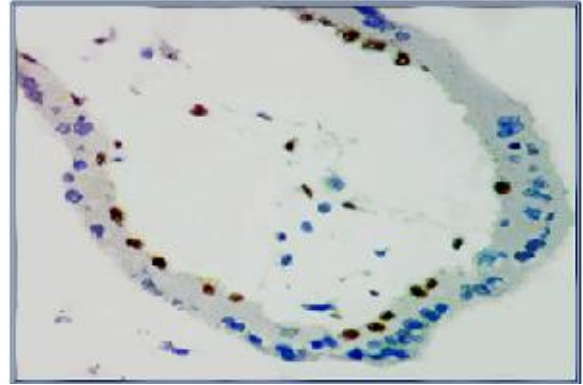


Figure 18: A case of complete mole showing strong nuclear immunopositivity to P53 antibody in the villous cytotrophoblasts and scattered stromal cells (DAB, original magnification x 400 & counterstained with Hx.).

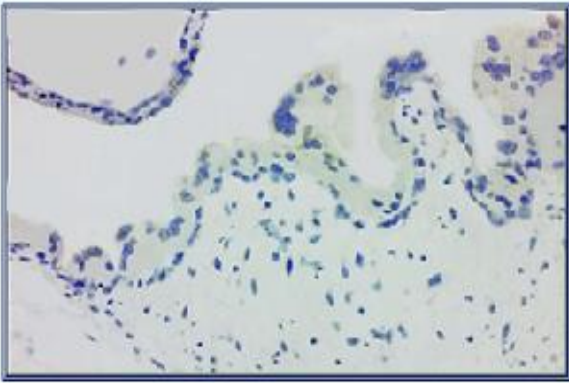


Figure 16: A case of partial mole showing nuclear immunonegativity to P53 antibody in the villous cytotrophoblasts and stromal cells (DAB, original magnification x 400 & counterstained with Hx.).

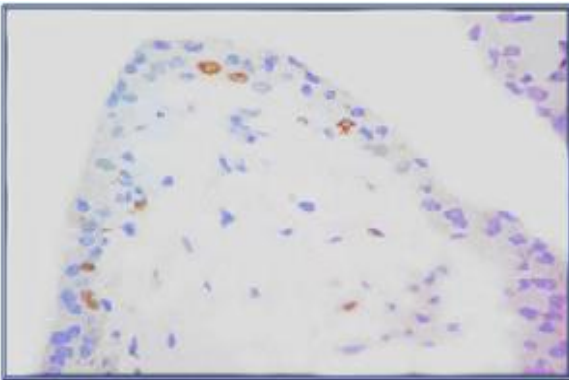


Figure 17: A case of partial mole showing focal mild nuclear immunoreactivity to P53 antibody in the villous cytotrophoblasts (DAB, original magnification x 400 & counterstained with Hx.).

DISCUSSION

Histopathological criteria that are used in the diagnosis of hydropic abortions, partial moles and complete moles are helpless in some problematic cases especially that the treatment is different in each diagnosis. The immunohistochemical staining is a very effective method in the diagnosis of androgenetic complete mole and differentiates it from partial mole and hydropic abortion⁽¹⁷⁾. As regard to the incidence of molar gestations in this study, the age distribution of molar pregnancies was 17-51 years with most of the patients were found to be above 40 years age group (48%) and the second commonest age group was between 17-21 years (32%). **Lurain**⁽¹⁸⁾ found that advanced or very young maternal age was consistently correlated with higher rates of CHMs. Also, **Nizam et al.**⁽¹⁷⁾ demonstrated that the maternal age has an influence on the incidence of molar gestations and there was an excess of molar pregnancies in the extremes of reproductive age. Several studies have demonstrated the importance of histology and other techniques to reach an accurate diagnosis in molar gestations⁽¹²⁾. Ancillary techniques included immunohistochemical staining of p57, p63, p53, ki67. In our study, we aimed to determine the most reliable protocol able to achieve the optimal diagnosis in these complicated conditions. P57 is a paternally imprinted gene and its expression is associated with the presence of maternal DNA which is present in cases of hydropic abortion and partial mole while absent in complete mole⁽¹⁹⁾. In the present study, almost all cases of CHMs (58/60) were p57-negative while almost all cases of HA

(58/60) and majority of PHM (52/60) exhibited p57 immunopositivity. **Banet *et al.***⁽²⁰⁾ studied p57 expression and molecular genotyping in a large series of molar specimens (678 cases) and reported similar results to this study. Also, **Shigeru *et al.***⁽²¹⁾ stated that p57 immunostaining alone can identify complete mole by its negative expression. **Shigeru *et al.***⁽²¹⁾ demonstrated that CHMs were always p57 negative and only rare occasions (0.5%) display aberrant positivity due to retention of the maternal copy of chromosome. The same authors also reported that partial moles are almost always p57-positive with rare occasions (1.3%) display aberrant negativity due to loss of maternal copy of chromosome. Also, the same study showed that most of non-molar gestations (264/272) were p57-positive and the authors concluded that p57 expression is highly correlated with genotyping results and serves as a reliable marker for diagnosis of CHMs with very little risk of misclassification. **Jose *et al.***⁽²²⁾ demonstrated that p57 immunostaining alone can identify complete mole by its negative expression, because of the lack of maternal DNA, but this analysis cannot distinguish partial mole from non-molar specimens as both express p57 (because of the presence of maternal DNA). **Maggiori and Peres**⁽²³⁾ demonstrated that P57 immunostaining provides a highly reliable method for accurately diagnosing complete mole in routine practice by using a single immunohistochemical stain with very little risk of misclassification of complete mole, and consequently, other methods as genotyping for diagnosis of complete mole is not necessary in routine practice and can be reserved for problematic cases, such as when p57 immunostaining is suboptimal or unsatisfactory or when there is a discrepancy between morphology and p57 results. Our study demonstrated the high capability of Ki67 staining and its index to differentiate between molar and non-molar placentas. As regard to Ki-67 immunoexpression in this study, the Ki-67 labeling index in cytotrophoblastic cells significantly differed between the molar and non-molar specimens, as well as between complete and partial moles. Among 60 cases of partial hydatidiform mole, 24 cases (40%) showed weak intensity (score 1+) of Ki-67 immunoexpression and 36 cases (60%) showed 2+ intensity. Among the 60 cases of complete hydatidiform mole, the 2+ intensity of

Ki-67 immunoexpression was found to be (40%) of cases (24/60) and 53.3% of cases (32/60) showed 3+ intensity while the remaining 6.7% of cases (4/60) showed 1+ intensity of Ki-67 immunoexpression. All the cases of HA (100%) showed weak intensity of Ki-67 immunoexpression (score 1+). So, in the current study, highest proliferative activity of Ki-67 ($\geq 50\%$ of Ki-67 labeling index) was found in complete hydatidiform mole. Similar results were reported by previous study⁽²³⁾. **Hasanzadeh *et al.***⁽²⁴⁾ concluded that proliferative activity is an additional useful parameter for evaluation of molar pregnancies and hydropic changes, with Ki-67 staining allowing better separation among the 3 groups. Also, **Khooei *et al.***⁽¹⁶⁾ demonstrated that Ki-67 immunoexpression shows variable intensities in different subgroups of hydatidiform mole by determining the labeling index (number of positive nuclei/total number of nuclei) in villous cytotrophoblasts, syncytiotrophoblasts and stromal cells, and concluded that Ki-67 labeling index of villous cells, especially cytotrophoblasts, is valuable in diagnosis and differentiation between different subgroups of molar pregnancies, being the highest in the complete mole ($>50\%$) followed by partial mole ($>20\%$). Our results were in contrast to the results reported by **Maggiori *et al.***⁽²³⁾, who found that Ki67 cannot reveal all proliferating cells in a reliable way, because the expression of Ki67 varies during the cell cycle and may not be expressed from G0 to G1, therefore, its tendency for being revealed by IHC is different. The same authors also found no difference between Ki67 levels in molar and normal placentas. **Erfanian *et al.***⁽²⁵⁾ reported that Ki-67 immunostaining differed significantly between the molar and non-molar placentas, but did not allow distinction of partial from complete hydatidiform moles. Conversely, **Chen *et al.***⁽²⁶⁾ reported that Ki-67 may be useful in separating complete moles from partial moles but not partial moles from hydropic abortions. Several studies have investigated the role of P63 in distinguishing molar from non-molar pregnancies, but the results were controversial. Some studies reported higher expression of this marker in hydatidiform mole whereas others reported similar expression in molar and non-molar pregnancies. In the present study, the utility of p63 in differentiating HA, PHM and CHM was investigated and showed no statistically significant

difference in distribution of P63 immunostaining between HA, PHM and CHM. These results were in agreement with other studies reported by **Heidarpour and Khanahmadi** ⁽²⁷⁾. In contrast to our results, **Erfanian et al.** ⁽²⁵⁾ evaluated the usefulness of p63 marker in differentiating HA from PHM and CHM and concluded that p63 labelling index was significantly higher in molar than non-molar pregnancy. Also, the evaluation of P63 intensity had been reported by **Masood et al.** ⁽¹⁴⁾ who demonstrated that it was much stronger in PHM and CHM than hydropic abortions. The same authors demonstrated that the evaluation of P63 intensity as other markers is doubtful and has inter-observer variability, so cannot depend on it as an accurate method for diagnosis. In addition to its pivotal roles in embryogenesis, several studies have revealed that overexpression of p53 is involved in the pathogenesis of gestational trophoblastic disease ⁽³⁶⁾. **Chen et al.** ⁽²⁶⁾ stated that the immunohistochemical analysis of p53 expression has been proposed as a potential diagnostic tool to discriminate HMs and HAs. As regard to P53 immunostaining in the current study, the majority of cases of HA (58/60 cases ~ 96.6%) showed negative expression for p53, while only 2 cases (3.3%) showed mild expression. Among the 60 cases of PHM, 54 cases (90%) were negative for p53, while the remaining 6 cases (10%) showed a mild reactivity. Out of the 60 cases of CHM, 6 cases (10%) showed immunonegativity for P53, 6 cases (10%) showed mild immunoreactivity, 12 cases (20%) showed moderate reactivity and the remaining 36 cases (60%) showed marked immunoreactivity. There is a statistically significant difference in p53 expression between HA and CHM (P value < 0.005), also between PHM and CHM (P value < 0.007), while no significant difference was noted between HA and PHM (P value < 0.8). **Rath et al.** ⁽²⁸⁾ reported increased expression of p53 in CHMs compared with PHMs with absence of expression in HA, however, only staining in the villous intermediate trophoblasts was considered for evaluation. In contrast to our results, **Chen et al.** ⁽²⁶⁾ reported a significantly higher p53 expression in PHMs than HAs, but that study compared the two entities with regard to the percentage of stained cells. **Uzunlar et al.** ⁽²⁹⁾ revealed absence of p53 protein expression in first trimester pregnancy trophoblast and p53 protein was occasionally detectable in the molar

trophoblastic tissue and this discrepancy may be due to the use of different antibody clones and retrieval methods.

CONFLICTS OF INTEREST

There are no conflicts of interest.

REFERENCES

1. **Tse KY and Ngan HY (2012):** Gestational trophoblastic disease. *Best Pract. Res. Clin. Obstet. Gynaecol.*, 26 (3):357-370.
2. **Singh Y, Singh L S, Singh L R, Liyak P and Vaz A (2016):** A study of molar pregnancy at tertiary centre of India. *Iosr. J. Med. Sci.*, 15 (9): 49–52.
3. **Fowler D J, Lindsay I and Seckl M J (2007):** Histomorphometric features of hydatidiform moles in early pregnancy: Relationship to detectability by ultrasound examination. *Ultrasound Obstet. Gynecol.*, 29 (1):76-80.
4. **Golfier F, Clerc J and Hajri T (2011):** Contribution of referent pathologists to the quality of trophoblastic diseases diagnosis. *Hum. Reprod.*, 26(10):2651-2658.
5. **Gersell D and Kraus F (2011):** Diseases of placenta. In: *Blaustein's Pathology of the Female Genetal Tract*. 6th ed. Springer, New York. PP: 1000-1073.
6. **Horn L C, Kowalzik J and Bilek K (2006):** Clinicopathologic characteristics and subsequent pregnancy outcome in 139 complete hydatidiform moles. *Eur. J. Obstet. Gynecol. Reprod. Biol.*, 128(2):10-14.
7. **Jaffar R, Kalsoom R and Quershi A (2011):** Histopathological review of partial and complete hydatidiform moles in a tertiary care hospital, Lahore. *Pakistan. Biomedica*, 27: 76 – 80.
8. **Juan R (2011):** Pregnancy, trophoblastic disease and placenta. In: *Rosai and Ackerman's Surgical Pathology*. 10th Edition, Chapter 19. Elsevier, New York. PP: 1636-1642.

9. **Buza N and Hui P (2014):** Immunohistochemistry and other ancillary techniques in the diagnosis of gestational trophoblastic diseases. *Semin. Diagn. Pathol.*, 31(3):223-232.
10. **Hui P, Martel M and Parkash V (2005):** Gestational trophoblastic diseases: recent advances in histopathologic diagnosis and related genetic aspects. *Adv. Anat. Pathol.*, 12(3):116–125.
11. **Ishikawa N, Harada Y and Tokuyasu Y (2009):** Re-evaluation of the histological criteria for complete hydatidiform mole, comparison with the immunohistochemical diagnosis using p57KIP2 and CD34. *Biomed. Res.*, 30 (3):141-147.
12. **Ngan H Y, Seckl M J, Berkowitz R S, Xiang Y, Golfier F, Sekharan P K and Lurain J R (2015):** Update on the diagnosis and management of gestational trophoblastic disease. *Int. J. Gynaecol. Obstet.*, 131(2): 123–126.
13. **Gupta M, Vang R, Yemelyanova A et al. (2012):** Diagnostic reproducibility of hydatidiform moles: ancillary techniques (p57 immunohistochemistry and molecular genotyping) improve morphologic diagnosis for both recently trained and experienced gynecologic pathologists. *Am. J. Surg. Pathol.*, 36 (12):1747–1760.
14. **Masood S, Imdad K and Shawana S (2015):** Differential expression of p63 in hydropic and molar gestations. *Journal of the College of Physicians and Surgeons Pakistan*, 25 (3): 198-201.
15. **Erol O, Süren D, Tutuş B et al. (2015):** Immunohistochemical analysis of E-Cadherin, p53 and inhibin α expression in hydatidiform mole and hydropic abortion. *Pathol. Oncol. Res.*, 22 (3):515-521.
16. **Khooei A, Atabaki P and Fazel A (2013):** Ki-67 expression in hydatidiform moles and hydropic abortions. *Iranian Red Crescent Medical Journal*, 15(7): 590-594.
17. **Nizam K, Haidar G, Memon N and Haidar A (2009):** Gestational Trophoblastic Disease: Experience at Nawabshah Hospital. *Med. Coll.*, 21:67–69.
18. **Lurain JR (2010):** Gestational trophoblastic disease: epidemiology, pathology, clinical presentation and diagnosis of gestational trophoblastic disease and management of hydatidiform mole. *Am. J. Obstet. Gynecol.*, 203(6):531-539.
19. **Ronnett B M, DeScipio C and Murphy K M (2011):** Hydatidiform moles: ancillary techniques to refine diagnosis. *Int. J. Gynecol. Pathol.*, 30:101–116.
20. **Banet N, DeScipio C and Murphy K M (2014):** Characteristics of hydatidiform moles: analysis of a prospective series with p57 immunohistochemistry and molecular genotyping. *Mod. Pathol.*, 27(2):238-254.
21. **Shigeru S, Yasushi S and Toshiaki K (2015):** Clinical usefulness of immunohistochemical staining of p57/kip² for the differential diagnosis of complete mole. *Biomed. Res. Int.*, doi.org/10.1155/2015/905648
22. **Jose M.M, Antonio R. B, Machline P., Isnard E. and Eliana Márcia Da Ros Wendland (2016):** Accuracy of p57^{KIP2} compared with genotyping for the diagnosis of complete hydatidiform mole: protocol for a systematic review and meta-analysis. *Biomed. Cent. Syst. Rev.*, (5): 169-175.
23. **Maggiore M S and Peres L C (2007):** Morphological, immunohistochemical and chromosome in situ hybridization in the differential diagnosis of hydatidiform mole and hydropic abortion. *Eur. J. Obstet. Gynecol. Reprod. Biol.*, 135(2):170-176.
24. **Hasanzadeh M, Sharifi N, Esmaili H, Dalooe MS and Tabari A (2013):** Immunohistochemical expression of the proliferative marker Ki67 in hydatidiform moles and its diagnostic value in the progression to gestational trophoblastic neoplasia. *J. Obstet. Gynaecol.*, 39(2):572–577.
25. **Erfanian M, Sharifi N and Omid AA (2009):** P63 and Ki-67 expression in trophoblastic disease and spontaneous abortion. *Journal of Research in Medical Sciences*, 14(6): 375-384.

- 26. Chen Y, Shen D, Gu Y, Zhong P, Xie J and Song Q (2012):** The diagnostic value of Ki-67, p53 and p63 in distinguishing partial hydatidiform mole from hydropic abortion. *Wien. Klin. Wochschr*, 124:184-187.
- 27. Heidarpour M and Khanahmadi M (2013):** Diagnostic value of P63 in differentiating normal gestation from molar pregnancy. *J. Res. Med. Sci.*, 18(6):462-466.
- 28. Rath G, Soni S, Prasad C P, Salhan S, Jain A K and Saxena S (2011):** Bcl-2 and p53 expressions in Indian women with complete hydatidiform mole. *Singapore Med. J.*, 52(7): 502–507.
- 29. Uzunlar AK, Yilmaz F, Bayhan G and Akkus Z (2002):** Expression of p53, proliferation cell nuclear antigen, and ki-67 in gestational trophoblastic disease. *Eur. J. Gynaecol. Oncol.*, 23:79–83.