

## Corneal Endothelial Cells Changes After Phacoemulsification in Type II Diabetes Mellitus

Mohamed S. ELKady, Mahmoud M. Saleh, Ahmed S. Aboalhamd

Department of ophthalmology, Faculty of Medicine, Al-Azhar University, Cairo, Egypt

### ABSTRACT

**Background:** Corneal endothelial cells are responsible for the clarity of the cornea; however, endothelial cells have limited cell division ability. Studies have proven that cornea is more vulnerable to chronic changes affecting endothelial cells in diabetic patients. Cataract extraction by phacoemulsification is one of the most ophthalmic surgeries having a negative effect on the corneal endothelial cells especially in elders. Age of the patient and diabetes mellitus have a negative effect on the outcome of phacoemulsification. The aim of the study is to compare the changes occur in corneal endothelium pre and post cataract extraction by phacoemulsification in diabetic patients in aspects of BCVA, CCT, CD, CV and HEX. **Aim of the work:** To assess endothelial cells changes following cataract extraction by phacoemulsification and posterior chamber IOL implantation in type II diabetic patients. **Methods:** The study included 20 eyes of 20 patients scheduled for cataract surgery by phacoemulsification at Al Azhar university hospitals. The patients were assigned to 2 groups. Group 1: Ten patients without diabetes were used as a control group, and a casual blood glucose test and glucose tolerance test were undertaken in accordance with the recommendations of the American Diabetes Association to disclose undetected diabetes. Group 2: Ten patients diagnosed with type II diabetes based on medical history and all were on oral anti-diabetic medication or subcutaneous treatment with insulin. Serum glycosylated hemoglobin (HbA1c) was obtained in all patients with diabetes to evaluate their glycemic status. In this prospective randomized study we did Preoperative specular microscopy and serial postoperative specular microscopy ( Topcon SP- 1P, Topcon Medical Inc., Japan.) were performed to evaluate endothelial cell count changes over 6 months. Endothelial cell images were collected in the central region of the cornea before surgery and 1 and 6 months after surgery. The main outcome measures were central corneal thickness (CCT), cell density (CD), coefficient of variation (CV), hexagonality (HEX) and best corrected visual acuity (BCVA). **Results:** In term of CCT, in group 1 the CCT mean  $\pm$ SD in preoperative is  $510.7 \pm 35.13$ , in 1 month postoperative is  $522.1 \pm 35.91$  and in 6 months postoperative is  $512 \pm 34.91$ , the difference between preoperative CCT and 6 months postoperative is  $1.3 \pm 0.95$ .

In group 2 the CCT mean  $\pm$ SD in preoperative is  $497.45 \pm 25.82$ , in 1 month postoperative  $515.64 \pm 26.59$  and in 6 months postoperative is  $500.18 \pm 25.5$ , the difference between preoperative CCT and 6 months postoperative is  $2.73 \pm 1.64$ . In term of CD, in group 1 the CD mean  $\pm$ SD in preoperative is  $2678 \pm 390$ , in 1 month postoperative is  $2599 \pm 378$  and in 6 months postoperative is  $2571 \pm 355$ , the difference between preoperative CD and 6 months postoperative is  $-107.17 \pm 15.53$ .

In group 2 the CD mean  $\pm$ SD in preoperative is  $2872 \pm 335$ , in 1 month postoperative is  $2703 \pm 326$  and in 6 months postoperative is  $2441 \pm 284$ , the difference between preoperative CD and 6 months postoperative is  $-430.8 \pm 50.31$ . In term of CV, in group 1 the CV mean  $\pm$ SD in preoperative CV is  $34.4 \pm 2.95$ , in 1 month postoperative is  $35.2 \pm 3.05$  and in 6 months postoperative is  $35 \pm 2.6$ , the difference between preoperative CV and 6 months postoperative is  $0.7 \pm 1.34$  which is statistically insignificant. In group 2 the CV mean  $\pm$ SD in preoperative CV is  $36 \pm 3$ , in 1 month postoperative is  $37 \pm 3.16$  and in months postoperative is  $36 \pm 3.2$ , the difference between preoperative CV and 6 months postoperative is  $-0.3 \pm 1.64$  which is statistically insignificant. In term of HEX, in group 1 the HEX mean  $\pm$ SD in preoperative is  $34 \pm 8$ , in 1 month postoperative  $29 \pm 7$  and in 6 months postoperative  $28 \pm 7$ , the difference between preoperative and 6 months postoperative is  $-6.2 \pm 1.55$  which is statistically significant. In group 2 the mean HEX mean  $\pm$ SD in preoperative is  $33 \pm 10$ , in 1 month postoperative is  $25 \pm 7$  and in 6 months postoperative is  $24 \pm 7$ , the difference between preoperative HEX and 6 months postoperative is  $-8.7 \pm 2.58$  which is statistically significant.

In term of BCVA, in group 1 the BCVA mean  $\pm$ SD in preoperative is  $0.15 \pm 0.05$ , in 1 month postoperative is  $0.38 \pm 0.11$  and in 6 months postoperative is  $0.5 \pm 0.07$ , the difference between preoperative BCVA and 6 months postoperatively is statistically significant. In group 2 the BCVA mean  $\pm$ SD in preoperative is  $0.128 \pm 0.034$ , in 1 month postoperative is  $0.285 \pm 0.0369$  and in 6 months postoperative is  $0.392 \pm 0.093$ , the difference between preoperative BCVA and 6 months postoperatively is statistically significant.

**Conclusion:** The endothelium in diabetic subjects is more vulnerable to surgical trauma and has a lower capability in the process of repair.

**Keywords:** phacoemulsification, endothelial cell loss, central corneal thickness.

## INTRODUCTION

Cataract has been documented to be the most significant cause of bilateral blindness. Worldwide more than 285 million people are affected by diabetes mellitus. This number is expected to increase to 439 million by 2030 according to the International Diabetes Federation. Phacoemulsification is nowadays the preferred technique for most types of cataract due to less astigmatism, less postoperative inflammation and rapid visual recovery<sup>(1)</sup>.

The hexagonal cells of the endothelium are responsible for maintaining the clarity of the cornea by actively removing the water, these cells have limited mitotic capacity, and any disturbance in the endothelial homeostasis might therefore have a profound effect on the clarity of the cornea<sup>(2)</sup>. Several studies have indicated an increased corneal vulnerability in diabetic subjects to intraocular surgical stress. It is likely that this phenomenon occurs because of chronic metabolic changes on the cellular level that primarily seems to affect the monolayer of corneal endothelial cells<sup>(3)</sup>.

Phacoemulsification with intraocular lens implantation is one of the most common surgical procedures performed. The patients are usually elderly, and this might have a negative impact on the surgical outcome because increasing age is associated with loss of endothelial cells. In childhood, the endothelium consists of approximately 4000 cells per square millimeter, whereas the number is reduced to about 2500 cells per square millimeter at age of 50 years<sup>(4)</sup>.

There are 2 important parameters, age and the presence of diabetes compromise the status of the endothelium, which may have a negative impact on the final visual outcome in case of surgery<sup>(5)</sup>.

The corneal endothelium is evaluated by central corneal thickness, corneal endothelial cell density, and morphology preoperatively and postoperatively<sup>(6)</sup>.

Descemet's Endothelium Complex (DEC) showed edematous thickening and different degrees of morphological changes after phacoemulsification. The DEC deformation and corneal edema recovered by one week after surgery, which indicated recovery of endothelial function. Pre-operative DEC thickness may indicate the integrity of the endothelium and could be used for predicting endothelial cell loss after phacoemulsification<sup>(7)</sup>.

Both transversal and torsional phacoemulsification machines were efficient, with similar endothelial cell loss. This endothelial cell

loss was related to the increased nuclear sclerosis grade and increased phacoemulsification power<sup>(8)</sup>.

## AIM OF THE WORK

To assess endothelial cells changes following cataract extraction by phacoemulsification and posterior chamber IOL implantation in type II diabetic patients.

## PATIENTS AND METHODS

Study included 20 eyes of 20 patients scheduled for cataract surgery by phacoemulsification at Al Azhar university hospitals from 2016 to 2017 . The patients were assigned to 2 groups.

**Group 1:** Ten patients without diabetes were used as a control group, and a casual blood glucose test and glucose tolerance test were undertaken in accordance with the recommendations of the American Diabetes Association to disclose undetected diabetes.

**Group 2:** Ten patients were diagnosed with type II diabetes based on medical history and all on oral anti-diabetic medication or subcutaneous treatment with insulin. Serum glycosylated hemoglobin (HbA1c) was obtained in all patients with diabetes to evaluate their glycemic status.

### Study design

A prospective randomized study. It was approved by the ethical board of Al-Azhar University and an informed written consent was taken from each participant in the study.

## PATIENTS SELECTION

### Inclusion criteria

- Any degree of cataract.
- Age from 40y to 60y.
- No previous ocular surgeries.
- Preoperative endothelial cell count at least 1500 cells per square millimeter
- Preoperative anterior chamber depth was at least 2.5 mm.

### Exclusion Criteria

- Any corneal pathology.
- Pseudoexfoliation.
- History of ocular trauma or intraocular surgery, intraocular inflammation.
- Age younger than 40 years

### Preoperative evaluation

- **History taking:**
  - Onset, course and duration of diminution of vision.
  - History of ocular trauma, ocular surgery, systemic disorder and drug intake
  - A complete ocular examination included: visual

- acuity, refraction,
- slit-lamp examination, indirect Ophthalmoscopy and specular microscopy.
- Visual Acuity: Uncorrected (UCVA) and best corrected visual acuity (BCVA).
- Refraction: Manifest and cycloplegic refraction were done, cycloplegic refraction is done one hour after instillation of 1% cyclopentolate eye drops.
- Slit Lamp Examination: Anterior segment examination using the slit lamp was performed.
- Indirect ophthalmoscopy: Fundus examination was done to assess the periphery as well as the central part of the retina.
- Applanation tonometry.

#### ■ **Investigations**

- Fasting blood glucose, 2hour postprandial blood glucose, Glycosylated haemoglobin (HbA 1C).
- Coagulation profile, Liver and Kidney function tests.
- Calculation of IOL power and axial length.

#### ■ **Phacoemulsification procedure:**

Phacoemulsification and intraocular lens implantation were performed using almost the standard techniques.

Before surgery, pupillary dilatation was achieved by 1% tropicamide and 1% cyclopentolate eye drops.

Cataract surgery was performed under local anaesthesia, anterior limbal incision was made using keratome, two side ports was made by micro vitreoretinal knife (MVR), formation of the anterior chamber by viscoelastic, anterior continuous circular curvilinear capsulorhexis was performed followed by hydrodissection and hydro-delineation, then phacoemulsification of the nucleus, bimanual irrigation aspiration, and implantation of intraocular lens in the bag after widening of the wound, finally hydration of the wound and the two paracentesis. After the operation all patients received the same standard medication for 4 weeks, consisting of 15 prednisolone acetate ophthalmic suspension 1% five times/ day with gradual tapering over one month, gatifloxacin eye drops five times daily one month and tobramycin 0.3% dexamethasone 0.1% eye ointment at bed time for one month.

#### **Post-operative medication**

- Topical Prednisolone acetate 1% eye drops every two hours (while the patient is awake only) for one week then tapered gradually over six weeks. Topical Gatifloxacin 0.3% eye drops every two awaken hours for one week then four times per day for two weeks. Combined Tobramycin 3%

with Dexamethasone phosphate 0.1% eye ointment once before sleep for one week.

- Actezolamide 250 mg tablet every 12 hours for 48 hours according to the needs.

#### **Postoperative examinations**

##### ■ **One day after surgery:**

Slit lamp biomicroscopy for:

- State of main incision.
- Cornea for clarity, oedema and ulcers.
- Anterior chamber (depth and contents).
- Any iris abnormality
- Intraocular lens regarding its position and any deposits on its surface.

##### ■ **One week after surgery:**

- Best corrected visual acuity.
- Slit lamp biomicroscopy.
- Intraocular pressure (IOP).
- Fundus examination: slit lamp biomicroscopy using non-contact Volk 90 Diopter lens, direct and indirect ophthalmoscopy.

##### ■ **One month and six months :**

- Best corrected visual acuity (BCVA).
- Slit lamp biomicroscopy.
- Intraocular pressure (IOP).
- Fundus examination.
- Specular microscopy The central endothelial cell density (cells per square millimeter), variation in size of endothelial cells, percentage of hexagonal cells, and CCT were analyzed using a noncontact specular microscope ,Central corneal endothelial photographs were taken at 1 and 6 months postoperatively.

The study was approved by the Ethics Board of Al-Azhar University.

##### ■ **Statistical analysis**

- The data were collected, revised, coded and entered to the statistical package for social science (SPSS)
- version 20. The qualitative data were presented as **number** and **percentages** while the quantitative data with parametric distribution were presented as **mean, standard deviations and ranges**.
- Comparison between two paired groups with quantitative data and parametric distribution were done by using *paired t-test*.
- The confidence interval was set to 95% and the margin of error accepted was set to 5%. So, the **P Value (Probability)** was considered significant as the following:
  - $P > 0.05$  means it is not statistically significant.
  - $P < 0.05$  means it is statistically significant.
  - $P < 0.01$  means it is statistically highly significant

## RESULTS

Table (1): Comparison of best corrected visual acuity (BCVA) in both Non diabetic and diabetic group.

CVA (mean value $\pm$ SD)	Non diabetic	Diabetic	P Value
Preoperative	0.15 $\pm$ 0.05	0.128 $\pm$ 0.034	0.3703 (NS)
1 month Postoperative	0.38 $\pm$ 0.11	0.285 $\pm$ 0.0369	0.0193 (S)
6 months Postoperative	0.5 $\pm$ 0.07	0.392 $\pm$ 0.093	0.0133 (S)
P Value of difference between preoperative and 6 months postoperative	<0.0001 (S)	<0.0001 (S)	

In group 1, the difference between preoperative BCVA and 6 months postoperatively is statistically significant. In group the difference between preoperative BCVA and 6 months postoperatively is statistically significant. In comparison between the two groups in term of preoperative BCVA and 1 month postoperative are statistically insignificant, while in the term of 6 months postoperative is statistically significant (Table 1) (Figure1).

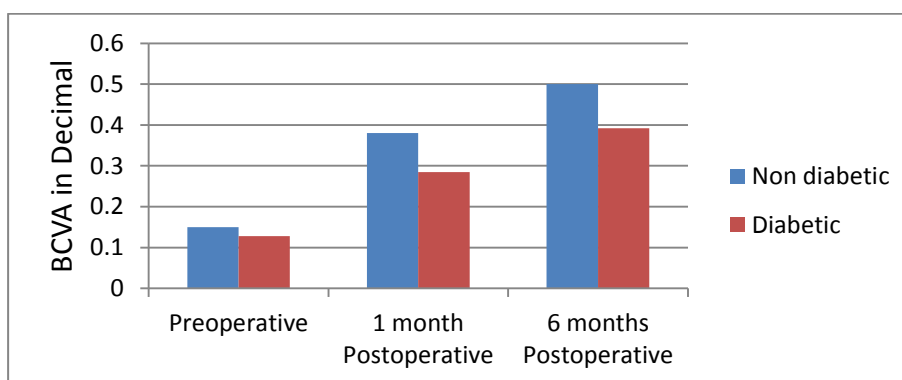


Fig. 1: Comparison of best corrected visual acuity (BCVA) in both Non diabetic and diabetic group.

Table (2): Comparison of Central Corneal Thickness (CCT) in both Non diabetic and diabetic group.

CCT (mean $\pm$ SD)	Non diabetic	Diabetic	P Value
Preoperative	510.7 $\pm$ 35.13	497.45 $\pm$ 25.82	0.5294 (NS)
1 month Postoperative	522.1 $\pm$ 35.91	515.64 $\pm$ 26.59	0.9172 (NS)
6 months Postoperative	512 $\pm$ 34.91	500.18 $\pm$ 25.5	0.5973 (NS)
Difference between preoperative and 6 months postoperative	1.3 $\pm$ 0.95	2.73 $\pm$ 0.64	0.0310 (S)
P Value of difference between preoperative and 6 months postoperative	0.0019 (S)	0.0002 (S)	

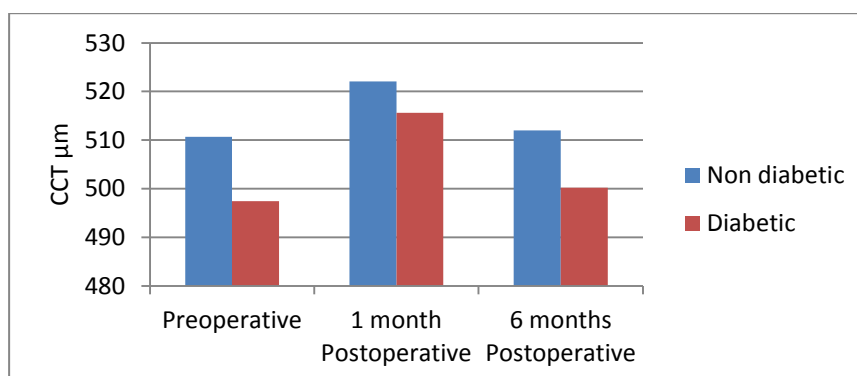
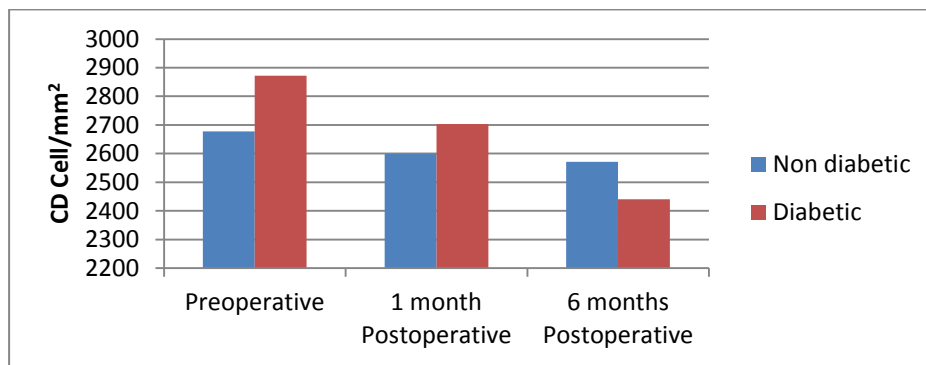


Fig. 2: Comparison of Central Corneal Thickness (CCT) in both Non diabetic and diabetic group. In group 1 the difference between preoperative CCT and 6 months postoperative is statistically significant. In group 2 the difference between preoperative CCT and 6 months postoperative is statistically significant. In comparison between the two groups in term of preoperative CCT, 1 month

postoperative and 6 months postoperative are statistically insignificant, while in the term of difference between preoperative CCT and 6 months postoperative is statistically significant (Table 2) (Figure 2).

**Table (3):** Comparison of Endothelial Cell Density (CD) in both Non diabetic and diabetic group.

CD (mean ±SD)	Non diabetic	Diabetic	P Value
Preoperative	2678 ±390	2872 ±335	0.2488 (NS)
1 month Postoperative	2599 ±378	2703 ±326	0.5188 (NS)
6 months Postoperative	2571 ±355	2441 ±284	0.3933 (NS)
Difference between preoperative and 6 months postoperative	-107.17 ±15.53	-430.8 ±50.31	<0.0001 (S)
P Value of difference between preoperative and 6 months postoperative	<0.0001 (S)	<0.0001 (S)	

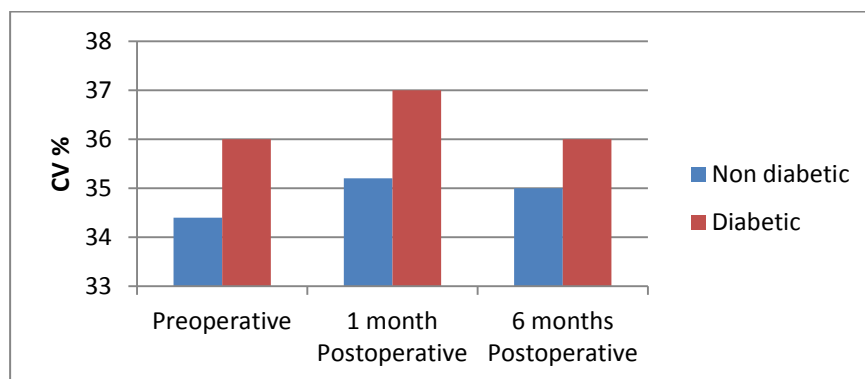


**Fig. 3:** Comparison of Endothelial Cell Density (CD) in both Non diabetic and diabetic group.

In group 1 the difference between preoperative CD and 6 months postoperative is statistically significant. In group 2 the difference between preoperative CD and 6 months postoperative is statistically significant. In comparison between the two groups in term of preoperative CD, 1 month postoperative and 6 months postoperative are statistically insignificant, while in the term of difference between preoperative CD and 6 months postoperative is statistically significant (Table 3) (Figure 3).

**Table (4):** Comparison of Coefficient of variation (CV) in both Non diabetic and diabetic group.

CV	Non diabetic	Diabetic	P Value
Preoperative	34.4 ±2.95	36 ±3	0.1964 (NS)
1 month Postoperative	35.2 ±3.05	37 ±3.16	0.2113 (NS)
6 months Postoperative	35 ±2.6	36 ±3.2	0.4931 (NS)
Difference between preoperative and 6 months postoperative	0.7 ± 1.34	-0.3 ±1.64	0.1519 (NS)
P Value of difference between preoperative and 6 months postoperative	0.1323 (NS)	0.5763 (NS)	

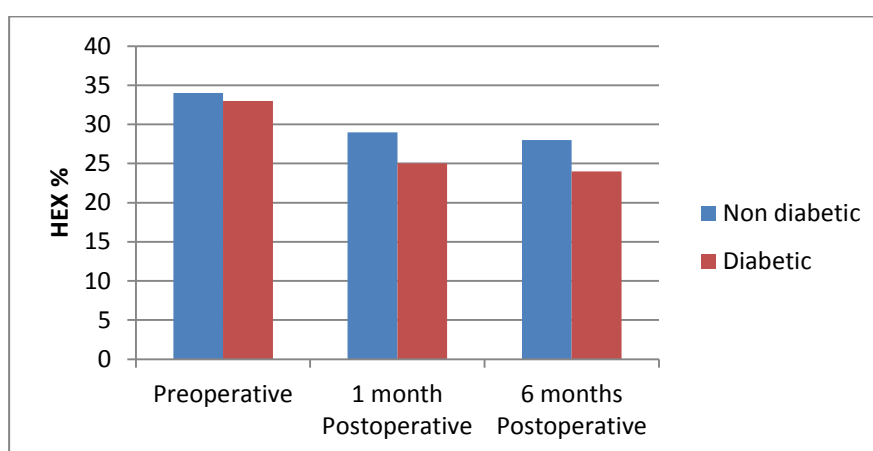


**Fig. 4:** Comparison of Coefficient of variation (CV) in both Non diabetic and diabetic group.

In group 1 the difference between preoperative CV and 6 months postoperative is statistically insignificant. In group 2 the difference between preoperative CV and 6 months postoperative is statistically insignificant. In comparison between the two groups in term of preoperative CV, 1 month postoperative 6 months postoperative and difference between preoperative CV and 6 months postoperative are statistically insignificant (Table 4) (Figure 4).

Table (5): Comparison of Hexagonality (HEX) in both Non diabetic and diabetic group.

HEX (mean $\pm$ SD)	Non diabetic	Diabetic	P Value
Preoperative	34 $\pm$ 8	33 $\pm$ 10	0.8072 (NS)
1 month Postoperative	29 $\pm$ 7	25 $\pm$ 7	0.2586 (NS)
6 months Postoperative	28 $\pm$ 7	24 $\pm$ 7	0.2766 (NS)
Difference between preoperative and 6 months postoperative	-6.2 $\pm$ 1.55	-8.7 $\pm$ 2.58	0.0172 (S)
P Value of difference between preoperative and 6 months postoperative	<0.0001 (S)	<0.0001 (S)	



**Fig. 5:** Comparison of Hexagonality (HEX) in both Non diabetic and diabetic group. In group 1 the difference between preoperative and 6 months postoperative is statistically insignificant. In group 2 the difference between preoperative HEX and 6 months postoperative is statistically insignificant. In comparison between the two groups in term of preoperative HEX, 1 month postoperatively and 6 months postoperatively are statistically insignificant, while in the term of difference between preoperative HEX and 6 months postoperative is statistically significant (Table 4) (Figure 4).

## DISCUSSION

This study included 20 eyes of 20 patients who did cataract surgery by phacoemulsification. Patients were assigned to two groups. Group 1 included ten patients without diabetes while group 2 included ten diabetic patients. A comparison between pre-operative, one month and six months postoperative in aspects of BCVA, CCT, CD, Coefficient of variation and hexagonality. In the early postoperative period, while hexagonality increases, endothelial cell density begin to decrease. And endothelial pump functions in the damaged regions generally improve within a period of 14 days. The coefficient of variation showed an objective parameter to evaluate the variability between cell areas. The normal value must be under 30%<sup>(9)</sup>. The human corneal endothelial cell is a non-regenerating predominantly hexagonal cell which

covers the posterior surface of descemet's membrane and faces the anterior chamber of the eye. Corneal endothelium is metabolically active and plays an imperative role in maintaining the corneal transparency<sup>(10, 11)</sup>. Diabetes mellitus is associated with structural changes in corneal endothelial cells and their thickness<sup>(12,13)</sup>. Many clinical evidences have shown that patients with diabetes have functional abnormalities such as a higher corneal auto-fluorescence, lower corneal sensitivity, greater baseline corneal thickness, less endothelial cell density, and increased endothelial permeability to fluorescein after intraocular surgery<sup>(14, 15)</sup>. Corneal endothelial decompensation after cataract extraction is a well-known complication after all types of cataract surgery. The overall incidence is less than 1%<sup>(16)</sup>.

Cataract surgery is the most common cause of iatrogenic corneal edema. Most corneas manifest temporary stromal edema for the first few days postoperatively because of high hydrostatic pressure from the flow of irrigating solutions<sup>(17)</sup>.

In this study including the results of comparison between the pre-operative and 6 months postoperative in each group in term of best corrected visual acuity, central corneal thickness, endothelial cell density and hexagonality are statistically significant in both groups but in term of coefficient variation is statistically insignificant. The results of comparison between the non-diabetic group and diabetic group in term of difference between preoperative and 6 months postoperative central corneal thickness, endothelial cell density and hexagonality were statistically insignificant but in term of difference between preoperative and 6 months postoperative in coefficient variation is statistically insignificant. Such results suggest that diabetic patients' endothelial cells are more vulnerable to phacoemulsification than in non-diabetic patients.

Khan et al.<sup>(1)</sup> had a similar study done on 66 patients of cataract, out of which 33 patients with and 33 without DM (Type 2). Both groups underwent preoperative investigation and ophthalmological assessment and then undergo phacoemulsification. After phacoemulsification all cases were followed up on 1st day, 1st week, 1 month and 3 months and uncorrected visual acuity (UCVA), best corrected visual acuity (BCVA), corneal thickness, endothelial cell count and morphometric analysis were recorded.

At the end of 3 months it was found that the mean endothelial cell loss in Group A (Diabetic) was  $6.9\% \pm 0.6$  and in Group B (control) was  $2.4\% \pm 0.3$  so the difference in pre and postoperative is statistically significant suggesting that the corneal endothelium in diabetic patients is under metabolic stress, and weaker against mechanical loads, such as phacoemulsification, than that in non-diabetic subjects. Despite good glycemic control and no corneal abnormalities before surgery, endothelium in diabetic subjects is more vulnerable to surgical trauma and has a lower capability in the process of repair. These findings should be considered when planning cataract surgery in patients with diabetes<sup>(1)</sup>

In Khan's study the mean endothelial cell loss in diabetic patients is less than in our study, however, it was still statistically significant as in our study. The difference in Khan's study is that the follow up was 3 months postoperative and the change in preoperative and 3 months post-operative hexagonality in each group is statistically significant

but in our study follow up was 6 months postoperative and the change in preoperative and 3 months postoperative hexagonality in each group is statistically insignificant.

Al-Sharkawy<sup>(18)</sup> 2015 had a similar study done on 100 eyes of 99 patients (49 with and 50 without type 2 diabetes) with senile cataract underwent phacoemulsification with foldable intraocular lens implantation. Specular microscopy was performed pre-operatively, at 1 week, and at 3 months postoperatively to evaluate endothelial cell density (ECD), coefficient of variation (CV) and central corneal thickness (CCT).

Al-Sharkawy<sup>(18)</sup> reported that there was no significant difference in the corneal endothelium preoperatively between diabetic and non-diabetic patients. Although no significant difference was found in ECL following phacoemulsification between the two groups, diabetic patients had a significantly greater increase in CV (polymegathism) and CCT compared with non-diabetic patients. So Al-Sharkawy<sup>(18)</sup> disagrees with our study in comparison between the non-diabetic and diabetic groups in term of the difference between preoperative and postoperative central corneal thickness but in term of endothelial cell loss as it was significant in our study and in term of Coefficient variation as it was insignificant<sup>(18)</sup>.

Mor et al.<sup>(19)</sup> have conducted a study which agrees with our study as they compared corneal thickness and morphology in 93 eyes in patients with type 2 diabetes with 93 eyes in patients without diabetes before and 1 day, 1 week, and 1 month after phaco-emulsification. Compared with non-diabetic group, the study found that the central corneal thickness increase observed 1 month after operation was 0.04% in the non-diabetic group 1.6% in the diabetic group. The increase after 1 month was significantly higher in the diabetic group than in the non-diabetic group ( $P=0.03$ ). The endothelial cell losses occurring 1 month after operation was 3.2%, in the non-diabetic group 7.2% in the diabetic group. The coefficient of variation 1 month after operation was 0.308, and in the non-diabetic group and 0.312 in the diabetic group, without significant differences between the 2 groups<sup>(19)</sup>. A study done by Schultz et al, to assess the response of endothelium to cataract surgery showed a decrease in the endothelial density over 3 months postoperatively, with an increase in the coefficient of variation. In our study the coefficient variation was insignificant<sup>(20)</sup>.

## CONCLUSION

Despite good glycemic control and no corneal abnormalities before surgery,

the endothelium in diabetic subjects is more vulnerable to surgical trauma and has a lower capability in the process of repair. Maintaining adequate corneal endothelium health poses a particular challenge after phacoemulsification and intraocular lens implantation in diabetic patients.

These findings should be considered when planning cataract surgery in patients with diabetes. However, despite significant higher loss of endothelial cells and a significant slower process of cell repair in diabetic subjects, functional ocular status seemed slightly changed as judged by CCT. Thus, a sufficient reserve capacity to maintain normal corneal functional status in well controlled patients with diabetes exists during the period of follow up. Diabetic patients with visually significant cataracts pose unique challenges during surgery, and they maybe prone to a more difficult postoperative recover.

## REFERENCES

1. **Khan A , Kose S , Jharwal MK *et al.*** (2016): Comparison of Corneal Endothelial Cell Counts in Patients with Controlled Diabetes Mellitus (Type 2) and Non Diabetics after Phacoemulsification and Intraocular Lens Implantation. *International Multispecialty Journal of Health* ,2 (6) : 2395-6291.
2. **Morikubo S, Takamura Y and Kubo E** (2004): Corneal changes after small-incision cataract surgery in patients with diabetes mellitus. *Arch Ophthalmol.*, 122:966–69.
3. **Saini J and Mittal S** (1996): In vivo assessment of corneal endothelial function diabetes mellitus. *Arch Ophthalmol.*, 114:649–53.
4. **Lee J , Lee J and Choi H** (2005): Corneal endothelial cell changes after phacoemulsification relative to the severity of diabetic retinopathy. *J Cataract Refract Surg.*, 31:742–49.
5. **Mirza S, Alexandridou A and Marshall T *et al.*** (2003): Surgically induced miosis during phacoemulsification in patients with diabetes mellitus. *Eye*, 17:19.
6. **Polack F and Sugar A** (1976): The phacoemulsification procedure. Corneal endothelium changes. *Invest Ophthalmol.*, 6:58-69.
7. **Tao A, Chen Z, Shao Y**(2013) : Phacoemulsification Induced Transient Swelling of Corneal Descemet's Endothelium Complex Imaged with Ultra-High Resolution Optical Coherence Tomography. *Invest Ophthalmol.*,9:545-60.
8. **Ataş M , Demircan S , Karatepe A S *et al.*** (2014): Comparison of corneal endothelial changes following phacoemulsification with transversal and torsional phacoemulsification machines. *Int J Ophthalmol.*, 7(5): 822–27.
9. **Hayashi K, Yoshida M, Manabe S *et al.*** (2011): Cataract surgery in eyes with low corneal endothelial cell density. *J Cataract Refract Surg.*, 37(8):1419–1425.
10. **Benetz BA, Diaconu E, Bowlin SJ *et al.*** (1999): Comparison of corneal endothelial image analysis by Konan SP8000 noncontact and Bio-Optics Bambi systems. *Cornea*, 18: 67-72.
11. **Van Schaick W.B, Van Dooren, Mulder PG *et al.*** (2005): Validity of endothelial cell analysis methods and recommendations for calibration in Topcon SP-2000P specular microscopy. *Cornea*, 24(5):538-44.
12. **Schultz RO, Matsuda M, Yee RW *et al.*** (1984): Corneal endothelial changes in type I and type II diabetes mellitus. *Am J Ophthalmol.*, 98: 401–410.
13. **Bourne WM** (1998): Clinical estimation of corneal endothelial pump function. *Trans Am Ophthalmol Soc.*, 96: 229–239.
14. **Schwartz DE**(1974): Corneal sensitivity in diabetics. *Arch Ophthalmol.*, 91: 174–178.
15. **Weston BC, Bourne WM, Hodge DO *et al.*** (1995): Corneal hydration control in diabetes mellitus. *Invest Ophthalmol Vis Sci.*, 36:586–595.
16. **Henderson BA, Steinert RF, Eichenbaum DA *et al.*** (2008): Complications of IOL Surgery. In: Albert and Jakobie FS. (eds.). *Principles and Practice of Ophthalmology* . WB Saunders . Pp 1536 - 1538.
17. **Vanmeter WS, Lee WB and Katz DG** (2013): Corneal edema. In: Duane TD(ed) *clinical Ophthalmology* 12th ed William Barry Lee. Pp 6171-6197.
18. **Al-Sharkawy HT** (2015): Corneal endothelial changes in type 2 diabetes mellitus before and after cataract surgery . *Bull Ophthalmol Soc Egypt* , 108:79–85.
19. **Morikubo S, Takamura Y, Kubo E *et al.*** (2004): Corneal changes after small incision cataract surgery in patients with diabetes mellitus. *Arch Ophthalmol.*, 122:966-9. 200.
20. **Schultz RO, Glasser DB, Matsuda M *et al.*** (1986): Response of the corneal endothelium to cataract surgery. *Arch Ophthalmol.*, 104: 1164-9.