

## Role of Magnetic Resonance Imaging in Breast Cancer: Detection of Tumor Response Post Neoadjuvant Chemotherapy

TALAL A. AMER, M.D.\*; MOHAMED A. HEGAZY, M.D.\*\*; GHADA H. ABDELRAOUF, M.Sc.\* and FATMA M. SHERIF, M.D.\*

The Departments of Diagnostic Radiology\* and Surgical Oncology\*\*, Faculty of Medicine, Mansoura University

### Abstract

**Background:** This study aimed at assessment of the role of magnetic resonance imaging (MRI) in evaluating residual disease, and its ability to detect response after neoadjuvant chemotherapy (NAC) for locally advanced breast cancer cases.

**Aim of Study:** The aim of this study was to assess the role of MRI in evaluating response to NAC for locally advanced breast cancer cases.

**Patients and Methods:** This prospective study included 40 female patients with pathologically proven locally advanced breast cancer, with mean age of 43.1 years. They underwent dynamic MRI with diffusion study after neoadjuvant chemotherapy (NAC) to assess the response after the NAC, results were compared to the histopathological results after surgery following NAC as the gold standard. The study was done at Radiology Department, Mansoura University, Egypt. This study was carried out in the period between February 2017, and September 2019.

**Results:** MRI showed sensitivity of 91.2%, specificity 66.7%, PPV 93.9%, NPV 57.1%, and accuracy 87.5% in assessment of the response to NAC. In (17.5%) of cases MRI showed overestimation compared to the pathological results. In (5%) of cases MRI showed underestimation compared to the pathological results.

**Conclusion:** MRI proved to be highly beneficial in assessment of response of locally advanced breast cancer to NAC. However, it may overestimate or underestimate residual disease in some patients. Further studies to improve the specificity of MRI may be of benefit.

**Key Words:** Neoadjuvant chemotherapy – MRI – Response – Residual disease – Locally advanced breast cancer.

### Introduction

**BREAST** cancer is the most common cancer in women. It accounts for 27% of all female cancers. If breast cancer is diagnosed at an early stage,

---

**Correspondence to:** Dr. Talal A. Amer, The Department of Diagnostic Radiology, Faculty of Medicine, Mansoura University

there is a good chance of cure. The more advanced the cancer, the more it has grown, and spread [1].

Improvements in diagnosis of breast cancer are largely responsible for increasing rate of survival among breast cancer women [2]. Breast cancer mortality has declined since 1990, and this can be attributed to early detection through screening mammography, and improved therapy [3].

Pre-operative or neoadjuvant chemotherapy (NAC) has gained a real accepted and underlying role in treatment of stage II and III breast cancer [4]. Obviously, the most significant effect of this treatment is its potential to clear the neoplastic tissue completely from the breast and axillary region. Complete response makes the conservative surgery feasible with an improved expected survival

The role of magnetic resonance imaging (MRI) in cases of NAC is crucial. During NAC, it allows evaluation of the therapeutic response. Thus, monitoring of the response allows the type of chemotherapy to be changed if the tumor does not shrink, or the chemotherapy to be interrupted if the tumor progresses. At the end of the treatment, the therapeutic response can be described. This response is an important prognostic factor as a complete response is associated with disease-free and overall survival benefit [6].

### Patients and Methods

This prospective study included 40 female patients with pathologically proven locally advanced breast cancer by “tru- cut” biopsy. Their ages ranged from 26 to 68 years, with the mean age of 43.1 years. This study was carried out in the period between February 2017, and September 2019. All patients underwent dynamic MRI with

diffusion study after NAC to assess the tumor response, results were compared to the histopathological results after surgery following NAC as the gold standard. Patients with contraindication to MRI examination (e.g. patients with cardiac pacemaker), and patients without histopathological results following surgery were excluded from the study.

Dynamic contrast-enhanced breast MRI with diffusion study of all patients was performed with a 1.5 Tesla MRI device (Philips Ingenia, Best, Netherland). All patients were examined in the prone position using dedicated breast coil. A localizer sagittal scout view was obtained, axial non-fat-saturated T1WI was obtained by FSE with the following imaging parameters: TR 450ms, TE 14ms, slice thickness 3mm, field of view (FOV) 300-360mm and matrix was 307x512. STIR sequence was obtained with the following parameters: TR 7000-9000ms, TE 70ms & inversion time (TI) was 150ms, slice thickness was 3-4mm with inter slice gap 1mm, field of view (FOV) 300-360mm and the matrix was 307 x 512. T2WI pulse sequence was obtained Using FSE with the following imaging parameters TR 2000ms, TE 8ms, slice thickness 80mm, field of view (FOV) 400-500mm, and matrix was 256x256, flip angle 90 degree to obtain axial non-fat saturated T2WI.

Diffusion weighted imaging (DWI) was done before contrast administration by a multisection single shot spin echo EPI sequence with TR/TE/NEX: 5800/139ms/1 with  $b$  values = 0, 500, and 1000mm<sup>2</sup>/sec. The diffusion gradients were applied sequentially in the three orthogonal directions (X, Y, & Z directions). Sections of 4mm thickness, interslice gap of 1mm, a 300-360mm FOV, and a 128x256 matrix were used for all images. The total acquisition time was 120sec. Orthogonal (DWI) images & ADC maps were obtained in all cases.

Then, dynamic contrast enhanced MR studies were made in the axial plane with fat suppression by applying fat saturated pulse. A bolus of gadolinium based contrast agent in a dose of 0.2mmol/Kg was injected intravenously with an automatic injector at a rate of 3-5ml/s, followed by 20ml saline flush. The sequence used was FLASH 3D GRE-T1W1 with the following parameters: TR 4-8ms, TE 2ms, flip angle 20-25 degrees, slice thickness 2mm with no inter-slice gap, field of view (FOV) 300-360mm, and the matrix was 307 X 512. Dynamic study consists of one pre contrast, and 5 post contrast series, each of them took about 1.15min with a break between the pre contrast, and post contrast study about 20sec.

Upon completion of imaging, image post processing and image analysis were done including maximum intensity projection (MIP) images, and subtraction images were created by using the Standard subtraction function of the device that subtracts early and late contrast-enhanced images from non-contrast images. The time signal intensity curves of the images were created.

The resulting data were analyzed using Statistical Package for Social Science version 22 (IBM SPSS Inc. released 2013, Chicago, Ill, USA). Qualitative data were reported using number and percent. Quantitative data were described using median (minimum and maximum) for non-parametric data and mean, standard deviation for parametric data. The obtained results were considered significant at  $p$ -value  $\leq 0.05$ . Receiver Operator Characteristic (ROC) curve analysis was performed to detect validity of MR findings compared to histopathology as the reference standard. Sensitivity and specificity were detected from the curve, positive predictive value (PPV), negative predictive value (NPV) and accuracy were calculated through cross tabulation.

## Results

This prospective study included 40 female patients with pathologically proven locally advanced breast cancer. Their ages ranged from 26 to 68 years with the mean age of  $43.1 \pm 10.18$  SD years. In our study, the premenopausal age category was the predominating, representing 75% of the studied cases. All patients underwent "Tru-cut" biopsy for diagnosis of the pathological type. The most common pathological type of breast cancer in this study was the "invasive duct carcinoma", that represented 65% of the studied cases.

On MRI, eight patients (20%) showed complete response to the NAC, 25 patients (62.5%) showed partial response (Fig. 2). Two patients (5%) showed stable course, and 5 patients (12.5%) showed progressive course. Table ( ) demonstrated MR findings in the examined group. Diffusion-weighted MR study was performed in 31 patients. As regard cases with partial response, 44% of them revealed restricted diffusion, and 52% declared non restricted diffusion. The time signal intensity curve was also applied in 31 patients. Three cases (9.7%) showed type 1 curve "Rising curve", 18 cases (58.1%) showed type 2 curve "Plateau curve", and 10 cases (32.3%) showed type 3 curve "Washout curve" (Table 1).

Pathological assessment following the NAC revealed with 11 patients (27.5%) complete response, 23 patients (57.5%) with partial response. Two cases showed stable course and four cases (10%) showed progressive course (Table 2).

Compared to pathological results, ROC curve analysis revealed that ADC value of  $0.75 \times 10^{-3} \text{ mm}^2/\text{s}$  can be used as a cutoff value to differentiated between presence or absence of response to NAC with sensitivity of 83.3%, specificity of 80% and accuracy of 83.3% (Fig. 1, Table 3). The validity of MRI findings was analyzed with reported sensitivity of 91.2%, specificity of 66.7% an accuracy of 87.5% (Table 4).

Table (1): MRI findings of the post NAC studied cases (n=40).

MRI	N=40	%
<i>Morphology (appearance of lesion):</i>		
No lesions	4	10.0
Non mass enhancement (NME)	6	15.0
Focal	10	25.0
Decentralized	18	45.0
Tiny Foci	2	5.0
<i>Morphology (LNs):</i>		
No significant	15	37.5
Positive unilateral	18	45.0
Positive bilateral	7	17.5
<i>Morphology chest wall invasion:</i>		
No chest wall invasion	38	95.0
Positive chest wall invasion	2	5.0
<i>Morphology pattern of enhancement:</i>		
Heterogeneous	23	57.5
NME	9	22.5
Marginal thick enhancement	2	5.0
Tiny enhancing foci	2	5.0
No residual enhancement	4	10.0
<i>Diffusion:</i>		
	n=31	
Non restricted	14	45.2
Restricted	17	54.8
<i>Time signal intensity Curve:</i>		
	N=31	
Type 1	3	9.7
Type 2	18	58.1
Type 3	10	32.3
<i>Impression of tumor response to NAC:</i>		
Complete response	8	20.0
Partial response	25	62.5
Stable disease	2	5.0
Progressive disease	5	12.5

NAC: Neoadjuvant chemotherapy.  
LN : Lymph nodes.

Table (2): Pathology results of studied cases (n=40).

Pathology	N=40	%
<i>Post NAC:</i>		
Complete response	11	27.5
Partial response	23	57.5
No response (stable)	2	5.0
No response (progressive)	4	10.0
<i>LNs:</i>		
Free	18	45.0
Infiltrated	22	55.0

Table (3): The ROC curve analysis of the validity of ADC value in assessment of the tumor response to the NAC.

AUC (95% CI)	Cut off point	Sensitivity (%)	Specificity (%)	PPV (%)	NPV (%)	Accuracy (%)
ADC 0.91	$\leq 0.75 \times 10^{-3} \text{ mm}^2/\text{s}$	83.3	80.0	50.0	95.2	83.3

ROC curve : Receiver operator characteristic curve.  
AUC : Area under curve.  
PPV : Positive predictive value.  
NPV : Negative predictive value.

Table (4): Validity of MRI in detection of breast cancer response to NAC in the studied cases compared to pathology.

	Pathology		Sensitivity (%)	Specificity (%)	PPV (%)	NPV (%)	Accuracy (%)
	No response	Response					
<i>MRI:</i>							
No response	4	3	91.2	66.7	3.9	57.1	87.5
Response	2	31					

PPV: Positive predictive value. NPV: Negative predictive value.

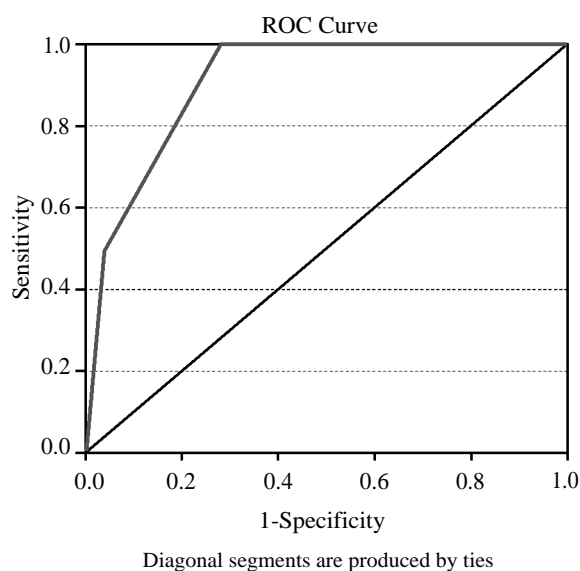


Fig. (1): The ROC curve of validity of ADC value in differentiation of breast cancer response to NAC compared to pathology.

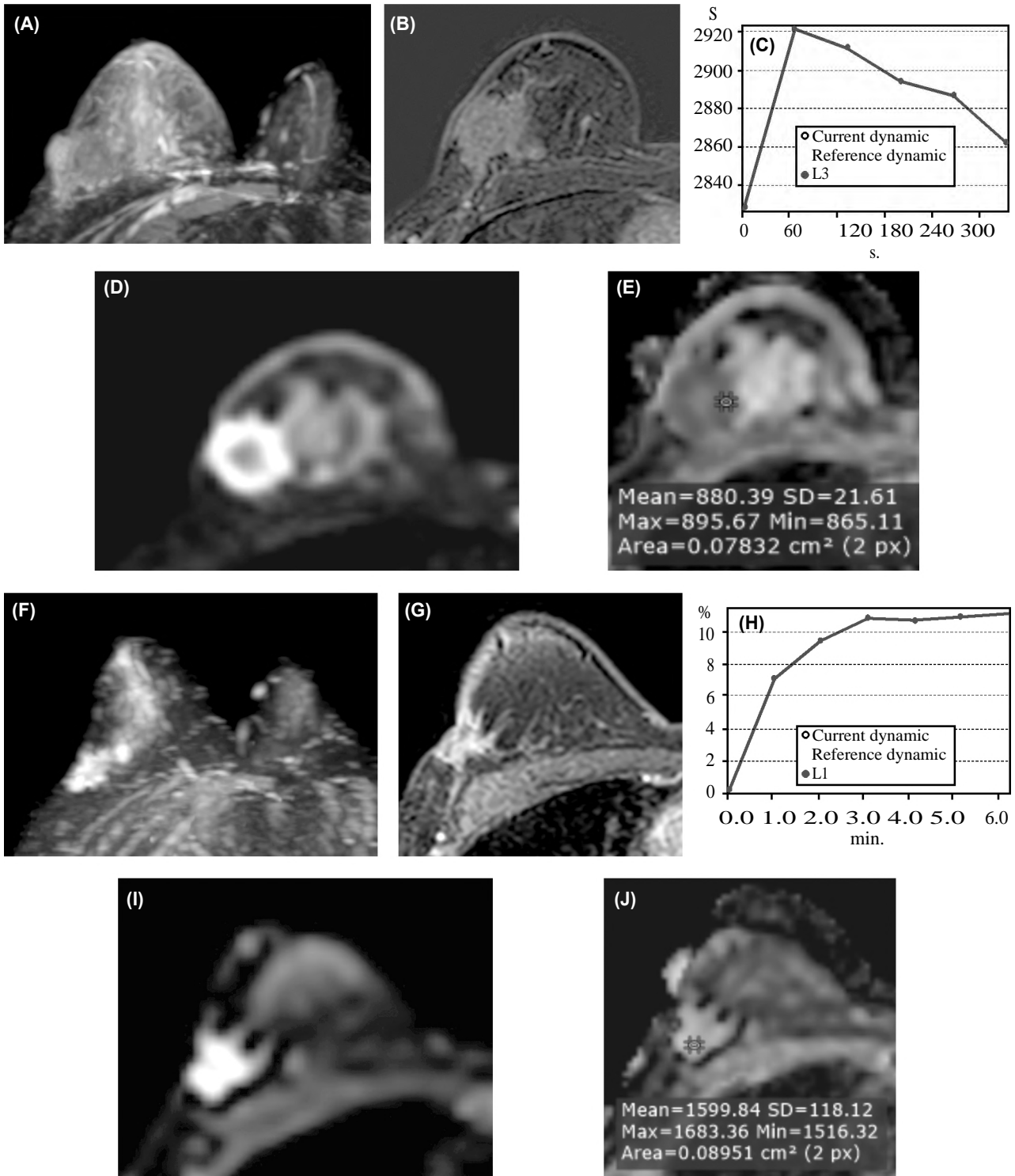


Fig. (2): Female patient, 30 years old, with right breast cancer (Pathologically proven infiltrating duct carcinoma) received NAC:

- MRI before NAC (2a-2e): Spiculated, heterogeneously enhancing fungating mass in right upper quadrant:
- 2a: MIP image of the lesion. 2b: Subtraction contrast-enhanced image. 2c: Time signal intensity curve of the mass showing type III (washout) curve. 2d: DWI, 2e: ADC map show restricted diffusion.
- MRI post NAC follow up (2f-2j):
- 2f: MIP image of the lesion. 2g: subtraction contrast-enhanced image showed decreased size of the mass. 2h: Time signal intensity curve of the mass showing type II (plateau) curve. 2i: DWI showed high signal of the lesion, 2j: ADC map showed higher signal with higher ADC value.
- MRI diagnosis: Partial response to therapy coping with histopathological diagnosis.

## Discussion

In this study all patients underwent “Tru-cut” biopsy before the NAC administration for the diagnosis of the pathological type. The most common pathological type of breast cancer in this study is the “invasive duct carcinoma” detected in twenty six patients (65% of cases). This was in agreement with many prospective and retrospective studies [7-9].

In the current study, MRI results revealed complete response to the NAC in 20% of cases, partial response in 62.5%, stable course in 5% of cases and progressive course in 12.5% of cases. While on pathological assessment following the NAC, 27.5% showed complete response, 57.5% showed partial response, 15% revealed no response. These results matched with those of previous studies [10-13]. In a study conducted by Gezer et al., [38] patients were examined after administration of NAC with a diagnosis of locally advanced breast cancer, complete response was revealed in 13.2%, 73.7% of patients showed partial response, 10.5% of cases were diagnosed to have stable course, and 1 case with progressive course. While on Pathology of the same study, 6 cases (15.8%) showed complete response, 28 cases (73.7%) showed partial response, 3 cases (7.9%) showed stable course, and 1 case (2.6%) showed progressive course [12]. In Abedi et al. study, [11] that was conducted on 20 patients of locally advanced breast cancer cases to evaluate the validity of MRI in evaluation of tumor response to NAC, dynamic MRI showed complete response in 3 patients, partial response in 13 patients, stable disease in 3 patients, and progressive disease in 1 of the patients.

On dynamic MRI in this study, mass lesions (including focal, or decentralized lesions) were detected in 28 patients (70%), while non mass lesions were detected in 6 patients (15%). Four patients (10%) showed no residual masses. Tiny foci were detected in two patients (5%). This matched with Gezer et al. [12] who reported a wide variation in the morphology of the lesions on the dynamic MRI study. Moreover, in agreement with the results of Gezer et al., [12] the most common pattern of enhancement in this study was heterogeneous enhancement, it was detected in 68.4% of the cases.

In our study, the assessment of the response to the NAC with MRI revealed sensitivity of 91.2%, specificity of 66.7% and accuracy 87.5%. These results was in agreement with De Los Santos et al., a retrospective study conducted on 746 women

with locally advanced breast cancer receiving NAC, who reported sensitivity of 92% and specificity 50% [14]. Also, similar validity was reported in Abedi et al., results, who found accuracy of 85% for MRI with sensitivity of 100% and specificity of 50% [11]. A retrospective study was conducted on 61 patients with locally advanced breast cancer after NAC with a mean age of 56 years, and reported an accuracy of 84%, a sensitivity of 86%, a specificity of 79% for MRI evaluation of complete response [15].

The difference in sensitivity and specificity from other studies might be related to small sample size. Also, MRI could show the residual tumor with a high sensitivity (100%) and an intermediate specificity (50%) due to some discrepancy between the MRI size measurement, and histologic reports [11].

Our results were not matched with Schott et al., study apart from the accuracy which was nearly close to ours), who reported MRI sensitivity of 25% and specificity of 97%.

In our study, there was two cases of underestimation “False negative results” in which there were no significant lesions on MRI and were reported as a complete responders radiologically. These two cases on histopathological examination showed residual millimetric foci. This agreed with Gezer et al., [12] who stated that it should be kept in mind that pathology accepts the tumor size as the entire width of the lesion, therefore, in patients with millimetric tumor foci, pathology determines a larger tumor size than MRI. Also, In some patients, there might be no contrast enhancement on MRI while a few invasive cells might be detected on pathology. It is difficult to determine the actual size of the tumor in lesions with originally multiple nodular contrast enhancements that show partial-patchy response after NAC.

Underestimation of the tumor in MRI in cases of NAC administration may be due to antivasular effects of the NAC (resulting in less tumor enhancement), lack of inflammatory response surrounding the tumor in docetaxel-receiving patients, more extensive ductal carcinoma in situ components, and partial volume effects in very small foci of residual disease [18]. Underestimation of residual disease could lead to positive resection margins with viable residual tumor cells, necessitating re-surgery. In addition, positive resection margins are associated with an increased long-term risk of disease recurrence in patients who have undergone breast-conserving surgery [17].

MR imaging can underestimate residual disease when fragmentation occurs and small foci of residual tumor cells are scattered over a large area or overestimate residual disease if there is host response of reactive inflammation and fibrosis within the treated tumor bed [18,19]. Also our results agreed with Shin et al., [10] study where MRI underestimated the size of the residual tumor in 7% (3/43) of patients and overestimated it in 19% (8/43).

On the other hand, in our study, MRI showed overestimation in 7 cases compared to the pathology, 4 cases of them reported partial response on MRI and complete response on pathology, 1 case of progressive course on MRI and partial response on pathology and 1 case of stable course in MRI and partial response on pathology. This was in agreement with Diguisto et al., [20] where for 19 women, among 30 women of pathological complete response, the MRI concluded that there was residual tumor, while in fact the pathological response was complete.

#### Conclusion:

MRI proved to be of highly beneficial in assessment of response of locally advanced breast cancer to NAC. However, it may overestimate or underestimate residual disease in some patients. Further studies with larger number of patients are needed for more meticulous assessment of the specificity of MRI.

#### References

- 1- ASLAM H.M., SALEEM S., SHAIKH H.A., SHAHID N., MUGHAL A. and UMAH R.: Clinico-pathological profile of patients with breast diseases. *Diagnostic Pathology*, 8 (1), 2013.
- 2- JANSEN S.A., FAN X., KARZMAR G.S., ABE H., SCHMIDT R.A. and NEWSTEAD G.M.: Differentiation between benign and malignant breast lesions detected by bilateral dynamic contrast-enhanced MRI: A sensitivity and specificity study. *Magnetic Resonance in Medicine*, 59 (4): 747-54, 2008.
- 3- BERRY D.A., CRONIN K.A., PLEVITIS S.K., FRYBACK D.G., CLARKE L., ZELEN M., et al.: Effect of Screening and Adjuvant Therapy on Mortality from Breast Cancer. *New England Journal of Medicine*, 353 (17): 1784-92, 2005.
- 4- CHAGPAR A.B., MIDDLETON L.P., SAHIN A.A., DEMPSEY P., BUZDAR A.U., MIRZA A.N., et al.: Accuracy of Physical Examination, Ultrasonography, and Mammography in Predicting Residual Pathologic Tumor Size in Patients Treated With Neoadjuvant Chemotherapy. *Annals of Surgery*, 243 (2): 257-64, 2006.
- 5- BHATTACHARYYA M., RYAN D., CARPENTER R., VINNICOMBE S., GALLAGHER C.J.: Using MRI to plan breast-conserving surgery following neoadjuvant chemotherapy for early breast cancer. *British Journal of Cancer*, 98 (2): 289-93, 2008.
- 6- GOLSHAN M., FUNG B.B., WILEY E., WOLFMAN J., RADEMAKER A. and MORROW M.: Prediction of breast cancer size by ultrasound, mammography and core biopsy. *The Breast*, 13 (4): 265-71, 2004.
- 7- CHEN J.-H., BAHRI S., MEHTA R.S., KUZUCAN A., YU H.J., CARPENTER P.M., et al.: Breast Cancer: Evaluation of Response to Neoadjuvant Chemotherapy with 3.0-T MR Imaging. *Radiology*, 261 (3): 735-43, 2011.
- 8- LYOU C.Y., CHO N., KIM S.M., JANG M., PARK J.-S., BAEK S.Y., et al.: Computer-Aided Evaluation of Breast MRI for the Residual Tumor Extent and Response Monitoring in Breast Cancer Patients Receiving Neoadjuvant Chemotherapy. *Korean Journal of Radiology*, 12 (1): 34, 2011.
- 9- HYLTON N.M., BLUME J.D., BERNREUTER W.K., PISANO E.D., ROSEN M.A., MORRIS E.A., et al.: Locally Advanced Breast Cancer: MR Imaging for Prediction of Response to Neoadjuvant Chemotherapy-Results from ACRIN 6657/I-SPY TRIAL. *Radiology*, 263 (3): 663-72, 2012.
- 10- SHIN H.J., KIM H.H., AHN J.H., KIM S.B., JUNG K.H., GONG G., et al.: Comparison of mammography, sonography, MRI and clinical examination in patients with locally advanced or inflammatory breast cancer who underwent neoadjuvant chemotherapy. *The British Journal of Radiology*, 84 (1003): 612-20, 2011.
- 11- ABEDI M., FARROKH D., HOMAEI F.S., JOULAEI A., ANBIAEE R., ZANDI B., et al.: The validity of MRI in evaluation of tumor response to neoadjuvant chemotherapy in locally advanced breast cancer. *Iranian journal of cancer prevention*, 6 (1): 28, 2013.
- 12- GEZER N.S., ORBAY O., BALCI P., DURAK M.G., DEMIRKAN B. and SAYDAM S.: Evaluation of Neoadjuvant Chemotherapy Response with Dynamic Contrast Enhanced Breast Magnetic Resonance Imaging in Locally Advanced Invasive Breast Cancer. *The Journal of Breast Health*, 10 (2): 111-8, 2014.
- 13- MUKHERJEE P., SHARMA S., SHEIKH Z. and VIJAY-KUMAR D.: Correlation of clinico-pathologic and radiologic parameters of response to neoadjuvant chemotherapy in breast cancer. *Indian journal of cancer*, 51 (1): 25, 2014.
- 14- De LOS SANTOS J., BERNREUTER W., KEENE K., KRONTIRAS H., CARPENTER J., BLAND K., et al.: Accuracy of Breast Magnetic Resonance Imaging in Predicting Pathologic Response in Patients Treated With Neoadjuvant Chemotherapy. *Clinical Breast Cancer*, 11 (5): 312-9, 2011.
- 15- CROSHAW R., SHAPIRO-WRIGHT H., SVENSSON E., ERB K. and JULIAN T.: Accuracy of Clinical Examination, Digital Mammogram, Ultrasound, and MRI in Determining Postneoadjuvant Pathologic Tumor Response in Operable Breast Cancer Patients. *Annals of Surgical Oncology*, 18 (11): 3160-3, 2011.
- 16- SCHOTT A.F., ROUBIDOUX M.A., HELVIE M.A., HAYES D.F., KLEER C.G., NEWMAN L.A., et al.: Clinical and Radiologic Assessments to Predict Breast Cancer Pathologic Complete Response to Neoadjuvant Chemotherapy. *Breast Cancer Research and Treatment*, 92 (3): 231-8, 2005.

- 17- DENIS F., DESBIEZ-BOURCIER A.V., CHAPIRON C., ARBION F., BODY G. and BRUNEREAU L.: Contrast enhanced magnetic resonance imaging underestimates residual disease following neoadjuvant docetaxel based chemotherapy for breast cancer. *European Journal of Surgical Oncology (EJSO)*, 30 (10): 1069-76, 2004.
- 18- COWEN D., HOUVENAEGHEL G., BARDOU V-J., JACQUEMIER J., BAUTRANT E., CONTE M., et al.: Local and distant failures after limited surgery with positive margins and radiotherapy for node-negative breast cancer. *International Journal of Radiation Oncology Biology Physics*, 47 (2): 305-12, 2000.
- 19- WASSER K., SINN H., FINK C., KLEIN S., JUNKER-MANN H., LÜDEMANN H., et al.: Accuracy of tumor size measurement in breast cancer using MRI is influenced by histological regression induced by neoadjuvant chemotherapy. *European Radiology*, 13 (6): 1213-23, 2003.
- 20- DIGUISTO C., OULDAMER L., ARBION F., VILDE A. and BODY G.J.Ar.: MRI evaluation of residual breast cancer after neoadjuvant chemotherapy: Influence of patient, tumor and chemotherapy characteristics on the correlation with pathological response, 35 (1): 581-5, 2015.

## تقييم دور فحص الرنين المغناطيسي الديناميكي بالصبغة وباستخدام خاصية الانتشار في تقييم أورام الثدي بعد العلاج الكيماوي ومدى الإستجابة لذلك العلاج ومقارنة تلك النتائج بنتائج التشريح المرضى كمراجع قياسي

في الأونة الأخيرة استخدام الرنين المغناطيسي لتصوير الثدي كوسيلة للوصول للتشخيص الصحيح للحالة في حال تعذر الوصول له بالطرق الإكلينيكية، الماموجرام أو الموجات فوق الصوتية. اليوم يستخدم الرنين المغناطيسي على نطاق واسع في توضيح مدى انتشار المرض في مرضى سرطان الثدي.

يستخدم الرنين المغناطيسي الديناميكي باستخدام الصبغة في توصيف الإصابة بالثدي، فهو يستطيع أن يميز الإصابة الحميدة من الخبيثة بدقة عالية وكذلك حينما لا تستطيع وسائل التصوير الأخرى الوصول لنتيجة فاصلة.

تخضع مريضات سرطان الثدي للعلاج الكيماوي قبل إجراء الجراحة من أجل الوصول لحجم أصغر للورم مما يسهل إجراء جراحة محافظة للثدي. إن التحديد الدقيق لحجم الورم المتبقى بعد العلاج الكيماوي يعتبر عامل مهم في تحديد احتمالية الشفاء من عدمه وكذلك احتمالية نجاة المرضى.

إن التوصيف الخاطئ لحجم الورم المتبقى بعد العلاج الكيماوي بنسبة أكبر مما هو عليه بالفعل يؤدي إلى إطالة فترة العلاج وأستئصال واسع غير مرغوب فيه للورم. بينما توصيف حجم الورم بنسبة أصغر مما هو عليه بالفعل يؤدي إلى عدم استئصال الورم بالكامل وزيادة فرصة الإنتكاسة بعد الخضوع للجراحة.

وقد أوضحت الدراسات السابقة أن الرنين المغناطيسي الديناميكي باستخدام الصبغة له دور فعال في توضيح مدى الإستجابة للعلاج الكيماوي أكثر من وسائل التصوير الإشعاعي الأخرى، بينما قد يكون له بعض النتائج الإيجابية أو السلبية الخاطئة

الهدف من العمل: تقييم دور فحص الرنين المغناطيسي الديناميكي بالصبغة وباستخدام خاصية الانتشار في تقييم أورام الثدي بعد العلاج الكيماوي ومدى الإستجابة لذلك العلاج ومقارنة تلك النتائج بنتائج التشريح المرضى كمرجع قياسي

خطة البحث: تمت هذه الدراسة على أربعين مريضة بسرطان الثدي بمعدل أربعين ورم.

تم اختيار المرضى على أساس هذه القواعد:

- إختيار مريضات سرطان الثدي اللاتي تخضعن للعلاج الكيماوي قبل إجراء التدخل الجراحي.
- أن لا يكون هناك مانع من إجراء فحص الرنين المغناطيسي بالصبغة مثل وجود جهاز التحكم بضربات القلب، وجود زرع قوقعة الأذن، أو وجود حساسية للصبغة المستخدمة في فحص الرنين المغناطيسي.
- كل المرضى خضعوا لفحص الرنين المغناطيسي على النحو التالي:
- فحص الرنين المغناطيسي العادي بدون صبغة.
- فحص الرنين المغناطيسي الديناميكي بالصبغة والذي يفيد في تشخيص نوع و مرحلة أورام الثدي الخبيثة كما أنها تعطينا معلومات عن شكل وحركة الورم ودرجة انتشاره وذلك قبل التدخل الجراحي.
- تصوير الرنين المغناطيسي باستخدام خاصية الانتشار وحساب معامل الانتشار الظاهري.
- بعد ذلك تمت مقارنة نتائج الفحص بالنتائج الهستولوجية للورم.

نتيجة البحث: إثبات فاعلية الرنين المغناطيسي الديناميكي بالصبغة في تحديد حجم الورم المتبقى بعد الخضوع للعلاج الكيماوي في مرضى سرطان الثدي وكذلك تحديد مدى الإستجابة لذلك العلاج وإثبات أن له صحة عالية مقارنة بنتائج التشريح المرضى، إلا أن له بعض النتائج الإيجابية أو السلبية الخاطئة والتي تحد من صحة ودقة هذا الفحص إلا أنها لا تنفي كون هذا الفحص هو الأعلى دقة وصحة في تحديد مدى الاستجابة للعلاج الكيماوي مقارنة بوسائل التصوير الإشعاعي الأخرى المستخدمة كالموجات فوق الصوتية وأشعة الماموجرام.