

Four Petal Evisceration: Pros and Cons

Rehab M. Kamel¹, Doaa A. Mahmoud¹, Ahmed M. Amin²

¹Department of Ophthalmology, Al-Azhar University University, Faculty of Medicine for Girls,

²Department of Ophthalmology, Al-Azhar University University, Faculty of Medicine for Boys,

ABSTRACT

purpose: To evaluate four petals evisceration as one of the best modifications in evisceration surgery, allowing the use of large orbital implant with low incidence of complications.

Methods: We conducted a retrospective, interventional study on evisceration with placement of spherical non porous orbital implant after four petal evisceration. Preoperative examination included full history, ophthalmological examination, indication for surgery, B-scan ultrasonography, axial length in cases of atrophic and socket surface in secondary cases. All patients were operated a four petal evisceration with spherical non porous implant of size 18 to 22. Postoperative, all patients were followed for at least 6 months for presence of complications, implant and prosthesis motility and the final cosmetic results.

Results: 18 eyes were included. Diagnosis necessitating evisceration was atrophica bulbi in 8 patients, endophthalmitis in 2 patients, and implant exposure in 4 patients, corneoscleral melting due to caustic exposure in 1 patient, self-eviscerated globe due to severe trauma in 1 patient and anophthalmic socket following evisceration without implant in 2 patients. Implant size was 18 in 1 patient, 20 in 6 patients, and 22 in 11 patients. No implant exposure occurred; superior sulcus deformity occurred in 3 patients, downward implant migration occurred in 1 patient. Regarding implant motility, it was good with mean of 75% in 14 patients; moderate with mean of 66% in 4 patients. The prosthesis motility was fair with mean of 35% in 12 patients (66.6%) and poor with mean (10%) in 6 patients.

Conclusion: Four petals evisceration facilitates the use of large sized implant in all cases even in implant exposure with deficient sclera with good post-operative final cosmetic results, very low rate of complications and moderate prosthesis motility.

Keywords: four petal evisceration, implant exposure, atrophica.

INTRODUCTION

Evisceration and enucleation are commonly performed procedures in conditions associated with a blind painful eye ^[1], in phthisis for cosmetic appearance and aesthetics and in microphthalmia to enhance bony orbital development ^[2]. In the past, enucleation has been preferred by most surgeons for various reasons, including the fear of sympathetic ophthalmia (SO) after evisceration. However, after recent studies demonstrating the high safety of evisceration and low risk of SO, interest in evisceration has increased because of its advantages ^[3]. Evisceration is technically easier surgery than enucleation, has better functional and aesthetic outcomes over enucleation with more favorable fornix outcomes, better sulcus contour and allow more greater motility of the implant due to less disruption of orbital anatomy particularly the pulley system ^[4]. Also enucleation is associated with a higher rate of postoperative complications like implant exposure and enophthalmus ^{[5], [6]}. Shah *et al* ^[7] in a national survey assessed the practice patterns regarding eye removal among oculoplastic surgeons. They found that surgeons who recently

completed fellowship training are more likely to perform eviscerations than their senior counterparts. The evisceration technique has undergone several modifications with the goals of achieving a lower rate of exposure and allowing colonization of the biointegratable implant by the receptor tissue, as the fibrovascular ingrowth in the implant begins at the sclerotomies ^[8] and to allow implantation of larger orbital implants, which are effective in preventing volume loss after evisceration surgery. However, at the same time, tension on the wound should be minimized to reduce implant exposure. Several investigators have described sclerotomy techniques to enlarge the scleral entry and expand the internal surface area of the sclera. The resultant increase in the scleral capacitance allows placement of larger orbital implants with superior functional and cosmetic results and decreased rates of extrusion ^[9].

MATERIALS AND METHODS

This study included eighteen patients who underwent placement of spherical non porous orbital implant after four petal evisceration. Preoperative examination including diagnosis

necessitating evisceration, B-scan ultrasonography to document pathology and exclude the possibility of intraocular malignancy, axial length was measured in cases of atrophy, socket surface was evaluated in secondary cases. Patients with irradiated orbits and socket surface deficiency who are candidate for dermis fat graft were excluded. Patients counseling and signed an informed consent before surgery. The study fulfilled all the ethical aspects required in human research.

The surgical procedure was four petal evisceration in all patients. The size of implant was documented. During follow-up period all patients were examined for the presence of exposure, migration and deep superior sulcus deformity. After 3 month, implant motility was evaluated by measuring conjunctival excursion in the horizontal movement by marking the center of the conjunctiva with a surgical skin marker and then calculating the value of movement by a ruler with the zero mark in the center and a scale on both sides. The percentage of movement is calculated in relation to the other eye. It was graded as: Good (75% to 100%) Moderate (fair) (25% to 75%) Poor < 25% and No movement (0 %). The motility of the prosthesis was compared to the other eye by using a ruler with a zero mark in the center and scale on both sides adjusting the zero at the center of the pupil and measuring the degree of movement of both eyes in the horizontal gaze. The percentage of movement of the artificial eye in relation to the normal one was then calculating. The final cosmetic appearance was documented. The study was done after approval of ethical board of Al-Azhar university and an informed written consent was taken from each participant in the study.

Surgical Technique

Just before surgery marking of the eye and sign out is performed by the surgeon. Under general anesthesia an eyelid speculum is placed between the eyelids. A 360-degree conjunctival peritomy is performed with Wescott scissors minimal sub-Tenon dissection with Stevens scissors is performed. Anterior chamber (Ac) is entered and complete keratectomy is done, removal of intraocular contents or removal of the exposed implant were done, in secondary cases dissection of the fibrosed sclera was carefully done. Four complete sclerotomies are performed from the limbus, between the recti muscle insertions, to the optic nerve, with every attempt is used to preserve

intermuscular septum. The optic nerve is cut at its insertion point in the posterior sclera and the stump is cauterized. The 4 sclerotomies reach one another to form 4 separate scleral petals, each containing 1 rectus muscle. Estimation of the resultant space is done by metallic sizer. The largest implant allowing closure of the petals without tension was used. Silicon or acrylic orbital implant of 18-22 is placed inside the 4 petals. The 4 petals are brought anterior to the implant. The vertical petals are sutured to each other in front of the implant using a interrupted 5/0 non absorbable braided polyester suture. The horizontal petals are sutured over the vertical petals Conjunctiva and Tenon capsule are both sutured in separate layers with a Vicryl 6/0 continuous horizontal suture. An ocular conformer is placed at the end of the surgery.

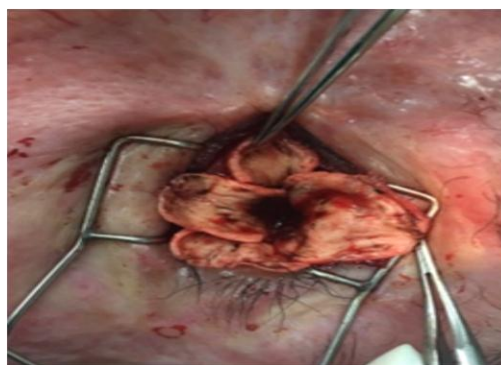


Figure1: Surgical procedure

RESULTS

Over all 18 eyes were included in this study, 11 males (61.1%) and 7 females (38.8%). The patient age ranged between 5 to 56 years. Diagnosis necessitating evisceration was atrophy in 8 patients (44.4%), endophthalmitis in 2 patients (11.1%) , implant exposure in 4 patients (22.2%) , corneascleral melting due to caustic (5.5%) in 1 patient, self-eviscerated globe due to severe trauma in 1 patient (5.5%) and anophthalmic socket following evisceration without implant in 2 patients (11.1%) . Implant size was 18 in 1 patient (5.5%), 20 in 6 patients (33.3%), 22 in 11 patients (61.11 %). Superior sulcus deformity occurred in 2 patients (11.1 %), downward implant migration occurred in 1 patient (5.5%) and there was no implant exposure. Regarding implant motility, it was good with mean of 75% in 14 patients (77.7%) and moderate with mean of 66% in 4 patients (22.2%). The prosthesis motility was fair with mean of 35% in 12 patients

(66.6%) and poor with mean of 15% in 6 patients (33.3%).

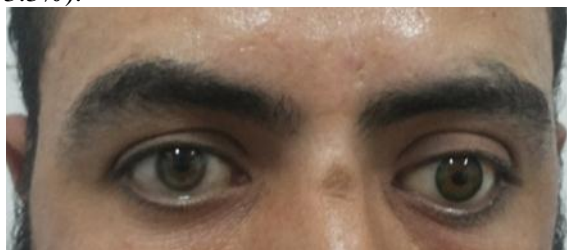

Figure 2: Final post operative cosmetic appearance (Left eye).

DISCUSSION

The importance of complete volume replacement is a primary object of orbital reconstruction procedures^[10]. Insertion of an implant of inappropriate size results in a variety of complications. Excessively, large implants are more prone to extrusion and may compromise the fitting, retention and comfort of the prosthesis. Placement of an abnormally small implant causes a volume deficit in the socket, contributing to a deep superior sulcus and the need for a large, poorly mobile prosthesis^[11]. Standard evisceration techniques typically only allow placement of a 13-16-mm spherical implant. External prosthesis usually are 1.5 mm in sagittal depth, so the best cosmetic results with evisceration are achieved when the orbital implant measures 3 mm less than the axial length of the fellow eye. Considering that eyes that undergo evisceration frequently have small scleral cavities because of phthisis bulbi, usually it is impossible to place an orbital implant greater than 16 mm in a cornea-off evisceration with an overlapped or edge-to-edge scleral closure without a sclerotomy^[12]. The modifications in the evisceration technique to increase the scleral capacitance includes trans-scleral evisceration with a posterior scleral incision^[13]. Massry and Holds in 2001^[9], created two scleral flaps by performing a full-thickness sclerotomy in the inferonasal and superotemporal quadrants. Yang *et al.*^[14] described scleral quadrisection after evisceration, without releasing it from the optic nerve. Four petal evisceration described first by Sales-Sanz & Sanz-Lopez in 2007^[15]. Kim *et al.*^[16], used evisceration with four anterior full thickness scleral relaxing incisions between the recti muscles insertion to the equator, and circumferential posterior sclerotomy surrounding the optic nerve for 330° Huang *et al.*^[17], described a similar technique involving scleral quadrisection and suturing the implant with

each rectus muscle through the scleral petal. In our study we tried to evaluate four petal evisceration as one of those modifications in various indications for evisceration. In comparison to evisceration with four anterior relaxing incisions and circumferential posterior sclerotomies by Kim *et al.*^[16], we have the same results of no migration and good final cosmetic results with easier technique and also in our study we find no great difference between our results and the other authors^{[14] [15][16]} used porous implants with much lower cost, and no implant exposure were reported in any case, this is also reported by other authors^{[15][16][17]}. We believe that four petal evisceration is better than dermis fat graft in cases of implant exposure if minimal socket surface is deficient with shorter anesthesia time and avoiding the morbidity of the donor site and socket fat atrophy. We implanted the largest implant can be used without tension on the flaps in comparison to Elbakery who used the simple formula described by Kaltreider and Lucarelli^[19]. They used implant diameter equals AL of the contralateral eye - 3 mm for the evisceration procedure. We reported superior sulcus deformity due to mild enophthalmos in 11.1 % of cases very similar to Elbakery^[18], who included only the cases of atrophied but we included also other categories with the same results. We included two patients with endophthalmitis with no increase in the rate of complication in comparison to other reports with the usual evisceration technique^[20]. So we conclude that Four petals evisceration facilitates the use of large sized implant in all cases even in implant exposure with deficient sclera with good post-operative final cosmetic results and very low rate of complications and moderate prosthesis motility.

REFERENCES

- 1-Ying Z, Hong Z, Yin-Wei S, Jing-Min G, Xiao-Lan X U, and Jun-Ming W (2015): Autologous sclera-muscle flaps technique in evisceration with hydroxy apatite implantation. *Int J Ophthalmol.*, 8(4): 714–718.
- 2-Moshfeghi DM, Moshfeghi AA and Finger PT (2000): Enucleation. *Surv Ophthalmol.*, 44:277–301.
- 3-Pan JC, Yap EY and Yip CC (2003): Traumatic eye injuries due to large unusual foreign bodies: A Singapore case series. *Eur J Ophthalmol.*, 3:398–402.
- 4-Nakra T, Ben Simon G, Douglas RS *et al.* (2006): Comparing Outcomes of Enucleation and Evisceration. *Ophthalmology*, 113:2270-2275.
- 5-Dortzbach RK and Woog JJ (1985): Choice of procedure. Enucleation, evisceration, or prosthetic fitting over globes. *Ophthalmology*, 92: 1249–1255.

Four Petal Evisceration: Pros and Cons

- 6-Demer JL, Miller JM, Poukens V et al. (1995):** Evidence for fibromuscular pulleys of the recti extraocular muscles. *Invest Ophthalmol Vis Sci.*, 6:1125–1136.
- 7- Shah RD, Singa RM, Aakalu VK, Setabutr P (2012):** Evisceration and enucleation: A national survey of practice patterns in the United States. *Ophthalmic Surg. Lasers Imaging* , 43:425–30.
- 8-Sarvananthan N, Liddicoat AJ, Fahy GT. (1999):** Synthetic hydroxyapatite orbital implants: a clinical and MRI evaluation. *Eye* 13:205–8.
- 9-Massry GG and Holds JB (2001):** Evisceration with scleral modification. *Ophthal Plast Reconstr Surg.*, 17: 42–47.
- 10- Culler AM (1951):** Enucleation and cosmetic rehabilitation; criteria for evaluation of current procedures. *Arch Ophthalmol.*, 45:445–57
- 11-Yousuf SJ, Jones LS and Kidwell ED (2012):** Enucleation and evisceration: 20 years of experience. *Orbit*,31(4):211–215.
- 12-Georgescu D, Vagefi MR, Cheng CC, McCann J and Anderson RL (2010):** Evisceration with equatorial sclerotomy for phthisis bulbi and microphthalmos. *Ophthal Plast Reconstr Surg.*,26(3):165–167.
- 13-Wang J, Zhang H, Chen W and Li G (2012):** The psychosocial benefits of secondary hydroxyapatite orbital implant insertion and prosthesis wearing for patients with anophthalmia. *Ophthal Plast Reconstr Surg.*,28(5):324–327.
- 14- Yang JG, Khwarg SI, Wee WR, Kim DM and Lee JH(1997):** Hydroxyapatite implantation with scleral quadrisection after evisceration. *Ophthalmic Surg Lasers*,28:915–9.
- 15-Sales-Sanz M and Sanz-Lopez A (2007):** Four petal evisceration: a new technique. *Ophthal Plast Reconstr Surg.*,23: 389–392. 2
- 16- Kim KH, Lee H, Park M, Chi Mc, Lee J and Baek S (2011):** Evisceration with four anterior relaxing incisions and circumferential posterior sclerotomies with porous polyethylene orbital implants: An 8-year study. *Acta Ophthalmol.*m 89:686–90.
- 17- Huang D, Yu Y, Lu R, Yang H and Cai J(2009):** A modified evisceration technique with scleral quadrisection and porous polyethylene implantation. *Am J Ophthalmol.* ,147:924–8.
- 18-Elbakary MA (2002):** Four Petals Evisceration for Atrophia Bulbi. *Middle East Afr J Ophthalmol.* ,22 (2): 226-229.
- 19- Kaltreider SA and Lucarelli MJ (2002):** A simple algorithm for selection of implant size for enucleation and evisceration: A prospective study. *Ophthal Plast Reconstr Surg.*, 18:336–41 9.
- 20- Hui JI (2010):** Outcomes of orbital implants after evisceration and enucleation in patients with endophthalmitis. *Curr Opin Ophthalmol.* ,21(5):375-9.