

Original Article

Bone Formation After Maxillary Sinus Floor Elevation Using Titanium Mesh Versus Titanium Screws Without Any Graft Material: A Preliminary Study

Salah Reda Ghanem¹, Mohammed Galal Gamal ElDin Beheiry¹, Ramy El Bialy¹

¹Oral and Maxillofacial Surgery Department, Faculty of Dentistry, Cairo University

Email: salahredaghanem@gmail.com

Submitted: 15-2-2020

Accepted: 16-10-2020

Abstract

Aim: The purpose of the present study is to evaluate the bone volume and quality formed following graftless maxillary sinus lifting through lateral window approach to compare the efficiency of the use of titanium screws versus the use of titanium mesh in preserving the space below the uplifted maxillary sinus membrane allowing for stable blood clot formation in severely atrophied posterior maxillary ridge.

Subjects and Methods: The current study include 10 maxillary sinuses, The study patients were partially or completely edentulous in the posterior maxilla and required unilateral or bilateral maxillary sinus augmentation. All patients were selected from the out-patient clinic of Oral and Maxillofacial Surgery Department, faculty of oral and dental medicine, Cairo University.

Results: The sinuses were divided into two equal groups (study and control groups), both groups underwent maxillary sinus lift procedures using either space-maintaining titanium screws for the study group or space-maintaining titanium mesh for the control group. The study was a double blind one (participants and outcome assessors were blinded throughout the study).

Conclusion: application of titanium mesh with micro screws to support the sinus membrane was easier clinically than using long titanium screws alone, as the accessibility and direction of drilling was more difficult when long titanium screws were used

Keywords: maxillary sinus floor - titanium mesh - titanium screws.

Introduction:

Restoration of the atrophied edentulous posterior maxillary region is considered one of the most significant challenges that face the Oral and Maxillofacial surgeon as well as the restorative dentist.

Implant therapy can predictably replace missing teeth in edentulous patients with adequate bone height and width. Inadequate alveolar bone volume is a common limitation in the posterior maxilla since advanced alveolar bone resorption following premature tooth loss is frequently combined with the

pneumatization of the maxillary sinus. Various maxillary sinus augmentation techniques have involved to overcome the deficiency of bone volume with simultaneous or delayed placement of endosseous dental implants. (Sheikh et al, 2015)

The classic technique for maxillary sinus floor augmentation entails the preparation of the trap door to elevate the schneiderian membrane in the lateral sinus wall. it can be done either in a single stage with simultaneous implant placement or in two stages with delayed implant placement, depending on the available residual alveolar ridge height that necessary for implant primary stability. The new compartment created between the floor of maxillary sinus and the elevated membrane was filled with either autogenous, allografts, xenograft or combination of them to maintain space for new bone formation. The disadvantages of such methods are high costs for grafting material, time consuming and high morbidity, because harvesting of bone grafts is needed. (Stern et al 2012).

Subjects and Methods:

1) Pre-operative evaluation:

After accepting to be enrolled in this study, each patient was interviewed in order to obtain a comprehensive medical and dental history; asking about their habits, any previous complication during local anesthesia or dental extraction. and their compliance in previous treatment procedure.

a. Clinical Evaluation:

A comprehensive intraoral examination of the remaining teeth was performed as well as evaluation of the thickness of the covering tissue, the interarch space for any signs of over-eruption of the opposing mandibular dentition or over space due to extreme resorption of the alveolar ridges

b. Medical Evaluation :

Each patient was given a questionnaire about his medical condition, previous dental procedures and personal information and then patients were interviewed to complete any missing data

c. Radiographic Examination

A. Digital panoramic radiograph was done for each patient as a primary survey to determine the residual alveolar bone height,

B. Cone beam computed tomography (CBCT)

2) Operative procedure

First stage surgery : maxillary sinus floor elevation

using lateral window technique was performed for each patient.

Group A (control group) The Schneiderian membrane was elevated and maintained using a space-maintaining titanium mesh.

Group B (study group) The Schneiderian membrane was elevated and maintained using a space-maintaining titanium screws.

Second stage surgery : After 6 months at the time of implant placement Core biopsy specimens were obtained from the planned implant sites.

Surgical procedure of the first stage (Sinus lift):

- Immediately before the surgery each patient was instructed to rinse with Chlorohexidine Gluconate 0.1 % mouth wash. All the surgical procedures were performed under local infiltration anaesthesia (Articaine HCl 4% with 1: 100 000 vasoconstrictor).
- The flap was performed in the form of Three lines with a mid-crestal incision and extended enough mesially and distally to facilitate flap reflection and provide.
- The Full thickness mucoperiosteal flap was reflected using mucoperiosteal elevator to expose the lateral wall of the maxilla.
- Measurement of the location and dimension of the lateral window based on the preoperative CBCT radiograph and clinical evaluation , round diamond bur of 8mm diameter was used in a straight hand piece under copious saline irrigation, to delineate the outline of the rectangular osteotomy.

Mesh and screws placement

In control group : 0.1 mm thickness micro titanium mesh was then cut and its sharp projections were smoothed then it bent as S- Shape then it was fixed to the lateral wall of the sinus above the superior osteotomy with two 1.5mm micro screws.

In the study group: 2.0 mm screws were fixed to the lateral wall of the sinus above the superior osteotomy and placed buccopalatally where the schneiderian membrane was elevated and maintained.

Then the soft tissue flap was readapted and sutured using continuous and interrupted sutures (3-0 resorbable vicryl)

Surgical procedure of the Second Stage (Implant Placement):

- Second stage surgery was performed 6 months after sinus lift procedure. It involved biopsy harvesting and implant placement.
- Immediately before surgery the patient was allowed to rinse with Chlorohexidine Gluconate 0.1 % mouth wash. All the surgical procedures were performed under local anesthesia ArticaineHcl 4% with 1: 100 000 vasoconstrictor was used
- A crestal incision was performed with anterior releasing incisions, and a full-thickness mucoperiosteal flap was reflected.
- Biopsy harvesting (one biopsy was taken from each sinus).

Results:

Linear Measurements

Descriptive statistics showing mean values, standard deviations (SD), standard error of mean (SEM), median and range (minimum and maximum) for alveolar bone height measured in (mm) recorded for both groups as function of evaluation periods summarized in table (1) and graphically represented in figure (3).

Bone density

Descriptive statistics showing mean values, standard deviations (SD), standard error of mean (SEM), median and range (minimum and maximum) for bone density measured in (HU) recorded for both groups as function of evaluation periods summarized in table (1)

Bone volume

Table (2) shows the means and SD values of bone volume. Comparison between the two groups yielded no statistical significance.

Discussion:

Rehabilitation of the edentulous posterior maxilla with dental implants has proven to be a challenge for the dental implant team due to a deficiency of available bone volume, especially vertical bone height. The inadequate bone volume is a result of ongoing maxillary sinus pneumatization and remodeling of the alveolar crest. Surgical procedures for augmenting the maxillary sinus have evolved during the last decade to give adequate solutions in cases in which insufficient bone volume rendered implant placement impossible (Wallace and Froum 2003).

From the data that extracted from the current study we see clear radiological and histological evidences to bone formation in the sinus after using lateral window technique for the lift while using blood clot alone for the bone formation. Thus, the cost-effectiveness and time-saving benefits are obvious, as instead of using autogenous bone or allografts. While the rate of failure with this technique is similar to those of conventional procedures. There is less contamination associated with this procedure, as no external grafts are involved. With this line of reasoning, a broad and firm consensus has been established regarding the importance of blood clot formation, which serves as autogenous graft filler material for bone regeneration during graftless maxillary sinus lifting.

Therefore the aim of the present study to evaluate the bone volume and quality formed following graftless maxillary sinus lifting through lateral window approach to compare the efficiency of the use of titanium screws versus the use of titanium mesh in preserving the space below the uplifted maxillary sinus membrane allowing for stable blood clot formation.

In the current study, fixed tenting of the sinus membrane by screws that fixed to the superior antral wall played an important role in stabilization of the blood clot volume and subsequent bone formation as documented by Xu et al, in 2005. who found that the newly formed blood clot decrease significantly in volume during the first weeks of healing. indicating the imponance of the a space holder of schindcrian membrane to decrease Its pumping pressure. (Xu et al.2005)

In the current study, trap-door lateral bone window with elevation of the schindcrian membrane from the floor and medial wall of the sinus ,was performed in all cases in order to guarantee complete supporting of the membrane till the medial wall and to be able to identify the trap door vertical bone (above the screws and mesh) as a radiopaque reference line in the CT cuts for linear measurement of the elevated membrane immediately and six months postoperatively.

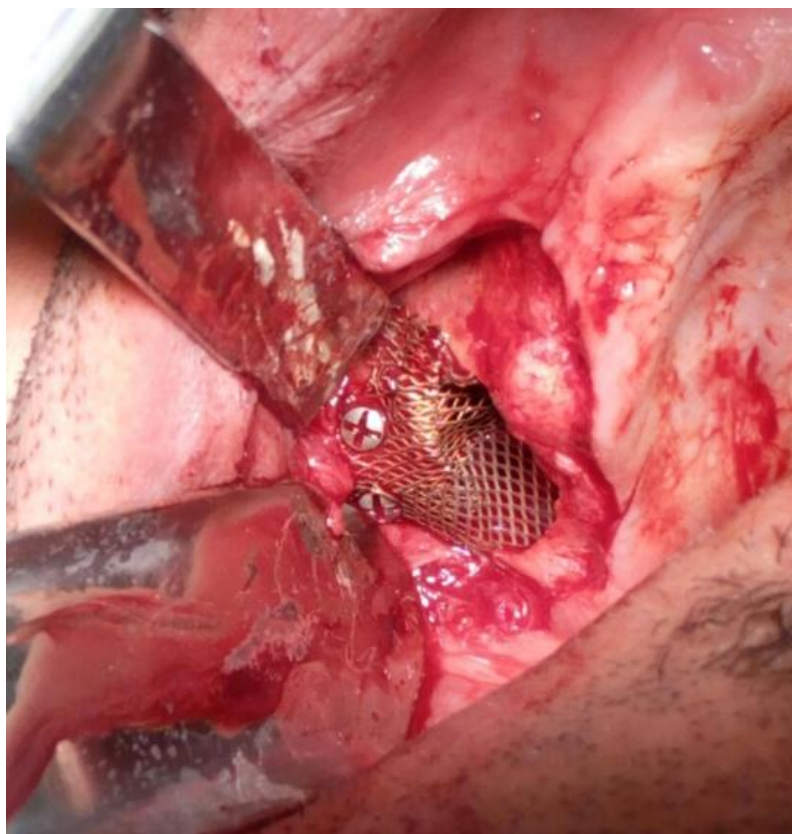


Fig. (1): showing fixation of the titanium mesh to the lateral wall of the sinus with micro screws.

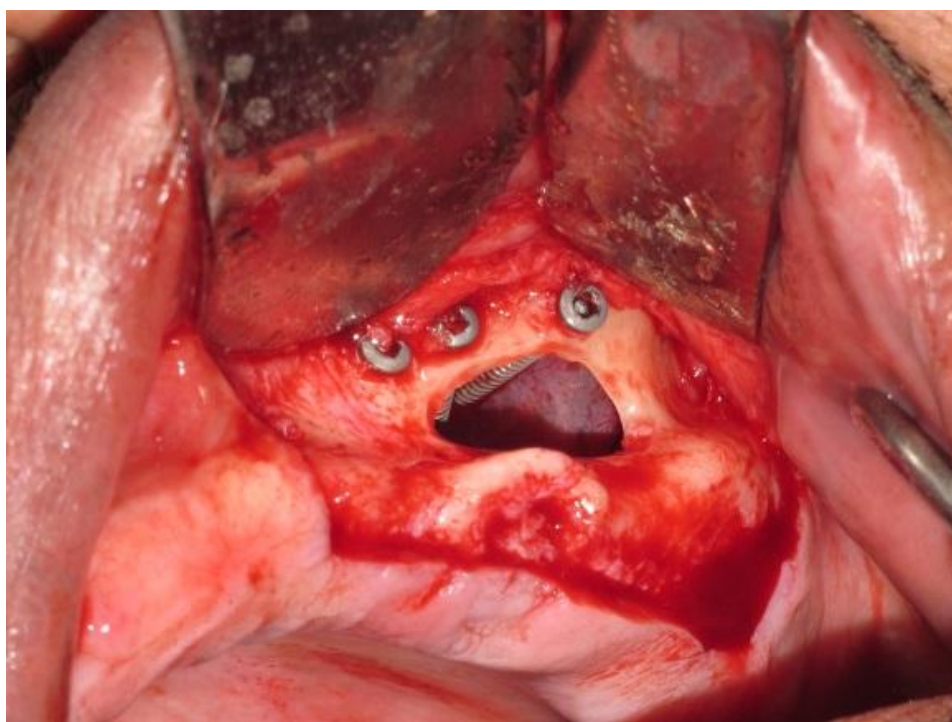


Fig. (2): Schneiderian membrane was elevated and maintained using titanium screws

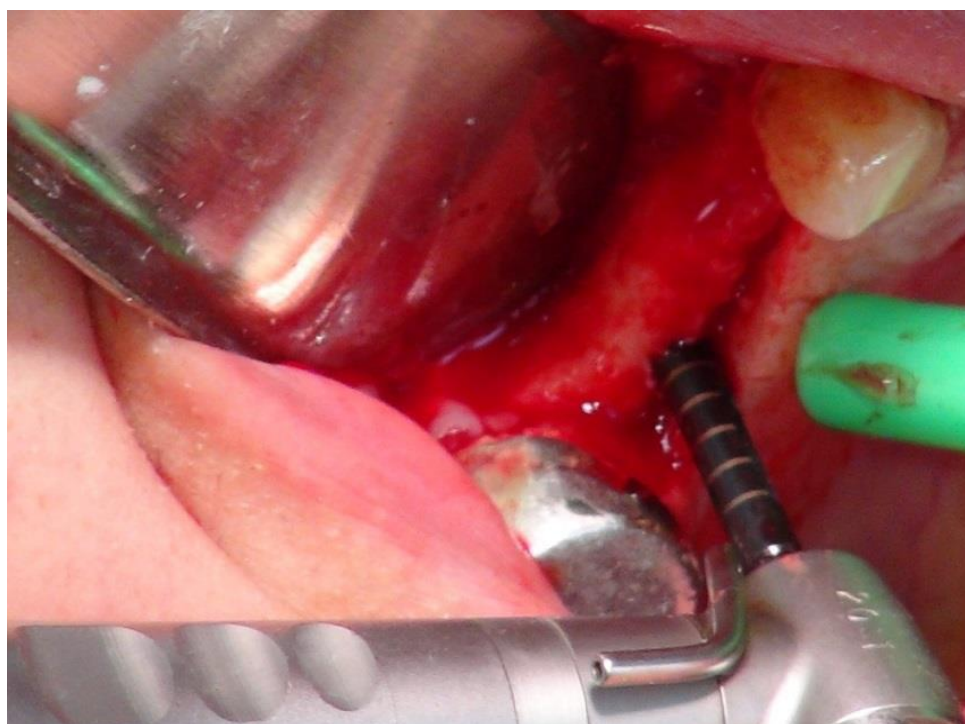


Fig.(3): Retrieving the core biopsy.

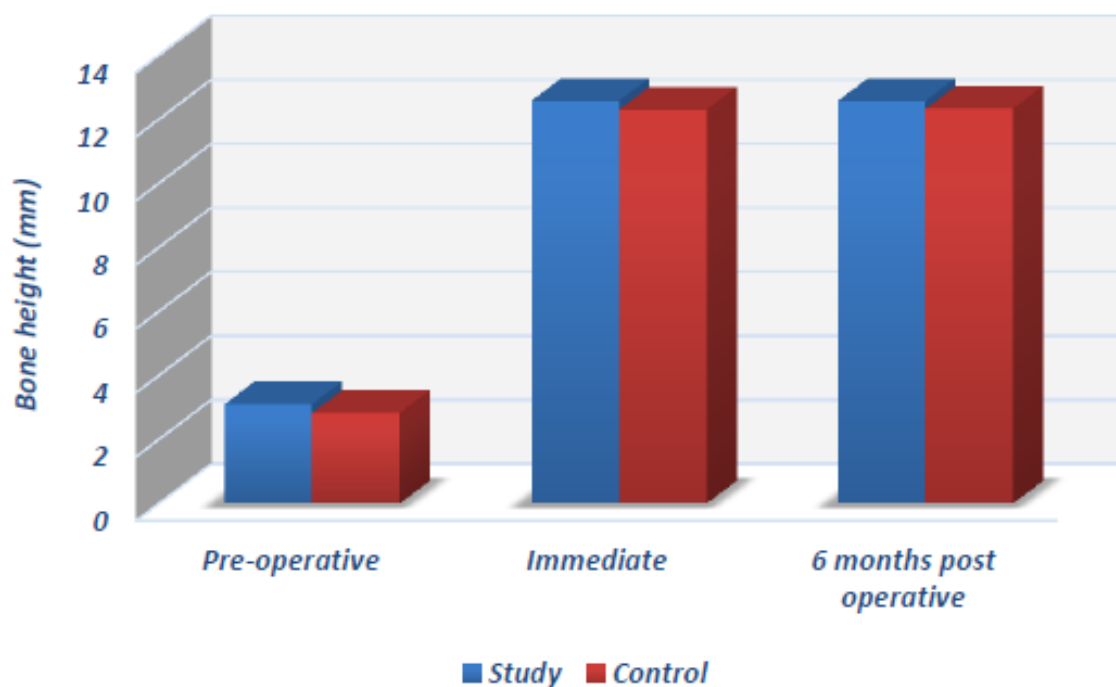


Fig. (4): Column chart showing alveolar bone height mean values for study and control groups at different evaluation periods.

Table (1) : Native and gained bone density in HU for both groups

Group	Native bone density in HU			Gained bone density in HU			t-test	
	mean	min	Max	mean	min	Max	t value	P value
Study	536.72	444.75	656.5	221.75	181.25	395	21.47	<.0001*
Control	504.25	412.75	622.75	216.75	161	339.5	12.31	0.000025*
t-test	t value	1.1		t value	0.233			
	P value	0.3019		P value	0.8218			

Table (2) Bone volume results (Mean values \pm SD) for both study and control groups

		Mean	SD	SEM	Median	Range		Statistics
						Min.	Max.	P value
6 months post operative	Study	56.558	13.18	11.75	57.38	30.46	64.41	0.1269ns
	Control	61.472	8.31	6.5864	62.1	32.86	68.99	

During preparation of the trapdoor in case no. 2 in study group bleeding had been occurred due to injury to the arterial supply of the bony wall. But, no negative outcome was observed as bone formation under the screws was detected.

There are 3 arteries; all are ultimate branches of the maxillary artery that supply the maxillary sinus. The posterior superior lateral nasal artery is relatively close to the sphenopalatine artery and may anastomose with the facial or other nasal arteries. It can course intra-osseously in the medial wall of the sinus. This effect presents the theoretical potential for a significant bleeding complication during lateral approach sinus elevation surgery. (Flanagan et al. 2005).

study for the arterial architecture of the area of the maxillary sinus by Traxler et al, examining the vascularization of the grafting material used in sinus elevation procedures occurs by three routes: the endosseous and extraosseous arterial anastomosis. In the present study, the osteotomies were large enough to make sure that the Titanium mesh covers all the area planned for the bone formation to allow for future implant placement (Traxler et al. 1999).

In the present study there was no membrane perforation occurred, but there are various methods to deal with this complication if it happened, from leaving them untreated after folding, suturing the Schneiderian membrane, and sealing the membrane with resorbable collagen membrane, the reported incidence of perforation in the literature ranges from 10: 60 % of cases. (Lozada et al. 2011).

In the current study no membrane was used to cover the osteotomy site meanwhile this gave a chance for the periosteum of the flap to express its osteogenic effect directly on the bone graft material. This is in agree with finding of Tawil and Mawla (2011) who found that when a membrane is not placed over the window, it is not uncommon to find a lack of corticalization of the graft surface with enclavation through the sinus window. They explained that by the fibrogenic nature of the adult periosteum once it has been elevated from the bone surface. (Tawil and Mawla 2011). In the present study minor enclavation has been seen in most of the cases although it did not affect the bone density or the width for the future

implant placement sites.

The qualitative assessment of CT radiographs showed that new bone formation in the space between the sinus membrane and basal bone in both groups, the bone formation starts from the walls and floor of the maxillary sinus and was completed at the lateral osteotomy site. These findings are general agreement with those of other studies after sinus elevation without any graft materials (Atef et al. 2014. Ahmed et al. 2017).

In conclusion, the current study found that application of titanium mesh with micro screws to support the sinus membrane was easier clinically than using long titanium screws alone, as the accessibility and direction of drilling was more difficult when long titanium screws were used.

References:

- Fermergård R, Åstrand P. Osteotome Sinus Floor Elevation without Bone Grafts - A 3-Year Retrospective Study with Astra Tech Implants. *Clin Implant Dent Relat Res.* 2012;14(2):198-205.
- Cricchio G, Palma VC, Faria PEP, et al. Histological outcomes on the development of new space-making devices for maxillary sinus floor augmentation. *Clin Implant Dent Relat Res.* 2011;13(3):224-230.
- Ahmed M, Abu Shama A, Hamdy RM, Ezz M. Bioresorbable versus titanium space-maintaining mesh in maxillary sinus floor elevation: a split-mouth study. *Int J Oral Maxillofac Surg.* 2017.
- Atef M, Hakam MM, Elfaramawey MI, Abou-Elfetouh A, Ekram M. Nongrafted sinus floor elevation with a space-maintaining titanium mesh: Case-series study on four patients. *Clin Implant Dent Relat Res.* 2014:893-903.
- Traxler H, Windisch a, Geyerhofer U, Surd R, Solar P, Firbas W. Arterial blood supply of the maxillary sinus. *Clin Anat.* 1999;12(June 1998):417-421.
- Wallace SS, Froum SJ. Effect of Maxillary Sinus Augmentation on the Survival of Endosseous Dental

Implants. A Systematic Review. *Ann Periodontol.* 2003;8(1):328-343.

- Boyne PJ, James RA. Grafting of the Maxillary Sinus Floor with Autogenous Marrow and Bone. *Journal of oral surgery (American Dental Association : 1965)* 38, 613-616 (1980).
- Falah M, Sohn DS, Srouji S. Graftless sinus augmentation with simultaneous dental implant placement: clinical results and biological perspectives. *Int J Oral Maxillofac Surg.* 2016;45(9):1147-1153.