

IJMA



INTERNATIONAL JOURNAL OF MEDICAL ARTS

Volume 3, Issue 1 (Winter 2021)

<http://ijma.journals.ekb.eg/>

Print ISSN: 2636-4174

Online ISSN: 2682-3780



Available online at Journal Website
<https://ijma.journals.ekb.eg/>
Main subject [Urology]*



Original article

Value of Intraoperative Ultrasound in Decreasing Incidence of Residual Radiolucent Stones Post-PCNL

Mohammed Mohammed Aboelmagd^[1]; Andrew Jones^[2]; Nabeel Kuwajjo ^[3]; Jalal Al shareef^[4]; Ibrahim Salman^[5]; Shady Soliman^[6]

Al Hada Hospital, Urology Department, Taif University, Saudi Arabia. Mater University Hospital, Urology Department, University College Dublin, Ireland.^[1]

Mater University Hospital, Urology Department, University College Dublin, Ireland^[2]

The Galway Clinic - Royal College of Surgeons in Ireland^[3]

Al Hada Hospital, Taif region, Urology Department, Taif University, Kingdom of Saudi Arabia ^[4]

Al Hada Hospital, Urology Department, Taif University, Kingdom of Saudi Arabia; Benha University, Egypt ^[5]

Al Hada Hospital, Urology Department, Taif University, Kingdom of Saudi Arabia; Urology Department, Mansoura University, Egypt^[6]

Corresponding author: Mohammed Mohammed;

Email: urodraboelmagd@yahoo.com

Received at: May 11, 2020; Revised at: October 17, 2020; Accepted at: October 17, 2020

DOI: [10.21608/ijma.2020.29998.1125](https://doi.org/10.21608/ijma.2020.29998.1125)

ABSTRACT

Background: Percutaneous nephrolithotomy (PCNL) is the gold standard treatment for large renal calculi. The primary goal of treatment is absolute clearance of stone. The incidence of residual stones after PCNL ranges from 10% to 60% and may be higher in radiolucent stones.

Aim of work: Our objective was to assess the effectiveness of using ultrasound during PCNL in patients with radiolucent stones in reducing the incidence of residual fragments postoperatively.

Patients and Methods: This was a single-center prospective study over a 6 year period. We identified 86 patients undergoing PCNL with radiolucent stones. Ultrasound was used in conjunction with traditional fluoroscopy to identify residual fragments. Each patient had a first-day postoperative computed tomography to assess for residual fragments. The sensitivity of ultrasound with fluoroscopy was compared to clinically or radiologically [CT] detected residual fragments.

Results: Our overall stone clearance rate was 82.6% [as evidenced by postoperative CT]. The sensitivity of intraoperative ultrasound, when compared to postoperative CT, was 95.8%, specificity 40.0%, the positive predictive value 88.3%, and negative predictive value 66.7%

Conclusions: The use of intraoperative ultrasound during PCNL for radiolucent stones may help in the reduction of postoperative imaging. However, future studies are recommended.

Keywords: Percutaneous Nephrolithotomy; Radiolucent; Residual fragments; Ultrasound; Stone clearance.

This is an open-access article registered under the Creative Commons, ShareAlike 4.0 International license [CC BY-SA 4.0] [<https://creativecommons.org/licenses/by-sa/4.0/legalcode>].

Please cite this article: Aboelmagd MM, Jones A, Kuwajjo A, Al shareef J, Salman I, Soliman S. Value of Intraoperative Ultrasound in Decreasing Incidence of Residual Radiolucent Stones Post-PCNL. IJMA 2021; 3[1]: 962- 966. DOI:10.21608/ijma.2020.29998.1125.

* Main subject and any subcategories have been classified according to the research topic.

INTRODUCTION

Percutaneous Nephrolithotomy [PCNL] is a standard technique for renal calculi treatment. The aim of the intervention is complete stone clearance. However, the stone-free rate ranged between 40 to 90% depending on many factors [e.g., the case's complexity, stone structure, stone site, and size]^[1].

Residual fragments [RF] are associated with different morbidity [e.g., additional need for further surgical intervention and recurrent urinary tract infection] and mortality^[2-3].

Nowadays, Computed tomography [CT] is considered the gold-standard imaging modality for renal calculi with high sensitivity and specificity^[4-5].

However, CT is not available in all centers and usually necessitates patient transmission, with marked exposure to radiation. Thus, a search for another imaging modality with compared sensitivity and specificity, which could be readily available, portable, and radiation-free, is continuing. Ultrasound could represent an optimal alternative. Another important advantage of ultrasound is its potential ability to detect radiolucent renal stone, which represents about 10.0% of all renal calculi^[6].

An additional problem during PCNL is the risk of stone dislocation to an invisible or inaccessible place. In addition, multiple stones represented a challenge when it is difficult to navigate through the kidney to illustrate all stones. A fluoroscopic guidance is effective for the detection of large radiopaque stones. But, small, radiolucent stones and stones overlying bony structures are easily missed, with overestimation of stone free-rate an increased need for future surgery^[7-8].

Many trials and interventions are present aiming to reduce the incidence of residual stone fragments. However, the challenge continues after all interventions.

AIM OF THE WORK

The current study aims to examine the effect of intra-operative ultrasound in reducing the residual stone fragments in patients with radiolucent renal calculi.

PATIENTS AND METHODS

This prospective single center study was completed between September 2011 and June 2019. All patients with complex radiolucent renal calculi for primary PCNL were included.

We defined complex renal calculi as staghorn stones (either partial or complete) or associated calyceal stones (figure 1). We defined radiolucent calculi as those which could not be seen on plain film X-ray of kidney, ureter, and bladder [KUB]. If we could not definitely assess renal anatomy by ultrasound [due to body composition for example], the patient was excluded from the study.

The study protocol had been approved the local research and ethics committee of Hada armed forces hospitals, Taif, Saudi Arabia; and study had been completed according to ethical codes of Helsinki declaration. An informed consent was signed by each of all participants.

All procedures were performed under the guidance of one consultant urologist in Al-Hada armed forces hospitals, Taif, Saudi Arabia. All procedures were performed in the urology suite in main theatre with availability of C-arm. Cystoscopy, retrograde pyelogram and insertion of an occlusion ureteric catheter was performed with the patient in lithotomy position. After turning the patient to the prone position, the most appropriate calyx was punctured using both fluoroscopic and ultrasound guidance. Multiple tract PCNL was used in certain cases. Mixed pneumatic and ultrasonic lithotripters with continuous suction were used in all cases. Flexible nephroscopy with the use of holium laser lithotripsy was used for selected cases. Intra-operative ultrasound (3.5MHZ abdominal probe) was used in assessment of residual radiolucent stones and any detected stones were operated by the surgeon accordingly.

On the first postoperative day all patients had a non-contrast CT to evaluate for residual fragments. We defined radiological stone clearance as clearance of all fragments >2mm in size. Pre and postoperative CT scans were compared to assess the percentage of remaining stone burden.

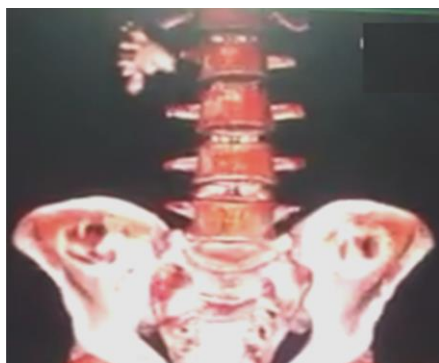


Figure [1]: Noncontrast CT with coronal reconstruction showing complete staghorn stone in the right kidney

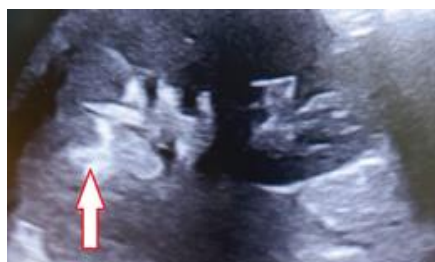

Figure [2]: Intraoperative ultrasound shows the residual stone in the upper calyx of the right kidney for the same above patient in figure No 1

Statistical analysis of data: All statistical calculations were performed by statistical package for social science, version 16 (SPSS Inc., USA). Frequency and percentages were calculated for qualitative data, while mean and standard deviations were calculated for quantitative data. Appropriate tests used to perform the comparison between groups: Chi-square or Fisher exact for qualitative and independent samples “t” test for numerical, normally distributed variables. For calculation of sensitivity and specificity, a 2 x 2 table was performed, and equations were used for calculation as presented in tables. P-value < 0.05 was considered as the cutoff for significance.

RESULTS

Between September 2011 and June 2019, 87 patients with radiolucent stones were identified. One patient was excluded to give us a final number of 86 (n=86). Patient demographic analysis revealed that 62.8% (n=54) were male and 37.2% (n=32) were female. The average BMI was 25.67 ± 1.72 kg/m² and the average age was 45.02 ± 7.98 years. The PCNL was on the right side of 39.5% of patients and on the left side in 60.5% [Table 1].

The average stone diameter within our cohort was 3.75 ± 0.35 cm. Total operative time ranged between 64 to 102 minutes with an average of 80.88 ± 9.18 minutes. The intraoperative ultrasound indicated that we had achieved complete clearance of renal calculi in 77 patients (89.5%), with inaccessible residual fragments in 9 patients (10.45%). On the other side, postoperative CT revealed we had achieved complete radiological clearance in 71 patients (82.6%) with radiologically proven residual fragments in 15 patients (17.4%) [Table 2].

Within the group of patients with radiologically proven residual fragments (n=15), nine had been identified as having residual fragments on ultrasound, and six had been assessed to be ultrasonically clear. Within the group of patients which had been assessed to be stone free ultrasonically intra-operative (n=77), 71 were found to be radiologically stone-free, with six patients having residual stone fragments. The overall sensitivity of ultrasound in detecting residual fragments is 95.8%, specificity 40.0%, the positive predictive value 88.3%, and a negative predictive value of 66.7% [Table 3].

Table [1]: Patient characteristics

Variable	Male [n=54]	Female [n=32]	Total	Test	P
Age [years]	44.90±8.67; 26-62	45.21±6.79; 29-62	45.02±7.98;29-62	0.17	0.68
BMI [kg/m ²]	25.77±1.70; 23-29	25.50±1.77; 23-29	25.67±1.72;23-29	0.72	0.47
Side [n,%]	Right	19(35.2%)	15(46.9%)	34(39.5%)	1.14
	Left	35(64.8%)	17(53.1%)		

Table [2]: Peri-operative data among studied populations

Variable	Male [n=54]	Female [n=32]	Total	Test	P
Stone dimension	3.73±0.34	3.77±0.38	3.75±0.35; 2.90-4.50	0.52	0.60
Operative time	80.11±9.19	82.18±9.17	80.88±9.18; 64-102	1.02	0.31
Intraoperative US	Clear	48(88.9%)	29(90.6%)	77(89.5%)	0.06
	Inaccessible F	6(11.1%)	3(9.4%)		
Postoperative CT	Clear	43(79.6%)	28(87.5%)	71(82.6%)	0.86
	Residual F	11(20.4%)	4(12.5%)		

Table [3]: Sensitivity of ultrasound in relation to computed tomography

		CT			
		Cleared [71]		None [15]	
		n	% U/S	n	% U/S
US	Cleared	68	95.8%	9	60.0%
	None	3	4.2%	6	40.0%
Sensitivity		TP/TP+FN = 68/ 68+ 3 = 95.8%			
Specificity		TN/TN+FP= 6/6+9 = 40.0%			
PPV		TP/TP+FP = 68+68+9 =88.3%			
NPV		TN/TN+FN = 6/6+3= 66.7%			

DISCUSSION

The incidence of renal calculi progressively increases in recent decades. This was associated with the increased use of already limited resources. The most effective treatment modality is associated with the best clearance rate [9-10]. Percutaneous nephrolithotomy is still the standard of care. However, it had a high rate of residual fragments^[2].

As PCNL is widely practiced, different techniques were described to locate residual fragments. However, intraoperative adjuvants were not widely practiced. **Portis et al.**^[11] described the use of high magnification rotational fluoroscopy in conjunction with aggressive nephroscopy with some success.

To the best of our knowledge, the use of intraoperative ultrasound has not been widely used before to reduce the rate of residual fragments, although ultrasound-guided PCNL is widely described. However, most studies assess the residual by different postoperative imaging modalities. The computed tomography is the most accurate. Thus, it was used as a standard for comparison in the current work.

The current work results revealed that intraoperative ultrasound is highly sensitive for detecting residual fragments compared to standard postoperative computed tomography. **Harraz et al.**^[12] compared intraoperative identification of the surgeon's residuals to postoperative non-contrast CT in 236 procedures. They reported that CT detected 72.0% of stone free. The clinical surgeon decision's sensitivity was 50%, specificity 97%, PPV 93.0%, and NPV was 72.0%. When compared to the current work, intraoperative ultrasound did better than the surgeon.

Another important advantage of the US is the reduction of the risk of ionizing radiation exposure by monitoring the whole PCNL. It is the most obvious advantage of intraoperative ultrasound for both patient and the operative team. The intraoperative ultrasound had many other potential advantages when used to guide PCNL. First, it could be performed while the patient is sitting in any position. Second, ultrasound easily identifies the posterior calyx compared to fluoroscopy, which favors the collecting system's access. Third, the US provides real-time imaging of any renal pathology (i.e., cysts, calyceal diverticula, tumors) and surrounding viscera to reduce the potential risk of organ injury. In addition, Doppler imaging guards against intra-renal blood vessel injury^[13].

Additional advantages had been provided by the current work and included its ability to reduce the risk of residual fragments as its high sensitivity in the detection of residuals when compared to postoperative computed tomography. However, both false positive and false negative cases were encountered. This represents some shortage of intraoperative ultrasound.

Regardless of the used modality for the diagnosis of residual fragments, the stone-free rate in the current study is within the reported rate in literature [76–84% or even higher]^[14-15].

The study limitation includes the small number of included patients, which was inevitable due to strict inclusion criteria of radiolucent stones. In addition, the absence of a comparison group represents another limiting step against the generalization of the current research results. However, the study's strengths include its uniqueness in the use of intraoperative ultrasound [feasible, readily available, radiation free with low cost tool], which showed significant sensitivity

compared to postoperative CT. This could be associated with a reduction of residual stones and its requirement for further surgical interventions.

Financial and Non-Financial Relationships and Activities of Interest

None

REFERENCES

1. **Van den Broeck T, Zhu X, Kusters A, Futterer J, Langenhuijsen J, d'Ancona F.** Percutaneous Nephrolithotomy with Intraoperative Computed Tomography Scanning Improves Stone-Free Rates. *J Endourol.* **2020** Sep 7. doi: 10.1089/end.2020.0365. Epub ahead of print.
2. **Emmott AS, Brotherhood HL, Paterson RF, Lange D, Chew BH.** Complications, Re-Intervention Rates, and Natural History of Residual Stone Fragments After Percutaneous Nephrolithotomy. *J Endourol.* **2018**;32(1):28-32. doi:10.1089/end.2017.0618
3. **El-Nahas AR, El-Assmy AM, Madbouly K, Sheir KZ.** Predictors of clinical significance of residual fragments after extracorporeal shockwave lithotripsy for renal stones. *J Endourol.* **2006** Nov; 20(11):870-4. doi: 10.1089/end.2006.20.870.
4. **Moore CL, Carpenter CR, Heilbrun ML, Klauer K, Krambeck AC, Moreno C, et al.** Imaging in suspected renal colic: systematic review of the literature and multispecialty consensus. *J Urol.* **2019** Sep; 202(3):475-483. doi: 10.1097/JU.000000000000342.
5. **Brisbane W, Bailey MR, Sorensen MD.** An overview of kidney stone imaging techniques. *Nat Rev Urol.* **2016** Nov;13(11):654-662. doi: 10.1038/nrurol.2016.154.
6. **Sibley S, Roth N, Scott C, Rang L, White H, Sivilotti MLA, Bruder E.** Point-of-care ultrasound for the detection of hydronephrosis in emergency department patients with suspected renal colic. *Ultrasound J.* **2020** Jun 8; 12(1):31. doi: 10.1186/s13089-020-00178-3.
7. **Zhu M, Wang X, Shi Z, Ding M, Fan D, Wang X, Jiang R.** Comparison between retrograde intrarenal surgery and percutaneous nephrolithotripsy in the management of renal stones: A meta-analysis. *Exp Ther Med.* **2019** Aug;18(2):1366-1374. doi: 10.3892/etm.2019.7710.
8. **Bryniarski P, Paradysz A, Zyczkowski M, Kupilas A, Nowakowski K, Bogacki R.** A randomized controlled study to analyze the safety and efficacy of percutaneous nephrolithotripsy and retrograde intrarenal surgery in the management of renal stones more than 2 cm in diameter. *J Endourol.* **2012** Jan;26(1):52-7. doi: 10.1089/end.2011.0235.
9. **Sorokin I, Mamoulakis C, Miyazawa K, Rodgers A, Talati J, Lotan Y.** Epidemiology of stone disease across the world. *World J Urol.* **2017** Sep;35(9):1301-1320. doi: 10.1007/s00345-017-2008-6.
10. **Romero V, Akpınar H, Assimos DG.** Kidney stones: a global picture of prevalence, incidence, and associated risk factors. *Rev Urol.* **2010** Spring;12(2-3):e86-96. PMID: 20811557.
11. **Portis AJ, Laliberte MA, Drake S, Holtz C, Rosenberg MS, Bretzke CA.** Intraoperative fragment detection during percutaneous nephrolithotomy: evaluation of high magnification rotational fluoroscopy combined with aggressive nephroscopy. *J Urol.* **2006** Jan; 175(1): 162-5; discussion 165-6. doi: 10.1016/S0022-5347(05)00052-2.
12. **Harraz AM, Osman Y, El-Nahas AR, Elsayy AA, Fakhreldin I, Mahmoud O, El-Assmy A, Shokeir AA.** Residual stones after percutaneous nephrolithotomy: comparison of intraoperative assessment and postoperative non-contrast computerized tomography. *World J Urol.* **2017** Aug; 35(8): 1241-1246. doi: 10.1007/s00345-016-1990-4.
13. **Beiko D, Razvi H, Bhojani N, Bjazevic J, Bayne DB, Tzou DT, Stoller ML, Chi T.** Techniques - Ultrasound-guided percutaneous nephrolithotomy: How we do it. *Can Urol Assoc J.* **2020** Mar; 14(3):E104-E110. doi: 10.5489/cuaj.6076.
14. **de la Rosette J, Assimos D, Desai M, Gutierrez J, Lingeman J, Scarpa R, Tefekli A; CROES PCNL Study Group.** The Clinical Research Office of the Endourological Society Percutaneous Nephrolithotomy Global Study: indications, complications, and outcomes in 5803 patients. *J Endourol.* **2011** Jan;25(1):11-7. doi: 10.1089/end.2010.0424.
15. **Abdelhafez MF.** Residual Stones after Percutaneous Nephrolithotomy. *Med Surg Urol* **2013**, 2(2): 3 pages. doi:10.4172/2168-9857.1000115

International Journal

<https://ijma.journals.ekb.eg/>

Print ISSN: 2636-4174

Online ISSN: 2682-3780

of Medical Arts