

RADIOGRAPHIC EVALUATION OF THE EFFECT OF DIFFERENT MINI-IMPLANTS DISTRIBUTION ON POSTERIOR MANDIBULAR RIDGE HEIGHT IN MANDIBULAR MINI-IMPLANTS ASSISTED OVERDENTURES CASES. AN 6-YEAR RETROSPECTIVE STUDY

Kawkb Mohmad Tamimi* and Ahmad Mohmad Elrawdy**

ABSTRACT

Statement of problem: Mandibular overdentures assisted by mini-implants induce severe bone changes in posterior mandible.

Purpose: This study aimed to evaluate the posterior mandibular ridges height changes using the digital panoramic radiographic technique under mandibular overdentures assisted by four mini-implants, in case of interforaminal distribution and in case of wide distribution after wearing overdentures for 6 years.

Methods and material: The subjects enrolled for this study (n = 20). They were treated with maxillary complete dentures, randomly assigned into two equal groups: **Group (I)** received mandibular overdentures assisted by four mini-implants distributed equally in the interforaminal region, exposed to immediate loading protocol. **Group (II)** received mandibular overdentures assisted by four mini-implants (two mini-implants inserted in canine regions and two mini-implants inserted in first molar regions) exposed to immediate loading protocol. Digital panoramic radiographic evaluation of posterior mandibular region was done for every patient of both groups, recorded at the time of mini-implants insertion and after 6 years.

Results: There was statistically significant difference in bone heights changes between interforaminal and wide distribution groups after six years. There was bone apposition in the wide distribution at 15mm and 20mm distal to mental foramen.

Conclusion: Posterior mini implants placement resulted in improved denture support and minimal overdenture displacement. The functional load on posterior mini implants has a positive effect on preservation of the residual alveolar ridge. Wide mini implants distribution is an acceptable alternative prosthodontic design to four-interforaminal mini implants distribution when anatomical and economical factors permit.

Keywords: Mini-implants distributions, mini-implants assisted overdenture, posterior mandibular ridge height changes, wide distribution, interforaminal distribution, digital panoramic radiographic evaluation.

* Department of Prosthodontics, Faculty of Dentistry, Suez Canal University.

** Assistant Professor, Oral Radiology Department, Faculty of Dentistry, Suez Canal University

INTRODUCTION

Complete dentures posse multiple deficiencies such as insufficient retention, stability and decreased chewing efficiency ⁽¹⁾. These drawbacks are aggravated by residual ridge resorption due to overall remodeling following teeth extraction and denture use ⁽²⁾. An implant-stabilized overdenture is treatment modality that removes many of the complete dentures problems and gets better function and comfort for edentulous patients. ⁽³⁾ The presence of implants to stabilize an overdenture will preserve the remaining bony ridge ⁽⁴⁾.

The mini implants are 3mm in diameter. ⁽⁵⁾ Mini-implants may be the best choice of treatment for patients with inadequate ridge width, which does not allow the placement of conventional sized implants without further surgical procedures ⁽⁶⁻⁹⁾. Four mini-implants at the interforaminal region have been exposed for immediate loading with mandibular overdentures ^(6, 8, 10, 11). These mini-implants were able to improve the mandibular overdenture's retention, the patient's life quality, the patient's satisfaction, and the chewing ability of the overdenture wearers^(6,8).

This improvement in oral functions and bite force in two or four implants assisted overdentures may cause more stress concentration that does not exist in conventional denture ⁽¹⁾. Due to the fixation of the overdenture anteriorly in the interforminal area, the axial direction of force and the free movement posteriorly may induce more resorption posteriorly than anteriorly ^(12,13).

Studies recommended the interforaminal implant overdenture as a suitable way of treatment of edentulous mandible without considering for posterior bone resorption ⁽¹⁴⁾.

Jacobs et al⁽¹²⁾ found more posterior mandibular ridge resorption in implant retained overdenture cases than complete denture cases over the same period. *Marjolein et al* ⁽¹⁾ reported a significant

difference in posterior ridge resorption between two and four implants assisted overdenture. For two implants, assisted overdenture the vertical posterior bone loss was 1.44 mm in 10 years. For four implants assisted overdenture the vertical posterior bone loss was 0.74 mm over the same period.

Wright et al ⁽¹⁵⁾ found that patients treated with implant-stabilized mandibular overdentures showed low rates of posterior mandibular residual ridge resorption, of 0.5 mm over 5 years whereas *Kordatzis et al*⁽¹⁶⁾ reported 0.69 to 1 mm of posterior residual ridge resorption over the same period. *Raedel et al*⁽¹⁴⁾ found posterior bone resorption of two implants bar retained overdentures was 1.5 mm in 10 years.

Panoramic radiography is commonly used in large institutional practices as good method of screening edentulous and dentate patients ⁽¹⁷⁾.

The panoramic radiographs of the jaws is part of the preprosthetic examination provide a graphic picture of bone resorption, especially in the mandible. In films of edentulous mandible, the superior and inferior borders of the mandible and the mental foramen are the only remaining radiographic landmarks in the body of the mandible. The present research used the image of the mental foramen as a reference point for assessment of the amount of alveolar bone resorption ⁽¹⁸⁾.

We pose the following question because of this situation: is the wide distribution of mini-implants in mandibular arch improves posterior ridge resorption.

MATERIALS AND METHODS

Sample size calculation

The sample size for this study was calculated according to *Arkin* ⁽¹⁹⁾ and *Jaykaran* and *Tamghna*⁽²⁰⁾ used the following equation:

$$N = \frac{(Z\alpha)^2 \times (SD)^2}{(D)^2}$$

N = Total sample size

$Z\alpha$ = Is Standard normal variate and its equal 1.96 at $P < 0.05$

SD = Standard diversion of variable

d = Absolute error or precision

$Z\alpha$	SD	d
1.96	4.55	2

Total Sample size $N = \frac{(1.96)^2 \times (4.55)^2}{(2)^2} = 19.883 \approx 20$ samples

Twenty male patients had completely edentulous ridges selected from the outpatients clinic, faculty of dentistry, suez canal University. The study protocol was explained in details to all patients and their consents for participating in the study were taken.

Patient selection

The selected patients had the following criteria: Free from any systemic diseases detected by blood / urine analysis that may affect bone quality and quantity. Their ages ranged from 50 to 60 years old with adequate inter-arch space, had a good oral hygiene, angle's Class I jaw relationship with adequate height of the residual ridges, no bad habits including heavy smoking, bruxism, clenching or tongue thrusting.

Dentures insertion

Upper and lower acrylic complete dentures were delivered to all patients with lingualized occlusal scheme with anterior light contact. The patients were recalled for necessary adjustments.

Patients grouping

The patients were divided into two equal groups according to mini-implants distribution.

Group I: The patients received four mini-implants distributed equally in the interforaminal region and exposed to immediate loading protocol.

Group II: The patients received four mini-implants, one mini-implant installed in the canine

region, and one mini-implant installed in the first molar region in each side of the arch and exposed to immediate loading protocol.

Mini-implants insertion

The finished lower denture duplicated for each patient and processed in transparent acrylic resin radiographic stent. At the proposed site for each mini-implant, holes were drilled through the fitting surface of the stent to accommodate a stainless-steel ball (2mm diameter). The balls were totally submerged into the holes. Panoramic radiograph was made with the radiographic stent in the patient's mouth. The ball's images were used to assess the bone height at the proposed mini-implant sites. According to the flapless surgical technique with atraumatic osteotomy and adjustable torque ratchet, four mini-implants (Dentium Co., Korea) 2.5 mm in diameter and 10 or 12 mm in length were used according to bone height. The mini-implant sites in group I were four mini-implants distributed equally in the interforminal area. A minimum of 5mm mesio-distal distance was kept between adjacent mini-implants in group (I). The mini-implants sites in group (II) were two mini-implants in cusped area and another two mini-implants in the first molar area in each side of the mandible. The mini-implants were installed by using the single-stage flapless surgical approach.

Direct Pick-up Procedure

As soon as the four mini-implants installed, undercut areas around the mini-implant heads were covered using sterile orthodontic O-rings. The female metallic housing caps were placed on the mini-implants. The female house surface marked with marker; the lower denture seated in patient's mouth. The areas opposing the housings were marked on the tissue surface of the denture. The marked areas were removed, until a clearance space of about 1-2mm. was provided around the metallic housings. The maxillary and mandibular dentures were seated into the patient's mouth to verify the complete seating of the lower denture without any interferences,

rocking or occlusal discrepancy. Four holes were then created in the lingual flange below the artificial teeth to allow the escapement of excess material.

A special type of self-cured acrylic resin that does not generate heat (Secure Hard Pick-Up Kit, 3M ESPE, USA) was mixed and applied in the dough stage to the relieved areas of the fitting surface of the denture. The mandibular denture was resealed in the patient's mouth. The patient was instructed to close in centric occlusion. After complete polymerization, the denture was removed from the patient's mouth picking up the metal housings. Excess material was trimmed using finishing stone, the mandibular mini-implants assisted over-denture was repolished and delivered to the patient, and the denture was placed in immediate functional loading on the same day of mini-implants placement.

Radiographic evaluation

Bone height measurements (Linear analysis)

The patients were subjected to two consecutive Direct digital panoramic radiographs, initial record after completing implants insertion (T0), and the final record after 6-years post-insertion (T6) respectively. The panoramic images were performed using digital panoramic machine (Sirona, ORTHOPHOS XG5 Ds/ Ceph., Germany) with CCD sensor technology and 27µm pixel size. The exposure parameters for all patients was 64KVp, 8Ma, and 14.1sec exposure time. All images were captured, analyzed processed and stored using SIDEXIS XG software (SIDEXIS

XG image processing software, Sirona Dental System, Germany).

The patients were positioned according to the standard procedure described by Stuart and Michael (21), as follows:

- The patient head was carefully aligned in the focal trough so the both arches are located in the middle of the focal trough.
- We removed the bite block, instead we placed the metal bar in such case the arch facing toward the column.
- The upper and lower arches are in line by using cotton pellet between them.
- The midsagittal plane was adjusted within the exact of focal trough and perpendicular to the floor.
- The Frankfort plane was aligned parallel with the floor.
- The patient's back and spine was adjusted to be erect with extended neck position.

For standardized measurements, reference lines were traced as perpendiculars from the lower border of the mandible (LBM) to the ridge crest (RC). Four regions on right and left side were identified; first region was at the tangent line to the posterior border of the mental foramen, second, third and fourth region were consecutively located 5 mm further distally fig (1) and fig. (2).

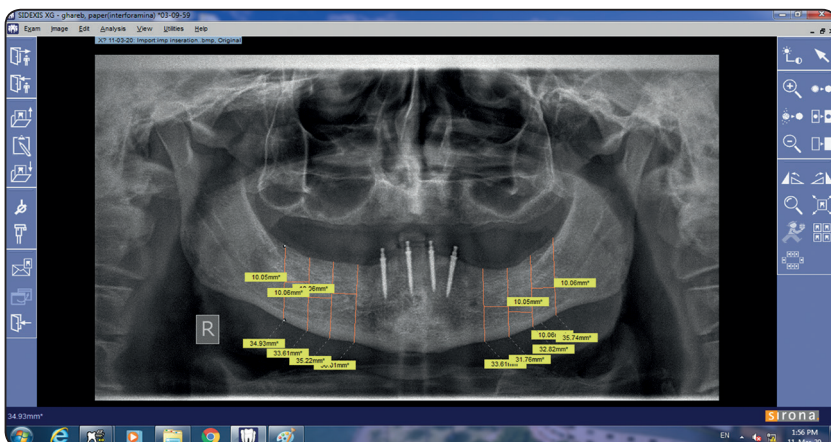


Fig. (1): Digital panoramic radiograph for interforaminal group, bone height measurements (Linear analysis), distal mental foramen.

Positive values indicate bone resorption, negative values indicate an increase in the heights of posterior residual ridge or bone apposition.

From table (2) there was no significant difference in bone heights changes after six years in wide distribution group. Figure (4) shows that at 5 and 10 mm there were minute bone loss but at 15 and 20 mm there were bone apposition.

Comparisons: Table (3) figure (5) shows the results of comparisons between the bone height changes for interforaminal and wide distribution groups in both right and left sides.

From table (3) and figure (5) there was significant difference in bone heights changes between interforaminal and wide distribution groups after six years. There is bone apposition in the wide distribution at 15mm and 20mm.

TABLE: (1) Comparison between the mean bone height changes every 5mm distal to mental foramen of mandibular alveolar ridge in interforaminal distribution group.

		(Interforaminal) group - Paired Differences						Paired T-rest	Sig.
		Mean	SD	Change (mm)	% Change	95% Confidence Interval of the Difference			
						Lower	Upper		
after 5 mm	Immediately	34.02 ^a	1.52	4.78	14.05	2.45	7.12	6.52	0.01**
	After 6 year	29.24 ^b	1.54						
after 5 mm	Immediately	33.06 ^a	2.37	7.82	23.65	4.21	11.43	6.90	0.01**
	After 6 year	25.24 ^b	3.27						
after 5 mm	Immediately	32.74 ^a	0.75	7.72	23.58	6.66	8.78	23.21	0.00**
	After 6 year	25.02 ^b	1.40						
after 5 mm	Immediately	34.56 ^a	0.96	8.21	23.76	6.99	9.44	21.27	0.00**
	After 6 year	26.35 ^b	1.59						
Mean changes				7.14 (21.26%)					

**; ^{ab} means significant difference between groups at P value <0.05

TABLE (2) Comparison between the mean bone height changes every 5mm distal to mental foramen of mandibular alveolar ridge in wide distribution group.

		(wide distribution) group - Paired Differences						Paired T-rest	Sig.
		Mean	SD	Change (mm)	% Change	95% Confidence Interval of the Difference			
						Lower	Upper		
After 5 mm	Immediately	32.78 ^a	2.52	1.01	3.08	-2.54	4.54	0.90	0.434 ^{ns}
	After 6 year	31.77 ^a	0.77						
After 10 mm	Immediately	30.22 ^a	3.97	0.09	0.3	-2.99	3.17	0.09	0.934 ^{ns}
	After 6 year	30.13 ^a	2.96						
After 15 mm	Immediately	28.74 ^a	5.45	-0.68	2.37	-7.13	5.77	-0.34	0.759 ^{ns}
	After 6 year	29.42 ^a	1.61						
After 20 mm	Immediately	31.51 ^a	3.82	-0.32	1.02	-5.63	5.01	-0.19	0.864 ^{ns}
	After 6 year	31.83 ^a	1.27						
Mean changes				0.03 (1.69%)					

ns, and similar letters means non-significant difference between groups at P value <0.05

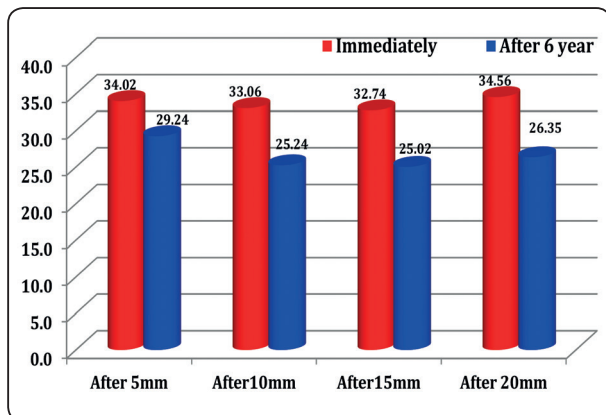


Fig. (3) Showing bone heights changes in interforaminal distribution group

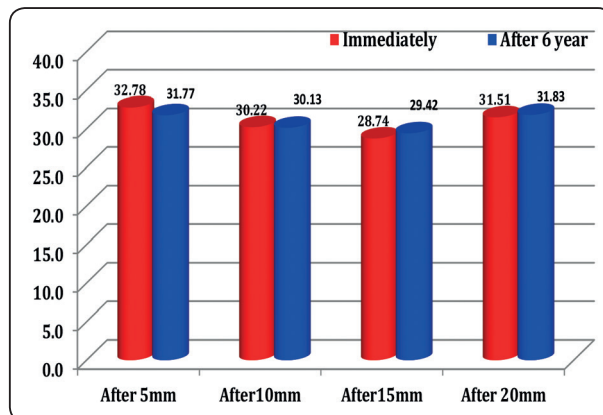


Fig. (4) Bone heights changes in wide distribution group

TABLE (3) Comparison between the mean bone height changes every 5mm distal to mental foramen of mandibular alveolar ridge in both groups.

	wide distribution	Inter-foraminal	Independent T-Test	p-values <0.05
	Mean ±SD	Mean ±SD		
After 5 mm	1.00±2.23 ^b	4.78±1.47 ^a	-2.84	0.030**
After 10mm	0.09±1.94 ^b	7.82±2.27 ^a	-5.18	0.002**
After 15mm	-0.68±4.05 ^b	7.72±0.67 ^a	-4.16	0.006**
After 20mm	-0.31±3.34 ^b	8.22±0.77 ^a	-4.97	0.003**

**; ^{ab} means significant difference between groups at P value <0.05

DISCUSSION

Since the use of implant installed in the posterior part of the mandible and their effect on stress distribution was point of concern in late years the present study aimed to assess the effect of mini-implants distribution on posterior residual alveolar ridge. Either the mini-implants assisted overdenture assisted by four mini implants installed in the interforaminal area or four mini-implants installed in the canine and first molar area in mandibular mini-implants assisted overdenture opposed by maxillary complete denture.

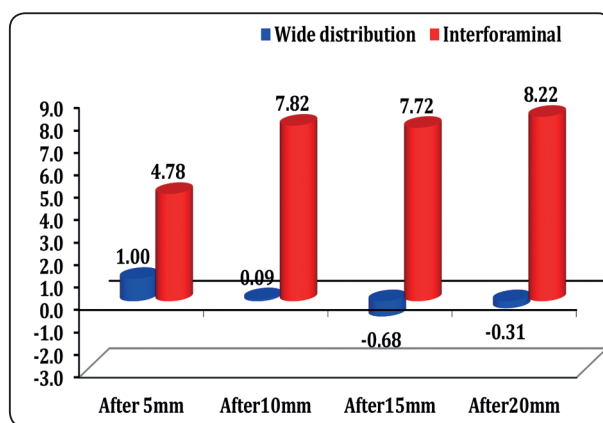


Fig. (5) Bone height changes in wide and interforaminal distribution groups

The concept of a prosthesis assisted only by implants anterior to the mental foramina as described by *Branemark* and coworkers ⁽²²⁾ has several advantages. Placement of implants anterior to the mental foramina allows the engagement of the inferior cortex by tip of the implant or at least guarantee that the implant is placed in the area of greatest density improving the primary stability and increasing the chance of osseointegration. The risk of damage to the mental branch of inferior alveolar nerve is reduced by avoiding more posterior implant placement. ⁽²³⁾

On the basis of studies on the precision of measurements of mandibular linear dimensions in panoramic radiographs, *Larheim et al.*^(24, 25) have indicated that the variability of vertical measurements made from repeated panoramic radiographs is small when patients are properly positioned in the panoramic apparatus. The effect of head position in the panoramic radiograph on vertical measurement⁽²⁶⁾ showed the possibility of making accurate vertical measurements in both jaws, particularly in the lower jaw. If reference lines and measured points are located in the same vertical plane or in approximately the same plane, variations in vertical measurements in the mandible and the posterior regions of the maxilla fall within a small range.

Reduction of the residual alveolar ridges is progressive in nature with age, the height of the alveolar ridge and basal bone will decrease, resulting in alveolar ridge bone loss as great as 1 mm per year in complete denture wearers.⁽²⁷⁾

Another study reported, a negative correlation between age and mandibular bone height in both genders but was found statistically significant in male patients specially >60 year.⁽²⁸⁾

In the 4 interforaminal implant assisted overdentures, majority of stresses are distributed on the posterior basal seat area⁽²⁹⁾ and bone resorption take place.^(12,15,30) The biomechanics of 4 interforaminal implants mandibular overdenture is similar to that of a *Kennedy* class I removable partial denture. Difference in compressibility between posterior ridge mucosa and osseointegrated implant will cause hinging of denture base around a fulcrum line passing through the two most distal anterior implants.⁽³¹⁾ During mastication, the increase in compressive load on the distal over-denture base will increase distal ridge resorption.^(30, 32, 33)

Marjolein et al⁽¹⁾ reported that the vertical posterior bone resorption for four implants assisted overdenture was 0.74 mm in 10 years. *Kordatzis et al*⁽¹⁶⁾ reported 0.69 to 1 mm of posterior residual ridge resorption over five years.

In our study the estimated mandibular ridge height resorption in interforaminal distribution group of mini-implants was 7 mm or 21 % of residual bone height over six years. The higher value of bone resorption may be caused by use of mini implants instead of standard size implants and aging factor.

In the present study the estimated mandibular ridge height resorption in wide distribution group of mini-implants was 0.03 mm or 1.7 % of residual bone height over six years.

The posterior implants placement is indicated to favorably change the biomechanical situation.⁽³⁴⁾ With the posterior implant placement, the denture hinging was significantly reduced, and more of a load was carried with posterior implants. Physiological functional load transmitted to implants will have a positive effect on preservation of the residual alveolar ridge around the implants.⁽³⁵⁾ The posterior implants would improve the overdenture support, reduce hinging action of denture, and transfer the *Kennedy* class I implant-and-mucosa supported overdentures to fully implant-supported *Kennedy* class III design.⁽³⁴⁾

CONCLUSION

Posterior mini-implant placement resulted in improved denture support and minimal overdenture displacement. The functional load on posterior mini-implants have a positive effect on preservation of the residual alveolar ridge. Wide mini-implants distribution is an acceptable alternative prosthodontic design to four interforaminal mini-implants distribution when anatomical and economical factors permit.

REFERENCE

1. Marjolein M, de Jong M, Wright P, Meijer H and Tymstra N. Posterior mandibular residual ridge resorption in patients with overdentures supported by two or four endosseous implants in a 10-year prospective comparative study. *Int J Oral Maxillofac Implants.* 2010; 25:1168–74.

2. Kova I, Elebi A, Knezovi D, Petri N and Bukovi D. Decreasing of Residual Alveolar Ridge Height in Complete Denture Wearers. A Five Year Follow up Study. *Coll Antropol.* 2010; 34: 1051–1056.
3. Juan F, Azorín M, Segura G, López J and Panadero R. Rehabilitation with implant-supported overdentures in total edentulous patients: A review. *J Clin Ex Dent.* 2013; 5:267–272.
4. Khalifa A, Wada M, Ikebe K and Maeda Y. To what extent residual alveolar ridge can be preserved by implant? A systematic review. *Int J Implant Dent.* 2016; 2:22-31.
5. Kumari P, Verma M, Sainia V, Gupta A, Gupta R and Gill S. Mini-implants, mega solutions: a case series. *J Prosthodont.* 2015; 10:12382.
6. Griffiths T, Collins C and Collins P. Mini dental implants: an adjunct for retention, stability, and comfort for the edentulous patient. *Oral Surg Oral Med Oral Pathol Oral Radiol Endod.* 2005; 100:81–4.
7. Shatkin T, Shatkin S, Oppenheimer B and Oppenheimer A. Mini dental implants for long-term fixed and removable prosthetics: a retrospective analysis of 2514 implants placed over a five-year period. *Compend Contin Educ Dent.* 2007; 28:92–101.
8. Preoteasa E, Imre M and Preoteasa CT. A 3-year follow-up study of overdentures retained by mini-dental implants. *Int J Oral Maxillofac Implants.* 2014; 29:1170–6.
9. Pongsakorn W, Pimduen R, Chaib R and Pathawee K. Effects of different numbers of mini-dental implants on alveolar ridge strain distribution under mandibular implant-retained overdentures. *J prosth research.* 2018; 62:35–43.
10. Flanagan D and Mascolo A. The mini dental implant in fixed and removable prosthetics: a review. *J Oral Implantol.* 2011; 37:123–32.
11. Scepanovic M, Calvo-Guirado JL, Markovic A, Delgado-Ruiz R, Todorovic A and Milicic B. A 1-year prospective cohort study on mandibular overdentures retained by mini dental implants. *Eur J Oral Implantol.* 2012; 5:367–79.
12. Jacobs R, Schotte A, van Steenberghe D, Quirynen M and Naert I. Posterior jaw bone resorption in osseointegrated implant-supported overdentures. *Clin Oral Implants Res.* 1992; 3:63–70.
13. Blum I and Fraser M. A clinical investigation of the morphological changes in the posterior mandible when implant-retained overdentures are used. *Clin Oral Implants Res.* 2004; 15:700–8.
14. Raedel M, Lazarek-Scholz K, Marr B, Boening KW and Walter MH. Posterior alveolar ridge resorption in bar-retained mandibular overdentures: 10-year results of a prospective clinical trial. *Clin Oral Implants Res.* 2015; 26:1397–401.
15. Wright P, Glantz P, Randow K and Watson RM. The effects of fixed and removable implant-stabilised prostheses on posterior mandibular residual ridge resorption. *Clin Oral Implants Res.* 2002; 13:169-74.
16. Kordatzis K, Wright PS and Meijer HJ. Posterior mandibular residual ridge resorption in patients with conventional dentures and implant overdentures. *Int J Oral Maxillofac Implants.* 2003; 18:447-52.
17. Tiwari P, Karambelkar V, Patel J and Sethuraman R. Use of panoramic radiographs for evaluation of maxillary and mandibular residual ridge resorption: invitro study. *Evolution of Med and Dent.* 2014; 3:60.
18. Sanders D: Mental Foramen Location in Humans, thesis for the MS. degree, University of Texas Dental Branch, Houston, Texas, May, 1972.
19. Arkin H. Handbook of Sampling for Auditing and Accounting, 3rd edition, (McGraw-Hill, 1984) Page 21.
20. Jaykaran C and Tamoghna B. How to Calculate Sample Size for Different Study Designs in Medical Research? *Indian J Psychol Med.* 2013; 35: 121–126.
21. Stuart C, Michael J. Oral Radiology Principles and interpretation. Chapter 11: Panoramic Imaging, 7TH edition, produced by Mosby Co., St. Louis, 2014.
22. Branemark P, Hasson B, Adell R, Breine U, Lindström J and Hallen O. Osseointegrated implants in the treatment of edentulous jaw. Experience from a 10 years period. *Scand J Plastic Reconstr Sur Suppl.* 1977; 16:1-123.
23. Misch C. Contemporary implant dentistry .3th ed. CV. Mosby Co., St. Louis, Boston, Chicago, London, Philadelphia, Sydney, Toronto, 2008.
24. Larheim TA, Svanaes DB and Johannessen S. Reproducibility of radiographs with the orthopantomograph 5: tooth-length assessment. *Oral Surg* 1984; 58:736–41.
25. Larheim TA and Svanaes DB. Reproducibility of rotational panoramic radiography: mandibular linear dimensions and angles. *Am J Orthod Dentofac Orthop* 1986; 90:45-51.
26. Xie Q, Soikkonen K, Wolf J, Mattila K, Gong M and Ainamo A. Effect of head positioning in panoramic radiography on vertical measurements: an in-vitro study. *Dentomaxillofac Radiol* 1996; 25:6 1-6.

27. Devlin H and Ferguson MW. Alveolar ridge resorption and mandibular atrophy. A review of the role of local and systemic factors. *Br Dent J* 1991; 170:101-4.
28. Al AlSheikh H, AlZain S, Warsy A, AlMukaynizi F and AlThomali A. Mandibular residual ridge height in relation to age, gender and duration of edentulism in a Saudi population: A clinical and radiographic study. *Saudi Dental Journal* 2019; 31:258–264.
29. Topkaya T and Solmaz M. The effect of implant number and position on the stress behavior of mandibular implant retained overdentures: A three-dimensional finite element analysis. *J Biomech.* 2015; 48: 2102-2109.
30. Elsyad M, Alokda M, Gebreel A, Hammouda N and Habib A. Effect of two designs of implant-supported overdentures on peri-implant and posterior mandibular bone resorptions: a 5-year prospective radiographic study. *Clin Oral Implants Res.* 2017; 28: 184-194.
31. Muraki H., Wakabayashi N, Park I and Ohyama T. Finite element contact stress analysis of the RPD abutment tooth and periodontal ligament. *J Dent.* 2004; 32: 659-665.
32. Ahmad R, Chen J, Abu-Hassan MI, Li Q and Swain MV. Investigation of mucosa induced residual ridge resorption under implant retained overdentures and complete dentures in the mandible. *Int J Oral Maxillofac Implants.* 2015; 30: 657–666.
33. Tymstra N, Raghoobar G, Vissink A and Meijer H. Maxillary anterior and mandibular posterior residual ridge resorption in patients wearing a mandibular implant retained overdenture. *J Oral Rehabil.* 2011; 38: 509–516.
34. Ohkubo C, Kurihara D, Shimpo H, Suzuki Y, Kokubo Y and Hosoi T. Effect of implant support on distal extension removable partial dentures: in vitro assessment *J Oral Rehab.* 2007;34: 52- 56.
35. Frost H. From Wolff's law to the Utta Paradigm: Insights about the bone physiology and its clinical application. *Anat Rec.* 2001; 262: 398- 419.