

Posterior Approach to Neurotize Suprascapular Nerve by Spinal Accessory Nerve

Muhammad Hassan Muhammad Abdel-Aal¹, Mohammad Reda Ahmad¹,
Hassan Rabea Galal Ashour², Ahmed Mohamed Desoky Hemid*¹

Departments of ¹Plastic & Reconstructive Surgery and ²Surgical Oncology,
Faculty of Medicine-Zagazig University

*Corresponding author: Ahmed Mohamed Desoky Hemid, **Mobile:** (+20) 01008308149,

ABSTRACT

Background: Surgical reconstruction of the shoulder is a high priority in patients with total brachial plexus injuries. This is not only because functional control of the shoulder is of paramount importance, but also because of the overall reduced success of reinnervation of muscles below the elbow.

Objective: This study aimed to neurotize suprascapular nerve by spinal accessory nerve through posterior approach.

Patients and methods: This prospective cohort study was conducted in the Department of Plastic and Reconstructive Surgery, Faculty of Medicine, Zagazig University within the period from November 2018 to July 2019. Twelve patients were included in the present study. All patients were exposed to traumatic brachial plexus injuries.

Results: our study showed progressive improvement of shoulder flexion, abduction and external rotation. By the comparison between pre- and postoperative range of movement. It was recorded that the mean value of shoulder flexion has significantly elevated from 4.167 ± 4.68 preoperative to be 59.58 ± 8.11 ($P < 0.001$). The mean value of shoulder abduction was increased significantly from 4.58 ± 4.50 preoperative to 65.41 ± 8.91 postoperative ($P < 0.001$). Moreover, the mean value of external rotation was improved significantly from 5.83 ± 5.15 preoperative to 65.42 ± 9.64 postoperative.

Conclusion: That transferring spinal accessory nerve to the suprascapular nerve via the posterior approach for restoring shoulder abduction and external rotation is an effective and reliable treatment with high success rate in patients with brachial plexus palsy.

Keywords: Brachial plexus injuries, Spinal accessory nerve, Nerve transfer, Neurotization.

INTRODUCTION

The brachial plexus is the most complex peripheral neural unit. It supplies the arm and hand, allowing expression of the mind through writing, art, athletic endeavor and delicate manipulation of the environment ⁽¹⁾. In most of the brachial plexus injuries, it is necessary to recover the stability of the shoulder as well as its abduction and external rotation ⁽²⁾. Although there are many techniques to achieve this goal, one of the most used techniques is the nerve transfer of fascicles of the accessory nerve (XI) to the supra scapular nerve (SSN), which gives better results than using nerve grafts from a ruptured C5 root. This technique can be performed either by an anterior approach or a posterior approach ⁽³⁾.

The anterior approach is simple and feasible for any surgeon used to access the brachial plexus by a supraclavicular route. However, many obstacles are encountered in this technique such as tedious dissection of spinal accessory nerve because it lies deep in fatty tissue rich in lymphatic and blood vessels. Distal suprascapular nerve injuries may also be missed when plexus exploration and nerve transfer have been performed through anterior approach. Also in healed clavicular fractures with exorbitant callus formation. Thus, suprascapular nerve dissection can be difficult and risky. Moreover, during anterior exploration of spinal accessory nerve few of its

important branches to the upper trapezius muscle may be sacrificed while attempting to gain a sufficient length ⁽⁴⁾.

Recent clinical series suggest that better results in shoulder abduction and external rotation can be obtained when the XI – SSN neurotization is performed using a posterior approach ⁽⁵⁾.

This study aimed to neurotize suprascapular nerve by spinal accessory nerve through posterior approach.

PATIENTS AND METHODS

This prospective cohort study was conducted in the Department of Plastic and Reconstructive Surgery, Faculty of Medicine, Zagazig University within the period from November 2018 to July 2019. Twelve patients were included in the present study. The sample was taken as a comprehensive sample due to rare presentation of brachial plexus injuries cases at Zagazig University Hospital about 2/month, so the sample was 6/12 months.

Inclusion criteria: Age more than 3 months and less than 60 years and less than 9 months from time of injury.

Exclusion criteria: Obstetric brachial plexus injuries cases. Cases with spinal accessory nerve injury.



This article is an open access article distributed under the terms and conditions of the Creative Commons Attribution (CC BY-SA) license (<http://creativecommons.org/licenses/by/4.0/>)

Patients who refused to undergo operation. Patients who refused or didn't follow up.

Ethical approval: Approval for performing the study was obtained from Plastic and Reconstructive Surgery Departments, Zagazig University Hospitals after taking approval of Institutional Review Board (IRB). The study was carried out according to The Code of Ethics of the World Medical Association (Declaration of Helsinki) for studies involving humans. A signed written consent was obtained from each patient.

Pre-operative

All patients were seen at the Outpatient Clinic for examination and assessment. Full history taking. Assessment of the patients' muscle power graded by the MRC scale. Laboratory investigations e.g. complete blood count (CBC), coagulation profile, RFTs, liver function tests (LFTs), viral markers. Preoperative surgical chemoprophylaxis: third generation cephalosporin e.g. one gram of cefotaxime sodium was given I.V to all patients one hour preoperatively. Preoperative photography for scientific and medicolegal documentation. Patient communication and explanation of the problem, procedure and post-operative management plan was done.

Operative

General anesthesia was given to the patient without muscle relaxant. Positioning of the patient in prone or lateral position with head of the operating table raised by 40°. Anatomical landmarks (which should be identified by palpation): the acromioclavicular joint (ACJ), the spine of the scapula, the upper and inner angle of the scapula, the inner border of the scapula, XI and SSN, which are located 11cm and 7 cm medially to ACJ respectively . Figure (1)

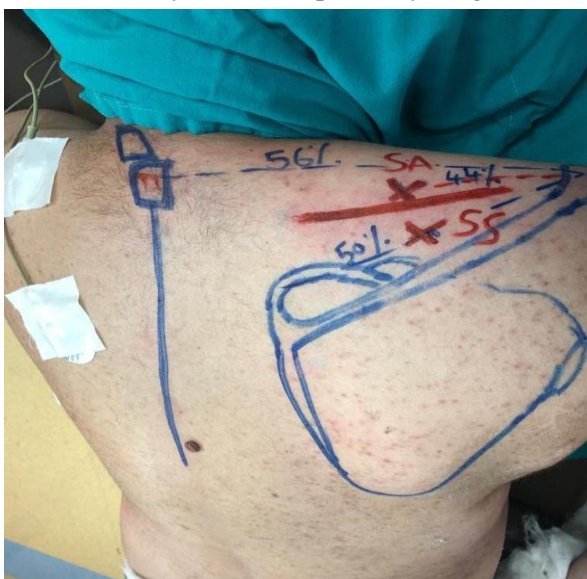

Figure (1): Incision it is placed one centimeter above the spine of the scapula and covering at least two points located 7cm and 11cm from the ACJ with approximately 12 to 15 cm long.

The trapezius muscle was splitted from the scapular spine with sharp scissors and a plane was dissected between the trapezius and supraspinatus muscles. Trapezius muscle was gently lifted up revealing the neurovascular bundle on its undersurface. The spinal accessory nerve was isolated and taped. Contractions of the trapezius muscle were observed on its electrical stimulation. With the index finger, upper border of scapula was palpated for suprascapular notch. A strong downward traction on upper border of supraspinatus muscle revealed the glistening white suprascapular ligament overlying the notch. Suprascapular artery and vein were ligated superficial to the ligament. The ligament was sectioned while protecting the underlying suprascapular nerve. The suprascapular nerve was mobilized proximally to allow sufficient length and coated with the distal spinal accessory nerve using 10-0 nylon suture Figure (2).

The trapezius muscle was sutured back to the spine of scapula with 3-0 polyglactin suture. Skin incision was closed without a drain.

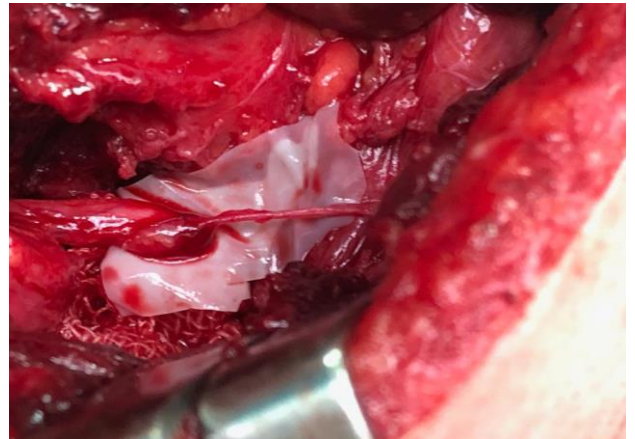


Figure (2): Anatomy of the spinal accessory and suprascapular nerve.

Postoperative:

Pain from the surgery was minimal and was controlled by analgesics (NSAIDs & morphia). A moulded cast for 3 weeks post-operatively was applied prohibiting any shoulder movement. Physical therapy is essential to strenghten recovering muscles and maintain flexibility of joints. Clinical care of the incision wound using a topically applied anti-scar cream. Postoperative assessment of the patients muscle power graded by the MRC scale.

Statistical analysis

Data were analyzed by Statistical Package of Social Science (SPSS), software version 22.0. Continuous data were expressed as Mean \pm SD, while the nominal data were presented by the frequency and percentage. The paired – sample t-test compared the means between preoperative and postoperative shoulder flexion ($^{\circ}$), shoulder abduction ($^{\circ}$) and shoulder external rotation ($^{\circ}$). In all testes used P value \leq 0.05 considered significant.

RESULTS

Twelve patients were included in the present study 9 males (75%) and 3 (25%) females, their ages ranged from 25 to 40 years old with a mean of 30.58 ± 4.40 years. The affected side was the right in 8 patients (66.67%) and the left in 4 patients (33.33%). As regards the cause of lesion " etiology": the road traffic accident in 8 patients (66.67%), falling from height in 2 patients (16.67%), gunshot in one patient (8.33%) and contact sport in one patient (8.33%) as shown table (1). The time lapsed from injury to surgery ranged from 3 to 7 months with a mean of 4.58 ± 1.44 months. Regarding the other performed procedures, ICNs transfer to musclocutaneous nerve was done for 4 patients (33.33%), Oberlin procedure was done for 3 patients (25%), motor fascicles from radial nerve to axillary nerve was done for one patient (8.33%) and ICNs transfer to musclocutaneous nerve + Cross C7 to lower trunk was done for one patient (8.33%).

Regarding the type of lesion, 4 patients had avulsion of all roots (33.33%), 5 patients had rupture

of C5-C6 (41.67%), 2 patients had rupture of C5-6 with avulsion of C7 (16.66 %) and one patient had rupture of C5-6 with avulsion of T1 (8.33%) as shown in table (2).

Concerning the evaluation of the improvement of shoulder range of movement by the comparison between pre- and postoperative range of movement, it was recorded that the mean value of shoulder flexion had significantly elevated from 4.167 ± 4.68 preoperative to be 59.58 ± 8.11 (P < 0.001).

In addition, the mean value of shoulder abduction was increased significantly from 4.58 ± 4.50 preoperative to 65.41 ± 8.91 postoperative (P < 0.001). Moreover, the mean value of external rotation was improved significantly from 5.83 ± 5.15 preoperative to 65.42 ± 9.64 postoperative (Table 3, Figure 3).

The mean values of Dash score improved significantly from being 81.58 ± 10.97 preoperative to become 28.167 ± 5.59 postoperative (P < 0.001) (Table 4).

Table (1): The classification of patients according to gender, side of lesion and the cause of lesion

Total number of patients :12		Number of patients	Percentage (%)
Gender	Male	9	75%
	Female	3	25%
Side of lesion	Right	8	66.67%
	Left	4	33.33%
Etiology	RTA	8	66.67%
	Falling from height	2	16.67%
	Gunshot	1	8.33%
	Contact sports		8.33%

Table (2): The nature of brachial plexus injury; in the twelve patients included in the study

Total : 12 patients	Avulsion of all roots	Rupture of C5-6 roots	Rupture of C 5-6 roots +Avulsion of C7	Rupture of C5 root Avulsion of C6 +T1 roots
No	4	5	2	1
%	33.33%	41.67%	16.67%	8.33%

Table (3): A statistical analysis represents the comparison between preoperative and postoperative shoulder range of movement (flexion, abduction and external rotation)

Shoulder range of movement		Mean ± SD	tt	P value
Flexion	preoperative	4.167 ± 4.68	38.54	< 0.001
	postoperative	59.58 ± 8.11		
Abduction	preoperative	4.58 ± 4.50	33.257	< 0.001
	postoperative	65.41 ± 8.91		
External rotation	preoperative	5.83 ± 5.15	28.600	< 0.001
	postoperative	65.42 ± 9.64		

Table (4): DASH score before and after surgery.

DASH score	Mean ± SD	tt	P value
Preoperative	81.58 ± 10.97	24.28	P< 0.001
Postoperative	28.167 ± 5.59		

DASH: Dietary Approaches to Stop Hypertension.




Figure (3): Histogram illustrates the pre- and postoperative range of movement in shoulder flexion, shoulder abduction and shoulder external rotation.

DISCUSSION

In this study, concerning the evaluation of the improvement of shoulder range of movement by the comparison between pre- and postoperative range of movement, it was recorded that the mean value of shoulder flexion had significantly elevated from 4.167 ± 4.68 preoperative to be 59.58 ± 8.11 ($P < 0.001$). In addition, the mean value of shoulder abduction was increased significantly from 4.58 ± 4.50 preoperative to 65.41 ± 8.91 postoperative ($P < 0.001$). Moreover, the mean value of external rotation was improved significantly from 5.83 ± 5.15 preoperative to 65.42 ± 9.64 postoperative. Besides, the mean values of Dash score improved significantly from being 81.58 ± 10.97 preoperative to become 28.167 ± 5.59 postoperative ($P < 0.001$). This means improvement in the ability of patients to do certain daily activities. We have not provided data about strength recovery because the classic Medical Research Council (MRC) scale is, in our opinion, not appropriate for shoulder evaluation because it does not incorporate range of motion⁽⁶⁾. However, if measurements were carried out with the patient standing, abduction range of motion is assessed against gravity. Hence, any degree of active motion recovery requires at least an M3 level of strength. Meanwhile, the strength needed to raise the limb to 30° against gravity is different from that needed to raise it to 60° , due to the limb's weight. It is reasonable to assume that all our patients with more than 30° of abduction recovery (i.e., 12 of our 12 patients) scored M3 – M4 approximately⁽⁷⁾.

There are a few studies carried out on the transfer of spinal accessory to suprascapular nerve, which make it very difficult to compare our results against those

reported in previous publications. In addition to that, range of motion results and separation of total and partial palsies are typically not available. However, they illustrate that the nerve transfer is effective for treatment of brachial plexus palsy, each with different success rate⁽⁸⁾.

Concerning the evaluation of our results, same percentage was nearly achieved in many studies as by **Texakalidis et al.**⁽⁷⁾, where 10 patients underwent SA to SSN transfer via posterior approach. In addition, during the long-term follow-up, patients achieved an average increase of 67.5° in shoulder abduction, with successful shoulder abduction ($> M3$) in 64.3%. Another study by **Luo et al.**⁽⁹⁾, nine patients underwent SA to SSN transfer via posterior approach. At a mean of 4 months post-operatively, the EMG examination confirmed signs of re-innervation in the recipient muscles. And at a mean length of 33 months follow-up, six of nine patients regained near the normal range of the shoulder abduction and external rotation with strengths graded to M3 or M4. The weight lifting with the shoulder in the full abduction ranged from 0 to 3 kg. The other three patients achieved the shoulder abduction from 50° to 130° and external rotation from 30° to 80° . The subluxation of shoulder was eliminated in all patients.

On the contrary, lower results were obtained when performing the anterior approach, as in the studies by **Socolovsky et al.**⁽¹⁰⁾ and **Bhatia et al.**⁽¹¹⁾ who operated on 49 patients with total brachial plexus palsy. They observed some recovery of abduction in 43 (88%) of their 49 patients, ranging from 30° to 45° in 36 patients and from 70° to 80° in the remaining 7. Another study of 22 patients by **Emamhadi et al.**⁽¹²⁾,

the mean of shoulder abduction reached $55.55 \pm 9.95^\circ$ (range, $40\text{--}72^\circ$) with a motor function recovery of M3 and M4 in 13.6 and 63.6% of the subjects, respectively. However, 22.7 % of the subjects remained with a motor function of M2. In a large study of 110 patients by **Shapira and Midha** ⁽¹³⁾, an overall failure rate was demonstrated, meaning less than 30° abduction, of only 9%, with an average range of abduction recovery of approximately 60° (SD 25°). **Songcharoen et al.** ⁽¹⁴⁾ assessed 577 spinal accessory nerve transfers and reported that 80 % of motor recovery with nerve transfer to suprascapular nerve achieved a mean shoulder abduction of 60° and a mean shoulder flexion of 45° .

Higher results were obtained by **Terzis and Kostas** ⁽¹⁵⁾, who reported a mean improvement in shoulder abduction by 98° in a series of 25 patients. Also **Suzuki et al.** ⁽¹⁶⁾ found that after spinal accessory nerve transfer to the suprascapular nerve and a mean follow-up of 28.5 months, the mean shoulder flexion and abduction reached 70.4° and 77.1° , respectively. Due to the complexity of shoulder motion, one-third of the motor fibers within the brachial plexus innervate shoulder muscles. Hence, it is not possible to obtain abduction recovery above horizontal by a single nerve transfer ⁽¹³⁾. By way of illustration, **Merrell et al.** ⁽¹⁷⁾ found that for rehabilitation of shoulder function, dual-nerve transfers to suprascapular (success rate of 92 %) and axillary (success rate of 69 %) nerves obtained substantial functional improvement ($M3 \leq$), compared with single nerve transfer. In a study of 14 patients by **Texakalidis et al.** ⁽⁷⁾, ten patients underwent a single SAN to SSN transfer procedure. Four patients underwent an additional radial to axillary nerve transfer procedure. Interestingly, patients who underwent the additional radial to axillary nerve transfer demonstrated a statistically significant higher range of abduction compared to SAN to SSN transfer alone (median, 90° vs. median, 42.5° $P = 0.022$).

MRC grade $> M3$ was reported in 100% (4/4) and 30% (3/10) of patients who had the double (SAN to SSN and radial to axillary) and single (SAN to SSN) nerve transfer respectively. However, this difference did not reach statistical significance ($P = 0.07$).

Interestingly, **Terzis and Barmptsioti** ⁽¹⁸⁾ suggested that the combined radial to axillary and SAN to SSN transfer is superior to the single radial to axillary transfer. In addition, a previous study proposed that the concomitant axillary nerve reconstruction along with the SAN to SSN transfer is associated with better functional outcomes (86% vs. 72% achieved $M3+$ to $M5-$, $P = 0.18$). This study demonstrates that whenever the C7 root is intact, radial to axillary nerve transfer after SAN to SSN should be considered to increase the range of abduction compared to SAN to SSN alone (medians, 90° vs. 42.5° range of abduction, respectively; $P = 0.022$).

The main limitation of this study is the relatively small number of patients, so more large or multi-centric studies are recommended to deeply investigate the outcomes and benefits of these procedures due to the limited number of cases available.

CONCLUSION

Transferring spinal accessory nerve to the suprascapular nerve via the posterior approach for restoring shoulder abduction and external rotation is an effective and reliable treatment with high success rate in patients with brachial plexus palsy. The advantages included the precise visualization of the nerves at a level much closer to the muscle targets. The coaptation at a level closer to the target muscle will provide improved functional recovery. The dorsal approach allows preservation of upper and middle trapezius function by the relatively distal donor neurotomy.

REFERENCES

1. **Kattan A, Borschel G (2011):** Anatomy of the brachial plexus. An Interdisciplinary Approach. Journal of Pediatric Rehabilitation Medicine, 4: 107–111.
2. **Martínez F (2017):** Technical Note: Spinal-Accessory to Suprascapular Nerve Transfer by Posterior Approach. Austin Neurosurgery Open Access, 4 (1): 1058-10.
3. **Bhandari P, Sadhotra L, Bhargava P et al. (2009):** Surgical outcomes following nerve transfers in upper brachial plexus injuries. Indian J Plast Surg., 42: 150–60.
4. **Colbert S, Mackinnon S (2006):** Posterior approach for double nerve transfer for restoration of shoulder function in upper brachial plexus palsy. Hand, 1 (2): 71-77.
5. **Martínez F, Pinazzo S, Jaume A et al. (2015):** Suprascapular nerve neurotization using fascicles of the spinal accessory nerve. Anterior vs. posterior approach. GERSAM Meeting. Wunzburg, Germany, Pp: 13-14.
6. **Paternostro-Sluga T, Grim-Stieger M, Posch M et al. (2008):** Reliability and validity of the Medical Research Council (MRC) scale and a modified scale for testing muscle strength in patients with radial palsy. Journal of Rehabilitation Medicine, 40 (8): 665-671.
7. **Texakalidis P, Tora M, Lamanna J et al. (2019):** Combined Radial to Axillary and Spinal Accessory Nerve (SAN) to Suprascapular Nerve (SSN) Transfers May Confer Superior Shoulder Abduction Compared with Single SA to SSN Transfer. World Neurosurgery, 126: 1251-1256.
8. **Seifman M, Ferris S (2017):** Traumatic Suprascapular Nerve Injury at the Notch—A Reason for the Posterior Approach in Brachial Plexus Reconstruction. Journal of Reconstructive Microsurgery, 33 (08): 592-595.
9. **Luo P, Chen L, Zhou C et al. (2011):** Results of intercostal nerve transfer to the musculocutaneous nerve in brachial plexus birth palsy. Journal of Pediatric Orthopaedics, 31 (8): 884-888.
10. **Socolovsky M, Costales J, Paez M et al. (2016):** Obstetric brachial plexus palsy: reviewing the literature comparing the results of primary versus secondary surgery. Child's Nervous System, 32 (3): 415-425.
11. **Bhatia A, Shyam A, Doshi P et al. (2011):** Nerve reconstruction: A cohort study of 93 cases of global brachial plexus palsy. Indian Journal of Orthopaedics, 45 (2): 153-156.

- 12. Emamhadi M, Alijani B, Andalib S (2016):** Long-term clinical outcomes of spinal accessory nerve transfer to the suprascapular nerve in patients with brachial plexus palsy. *Acta Neurochirurgica*, 158 (9): 1801-1806.
- 13. Shapira Y, Midha R (2016):** Modified extended approach improves recovery following spinal accessory to suprascapular nerve transfer. *Journal of Neurosurgery Spine*, 24 (6): 986-989.
- 14. Songcharoen P, Wongtrakul S, Spinner R (2005):** Brachial plexus injuries in the adult. Nerve transfers: the Siriraj Hospital experience. *Hand Clinics*, 21 (1): 83-89.
- 15. Terzis J, Kostas I (2008):** Outcomes with suprascapular nerve reconstruction in obstetrical brachial plexus patients. *Plastic and Reconstructive Surgery*, 121 (4): 1267-1278.
- 16. Suzuki K, Doi K, Hattori Y et al. (2007):** Long-term results of spinal accessory nerve transfer to the suprascapular nerve in upper-type paralysis of brachial plexus injury. *Journal of Reconstructive Microsurgery*, 23 (06): 295-299.
- 17. Merrell G, Barrie K, Katz D et al. (2001):** Results of nerve transfer techniques for restoration of shoulder and elbow function in the context of a meta-analysis of the English literature. *The Journal of Hand Surgery*, 26 (2): 303-314.
- 18. Terzis J, Barmptsioti A (2010):** Axillary nerve reconstruction in 176 posttraumatic plexopathy patients. *Plastic and Reconstructive Surgery*, 125 (1): 233-247.