

Role of Ultrasonographic Examination of the Knee in Evaluation of Meniscal Injury in Correlation with Magnetic Resonance Imaging

Hesham El Sheikh, Mohamed H. Faheem, Ahmed K. Abdelmoeim

Department of Radiology, Benha faculty of medicine, Benha University, Egypt.

Correspondence to: Ahmed K. Abdelmoeim, Department of Radiology, Benha faculty of medicine, Benha University, Egypt.

Email:

ahmed2890@gmail.com

Received: 20 August, 2020

Accepted: 13 October, 2020

Abstract:

Background: meniscal tear is one of the most common injuries of knee joint. MRI is considered to be 1st choice to diagnose meniscal tear. The question of the study is, if we can use U/S as screening tool for meniscal injuries before MRI. **Aim of the Work:** to determine the clinical usefulness of ultrasonography for diagnosis of meniscal pathology in patients with acute knee pain and to compare its diagnostic accuracy to MRI in a clinical setting. **Patients and Methods:** this study was carried out in Radiology department, Benha University hospitals. Forty patients with clinical suspicion of post-traumatic meniscal injury were submitted to the following: i. data collection, ii. Clinical examination, iii. Ultrasound examination, iv. MRI examination. Data management and statistical analysis were done using SPSS vs.25. (IBM, Armonk, New York, USA). **Results:** the overall accuracy of ultrasound examination for meniscal tears was 85.2% while the overall accuracy of ultrasound examination for meniscal degeneration was 70.6% **Conclusion:** ultrasound appears to be useful for the screening of meniscal tears.

Keywords: Meniscal Tear, Magnetic Resonance Imaging, Musculoskeletal Ultrasound

Introduction

The knee joint is a compound type of synovial joint and due to the lack of bony support, stability of the joint is highly dependent on its supporting ligamentous

structures, and therefore injuries of ligaments and menisci are extremely common⁽¹⁾

Knee injuries are common. Injuries to soft tissues, such as ligaments, cartilage

(meniscus) and tendons, are the most common, though damage to the bones is also possible⁽²⁾

An accurate and rapid diagnosis of injury is important to determine the treatment plan and whether surgical intervention will be necessary⁽³⁾

Magnetic resonance imaging (MRI) has historically been considered to be the golden standard imaging modality to diagnose knee injuries. However, there are significant limitations of using MRI⁽⁴⁾. As a result, recent studies have demonstrated ultrasound as an alternative, non-invasive and real-time imaging modality.⁽⁵⁾

Ultrasound is emerging as a viable imaging modality in the diagnosis and assessment of the musculoskeletal system. Advantages of High Resolution Ultrasound include its easy availability and multi-planar capability, as well as economic advantages. The ability to compress, dynamically assess structures and compare easily with the contra lateral side is advantageous⁽⁶⁾

The use of sonography remains controversial⁽⁷⁾ therefore, we conduct this study to correlate role of ultrasound in evaluation of meniscal injury with MRI.

Aim of work

To study ultrasound scan (USS) as a noninvasive method to diagnose meniscus

lesions of the knee and to show if this was sufficient for diagnosing meniscus lesions (i.e., if it could be used for this task instead of MRI investigations performed by a radiologist) by comparing their diagnostic accuracies.

Patients and methods

Our study is prospective study done from January 2018 to July 2019 (1.5 years duration). The research ethical committee of Benha faculty of medicine approved the protocol of this study. An informed consent was taken from every participant in this study.

Population of the study: The study was performed in Benha University Hospitals. Symptomatic patients with clinical suspicion of meniscal injury suffering from knee joint disorders like pain, swelling, locking, limitations of movements post traumatic were referred to the radiology department from the outpatient clinic and internal wards of the orthopedic surgery.

Our Study included 40 patients 31 males and 9 females, their ages ranged from 20 years to 58 years with the mean age 35.3 years were examined. Inclusive criteria: All patients referred to the department of radiology with history of trauma and clinically suspicious cases of knee injuries. Patients approve to be enrolled in this study. Exclusion criteria: Any

absolute contraindication for MRI. Previously operated patients for knee injuries. Patients with knee joint neoplasm. Patients refusing to be enrolled in this study, were excluded from the study.

All patients were submitted to the following:

I. Data collection: Demographic data were collected (patient's name, age, Full clinical history taking regarding the clinical presentation, duration of complaint, family and past history, presence of malignancy (primary), other diseases or any taken medications (as anticoagulants), previous intervention as (biopsy), trauma **II. Clinical examination:** Physical examination and careful clinical examination by the referring clinician.

The clinical diagnosis was established on the basis of history and clinical examination. **III.**

Ultrasound examination: All the patient's knees are imaged by high resolution USG transducer of 6-12 MHz of General electric company (GE) health care model GE Logic P5, and p6) and Samsung (HS40)

Technique: Sonographic exams using ultrasound device were performed with 5 to 12 MHz probes in prone and supine positions through the anterior, lateral and posterior approaches using static and dynamic techniques. Most of the imaging was done in the longitudinal plane. A copious amount of

gel was applied over the surface of the lesions. A high-resolution probe (6-12 MHZ) was used. In the static technique, the anterior horns of the menisci were imaged in supine position with the knee in full extension and 30–45 degrees of flexion. Then the probe was moved to sides to visualize the bodies of the menisci. Afterwards the patients were placed prone and posterior horns were imaged with the knee in extension first then 45 degrees flexion.

In dynamic imaging, the knee was subjected to mild internal and external varus stresses to allow better imaging of the menisci using movements ⁽⁸⁾ **IV. MRI examination:** All the patient's knees are imaged by high TESLA (1.5 T) MRI of Siemens Magnetom Aera

Technique: The patient was examined using a 1.5 T MRI unit. Dedicated knee coils were used in all studies and the patients were placed in supine position with the knee in extension in all exams, a small field of view (FOV) typically in the range 14-16 cm. The following sequences were selected as required: T1WI (Coronal), T2WI (Axial, Sagittal), STIR (Coronal), Proton Density (sagittal), Fat Suppressed Proton Density- (Sagittal)⁽⁸⁾

CASES

Case 1.

Clinical Background:

Male patient 20 years old with history of left knee trauma (falling on his knee) 2 weeks prior to radiological investigations presented with knee pain, swelling, clicky sensation and limitation of movement.

US Meniscal Findings: RT knee showed linear hypoechoic streak reaching the

articular surface of posterior horn of medial meniscus (PHMM). Picture suggestive of PHMM tear

MRI Meniscal Findings:

In MRI the PHMM show abnormal signal intensity reaching articular surface at sagittal PD and PD fat suppression picture suggestive of meniscal tear

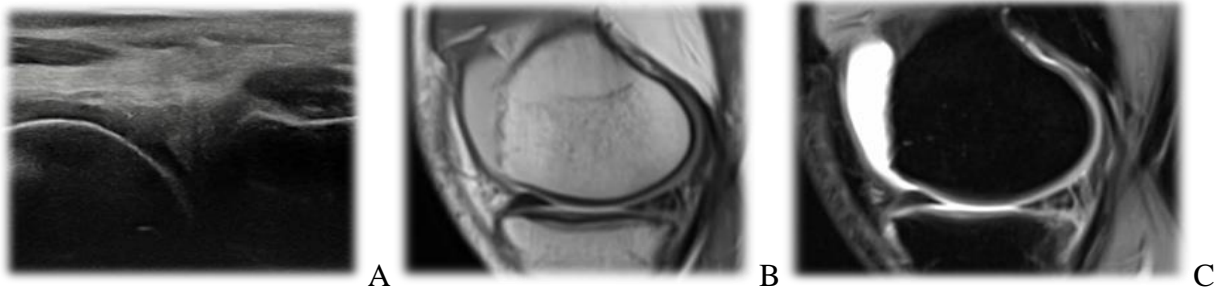


Fig. 1: A US images of PHMM tear, B, C MRI images PD and PD fat suppression of PHMM tear.

Case 2.

Clinical Background:

Male patient 31 years old with history of left knee trauma (falling on his knee) 1 week prior to investigations, presented with knee pain, swelling and limitation of movement.

US Meniscal Findings:

RT knee showed linear hypoechoic streak reaching the articular surface of posterior

horn of lateral meniscus (PHLM). Picture suggestive of PHLM tear

MRI Meniscal Findings:

In MRI the PHLM show abnormal signal intensity reaching articular surface at sagittal PD and PD fat suppression picture suggestive of meniscal tear.

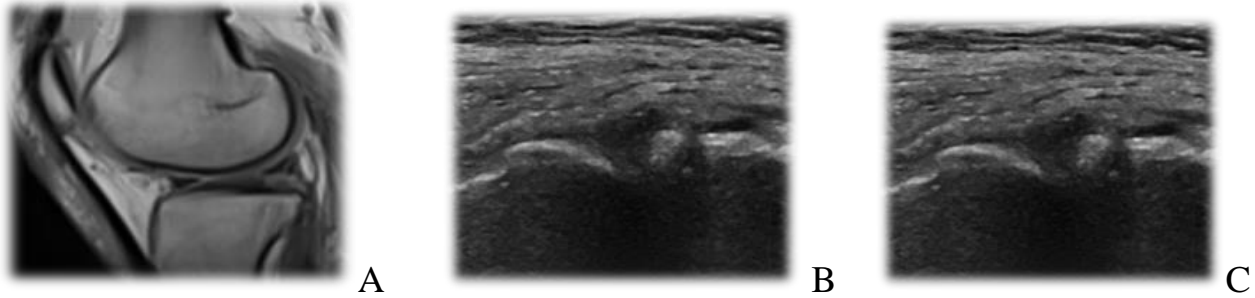


Fig. 2. A. US image of PHLM tear, B, C, MRI images PD and PD fat suppression of PHLM tear

RESULTS

This study was conducted on 40 patients attending to radiology department, Benha university hospital with history of trauma and clinically suspicious cases of knee injuries for radiological evaluation by ultrasound and MRI.

Table (1): Sex distribution of the studied group

Variables	Minimum	Maximum	Mean ±SD
Age(years)	20	58	35.3±10.4
Weight (Kg)	62	115	83.7±14.02

Table (2): Age and weight distribution of the studied group

Sex	No.	%
Male	31	77.5%
Female	9	22.5%
Total	40	100

Table (3): Type of injury diagnosed by US among positive group

Sex	No.	%
Male	31	77.5%
Female	9	22.5%
Total	40	100

22 cases of this group show meniscal tear by ultrasonography while the other 10 positive cases show meniscal injury.

Table (4): Type of injury diagnosed by MRI among positive group cases.

Type of injury	No.	%
Tear	22	62.9
Degeneration	13	37.1
Total	35	100

22 cases of this group show meniscal tear by MRI while the other 13 positive show meniscal injury

Table (5): Comparison between US & MRI findings regarding all meniscal injuries

		MRI		
		Positive	Negative	Total
US	Positive	30	2	32
	Negative	5	3	8
	Total	35	5	40

this table compares between ultrasound and MRI findings regarding all meniscal injuries giving the following results. Sensitivity of US in diagnosis of meniscal injury: 85.7%, Specificity of US in diagnosis of meniscal injury: 60%, PPV of US in diagnosis of meniscal injury: 93.8%, NPV of US in diagnosis of meniscal injury: 37.5%, Accuracy of US in diagnosis of meniscal injury: 82.5%

Discussion

The most common causes of knee pain and disability are tears in medial or lateral menisci. Meniscal injuries are common in both athletes and the general population.

In the last decade, musculoskeletal imaging has rapidly expanded due to the imaging capabilities of magnetic resonance imaging and ultrasound.

A study showed that clinical examination alone did not give adequate information to demonstrate arthroscopic examinations. In this way, imaging contemplates were quite often required.

Arthroscopy was the best quality level test for meniscal sores which can be utilized both for analysis and for treatment in the meantime, anyway intrusiveness was a burden and furthermore fringe tears might be

missed if the examination was not cautiously and completely led.⁽⁹⁾

As of late, intrigue has developed whether US can be utilized as an elective test to MRI in meniscal imaging. US, as opposed to MRI was a generally accessible and an ease test and has an expanding job in the musculoskeletal applications too⁽¹⁰⁾

In this study we wanted to determine whether US can be used as an alternative to MRI for detection of tears and degeneration.

Regarding the distribution of the patients according to sex, in our study the percentage of males was 77.5% and the percentage of females was 22.5% in a group of 40 patients, in comparison to 78% & 22% respectively in a group of 39 patients in the study carried out by Nasir.⁽¹¹⁾

This could be explained by the fact that males are more vulnerable to such traumatic knee injury during daily activity and sports injury, while females were more vulnerable to meniscal degeneration resulting from weight bearing due to obesity.

The patient's age in our study ranged between 20 and 58 years with a mean of 35.3 ± 10.4 SD. Taking in mind the distribution of the lesions according to the affected horn, 77.5% was the percentage of the posterior horn lesions, and 2% was the percentage of the anterior horn lesions, which

was away different from the results reported by Nasir,⁽¹¹⁾ with a percentage of 46.2% posterior horn lesions and 53.8% anterior horn lesions.

Regarding our statistical results for meniscal tears. Ultrasound was consistent with MRI in 20 (90.9%) lesions out of 22; as it yielded 20 true positive and 3 true negative lesions. Sensitivity of Ultrasound in detecting meniscal tears was hence found to be 90.9% specificity was 60%, while accuracy was 85.2%

In comparison to the study done by El-Monem et al.⁽¹²⁾, the sensitivity of US in diagnosis of meniscal tears were 80.5%, specificity was 76.9%, while accuracy was 80 %. Results are nearly the same.

Our results also are in agreement with the findings of Peterson et al.⁽¹³⁾ who reported a sensitivity of 86% and specificity of 83% for conventional sonography in the diagnosis of meniscal tears. In our study, it was difficult to comment on the type of tear with an ultrasonography evaluation alone.

Our study had a few limitations.

Apart from the smaller sample size of only 40 patients, in spite of the attempt to undertake a blind review, the absolute blinding was difficult to achieve because of the obvious difference in image quality

between the two modalities made some bias inevitable.

In addition, the accuracy of MRI in the diagnosis of meniscal tears was dependent on the experience of the interpreter and his or her knowledge of the potential imaging pitfalls.

Correlation with arthroscopy was not obtained as the arthroscopy with solely diagnostic purpose was not done routinely at our institution and not all patients need a therapeutic arthroscopic procedure.

On other hand, ultrasonography may be used as a screening tool prior to arthroscopy in selected cases where MRI was a contraindication or is not available or if the patient was not affording.

Ultrasonography showed a dynamic image of the meniscus and thus may prove useful if studied in conjunction with a proper clinical examination.

It was difficult to comment on the type of tear with an ultrasonography evaluation alone

References

1. Li DK, Adams ME, McConkey JP. Magnetic resonance imaging of the ligaments and menisci of the knee. *Radiologic Clinics of North America*. 1986 Jun;24(2):209-27.
2. Kapur S, Wissman RD, Robertson M, Verma S, Kreeger MC, Oostveen RJ. Acute knee dislocation: review of an elusive entity. *Current*

- problems in diagnostic radiology. 2009 Nov 1;38(6):237-50.
3. Cook JL, Cook CR, Stannard JP, Vaughn G, Wilson N, Roller BL, et al. MRI versus ultrasonography to assess meniscal abnormalities in acute knees. *The journal of knee surgery*. 2014 Aug;27(04):319-24.
 4. Najafi J, Bagheri S, Lahiji FA. The value of sonography with micro convex probes in diagnosing meniscal tears compared with arthroscopy. *Journal of ultrasound in medicine*. 2006 May;25(5):593-7.
 5. Artul S, Khazin F, Hakim J, Habib G. Ultrasonographic findings in a large series of patients with knee pain. *Journal of clinical imaging science*. 2014;4.
 6. Friedman L, Finlay K, Popovich T, Chhem RK. Sonographic findings in patients with anterior knee pain. *Journal of clinical ultrasound*. 2003 Feb;31(2):85-97.
 7. Wang CY, Wang HK, Hsu CY, Shieh JY, Wang TG, Jiang CC. Role of sonographic examination in traumatic knee internal derangement. *Archives of physical medicine and rehabilitation*. 2007 Aug 1;88(8):984-7.
 8. Unlu EN, Üstüner E, Saylisoy S, Yilmaz Ö, Özcan H, Erden I. The role of ultrasound in the diagnosis of meniscal tears and degeneration compared to MRI and arthroscopy. *Acta Medica Anatolia*. 2014;2:80–87.
 9. Ravichandra G, Aravinda M, Usman SM, Vivek S. USG and MRI correlation in the evaluation of meniscal lesions of knee. *Journal of Evolution of Medical and Dental Sciences*. 2014 Sep 25;3(47):11331-8.
 10. Mostafa M, Adel H, Elfotuh A, Mohamad A, Alsakka MM. MRI Versus Ultrasound In Diagnosis Of Meniscal Tear In Knee Joint. *Egyptian Journal of Hospital Medicine*. 2019 Jan 3;74(2).
 11. Nasir AI. The role of magnetic resonance imaging in the knee joint injuries. *International Research Journal of Medical Sciences*. 2013;1(5):1-7.
 12. EL-MONEM SA, ENABA MM. Comparative Study between High Resolution Ultrasound (HRUS) and MRI in Diagnosis of Meniscal and Cruciate Ligaments Injury of the Knee. 2012 Mar:233.
 13. Petersen LJ, Rasmussen OS. Ultrasonography as a diagnostic method in suspected meniscal lesion of the knee. A prospective single blind study of 52 patients. *Ugeskrift for laeger*. 1999 Oct;161(41):5679-82.

To cite this article: Hesham El Sheikh, Mohamed H. Faheem, Ahmed K. Abdelmoeim. Role of Ultrasonographic Examination of the Knee in Evaluation of Meniscal Injury in Correlation with Magnetic Resonance Imaging. *BMFJ* 2021; 38 (Radiology): 90-97. DOI: 10.21608/bmfj.2020.16018.1037.