

SURGICAL OUTCOME OF INFERIOR RECTUS RECESSION IN MANAGEMENT OF MONOCULAR ELEVATION DEFICIT

By

Tamer Tawheed Mohamed Abd El-Salam, Attiat Mostafa El-Sayed Mostafa and Mahmmoud Mohamed Saleh

Department of Ophthalmology, Al-Azhar Faculty of Medicine, Cairo, Egypt

Corresponding Author: Tamer Tawheed Mohamed Abd El-Salam,

Mobile: 01280049466, **E-mail:** Tamer.Twheed@gmail.com

ABSTRACT

Background: Monocular Elevation Deficiency (MED) is an inability to elevate one eye in all field of gazes usually resulting in one eye that is pointed downward relative to the other eye.

Objective: To evaluate the efficacy of inferior rectus recession in management of monocular elevation deficit (MED) with +ve or -ve forced duction test (FDT).

Patients and Methods: Our study was carried out on 20 patients complaining of MED who were selected from out-patients clinic in Sayed Galal and Al-Hussein University Hospitals. From January 2017 to May 2019. The patients were divided into 2 equal groups. Group A with +ve FDT, and group B with -ve FDT. Both groups had inferior rectus recession (IRR).

Results: Preoperatively, 40% of patients in group A were -4 (limited elevation), and 60% of patients were -3. All those patients improved to -1 postoperatively. On the other hand, 90% of patients in group B were -4, and 10% of patients were -3 (limited elevation). They improved postoperatively to -3 and -2 respectively. In group (A), the average of preoperative hypotropia was 19.40 ± 1.43 PD. All the patients had IRR: the postoperative average of hypotropia was 1.10 ± 1.91 PD with average of correction 18.30 ± 1.42 PD. In group (B) having MED with -ve FDT were operated by IRR. A reliable and effective correction of hypotropia in 7 patients with preoperative mean deviation of 19.86 ± 1.68 PD, and postoperative mean deviation of 2.71 ± 2.56 PD with average of correction 17.14 ± 1.86 PD. Partial correction of hypotropia in 3 patients underwent Knapp's procedure with preoperative mean deviation of 50.0 ± 5.00 , postoperative average of correction of 18.00 ± 0.00 PD, post Knapp procedure the deviation was 3.00 ± 2.65 with average of correction of 29.00 ± 2.65 .

Conclusion: Although the MED is etiologically multifactorial, satisfactory surgical results can be achieved by IRR as a simple and reliable 1ry intervention for both types (+ve FDT and -ve FDT).

Keywords: Inferior rectus recession, Monocular Elevation Deficiency (MED).

INTRODUCTION

Previously MED was known as double elevator palsy, this condition may be associated with ptosis and co-existent horizontal deviation. Both parietic and restrictive causes have been found on FDT and saccadic velocity measurements. The

unilateral elevation deficit may also have supranuclear etiology (*Zafar et al., 2012*).

Monocular elevation deficiency (MED) is classified as three subtypes: 1) Restrictive form, with features including positive forced duction test (FDT) for elevation, normal elevation force

generation test (FGT), and elevation saccadic velocity, often an extra or deeper lower eyelid fold on attempted up gaze and poor or absent Bell's phenomenon; 2) Paretic form with elevator muscle weakness, with features including free FDT, reduced elevation FGT and saccadic velocity, in which the Bell's phenomenon is often preserved; and 3) A combination form, with features including positive FDT for elevation and reduced FGT and saccadic velocity for elevation (*Talebnejad et al., 2014*).

MED can be congenital or acquired. Congenital cases of MED occur sporadically and include supranuclear palsy, primary superior rectus (SR) paresis, and primary inferior rectus (IR) restriction as in cases of congenital fibrosis of inferior rectus. Acquired MED is usually caused by trauma, cerebrovascular diseases like hypertension, thromboembolism, sarcoidosis, syphilis, and midbrain tumors like pineoblastoma, acoustic neuromas and metastatic tumors affecting supranuclear pathways (*Saluja and Bhari, 2019*).

The pathophysiology of MED is poorly understood. The early description of this condition was thought to be due to a combination of SR and inferior oblique muscle palsy (called double elevator palsy). Studies have shown that only 30% of cases are caused by this problem, and the FDT has demonstrated that 70% is caused by IR restriction. Magnetic resonance imaging (MRI) may be a useful adjunct to saccadic velocity assessment in differentiating between primary IR restriction, primary SR paresis, and

congenital supranuclear elevation deficiency (*Talebnejad et al., 2014*).

The first step in surgical correction of MED is to confirm the type of MED restrictive or paralytic. It was done by doing FDT (forced duction test) for inferior rectus. If FDT is positive for IR (Type 1 MED), an IR recession (IRR) with conjunctival recession is done. The eye should now elevate freely if all the adhesions and tight inferior rectus fibres have been severed. FDT is repeated after the inferior rectus was reattached. Elevation of the eye by at least 20-25 degrees should be possible. In cases of secondary IR restriction, the hypotropia persists after IRR because of primary superior rectus muscle (SR) palsy. In such cases, Knapp's procedure is described with IRR along with conjunctival recession. If vertical deviation is small, and eye was able to elevate above the midline, IR recession combined with SR resection can also be done (*Goray, 2015*).

The aim of this work was to evaluate the efficacy of inferior rectus recession in management of monocular elevation deficit (MED) with +ve or -ve forced duction test (FDT).

PATIENTS AND METHODS

Our study was carried out on 20 patients complaining of MED selected from out-patients clinic in Sayed Galal and Al-Hussein University Hospitals, from January 2017 to May 2019. The patients were able to read and give consents. The patients were divided into 2 equal groups. Group A with +ve FDT, and group B with -ve FDT. Both groups had IRR (inferior rectus recession). Patients with limited elevation above the

horizontal line with positive or negative duction test, hypotropia, chin-up head posture and ptosis were included. Patients with complex eye motility disorders, trauma, superior oblique over action, third nerve palsy, previous strabismus surgery were excluded.

All patients were subjected to complete medical, ocular, history, complete ocular examination, and documented digital photography.

Response to treatment: patient with hypotropia < 5 PD was considered successful outcome. Ptosis surgery, if required, was performed after strabismus surgery. Any patient of both groups with post-operative residual significant hypotropia or chin-up was undergoing surgical procedure (Knapp's operation) after 6 months. Postoperative evaluation

of results of surgery was recorded after one week, 1 month, 3 months and 6 months of operation.

Statistical Methods:

Data were collected, tabulated, then analyzed using IBM© SPSS© version 22 (IBM© Corp., Armonk, NY). Normally, distributed numerical data were presented as mean and standard deviation (SD). Qualitative data were presented as number and percentage. Comparison of normally distributed numerical data using the unpaired Student t test. Skewed data were compared using the Mann-Whitney U test. Categorical data were compared using the chi-squared test or Fisher's exact test, when appropriate. A two-sided p-value <0.05 were considered statistically significant.

RESULTS

In comparing between two studied groups regarding age, range of age in group A was 10-27 year versus 4-42 year in group B, and p-value was 0.367. Regarding sex, both groups were similar.

Regarding eye in group A, right eye was in 3 cases, and left eye in 7 cases. IN group B right eye was in 2 cases, and left eye in 8 cases. Regarding FDT, p-value was significant (**Table 1**).

Table (1): Comparison between the two studied groups regarding age, sex, eye and FDT

Parameters	Groups	Group A	Group B	P-value
		No. = 10	No. = 10	
Age	Mean±SD	17.30 ± 5.29	21.30 ± 12.60	0.367
	Range	10 – 27	4 – 42	
Sex	Female	2 (20.0%)	2 (20.0%)	1.000
	Male	8 (80.0%)	8 (80.0%)	
	Right	3 (30.0%)	2 (20.0%)	0.606
	Left	7 (70.0%)	8 (80.0%)	
FDT	-4.00-	0 (0.0%)	9 (90.0%)	0.000
	-3.00-	0 (0.0%)	1 (10.0%)	
	3.00	5 (50.0%)	0 (0.0%)	
	4.00	5 (50.0%)	0 (0.0%)	

P value of elevation was statistically significant between preoperative and postoperative in the two groups (Table 2).

Table (2): Comparison between the two studied groups regarding elevation of the eye pre and post operative

Elevation		Group A		Group B		P-value
		No.	%	No.	%	
Pre-operative	-4.00-	4	40.0%	9	90.0%	0.019
	-3.00-	6	60.0%	1	10.0%	
	-2.00-	0	0.0%	0	0.0%	
	-1.00-	0	0.0%	0	0.0%	
Post-operative	-4.00-	0	0.0%	0	0.0%	<0.001
	-3.00-	0	0.0%	3	30.0%	
	-2.00-	0	0.0%	7	70.0%	
	-1.00-	10	100.0%	0	0.0%	
P-value		<0.001		0.001		

Ptosis improved postoperatively in 12 cases: 7 cases in group A (70%), and 5 cases in group B (50%). In 8 cases, surgery was needed: 3 cases in group A (30%), and 5 cases in group B (50%) (Table 3).

Table (3): Comparison between the two studied groups regarding ptosis of the eye pre and postoperative

Ptosis		Group A		Group B		P-value
		No.	%	No.	%	
Pre-operative	TRUE	3	30.0%	2	20.0%	0.819
	PSEUDO	2	20.0%	3	30.0%	
	TRUE + PSEUDO	5	50.0%	5	50.0%	
Post-operative	Mild	5	50.0%	2	20.0%	0.196
	Moderate	3	30.0%	2	20.0%	
	Severe	0	0.0%	3	30.0%	
	Improved	2	20.0%	3	30.0%	
Need Surgery	No need	7	70.0%	5	50.0%	0.361
	Need	3	30.0%	5	50.0%	

Hypotropia in group A improved from 19.4 PD preoperatively to 1.10 PD postoperatively with P-value 0.005. In group B, it improved from 28.90 PD preoperatively to 11.50 PD postoperatively with P-value 0.004 (Table 4, Figure 1 & 2).

Table (4): Comparison between the two studied groups regarding hypotropia of the eye pre and postoperative

Hypotropia (PD)		Groups	Group A	Group B	P-value
			No. = 10	No. = 10	
Pre-operative	Mean±SD		19.40 ± 1.43	28.90 ± 14.81	0.111
	Range		17 – 22	18 – 55	
Post-operative	Mean±SD		1.10 ± 1.91	11.50 ± 14.49	0.026
	Range		0 – 5	0 – 37	
Average of corrections	Mean±SD		18.30 ± 1.42	17.40 ± 1.58	0.196
	Range		16 – 20	15 – 20	
P-value			0.005 (HS)	0.004 (HS)	

In group B, 3 patients had Knapp's procedure; those 3 cases hypotroia improved by IRR from 50 PD preoperative to 32 PD postoperative then to 3 PD after Knapp's procedure **Tables (5 & 6)**.

Table (5): Comparison between preoperative and postoperative results regarding hypotropia and Knapp's procedure in group B

Hypotropia (PD)		Pre	Post	Average correction	P-value	Sig.
Knapp (need = 3)	Mean±SD	50.0 ± 5.00	32.00 ± 5.00	18.00 ± 0.00	0.03	S
	Range	45 – 55	27 – 37	18 – 18		
Knapp (No need= 7)	Mean±SD	19.86 ± 1.68	2.71 ± 2.56	17.14 ± 1.86	0.017	S
	Range	18 – 23	0 – 5	15 – 20		

Table (6): Comparison between the results of group B (3 patients) before and after Knapp's procedure

Hypotropia (PD)		Before Knapp	Post Knapp	Average correction	P-value	Sig.
Knapp (need = 3)	Mean±SD	32.00 ± 5.00	3.00 ± 2.65	29.00 ± 2.65	0.009	HS
	Range	27 – 37	0 – 5	27 – 32		

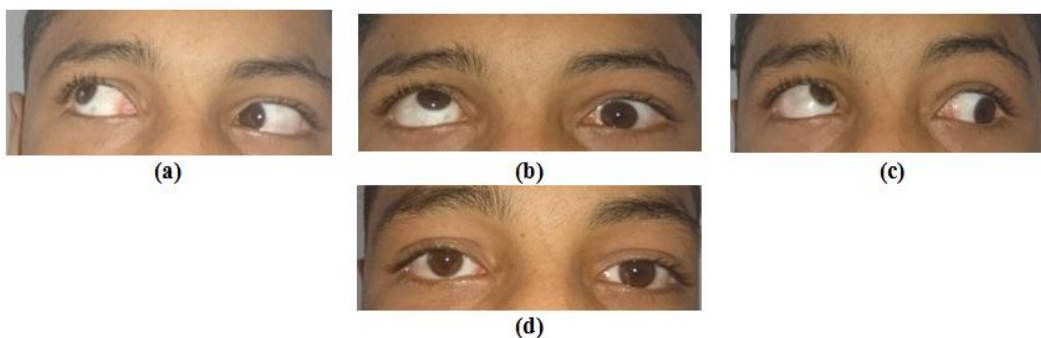


Figure (1): Preoperative; Case No. (4) in group A, (a) limited elevation of left eye in adduction, (b) limited elevation of left eye in up gaze, (c) limited elevation of left eye in abduction, (d) hypotropia in primary position.

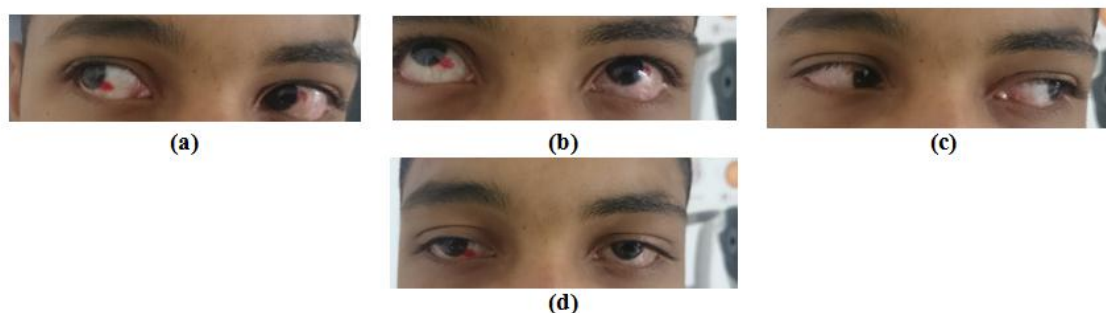


Figure (2): Postoperative: Case No. (4) in group A, (a) improved elevation of left eye in adduction, (b) improved elevation of left eye in up gaze, (c) improved elevation of left eye in abduction, (d) improved hypotropia in primary position.

DISCUSSION

In the current study, 20 patients with MED were collected from outclinic in Sayed Galal and El-Hussein University Hospitals. At the period from January 2017 to May 2019. The patients were divided into 2 equal groups: Group A with +ve FDT and group B with -ve FDT both groups had IRR. Age, gender, and laterality provided no particular diagnostic information. All cases have ptosis; 25% had true ptosis, 25% had pseudo ptosis, 50% had pseudo and true ptosis. Postoperative 25% of patients improved completely, 35% of patients improved with mild ptosis and 40% of patients had lid surgery. In *Talebnejad et al. (2014)* 70% of patients had true ptosis and 30% of patients had pseudoptosis of studied cases.

In the present study, although IRR markedly improving the elevation of the eye in patients with +ve FDT had limited effectiveness in patients with -ve FDT. Preoperatively, 40% of patients in group A were -4 (limited elevation), and 60% of patients were -3. All those patients improved to -1 (limited elevation) postoperatively. On the other hand, 90%

of patients in group B were -4 and 10% of patients were -3. They improved postoperatively to -3 and -2 respectively. *Talebnejad et al. (2014)* studied 18 patients had MED with different surgical interference according to FDT. The preoperative limitation of up gaze was -2 to -4 (mean -3.5) and postoperative was -1 to -3 (mean -1.55). This finding indicated a significant decrease in up gaze limitation.

In the current study, one surgical procedure was used as a 1ry intervention whatever the results of FDT in patients with MED and evaluated the results based on ocular alignment in 1ry position and those with residual significant hypotropia had Knapp's procedure.

In group (A), the average of preoperative hypotropia was 19.40 ± 1.43 PD. All the patients had IRR the postoperative average of hypotropia was 1.10 ± 1.91 PD with average of correction 18.30 ± 1.42 PD. The results agree with most reports that studied the results of IRR in MED with +ve FDT as following; *Bagheri et al. (2013)* the average of correction was 20 PD, *Talebnejad et al. (2014)* the average of correction was 18.6

and *Bandyopadhyay et al. (2016)* the average of correction was 16 PD.

In group (B), a reliable and effective correction of hypotropia in 70% of patients with preoperative mean deviation 19.86 ± 1.68 PD and postoperative mean deviation 2.71 ± 2.56 PD with average of correction 17.14 ± 1.86 PD. Partial correction of hypotropia in 30% of patients with preoperative mean derivation 50.0 ± 5.00 PD and postoperative mean deviation 32.00 ± 5.00 PD with average of correction 32.00 ± 5.00 PD. Then the 30% of patients underwent Knapp's procedure with postoperative average of correction was 29.00 ± 2.65 PD This results was in agreement with studies of IRR followed by Knapp's procedure as following; *Kocak-Atinatas (2011)* the average of correction was 25.8 ± 5.6 PD, *Talebenjad et al. (2014)* the average of correction was 26 PD, *Bandyopadhyay et al. (2016)* the average of correction was 28.6 PD and.

In this study, the effectiveness of Knapp's procedure in correction of vertical deviation increased in eyes with previous IRR. Not only vertical deviation, but also elevation of eye and chin elevation improved. This result was in agreement with *Kockak-Altinas (2011)*. In their study 14 of patients underwent surgery were reviewed 43% of patients had IRR followed Knapp's procedure and correction of vertical deviation was $25.8 \text{ PD} \pm 5.6 \text{ PD}$ and 57% of patients had Knapp's procedure without IRR and the average of correction was $18.6 \text{ PD} \pm 4.4 \text{ PD}$. They concluded that surgical effectiveness of transposition surgery may be enhanced by IRR.

Awadein and El-Fayoumi (2015) studied cases with MED with inferior

rectus restriction by evaluating the results of ipsilateral inferior rectus recession alone or combined with contralateral superior rectus recession. They found that combined contralateral SR recession with ipsilateral inferior rectus recession achieved better ocular alignment in up gaze and down gaze.

Gundhi and Kekunnaya (2019) who studied patients with MED. IRR were done with single muscle transposition. The average correction was 34.6 PD which considered promising results but this surgical procedure.

Kamlesh and Prolima (2017) studied the efficacy of vertical muscle surgery for management of hypotropia in monocular elevation deficiency (MED) with hypotropia. They found that vertical superior rectus resection and inferior rectus recession are good alternative for management of MED. They spared horizontal muscles for correction of any associated horizontal deviation.

CONCLUSION

Although the MED is etiologically multifactorial. Satisfactory surgical results can be achieved by IRR as a simple and reliable 1ry intervention for both types (+ve FDT and -ve FDT). IRR is suitable for those patients with hypotropia < 25 PD. Patients with hypotropia > 25 PD and -ve FDT usually need Knapp's procedure. Although the IRR in patients with - ve FDT is effective intervention for correcting the alignment of eyes in 1ry position, it still with limited effectiveness in elevation of eye. IRR increased the magnitude of Knapp's procedure.

Conflicts of interest: No conflicts of interest were encountered.

REFERENCES

1. **Awadein A and El Fayoumi D (2015):** Surgical management of MED combined with inferior rectus restriction. *JAAPOS*, 19: 316-321.
2. **Bagheri A, Sahebghalam R and Abrishami M (2013):** Double elevator palsy, subtypes and outcomes of surgery. *Journal of Ophthalmic & Vision Research*, 3: 108-112.
3. **Bandyopadhyay R, Shetty S and Vijayalakshmi P (2016):** Surgical outcome in monocular elevation deficit: A retrospective interventional study. *Indian Journal of Ophthalmology*, 56: 127-131.
4. **Gandhi U and Kekunnaya R (2019):** Single Horizontal Muscle (Medial or Lateral Rectus) Transposition and Inferior Rectus Recession in Monocular Elevation Deficit: A Novel Surgical Technique. *Journal of Pediatric Ophthalmology and Strabismus*, 56: 183-187.
5. **Goray A (2015):** Monocular Elevation Deficit-Simplified. *The official Scientific Journal of Delhi Ophthalmological Society*; 26:7-13.
6. **Kamlesh SD and Prolima T (2017):** To Assess the Efficacy of Vertical Muscle Surgery for Management of Hypotropia in Monocular Elevation Deficiency Type II. *Int ophthalmol*; 37(4): 1009-1016.
7. **Kocak-Altintas AG (2011):** Selective management of double elevator palsy by either inferior rectus recession and/or knapp type transposition surgery. *Binocular Vision & Strabismus Quarterly*, 15: 39-46.
8. **Saluja G and Bhari A (2019):** Monocular elevation deficit after scleral perforation repair. *BMJ case reports CP*; 10:129-133.
9. **Talebnejad MR, Roustaei GA and Khalili MR (2014):** Monocular elevation deficiency: a case series of surgical outcome. *Iranian Journal of Medical Sciences*, 39:102-105.
10. **Zafar SN, Azad N and Khan A (2012):** Outcome of surgical treatment of MED: *J Pak Med Assoc*, 62: 355-337.

تقييم إرجاع العضلة المستقيمة السفلية في علاج إضراب رفع العين الأحادي

تامر توحيد محمد عبدالسلام، عطيات مصطفى السيد مصطفى، محمود محمد صالح.

قسم طب وجراحه العيون، كلية الطب، جامعة الأزهر، القاهرة، مصر

خلفية البحث: عجز رفع العين الأحادي هو عدم قدرة رفع العين المصابة لأعلي.

الهدف من البحث: تقييم إرجاع العضلة المستقيمة السفلية في علاج عجز رفع العين الواحدة سواء أكان إختبار "تحريك العين الإجباري" إيجابى أو سلبى.

المرضى وطرق البحث: أجريت هذه الدراسة على 20 مريض من المترددين في مستشفى الحسين الجامعى ومستشفى السيد جلال الجامعى في الفترة من يناير 2017 إلي مايو 2019. وتم تقسيم المرضى إلي مجموعتين متساويتين: المجموعة الأولى وفيها إختبار "تحريك العين الإجباري" إيجابى، والمجموعة الثانية فيها إختبار "تحريك العين الإجباري" سلبى وفي كلتا المجموعتين تم عمل عملية إرجاع العضلة المستقيمة السفلية.

نتائج البحث: 40% من مرضى المجموعة الأولى كانوا يعانون من عدم قدرة رفع العين بمقدار 4_، 60% منهم بمقدار 3_ وبمتابعة المرضى بعد العملية تحسن جميع المرضى إلي 1_ 90% من مرضى المجموعة الثانية كانوا يعانون من عدم قدرة رفع العين بمقدار 4_، 10% بمقدار 3_ وبمتابعة المرضى، تحسنت قدرة العين للتحرك للأعلي بمقدار 3_ و 2_ علي التوالي. وكان متوسط الحول بين مرضى المجموعة الأولى قبل العملية 19.4 ديوبتر منشوري، ومتوسط الحول

بين المرضى بعد العملية 1.1 ديوبتر منشوري، وكان متوسط إصلاح الحول حوالي 18.3 ديوبتر منشوري. وكان متوسط الحول بين 7 مرضى في المجموعة الثانية قبل العملية 19.8 ديوبتر منشوري وبعد العملية 2 ديوبتر منشوري وكان متوسط إصلاح الحول حوالي 17.8 ديوبتر منشوري. وتم إجراء عملية نقل العضلات المستقيمة الأفقيه (طريقه ناب) للمرضى الثلاثة المتبقين من المجموعة الثانية وكان متوسط إصلاح درجة الحول 29 ديوبتر منشوري.

الإستنتاج: بالرغم من أن مرض عجز الرفع للعين الواحدة هو مرض متعدد الأسباب، إلا أن عملية إرجاع العضلة المستقيمة السفلية كتدخل جراحي أولي له نتائج جيدة سواء أكان إختبار " تحريك العين الإجباري " إيجابى أم سلبى.