



Thymoquinone attenuates dimethoate induced hepatic and testicular genotoxicity in rats

Fatma B Zakzok*, Hanaa M Hegazy, Tarek A Yosef, Ghada M Gomaa

Department of Forensic Medicine and Toxicology, Faculty of Veterinary Medicine, Kafrelsheikh University, Egypt

*Correspondence: fatmablal2@gmail.com

Abstract

Background: Dimethoate (DM) is an organophosphate insecticide widely used on crops in Egyptian fields. DM has many toxic impacts on non-target organisms especially mammals.

Objective: This study aimed to evaluate the role of thymoquinone (TQ) against DM-induced hepatic and testicular subchronic genotoxicity.

Methods: Forty- eight rats were randomly divided into 6 groups each of eight animals. Group 1 served as the normal control received distilled water; Group 2 was given DM; Group 3 received DM+TQ; Group 4 was treated by TQ; Group 5 was supplemented with DM+ olive oil (as a vehicle); and Group 6 was given olive oil. Oxidative/antioxidant status was assessed by quantification of malondialdehyde (MDA) levels and superoxide dismutase (SOD) and catalase (CAT) activities. Genotoxicity and apoptosis in the liver and testis were evaluated using the comet assay and immunohistochemical expression of caspase3 and Bax, respectively.

Results: Significant DNA damage, marked histopathological changes in liver and testis, intense nuclear and cytoplasmic immune-expression of caspase 3 and Bax, significant decreases in catalase (CAT) and superoxide dismutase (SOD) activities and significant increase in malondialdehyde (MDA) levels were observed in DM-treated rats as compared to the control group. Concomitant treatment of TQ with DM drastically alleviated all the above-mentioned alterations.

Conclusion: These findings suggest that TQ exhibits an outstanding ameliorative role against DM-induced hepatic and testicular genotoxicity in rats through the mitigation of oxidative stress and apoptosis.

Keywords: Apoptosis; Dimethoate; Genotoxicity; Oxidative stress; Thymoquinone.

1. Introduction

Different types of pesticides are used in tropical and sub-tropical countries because of the obvious crop loss by pests. The random use of these pesticides for agricultural, industrial and domestic purposes has posed a threat to animals and humans besides causing environmental pollution (Alavanja, 2009). Organophosphates (OPs) are widely used in agriculture and household applications with a high share of the global insecticide market. Unrestricted use of OPs has sorely affected many non-target organisms including humans and animals (Baselt, 2008).

Dimethoate (DM) is one of the most important systemic and contact OP insecticides (Barski and Zasadowski, 2006) used extensively in agricultural fields on a large number of crops and the domestic environment against a broad range of insects and mites and is also used for indoor control of houseflies. Generally, the majority of the population is chronically exposed to low doses of DM *via* food, contaminated drinking water, or by application of household insecticides containing DM (WHO/IPCS, 2001). Inhibition of acetylcholinesterase is the main toxic action of DM (Hoffmann and Papendorf, 2006). Additionally, DM induces oxidative stress in humans (Ranjbar et al., 2002) and animals (Sharma et al., 2005a). DM exerts its toxic effects on many tissues and organs including the pancreas (Kamath et al., 2008), liver (Saafi et al., 2010), kidney (Mahjoubi-Samet et al., 2008) and brain (Astiz et al., 2009). Equally

important, DM was also shown to affect the reproductive system (Astiz et al., 2009).

Our main question is how DM induces subchronic hepatic and testicular genotoxicity when administered to rats, with special regard to the role of oxidative stress which can be a leading cause of DNA damage and apoptosis in the liver and testis of treated rats. Oxidative stress is defined as a condition in which pro-oxidant-antioxidant balance in the cell is disturbed; ultimately compromising cell viability (Abdelhady et al., 2017). Also, it may cause cellular apoptosis via both the mitochondria-dependent and mitochondria-independent pathways (Abu Khudir et al., 2019; Krishnendu et al., 2013).

So far, very little research has been carried out on the subchronic genotoxic effect of DM on the liver and testis of rats. So, our goal in this study is to spot the light on this effect. Ayed *et al.* (2012) reported a genotoxic effect for DM on mice with a significant increase in the frequency of micronucleated bone marrow cells, marked increase in the percentage of chromosome abnormalities in a dose-dependent manner, as well as DNA damage in bone marrow cells. Moreover, DM-induced DNA damage in the liver and kidney of treated mice in a dose-dependent manner; this induction was associated with DM-induced oxidative stress (Ayed et al., 2012).

Another crucial question in this study sheds light on using Thymoquinone (TQ) against subchronic genotoxicity as there have

been no previous attempts to investigate this effect. TQ, the main active component of the essential oil of *Nigella sativa* seeds, is known for its ability to reduce oxidative stress not only through direct antioxidant effect but also indirectly (Ayman et al., 2016). The indirect antioxidant action is mediated through the activation of nuclear factor erythroid-2 (Nrf2) protein and increases the expression of genes involved in the recognition and repair of damaged deoxy ribonucleic acid (DNA) (Zhou et al., 2007). So, the present study aimed to assess and interpret the role of TQ against subchronic genotoxicity induced by DM in the liver and testis of rats.

2. Materials and methods

The study was approved by the Ethics Committee of Local Experimental Animals Care Committee and conducted in accordance with the guidelines of Kaferelsheikh University, Egypt.

2.1. Chemicals

Dimethoate (technical grade 95%) supplied by Kafr Elzayat Pesticides and Chemicals Co. (Egypt). Thymoquinone (purity $\geq 98\%$) was purchased from Sigma Aldrich (Saint Louis, USA, cat # MO 63103) and was in the form of white crystalline powder. Olive oil used for dissolving of TQ, purchased from El Baraka for Natural oils company (Egypt). Primary antibodies for caspase 3 (cat # PA1-29157) and Bax (cat # PA5-11378) were got from Thermo Fisher Scientific Company. Kits used for CAT, SOD and MDA measurements were purchased from Bio Diagnostic Company (Giza, Egypt).

2.2. Animals and housing conditions

White male Sprague Dawley albino rats, weighing 120 ± 6 g, were obtained from the Animal Experimental Unit, Faculty of Veterinary Medicine, Zagazig University, Egypt. They were housed in stainless steel well-aerated cages (4 rats per cage) at normal atmospheric temperature ($25 \pm 5^\circ$ C) and normal 12-hour light/dark cycle. They had free access to water and were supplied with a standard daily diet of rodents.

2.3. Experimental protocol

Forty-eight rats were randomly divided into six groups each of eight animals. All treatments were applied by oral gavage twice weekly for 11 weeks. The first group was used as control and administered distilled water. The second group was administered DM. The third group was supplied with DM + TQ. The fourth group received TQ. The fifth group was given DM + olive oil. The sixth group was given olive oil. DM was dosed by 20 mg/kg b.wt. (Kamath and Rajini, 2007) which is equivalent to 1/20 of LD₅₀. TQ was administered by a dose level of 10 mg/kg b.wt (Sener et al., 2016). Olive oil was administered by the same dose of TQ.

2.4. Sample collection

After completion of the treatment period, animals of different groups were sacrificed under anesthesia by cervical dislocation and their liver and testis were carefully separated and washed in normal saline then divided into 3 portions; one portion was preserved in PBS at -20° C for comet assay then finely minced to obtain a cellular

suspension. The second portion of the same samples was fixed in 10% phosphate-buffered formalin (pH 7.4) for histopathological and immunohistochemical examination, while the third portion (hepatic samples) was cut into small pieces, homogenized in phosphate buffer saline (PBS, PH 7.4), and centrifuged at 4000 rpm for 15 min at 4° C. Supernatants were collected and stored at -80° C until their use for measurement of SOD and CAT activities and MDA level.

2.5. Determination of DNA damage by comet assay

The alkaline comet assay was carried out as described by Tice et al. (2000) with some modifications (Singh et al., 1988). Immediately after euthanasia, a small piece of liver or testis was placed in 1 ml of cold PBS containing 20 mM EDTA/ 10% DMSO and minced into fine pieces to obtain a cellular suspension. Suspensions (10 μ l) were embedded in 75 μ l of 1% low melting point agarose and spread on a base slide pre-coated with a layer of 1% normal melting point agarose. The agarose was allowed to set at 4° C for 5–10 min and the slides were immersed in lysis solution (2.5 M NaCl, 100 mM EDTA, 10 mM Trizma base, NaOH to pH 10.0) with freshly added 1% Triton X-100 and 10% DMSO at 4° C overnight. Slides were then placed side by side on the horizontal gel box along with filling the buffer reservoirs with freshly made pH >13 electrophoresis buffer containing 300 mM NaOH and 1 mM EDTA for 20 min before electrophoresis at 24 V for 30 min at an ambient temperature. The slides were then washed three times by neutralization buffer for 5 min each with 0.4 M Tris-HCl, pH 7.5, before staining with 80 μ l ethidium bromide (20 μ g/ml). For visualization of DNA damage, observations are made of ethidium bromide-stained DNA using a 40x objective on a fluorescent microscope.

2.6. Histopathological examination

Liver and testicular specimens were dehydrated in a series of graded ethanol solutions, cleared in xylene and embedded in paraffin. Sections of 4 μ m thickness were obtained then stained with hematoxylin and eosin. After staining, tissue sections were mounted with a coverslip to be observed under a light microscope (Bancroft, 1996).

2.7. Immunohistochemical examination of caspase 3 and Bax

Caspase 3 and Bax immunostaining were done according to the method mentioned by Frost et al. (2000) with some modifications Sheriffs et al. (2001). Fixed liver and testicular tissues were embedded in paraffin wax and the sections were cut into 5 μ m thickness. Formalin-fixed slides were deparaffinized in xylene for 2-5 min, hydrated with 100% ethanol for 2-3 min then hydrated with 95% ethanol for 1 min, finally they were rinsed in distilled water. Pre-treatments of tissue sections (Epitope Retrieval) was achieved by heat treatment in an autoclave at 121° C for 1-2 min in tris buffer then the slides were put in hydrogen peroxide in methanol (0.3%) for 20-30 min; sections were incubated at 37° C for 10-30 min. Immunoenzyme staining was achieved by rinsing solutions in PBS for 2 min then serum blocking by incubating sections in normal goat serum blocking solution at room temperature for 30 min. These sections were incubated in primary antibody (caspase 3 and Bax with dilution 1:100) at 4° C overnight and were rinsed in PBS for 3-20 min. Peroxidase blocking was carried out by incubating sections in peroxidase blocking solution (3% H₂O₂ in PBS) for 10 min at room temperature than were rinsed in PBS for 2-3 min. After that, sections were incubated in an anti-rabbit secondary antibody (Dako) for 30 min

at room temperature then rinsed in PBS for 3-10 min. Additionally, sections were incubated in DAB peroxidase substrate and rinsed in PBS for 2-3 min. Counterstaining of sections was carried out with Mayer's hematoxylin solution then washed in running tap water for 2-5 min. Following this step, dehydration was carried out in graded ethanol (95%, 100%) for (1, 2-3) min respectively. Finally, Sections were cleared in xylene for 2-5 min followed by their coverslipping with mounting medium. Immunostaining reaction was quantified using Image J software/

2.8. Determination of Oxidant/ antioxidant status

CAT was estimated according to the method mentioned by Aebi, (1984) while, SOD was determined according to the method described by Nishikimi et al. (1972) in hepatic homogenates. Lipid peroxidation in liver homogenates was estimated by measuring the level of malondialdehyde (MDA) as stated by the method of Ohkawa et al. (1979).

2.9. Statistical analysis

Analyzing of data was done using PROC MIXED of SAS (SAS 2012). The model for data analysis contained treatment, and rats were nested within treatment as a random effect. Statistical differences were declared significant at $p < 0.5$.

3. Results

3.1. Effect of TQ on DNA damage of liver and testis of DM-intoxicated rats

Table 1 and Fig. 1 show the effects of DM, DM+ TQ treatments on DNA damage (comet %, head diameter, DNA% head, tail length, DNA % tail, tail moment, olive tail moment) in rat hepatic and testicular tissues using the comet assay. Compared to the control group, DM treated group revealed a significant increase in the levels of all tested parameters except DNA % head which showed a significant decrease. Otherwise, the co-treatment of TQ with DM ameliorated the level of DNA damage caused by DM as stated by a significant decrease in the above parameters with an obvious increase in DNA% head.

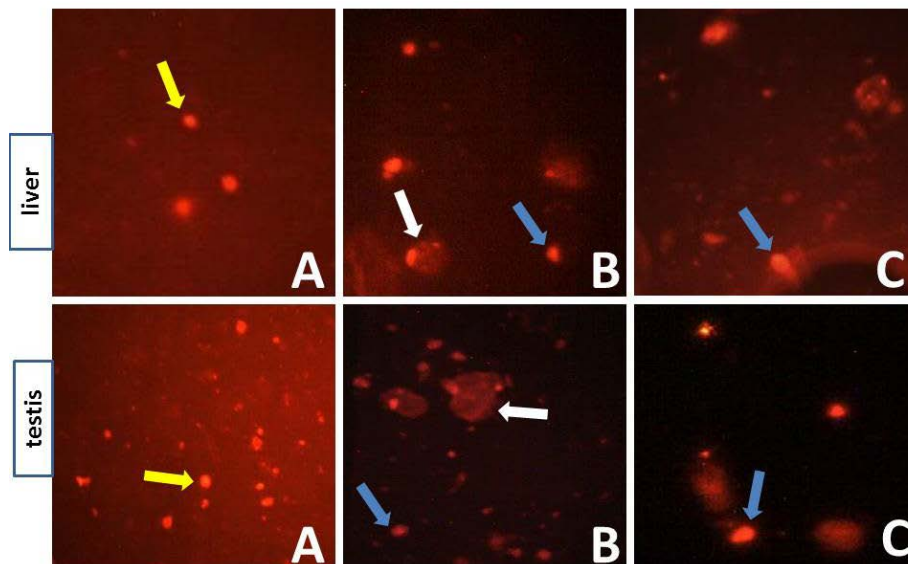


Figure 1: Photomicrographs representative the different degrees of DNA damage in the liver and testis of rats as evaluated by the comet assay after treatment by DM and the co-treatment of TQ with DM. Yellow arrows: intact nuclei, blue arrows: low degree of damage, white arrows: high degree of damage in different treated groups. (A) Control group, (B) DM-treated group, (C) DM+ TQ-treated group. Ethidium bromide X40.

Table 1: The level of DNA damage assessed by comet assay in the liver and testis of male rats administered DM and the effects of TQ co-administration.

	Comet %	Head diameter	DNA% head	Tail length	DNA% tail	Tail moment	Olive tail
DM	36.675 ^a ± 1.219	16.963 ^a ± 0.678	62.988 ^d ± 1.370	7.413 ^a ± 0.264	37.175 ^a ± 1.047	3.175 ^a ± 0.104	0.939 ^a ± 0.035
Control	13.950 ^e ± 0.515	12.650 ^e ± 0.351	76.813 ^a ± 1.747	4.750 ^d ± 0.245	24.900 ^e ± 1.604	1.513 ^d ± 0.083	0.449 ^d ± 0.028
DM+TQ	22.663 ^a ± 0.891	14.850 ^e ± 0.499	70.263 ^e ± 1.692	5.750 ^e ± 0.245	31.538 ^e ± 0.707	2.750 ^b ± 0.120	0.550 ^e ± 0.029
TQ	16.813 ^d ± 0.617	12.838 ^e ± 0.760	75.075 ^b ± 1.481	4.625 ^d ± 0.167	26.863 ^d ± 1.695	1.700 ^e ± 0.093	0.379 ^e ± 0.019
DM+ Q.oil	30.800 ^b ± 0.926	15.250 ^{bi} ± 0.342	63.525 ^d ± 1.140	6.838 ^b ± 0.504	33.225 ^b ± 1.116	2.788 ^b ± 0.083	0.846 ^b ± 0.055
Q.oil	14.238 ^e ± 0.641	14.413 ^{cd} ± 0.372	75.488 ^{ab} ± 0.906	4.738 ^d ± 0.407	24.813 ^e ± 0.895	1.300 ^e ± 0.093	0.559 ^e ± 0.025

3.2. Effect of TQ on histology of liver and testis of DM-intoxicated rats

Normal hepatic histoarchitecture in the form of hepatocytes arranged in cords around the central vein was observed in the normal control group (upper lane, arrow, Fig.2 A). In DM-treated rats, there were periportal vacuolation, diffuse vacuolation of hydropic nature, fatty degeneration, and marked inflammatory reaction associated with mononuclear cell infiltration within the periportal area (arrow, Fig.2B). A mild to moderate degree of hepatic vacuolation in the perinuclear area was noticed in DM rats treated with TQ (arrow, Fig. 2C).

In testis, control rats showed normal testicular structure (upper lane, arrow, Fig.3A). In rats treated with DM, testes have illustrated marked tissue alteration represented by degeneration, necrosis and loss of spermatogenic cell layer (arrow, Fig.3B). The most interesting feature is represented by Sertoli cell vacuolation and severe interstitial edema (arrowhead, Fig.3B). Co-administration of TQ with DM showed a mild testicular degeneration with the presence of free sperms in the lumen when compared to the DM treated group (arrow, Fig.3C).

3.3. Effect of TQ on caspase 3 and Bax immunostaining in liver and testis of DM-intoxicated rats

The control group revealed negative immunostaining for caspase 3 (middle lane, arrowhead, Fig.2A). Meanwhile, liver samples of DM treated rats showed marked cytoplasmic and nuclear expression of caspase 3 (arrow, Fig.2B). DM + TQ treated animals showed few focal immunostained positive cells as compared to the DM treated rats (arrowhead, Fig.2C).

Testicular tissue from the control group showed minimal caspase3 cytoplasmic immunostained cells (middle lane, arrowhead,

Fig.3A). In contrast, testis of DM treated group demonstrated intense expression of caspase 3 mostly within the degenerated spermatogenic cells (arrowhead, Fig.3B). Co-treatment of DM rats with TQ showed a minimal immune-expression for caspase 3 (arrowheads, Fig.3C).

Hepatic tissue of the control group revealed negative immunostaining for Bax (lower lane, Fig.2A). However, the liver of DM treated animals exhibited aggravated nuclear and cytoplasmic immuno-expression, especially within the mid zonal area (arrowhead, Fig.2B). Liver of DM + TQ treated animals showed focal perivascular positive immunostaining for Bax (arrowhead, Fig.2C).

Minimal Bax cytoplasmic immunostaining in the testicular tissue of the control group (lower lane, Fig.3A). Treatment with DM revealed an enhancement in nuclear and cytoplasmic expression within the spermatogonia (arrowhead, Fig.3B). The cytoplasmic expression for Bax was only demonstrated in the testis of the DM+ TQ treated group (Fig.3C). The immune labeling index of caspase3 and Bax in the liver and testis of all groups was illustrated in Figure 4.

3.4. Effect of TQ on antioxidant and oxidative status in the liver of DM-intoxicated rats

Exposure of rats to DM resulted in a significant decline in the CAT activity compared to the control group. Co-treatment of DM rats with TQ caused a significant elevation in hepatic CAT activity as compared to the DM treated group (Table 2). The DM rats showed a significant increment in the inhibition% of SOD activity in contrast to the control group. Supplementation of TQ to DM treated rats caused a decrease in the elevated inhibition % of hepatic SOD activity when compared to DM treated group (Table 2). MDA, as a lipid peroxidation marker, significantly increased in DM treated rats relative to the control group. Co-administration of DM with TQ revealed a significant reduction in the elevated hepatic MDA content as compared to DM treated group (Table 2).

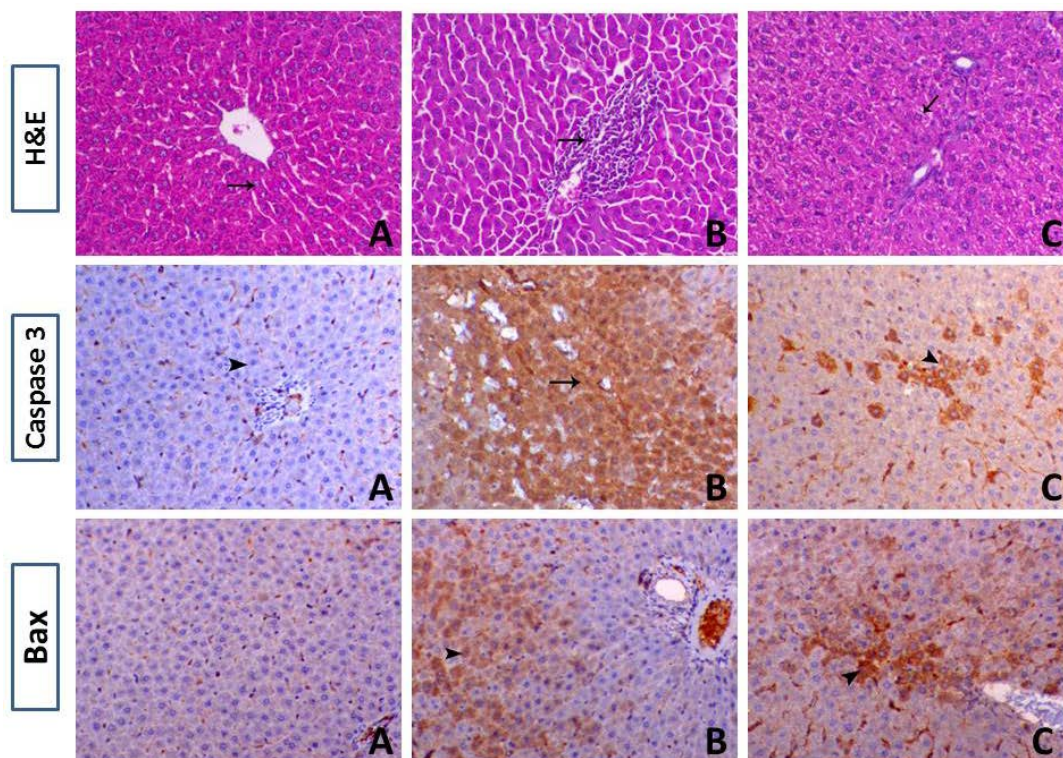


Figure 2: The upper lane illustrates histopathological images of the liver of control rats (A), DM-treated rats (B), and DM+TQ-treated animals (C) (X200). Middle lane: immunolocalization of caspase 3 in the liver of control rats (A), DM-treated rats (B), and DM+TQ-treated rats (C) (X200). Lower lane: immunohistochemical expression of Bax in the liver of control rats (A), DM-treated rats (B), and DM+TQ-treated rats (C) (X200).

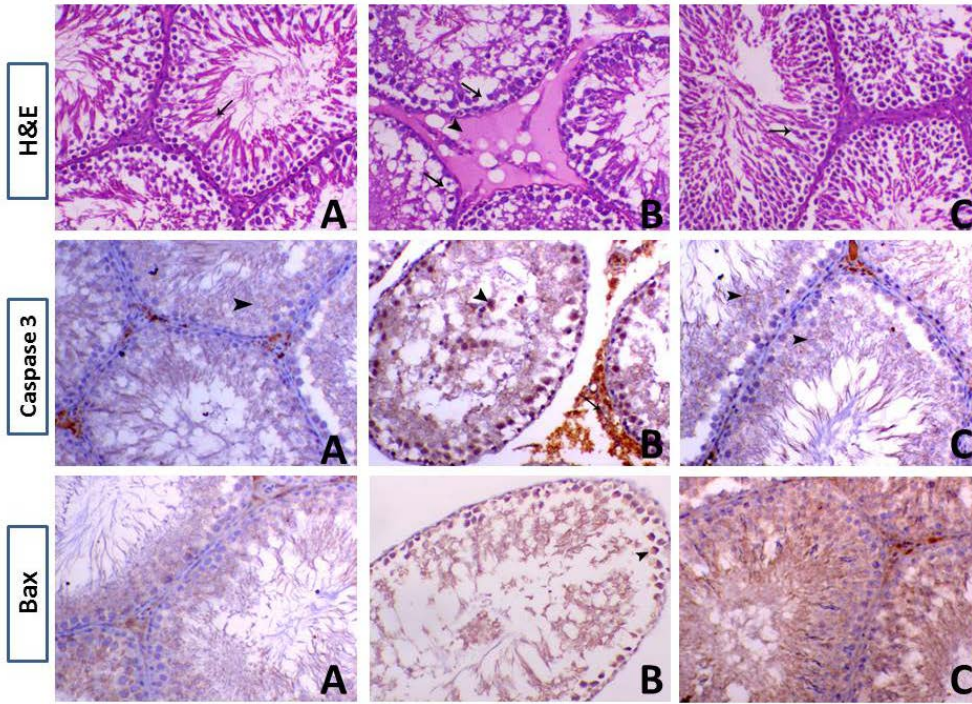


Figure 3: The upper lane illustrates histopathological images of the testis of control rats (A), DM-treated rats (B), and DM+TQ-treated animals (C) (X200). Middle lane: immunolocalization of caspase 3 in the testis of control rats (A), DM-treated rats (B), and DM+TQ-treated rats (C) (X200). Lower lane: immunohistochemical expression of Bax in the testis of control rats (A), DM-treated rats (B), and DM+TQ-treated rats (C) (X200).

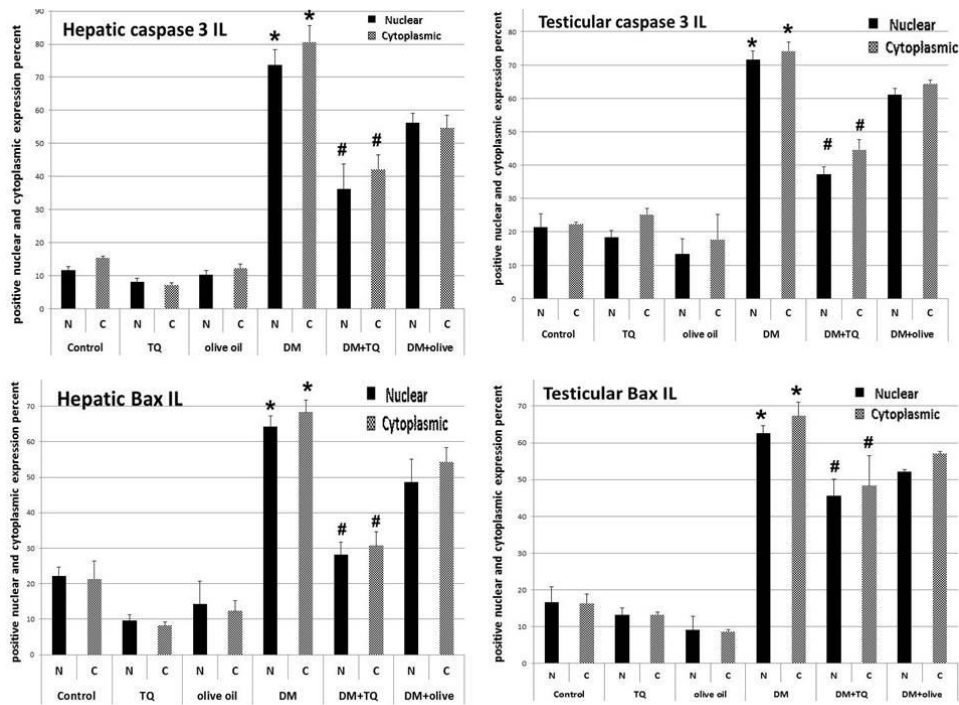


Figure 4: Quantification (immune labeling index, IL) of caspase 3 and Bax expression in liver and testis of different groups, * $P \leq 0.05$ (DM vs control), # $p \leq 0.05$ (DM vs DM+TQ).

Table 2. The activities of antioxidant enzymes and MDA levels in the liver of rats administered DM and the effects of TQ co-administration.

	CAT	SOD (inhibition %)	MDA
DM	4.566 ^f ± 0.127	96.300 ^a ± 1.772	9.571 ^a ± 0.231
Control	8.748 ^a ± 0.140	43.000 ^e ± 1.369	6.731 ^e ± 0.124
DM+TQ	7.198 ^c ± 0.046	74.238 ^c ± 1.062	7.649 ^c ± 0.075
TQ	7.820 ^b ± 0.054	41.275 ^f ± 0.959	6.652 ^e ± 0.130
DM + O. oil	7.609 ^c ± 0.118	86.950 ^b ± 1.522	8.701 ^b ± 0.199
O. oil	7.421 ^d ± 0.176	45.913 ^d ± 1.076	6.598 ^e ± 0.225

Values are expressed as mean ± SD. Means within the same column having different superscripts are significantly different ($P \leq 0.05$).

4. Discussion

The extensive use of pesticides resulted in a series of toxicological problems (Mokhbatly, et al., 2019). Recent studies have demonstrated that reactive oxygen species (ROS) are a double-edged sword – they serve as key signal molecules in physiological processes but also their overabundance results in oxidative stress which results from an imbalance between pro-oxidants (free radical species) and the body's scavenging ability (antioxidants) that leads to oxidative damage to all cell components and plays a pivotal role in apoptosis (Abdelhady et al., 2017; Ashok et al., 2005). Apoptosis may involve mitochondria or may follow a mitochondria independent pathway in a caspase-dependent or caspase-independent manner (Badawy et al., 2018; Krishnendu et al., 2013). Antioxidants can block or delay apoptosis (El-Magd et al., 2019, Krishnaswamy and Sushil, 2000). In this line, NRF2 appears to be the master regulator to protect cells from oxidative and electrophilic stress. Also, it conserves them from apoptosis (El-Magd et al., 2018; Sajadimajd and Khazaei, 2017).

The most obvious finding to emerge from our comet analysis is that DM- treated group depicted a significant increase in the comet %, head diameter, tail length, DNA% tail, tail moment and olive tail moment in hepatic and testicular tissues as compared to the control group. These findings infer that DM has a genotoxic effect on mammalian *in vivo* system (Vijayaraghavan and Nagarajan, 1994). It is also considered as cytotoxic stimuli that booster ROS production and oxidative stress (Ogutcu et al., 2006). Oxidative stress considers a conjoint pathological mechanism that initiates DNA damage and apoptosis in exposed rats (Abu El-Saad and Elgerbed, 2010; Magdy et al., 2020) through their indiscriminate oxidation of all molecules in biological membranes and tissues (Demple and Harrison, 1994) as these radicals attack not only proteins but also DNA bases (Ben Amara et al., 2013) owing to its alkylating property (Wild, 1975).

Hepatic and testicular dysfunction was substantiated by histopathological data. In the liver of DM-treated rats, there was a marked mononuclear cell infiltration mainly the macrophages considered as a prominent response of the body facing any injurious impacts. One interesting finding is the peri-portal vacuolation, indicating the beginning of a necrosis step. Moreover, diffuse vacuolation of hydropic nature and fatty degeneration were noticed. Additionally, the most interesting feature in the testis of DM treated rats is represented by Sertoli cell vacuolation and severe interstitial edema. Furthermore, marked tissue alteration represented by degeneration, necrosis and loss of spermatogenic cell layer was detected. These results corroborate the ideas of Creasy (2001) who reported that one of the most common morphological responses of Sertoli cells to injury is vacuolation and germ cell degeneration. A possible explanation for these results may be the accumulation of free radicles as the consequence of the increased LPO levels in the hepatic and testicular tissues suggesting the involvement of oxidative stress following exposure to DM (Ben Amara et al., 2013).

Immunohistochemical observations in our study revealed increased nuclear and cytoplasmic expression of Bax and caspase 3 in the hepatic and testicular tissue of DM exposed rats compared with the control group suggesting that DM is a potent inducer of apoptosis. These results agree with those of the previous studies that reported an increase in Bax and caspase3 activity in cardiac tissue of rats after diazinon administration for 4 weeks (Razavi et al., 2013). Furthermore, subchronic exposure to dichlorvos was reported to increase caspase 3 and 9 activities in endometrium tissue (Oral et al., 2006). These results confirm the association between OP including

DM and apoptosis through caspase3 activation (Masoud et al., 2003). Güney et al. (2007) reported that activated caspase-3 and -9 is responsible for the breakdown of several cellular components related to DNA repair and regulation during apoptosis. Additionally, intracellular ROS generation and/ or depletion of cellular antioxidants are contributing factors to these findings (Serbecic and Beutelspacher, 2005).

The current study showed that there is a significant decrease in the CAT activity besides, marked increase in inhibition% of SOD activity along with a tremendous increase in MDA level in DM treated group when compared to the control. Several factors could explain these observations. Firstly, OP including DM induce oxidative stress through the formation of free radicles suggesting the dysfunction of the mitochondrial respiratory chain (Ben Amara et al., 2013), and secondly, they change the normal antioxidant homeostasis resulting in antioxidant depletion (Possamai et al., 2007) as well as, disturbing the redox processes, thereby changing the activities of antioxidant enzymes processes along with enhancement of lipid peroxidation (Ben Amara et al., 2012). Lipid peroxidation is one of the well-recognized mechanisms of cell damage analyzed as an oxidative stress biomarker (El-Magd et al., 2016; Işık and Celik, 2008). Elevation determined in lipid peroxidation shows that reactive species produced under DM stress were not eliminated effectively by antioxidant enzymes (Modesto and Martinez, 2010). These disruptions consider as a compensatory mechanism through the effects of DM on the liver and testicular cells.

Treating rats with TQ in our study has led to an ameliorative effect against DM-induced subchronic hepatic and testicular toxicity. Initially, TQ restoration effect was declared by a significant decrease in the comet%, head diameter, tail length, DNA % tail, tail moment and olive tail moment with a marked increase in DNA% head. Histological analysis revealed a substantial decrease in hepatic and testicular vacuolation with minimal hepatic alteration and normal seminiferous tubules in contrast to DM treated rats. Moreover, the reduction in immunohistochemical expression of caspase3 and Bax in the liver and testis suggests the ability of TQ to mitigate apoptosis induced by DM. Additionally, TQ alleviates the decrease in CAT activity and the increase in SOD activity inhibition% also; it ameliorates the increase in MDA when compared to DM treated group. These results are likely to be related to TQ's ability to reduce oxidative stress through direct and indirect antioxidant actions. Considering its direct antioxidant effect, it seems to be related to its quinone structure (El-Najjar et al., 2010). TQ is reported to induce phase-II enzymes involved in the antioxidant activities through activation of the Nrf2 pathway (Kundu et al., 2014) and increase the expression of genes involved in the recognition and repair of damaged DNA through an indirect mechanism (Zhou et al., 2007). TQ exhibits a protective effect by restoring the endogenous antioxidant system, preventing DNA fragmentation besides reducing lipid peroxide metabolism (Prashant et al., 2016). The anti-apoptotic effects of TQ may be mediated by one or more of the following mechanisms: antioxidant activity, immunomodulatory action and geno-protective effects (Rastogi et al., 2010) by regulating the mitochondrial pathway (Ullah et al., 2012). In support, Sener et al. (2016) illustrated the protective role of TQ against apoptosis and oxidative stress induced by arsenic in rat kidney. TQ's supplementation increases the expression of antioxidant genes of SOD, GPX, CAT, and GST in rat liver (Ismail et al., 2010). These results agree with other studies as protection and treatment with TQ in lung cancer in mice attenuated the increase in Cox-2, caspase 3 and DNA fragmentation in lung tissues when compared with the non-treated group (Samy et al., 2014). These findings highlight the potential usefulness of TQ as a potent antioxidant in DM-induced subchronic genotoxicity in rats but, further research

should be undertaken to investigate these effects with different doses.

Acknowledgments: Authors thank biochemistry, physiology, internal medicine and pathology departments, faculty of veterinary medicine, Kafrelsheikh University, Egypt, for their kind help in this research.

Conflict of interest: The authors declare that they have no conflict of interests.

References

- Abdelhady, D., El-Abasy, M., Abou-Asa, S., Elbially, Z., Shukry, M., Hussein, A., Saleh, A., El-Magd, M., 2017. The ameliorative effect of *Aspergillus awamori* on aflatoxin B1-induced hepatic damage in rabbits. *World Mycotoxin Journal* 10, 363-373.
- Abdelhady, D.H., El-Magd, M.A., Elbially, Z.I., Saleh, A.A., 2017. Bromuconazole-induced hepatotoxicity is accompanied by upregulation of PXR/CYP3A1 and downregulation of CAR/CYP2B1 gene expression. *Toxicol Mech Methods* 27, 544-550.
- Abu El-Saad AM, Elgerbed MS. Dimethoate-induced hepatotoxicity in rats and the protective roles of vitamin E and N-Acetylcysteine. *Egypt. J. Exp. Biol. (Zool.)* 2010; 6: 219 – 230.
- Abu Khudir, R., El-Magd, M.A., Salama, A.F., Tousson, E.M., El-Dsoki, S.M., 2019. Curcumin Attenuated Oxidative Stress and Inflammation on Hepatitis Induced by Fluvastatin in Female Albino Rats. *Alexandria Journal of Veterinary Sciences* 62, 102-115.
- Aebi H. *Methods Enzymol.* 1984; 105: 121-126.
- Alavanja MC. Introduction: pesticides use and exposure extensive worldwide. *Rev Environ Health* 2009; 24: 303-309.
- Ashok A, Sajal G, Rakesh KS. Role of oxidative stress in female reproduction. *Reproductive Biology and Endocrinology* 2005; 3:28.
- Astiz M, de Alaniz MJ, Marra CA. Effect of pesticides on cell survival in liver and brain rat tissues. *Ecotoxicol Environ Saf* 2009; 72: 2025-2032.
- Ayed-Boussema I, Rjiba K, Mnasri N, Moussa A, Bacha H. Genotoxicity Evaluation of Dimethoate to Experimental Mice by Micronucleus, Chromosome Aberration Tests, and Comet Assay. *International Journal of Toxicology* 2012; 31: 78-85.
- Aymen Mabrouk, Imen Bel Hadj S, Wafa C, Hassen BC. Protective effect of thymoquinone against lead-induced hepatic toxicity in rats. *Environ Sci Pollut Res* 2016; 23: 12206-12215.
- Badawy, A.A., El-Magd, M.A., AlSadrah, S.A., 2018. Therapeutic Effect of Camel Milk and Its Exosomes on MCF7 Cells In Vitro and In Vivo. *Integrative Cancer Therapies* 7, 1235-1246.
- Bancroft JD, Stevens A. *Theory and Practice of Histological Techniques*, 4th ed. Churchill: Livingstone, New York, 1996.
- Barski D, Zasadowski A. Residues of DM in the liver and AChE activity in blood of rats after exposure to DM, and DM and pyrantel embonate. *Pol J Vet Sci* 2006; 9: 43-49.
- Baselt R. *Disposition of Toxic Drugs and Chemicals in Man*, 8th ed. Biomedical Publications, Foster City, CA, 2008.
- Ben Amara I, Karray A , Hakim A , Ben Ali Y, Troudi A , Soudani N , Boudawara T , Zeghal KM , Zeghal N. Dimethoate Induces Kidney Dysfunction, Disrupts Membrane-Bound ATPases and Confers Cytotoxicity through DNA Damage. Protective Effects of Vitamin E and Selenium. *Biol Trace Elem Res* 2013; 156: 230-242.
- Ben Amara I, Soudani N, Troudi A, Hakim A, Zeghal Km, Boudawara T, Zeghal N. Dimethoate induced oxidative damage and histopathological changes in lung of adult rats: Modulatory Effects of Selenium and/or Vitamin E. *Biomed Environ Sci* 2012; 25: 340-351.
- Creasy DM. Pathogenesis of male reproductive toxicity. *Toxicol Pathol* 2001; 29: 64-76.
- Demple B, Harrison L. Repair of oxidative damage to DNA: enzymology and biology. *Annu Rev Biochem* 1994; 63: 915-948.
- El-Magd, M.A., Kahilo, K.A., Nasr, N.E., Kamal, T., Shukry, M., Saleh, A.A., 2016. A potential mechanism associated with lead-induced testicular toxicity in rats. *Andrologia* 49, e12750.
- El-Magd, M.A., Khalifa, S.F., A. Alzahrani, F.A., Badawy, A.A., El-Shetry, E.S., Dawood, L.M., Alruwaili, M.M., Alrawaili, H.A., Risha, E.F., El-Taweel, F.M., Marei, H.E., 2018. Incensole acetate prevents beta-amyloid-induced neurotoxicity in human olfactory bulb neural stem cells. *Biomedicine & Pharmacotherapy* 105, 813-823.
- El-Magd, M.A., Mohamed, Y., El-Shetry, E.S., Elsayed, S.A., Abo Gazia, M., Abdel-Aleem, G.A., Shafik, N.M., Abdo, W.S., El-Desouki, N.I., Basyony, M.A., 2019. Melatonin maximizes the therapeutic potential of non-preconditioned MSCs in a DEN-induced rat model of HCC. *Biomedicine & Pharmacotherapy* 114, 108732.
- El-Najjar N, Chatila M, Moukadem H, Vuorela H, Ocker M, Gandesiri M, Schneider-Stock R, Gali-Muhtasib H. Reactive oxygen species mediate thymoquinone-induced apoptosis and activate ERK and JNK signaling. *Apoptosis* 2010; 15: 183-195.
- Frost AR, Sparks D, Grizzle WE. Methods of antigen recovery vary in their usefulness in unmasking specific antigens in immunohistochemistry. *Appl. Immunohistochem Mol Morphol* 2000; 8: 236-243.
- Güney M, Demirin H, Oral B, Özgüner M, Bayhang, Altuntas I. Ovarian toxicity in rats caused by methidathion and ameliorating effect of vitamins E and C. *Hum Exp Toxicol* 2007; 26: 491- 498.
- Güney M, Oral B, Demirin H, Özgüner M, Take G, Mungan T, Altuntas I. Evaluation of caspase-dependent apoptosis during methyl parathion-induced endometrial damage in rats: Ameliorating effect of Vitamins E and C. *Environ Toxicol Pharmacol* 2007; 23: 221-227.
- Hoffmann U, Papendorf T. Organophosphate poisonings with parathion and DM. *Intensive Care Med* 2006; 32: 464-468.
- Işık I, Celik I. Acute effects of methyl parathion and diazinon as inducers for oxidative stress on certain biomarkers in various tissues of rainbow trout (*Oncorhynchus mykiss*). *Pestic. Biochem. Phys* 2008; 92: 38-42.
- Ismail M, Al-Naqeeq G, Chan KW. Nigella sativa thymoquinone rich fraction greatly improves plasma antioxidant capacity and expression of antioxidant genes in hypercholesterolemic rats. *Free Radic Biol Med* 2010; 48: 664-672.
- Kamath V, Joshi AKR, Rajini PS. DM induced biochemical perturbations in rat pancreas and its attenuation by cashew nut skin extract. *Pestic Biochem Phys* 2008; 90: 58-62.
- Kamath V, Rajini PS. Altered glucose homeostasis and oxidative impairment in pancreas of rats subjected to dimethoate intoxication. *Toxicology* 2007; 231: 137-146.
- Krishnaswamy K, Sushil KJ. Oxidative stress and apoptosis. *Pathophysiology* 2000; 7: 153-163.
- Krishnendu S, Joydeep D, Pabitra BP, Parames CS. Oxidative stress: the mitochondria-dependent and mitochondria-independent pathways of apoptosis. *Arch Toxicol* 2013; 87: 1157-1180.
- Kundu J, Kim D-H, Kundu JK, Chun K-S. Thymoquinone induces heme oxygenase-1 expression in HaCaT cells via Nrf2/ARE activation: Akt and AMPK α as upstream targets. *Food Chem Toxicol* 2014; 65: 18-26.
- Magdy, A., Sadaka, E., Hanafy, N., El-Magd, M.A., Allahloubi, N., El Kemary, M., 2020. Green tea ameliorates the side effects of the silver nanoparticles treatment of Ehrlich ascites tumor in mice. *Molecular & Cellular Toxicology* 16, 271-282.
- Mahjoubi-Samet A, Fetoui H, Zeghal N. Nephrotoxicity induced by DM in adult rats and their suckling pups. *Pestic Biochem Physiol* 2008; 91: 96-103.
- Masoud L, Vijayarathay C, Fernandez-Cabezudo M, Petroianu G, Saleh AM. Effect of malathion on apoptosis of murine L929 fibroblasts: a possible mechanism for toxicity in low dose exposure. *Toxicology* 2003; 185: 89-102.
- Modesto KA, Martinez CB. Effects of roundup transorb on fish: hematology, antioxidant defenses and acetylcholinesterase activity. *Chemosphere* 2010; 81: 781- 787.

- Mokhbatly, A.A., Aburawash, A., Ghazi, E., Goda, W., Elbially, Z.I., Abou-Asa, S.S., El-Maghd, M.A., Elesh, I., Abdelhady, D.H., 2019. A potential molecular mechanism and biochemical alterations associated with bromoconazole-induced testicular toxicity in rats. *Arabian journal of medical sciences* 2, 20-24.
- Nishikimi M, Roa NA, Yogi K. *Biochem.Bioph.Res.Common* 1972; 46: 849-854.
- Ogutcu A, Uzunhisarcikli M, Kalender S, Durak D, Bayrakdar F, et al. The effect of organophosphate insecticide diazinon on malondialdehyde levels and myocardial cells in rat heart tissue and protective role of Vitamin E. *Pest Biochem Physiol* 2006; 86: 93-98.
- Ohkawa H, Ohishi W, Yagi K. *Anal.Biochem* 1979; 95: 351-358.
- Oral B, Guney M, Demirin H, Ozguner M, Giray Sg, Take G, Mungan T, Altuntas I. Endometrial damage and apoptosis in rats induced by dichlorvos and ameliorating effect of antioxidant vitamins E and C. *Reprod Toxicol* 2006; 22: 783-790.
- Possamai FP, Fortunato JJ, Agostinho J, Quevedo D, Wilhelm FF, Dal-Pizzol F. Oxidative stress after acute and subchronic malathion intoxication in Wistar rats. *Environ Toxicol Pharmacol* 2007; 23: 198-204.
- Prashant RG, Chaitali PP, Umesh BM, Sameer NG, Sateesh B, Shreesh O, Chandragouda RP. Protective Effect of Thymoquinone against Cyclophosphamide-Induced Hemorrhagic Cystitis through Inhibiting DNA Damage and Upregulation of Nrf2 Expression. *Int. J. Biol. Sci* 2016; 12: 944-953.
- Ranjbar A, Pasalar P, Abdollahi M. Induction of oxidative stress and acetylcholinesterase inhibition in organophosphorous pesticide manufacturing workers. *Hum Exp Toxicol* 2002; 21: 179-182.
- Rastogi L, Feroz S, Pandey BN, Jagtap A, Mishra KP. Protection against radiation-induced oxidative damage by an ethanolic extracts of *Nigella sativa* L. *NT J Radiat Biol* 2010; 86: 719-731.
- Razavi BM, Hosseinzadeh H, Movassaghi AR, Imenshahidi M, Abnous K. Protective effect of crocin on diazinon induced cardiotoxicity in rats in subchronic exposure. *Chem Biol Interact* 2013; 203: 547-555.
- Saafi EB, Louedi M, Elfeki A, et al. Protective effect of date palm fruit extract (*Phoenix dactylifera* L.) on DM induced oxidative stress in rat liver. *Exp Toxicol Pathol* 2010; 63: 433-441.
- Sajadimajd S, Khazaei M. Oxidative Stress and Cancer: The Role of Nrf2. *Current Cancer Drug Targets* 2017; 17.
- Samy AH, Abdel-Aal SA, Heba AK. Chemopreventive effect of thymoquinone on benzo(a)pyrene-induced lung cancer in male swiss albino mice. *Benha veterinary medical journal* 2014; 27:330-340.
- SAS. (2012). Institute Inc., Cary, NC, v9.3, USA.
- Sener U, Uygur R, Aktas C, Uygur E, Erbogga M, Balkas G, Caglar V, Kumral B, Gurel A, Erdogan H. Protective effects of thymoquinone against apoptosis and oxidative stress by arsenic in rat kidney. *Ren Fail* 2016; 38: 117-123.
- Serbecic N, Beutelspacher SC. Anti-oxidative vitamins prevent lipid-peroxidation and apoptosis in corneal endothelial cells. *Cell Tissue Res* 2005; 320: 465-475.
- Sharma Y, Bashir S, Irshad M, Gupta SD, Dogra TD. Effects of acute DM administration on antioxidant status of liver and brain of experimental rats. *Toxicology* 2005a; 206: 49-57.
- Sheriffs IN, Rampling D, Smith VV. Paraffin embedded muscle is suitable for the diagnosis of muscular dystrophy. *J.clin.pathol* 2001; 54: 17-20.
- Singh NP, McCoy MT, Tice RR, Schneider EL. A simple technique for quantitation of low levels of DNA damage in individual cells. *Exp Cell Res* 1988; 175(1):184-191.
- Tice RR, Agurell E, Anderson D, Burlinson B, Hartmann A, Kobayashi H, Miyamae Y, Rojas E, Ryu JC, Sasaki YF. Single cell gel/comet assay: guidelines for in vitro and in vivo genetic toxicology testing. *Environ Mol Mutagen* 2000; 35: 206-221.
- Ullah I, Ullah N, Naseer MI, Lee HY, Kim MO. Neuroprotection with metformin and TQ against ethanol-induced apoptotic neurodegeneration in prenatal rat cortical neurons. *BMC Neuroscience* 2012; 13:11.
- Vijayaraghavan M, Nagarajan B. Mutagenic potential of acute exposure to organophosphorus and organochlorine compounds. *Mutat. Res* 1994; 321: 103-111.
- WHO/IPCS. Classification of pesticides by hazard and guidelines to classification. Switzerland: Geneva, 2001.
- Wild D. Mutagenicity studies on organophosphorus insecticides. *Mutat. Res* 1975; 32: 133-150.
- Zhou F, Wu JY, Sun XL, Yao HH, Ding JH, Hu G. Iptakalim alleviates rotenone-induced degeneration of dopaminergic neurons through inhibiting microglia-mediated neuroinflammation. *Euro psycho pharmacol* 2007; 32: 2570-80.
- Saleh AA, Zaki A, El- Awady A, Amber Kh, Badwi N, Eid and Y, Ebeid T (2020): Effect of substituting wheat bran with cumin seed meal on laying performance, egg quality characteristics and fatty acid profile in laying hens. *Veterinarski Arhiv* 90 (1),: 47-56.
- Slominski BA, Gdala J, Boros D, Campbell LD, Guenter W and Jones O (2000): Variability in chemical and nutritive composition of Canadian wheat and the potential for its minimization by enzyme use. In *Proceedings of the XXI World Poultry Congress*, Montreal, QC, Canada, 20–24 August.