

## Ultrasound Imaging of Tympanic Bulla and The Surrounding Structures in Donkey (*Equus asinus*)

Ahmed Sharsher<sup>1</sup>; Safwat Ali<sup>2</sup>; Reda Rashed<sup>3\*</sup>; Bahaa Eldeen Abedellaah<sup>4</sup>

1. Department of Veterinary Surgery, Anesthesiology and Radiology, Faculty of Veterinary Medicine, University of Sadat City, Egypt.

2. Department of Anatomy and Embryology, Faculty of Veterinary Medicine, Minia University, Egypt

3. Department of Anatomy, Faculty of Veterinary Medicine, University of Sadat City, Egypt.

4. Department of Veterinary Surgery, Anesthesiology and Radiology, Faculty of Veterinary Medicine, Sohag University. 82524 Sohag, Egypt.

\*Corresponding author: [reda.rashed@vet.usc.edu.eg](mailto:reda.rashed@vet.usc.edu.eg) Received: 7/7/2020 Accepted: 15/8/2020

### ABSTRACT

This study was carried out to describe the normal ultrasonographic appearance of the tympanic bullae and its surrounding structures in donkey. The present study was conducted on 10 clinically healthy and mature Egyptian donkeys of both sexes. For the bullae, brief anatomic reminders are first performed. Then, the scanning techniques and normal images are described. Ultrasonographic study of the retromandibular area showed a lot of landmarks which were detected in different positions. For bullae, the lateral approach using micro convex transducer at 6.6 MHz was used. Such approach gives adequate acoustic window for examination. The micro convex transducer at 6.6 MHz proved to be the most suitable tool for complete evaluation of TB and the surrounding structures in donkeys.

**Keywords:** *Donkey, tympanic bulla, ultrasonography*

### INTRODUCTION

Since about 6000 years ago, the African villagers, and because of aridity in the Sahara, domesticated the wild ass (Beja-Pereira *et al*, 2004; Denham *et al*, 2007; Rossel *et al*, 2008). Pronunciation donkey replaced ass firstly in 1784 (Fairman, 1994). In 2006, donkeys estimated by about 41 million in the world (Waltraud -Kugler and Broxham *et al*, 2008) and in Egypt, they counted about nine million at 1949 diminished to 1.7 million at 1996. About, 95% from donkeys are used for work (Starkey and Starkey, 2009).

The auditory system receives sounds and auditory perception and plays an important role in equilibrium (Mason, 2006). The middle ear is

that part of the auditory system that lies in an air-filled space in the temporal bone called the tympanic cavity (Dyce *et al*, 2002). The ossicles of the middle ear in addition to the tympanic membrane play a fundamental role in hearing through transmitting the sound waves to the cochlea in the inner ear (Merchant and Rosowski, 2010). The middle ear connected directly with the pharynx via the auditory tube. In equines, such tube has ventro-lateral dilatation called the guttural pouches that extend bilaterally from the pharynx to the atlanto-occipital articulation (Nickle *et al*, 1973; Sasaki *et al*, 1999; Manglai *et al*, 2000; Dyce *et al*, 2002; König and Liebich; 2014).

Infections of the tympanic bulla are not different in domestic animals but instead can be going

after for veterinary experts in the field. With the board advancement of compact ultrasonography units and their accessibility in the field, ultrasonography of these anatomic structures gives new demonstrative devices to the veterinary professional in an emergency clinic setting just as in field conditions (Gosselin *et al*, 2016). Tympanic bullae were assessed sonographically in dog (Dickie *et al*, 2003<sup>a</sup>), rabbit (King *et al*. 2007<sup>a</sup>), cat (King *et al*. 2007<sup>b</sup>), calves (Gosselin *et al*, 2012, 2016). The aim of this study was to describe the normal ultrasonographic appearance of some components in the middle ear of donkey as well as, to determine the anatomic landmarks for correct probe positioning to obtain the correct images for this area.

## MATERIALS AND METHODS

The present study was conducted on 10 clinically healthy mature Egyptian donkeys of both sexes. The mean age of the animals was 10 years (range from 6-14 years) and mean body weight was 180 kg (range, 160 to 240 kg). The animals had no previous history of ear affections. The animals were divided into two groups. Group I (contain 3 donkeys) and group II (contain 7 donkeys).

**Group I:** The animals were euthanized and used for identification of anatomic landmarks of the tympanic bulla and its surrounding structures. The area at the base of the ear was dissected and the anatomical structures including the tympanic bulla, the mastoid process, the styloid cartilage, the annular cartilage, and the mandibular ramus were identified and photographed. The dissected structures were used as guide for the following ultrasonographic examination.

**Group II:** The animals were used for ultrasonographic evaluation of the tympanic bulla and its surrounding structures. Ultrasonographic examinations were performed using ultrasound unit ESAOTE MYLAB ONE-507, Italy equipped with 6.6 to 10 MHz micro-convex probe. The examination was performed on the same bases as described in calves by **Gosselin et al (2012)**. The animals were controlled in a standing position and the area at the base of the ear was clipped following by application of ultrasonographic gel. Evaluation

of the tympanic bulla and its surrounding structures were performed by placing the probe in three positions.

**In position 1;** the probe was placed vertically at the base of the ear just above the proximal end of the vertical ramus of the mandible on a line extending upward from the caudal rim of the mandible to the base of the ear. The beam was oriented perpendicular to the skin in a dorso-ventral direction and directed slightly rostral. In such position tympanic bulla (TB), the styloid process of the auricular cartilage (STP-A) and the mastoid process (MP) were imaged and evaluated. The thickness, length, and depth of TB from skin surface were measured as well as, the distance between TB and both STP-A and MP and the depth of MP from skin surface were measured and recorded also (Fig. 1A)

**In position 2;** the probe was placed vertically blow the base of the ear just above the proximal end of the vertical ramus of the mandible and cranial to position 1 by 3-5 cm. the beam was oriented perpendicular to the skin in a dorso-ventral direction and directed slightly caudal. in such position TB, Styloid process of the Petrus part of temporal bone (STP-P) and the annular cartilage (AC) were imaged and evaluated (Fig. 2A).

**In position 3;** the probe was places in a horizontal plane at the base of the ear just above the proximal end of the vertical ramus of the mandible and was moved up and down. The beam was oriented perpendicular to the skin in a rostro-caudal direction. In such position, TB, MP, STP-A and mandibular ramus (MR) were imaged and evaluated (Fig. 3A)

### **Statistical analyses:**

The differences in values between the right sides of all examined animal and left sides of all examined animals were reported and analyzed using a nonpaired *t* test. The differences in values between the right and left side of were also analyzed using paired *t* test. For all tests, significance was set at  $P < 0.05$  (Table 1).

### **Results**

The external ear of donkey consists of the auricular cartilage with voluminous auricular muscles, scutulum and annular

cartilage that connect the ear Penna to the external aquastic meatus. ultrasonographic study of the retromandibular area showed a lot of landmarks which were detected in different positions: -

### **Position (1)**

Grossly: The mastoid process, the tympanic bulla and the styloid process of the auricular cartilage were easily detected.

Ultrasonographically; the tympanic bulla (TB) appears as echogenic curvilinear structure directed dorsoventrally with slightly hyperechoic rim. It pounded dorsally by the styloid process of auricular cartilage (STP-A) and ventrally by mastoid process (MP). The STP-A appeared as slightly hyper echoic linear structure directed lateromedially with an angle to the vertical axis. The mastoid process appears as an oblique echogenic linear structure directed ventro-laterally with an angle to the vertical axis (Fig. 1B).

### **Position (2)**

Grossly; Styloid process of the Petrus part of temporal bone, tympanic bulla trabeculations and the annular cartilage were clear.

### **Statistical analyses:**

**Table (1) :** The mean and standard error (SE) of the recorded measurements

Criteria	Right $\pm$ SE	Left $\pm$ SE
Thickness of TB (mm)	1.151 $\pm$ 0.1136	1.247 $\pm$ 0.1041
Length of TB (cm)	1.726 $\pm$ 0.1377	1.576 $\pm$ 0.1188
Distance between TB and MP (cm)	1.157 $\pm$ 0.1109	1.223 $\pm$ 0.101
Distance between TB and STP-A (cm)	0.7643 $\pm$ 0.1245	0.8371 $\pm$ 0.1029
Distance between skin and TB (cm)	0.9 $\pm$ 0.06195	0.9857 $\pm$ 0.0892
Distance between skin and MP (cm)	0.8714 $\pm$ 0.08554	0.9029 $\pm$ 0.07373

*There is no significance difference between the right and the left sides. Note. TB, tympanic bulla. MP, mastoid process. STP-A, styloid process of the auricular cartilage*

Ultrasonographically; the tympanic bulla (TB) appears as an S-shape hyperechoic structure directed dorso-medially to the vertical axis with trabeculations which appears as an echogenic mass located ventral to its dorsal end. The styloid cartilage of petrous bone (STP-P) located at the ventral end of the tympanic bulla which appears as slightly echogenic linear structure. The auricular cartilage (AC) appears as hyperechoic linear structure directed lateromedially with an angle to the dorsal axis (Fig.2B).

### **Position (3)**

Grossly; The mastoid process, the tympanic bulla, the styloid process of the auricular cartilage mandibular ramus was seen.

Ultrasonographically; the tympanic bulla (TB) appears as hyperechoic curved structure pounded caudally by the mastoid process (MP) which appears as hyperechoic linear structure and pounded rostrally by styloid process of the auricular cartilage (STP-A) which appears as echogenic circular structure with hypoechoic center. The styloid process of the auricular cartilage (STP-A) pounded rostrally by the mandibular ramus (MR) which appears as hyperechoic linear structure directed dorsoventrally with an angle to the longitudinal axis (Fig. 3B).

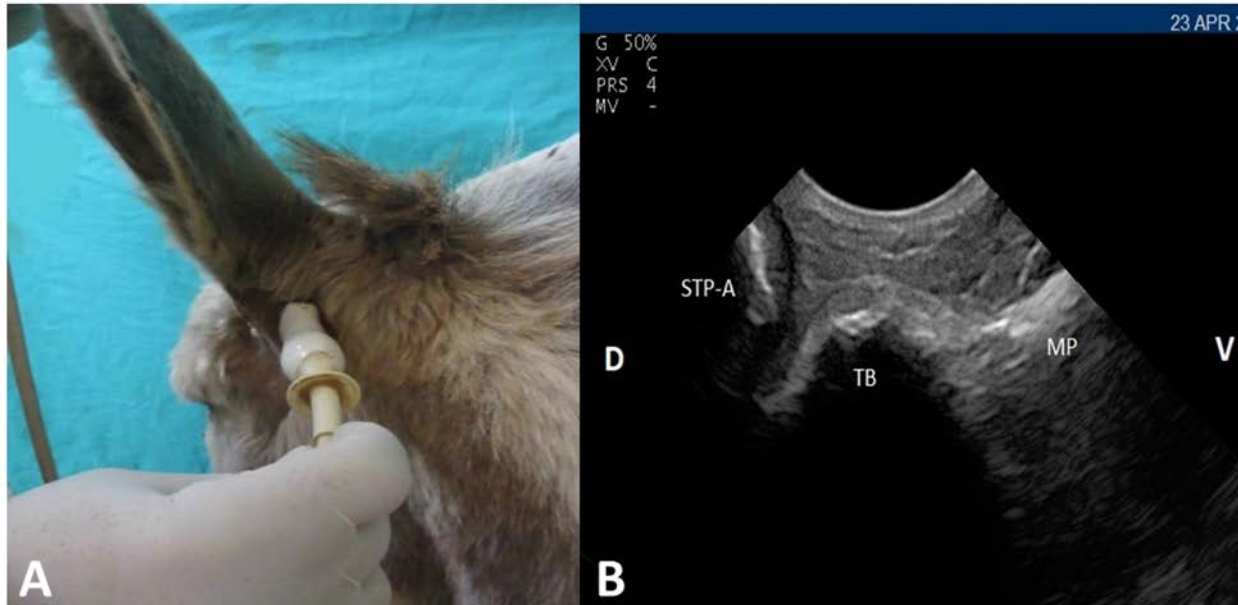


Fig. (1)

A; showing proper prob placement in position 1 for examination of tympanic bulla and its surrounding structures. Note: the probe is placed vertically at the base of the ear just above the proximal end of the vertical ramus of the mandible on a line extending upward from the caudal rim of the mandible to the base of the ear

B; showing normal ultrasonographic appearance of the tympanic bulla (TB) in position 1 and its surrounding structures including the styloid process of the auricular cartilage (STP-A) and the mastoid process (MP). D, dorsal and V, ventral

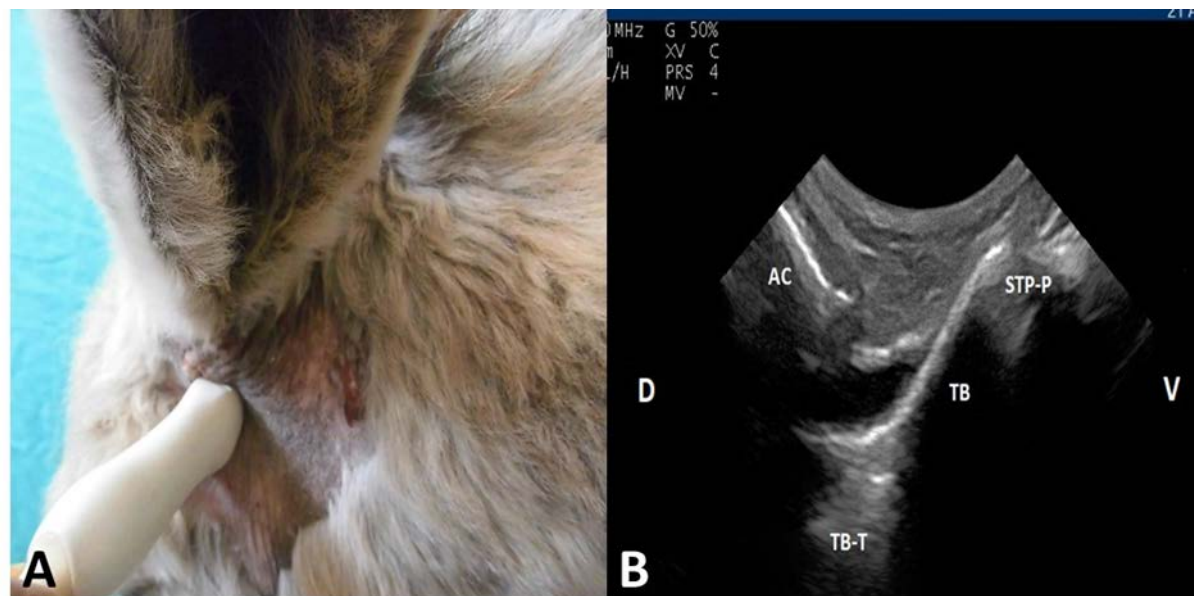


Fig. (2)

A; showing proper prob placement in position 2 for examination of tympanic bulla and its surrounding structures. Note: the probe is placed vertically below the base of the ear just above the proximal end of the vertical ramus of the mandible and cranial to position 1 by 3-5 cm

B; showing normal ultrasonographic appearance of the tympanic bulla (TB) in position 2 and its surrounding structures including tympanic bulla trabeculation (TB-T), Styloid process of the Petrus part of temporal bone (STP-P) and the annular cartilage (AC). D, dorsal and V, ventral

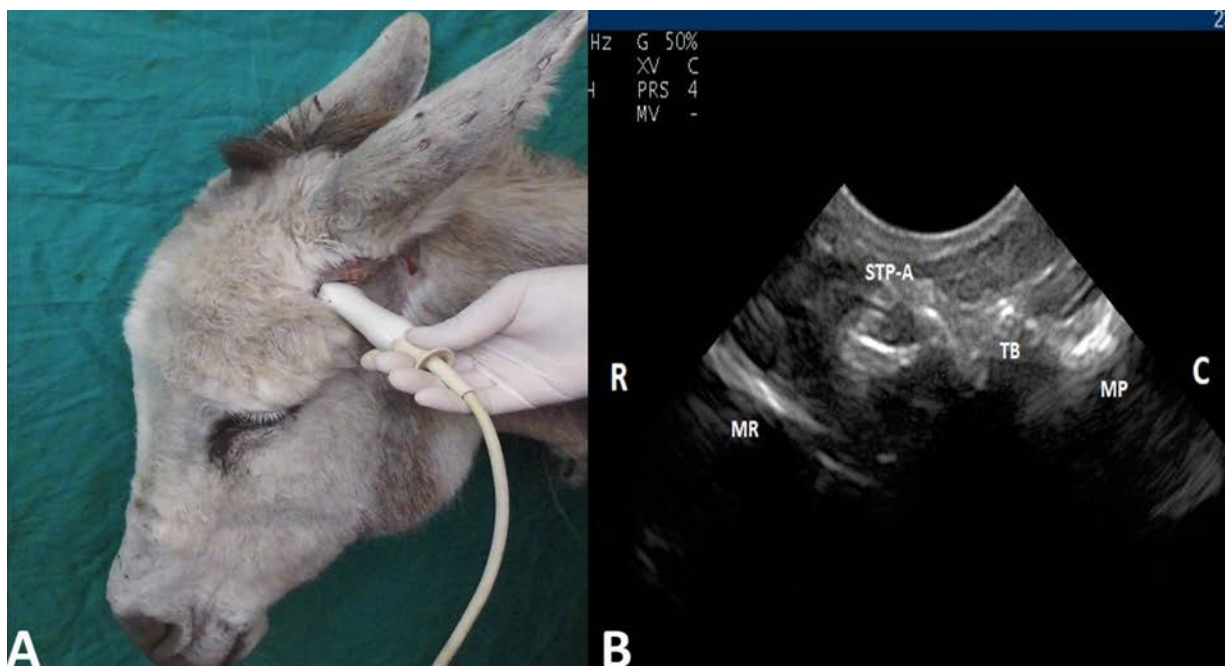


Fig. (3)

A; showing proper prob placement in position 3 for examination of tympanic bulla and its surrounding structures. Note: the probe is placed horizontally at the base of the ear just above the proximal end of the vertical ramus of the mandible  
 B; showing normal ultrasonographic appearance of the tympanic bulla (TB) in position 2 and its surrounding structures including mastoid process (MP), styloid process of the auricular cartilage (STP-A) and mandibular ramus (MR)

## DISCUSSION

Middle ear affection is common in all domestic animals (Gosselin *et al*, 2016). Evaluation of middle ear has been accomplished in different animal species (Dickie *et al*, 2003<sup>a</sup>; King *et al*. 2007a, King *et al*. 2007b, Gosslin *et al*, 2012, 2016). To our knowledge, this may be the first report dealing with ultrasonographic description and evaluation of tympanic bulla and its surrounding structures in donkeys.

Ultrasonography is more sensitive and specific than radiography in detecting fluid in the TB in the absence of bone remodeling in cadaver specimens of cats (King *et al*. 2007<sup>b</sup>). in cadavers and live calves Ultrasonography permits the visualization of the TB and adjacent structures (Gosslin *et al*, 2012).

Ventral and/or lateral approach has been described for tympanic bulla examination in dog cat and rabbit (Dickie *et al*, 2003<sup>a</sup>; King *et al*. 2007<sup>a&b</sup>). however, only the lateral approach was useful in calves (Gosslin *et al* ,2012). In the present study

the lateral approach is the only suitable one that provided an adequate acoustic window for examination of TB sonographically in donkeys, while the ventral one was hampered by the Guttural pouch.

Convex transducer with frequency 6.5 MHz was proofed to be the optimum one for examination of TB in dog (Dickie *et al*, 2003<sup>b</sup>), while in calf, Gosselin *et al.*, (2012) appropriate the use of 10 MHz linear transducer for evaluation of the intended parts of TB. According to this study, micro-convex transducer at 6.6 MHz provided adequate and complete evaluation of TB and the surrounding structures in donkey.

For complete evaluation of the bulla and its surrounding structures, it should be combined between the three examination positions. Position 1 allow better visualization of the TB, MP, and STP-A. It also permits evaluation of TB length, thickness, and depth. While position 2 permits better visualization of AC, STP-P and TB and its inside trabeculations. Position 3 permits visualization and evaluation of TB, MP, STP-A. In position 1, and 3 TB in donkey showed the same ultrasonographic appearance

as previously described in calves (Gosselin et al 2012) while greatly differs than dog and cat (Dickie *et al*, 2003<sup>a</sup>; King et al. 2007<sup>b</sup>). In position 2 the TB of donkey appeared as an S-shape hyperechoic structure with trabeculations which appears as an echogenic mass located ventral to its dorsal end. Our results in that respect greatly differ than that previously described in calves (Gosselin et al 2012). In position 3, particularly for the live calves of various ages, the structure first visible and permitting the identification of the bulla was the stylohyoid cartilage, which visible in the transverse view as a hypoechoic round structure (Gosselin et al 2012). In this study, the tympanic bulla was identified by localizing the styloid process of the auricular cartilage (STP-A) which appears as echogenic circular structure with hypoechoic center.

The thickness of the bulla wall as well as, probe position and beam orientation are important factor influencing the ability of the beam to penetrate the osseous surface with subsequent evaluation. In the rabbit, the thickness of the lateral surface of the TB compared to the ventral surface prevents an adequate image from the lateral approach (king et al., 2007<sup>a</sup>). In this study complete and efficient evaluation of TB trabeculation was accomplished in position 2 with beam oriented vertically while slightly directed caudally.

In conclusion, TB of donkey has the same ultrasonographic appearance as calves in position 1 and 3 while greatly differ in position 2. The obtained results may be used as a reference guide for future studies dealing with evaluation TB and its surrounding structures in equine species.

## REFERENCES

- Beja-Pereira, A., England, P.E., Ferrand, N., Jordan, S., Bakhiet, A.O., Abdalla, M.A., Mashkour, M., Jordana, J., Taberlet, P., Luikart, G. (2004): The African origins of the domestic donkey *Science*; 304:1781.
- Denham, T.P., Iriarte, J., Vrydaghs, L., Marshall, F. (2007): In *Rethinking Agriculture: Archaeological and Ethnoarchaeological Perspectives*, eds
- Dickie, A.M., Doust, R., Cromarty, L., Johnson, V.S., Sullivan, M., Boyd, J.S. (2003<sup>a</sup>): Ultrasound imaging of the canine tympanic bulla. *Res Vet Sci*; 75: 121-126.
- Dickie, A.M., Doust, R., Cromarty, L., Johnson, V.S., Sullivan, M., Boyd, J.S. (2003<sup>b</sup>): Comparison of ultrasonography, radiography and a single computed tomography slice for the identification of fluid within the canine tympanic bulla. *Res Vet Sci*;75:209–216.
- Dyce, K.M., Sack, W.O., Wensing, C.J.G. (2002): *Textbook of Veterinary Anatomy*, 3rd ed., Chapter 18, the Head and Ventral Neck of the Horse. Saunders-Elsevier Science, Philadelphia: 496-501.
- Fairman, T. (1994). "How the ass became a donkey". *English Today*; 10 (4): 32.
- Gosselin, B., Babkine, M., Nichols, S., Desrochers, A. (2012): Ultrasound evaluation of tympanic bulla in calves. *Can Vet J*; 53:849–854.
- Gosselin, B., Babkine, M., francoz, D. (2016): Ultrasonography of the tympanic bulla and larynx in cattle. *Vet Clin Food Anim* 32: 119–131
- King, A.M., Hall, J., Cranfield, F., Sullivan, M. (2007<sup>a</sup>): Anatomy and ultrasonographic appearance of the tympanic bulla and associated structures in the rabbit. *Vet J* 2007; 173:512-521.
- King, A.M., Weinrauch, S.A., Doust, R., Hammond, G., Yam, P.S., Sullivan, M. (2007<sup>b</sup>): Comparison of ultrasonography, radiography and a single computed tomography slice for fluid identification within the feline tympanic bulla. *Vet J*;173:638-644.
- König, H. and Liebich, H. (2014) *Veterinary Anatomy Domestic Mammals: Textbook and Color Atlas*, Sixth Edition.
- Manglai, D., Wada, R., Endo, H., Kurohmaru, M., Yoshihara, T., Sasaki, M., Oikawa, M., Hayashi, Y. (2000): Macroscopic anatomy of the auditory tube diverticulum (guttural pouch) in the thoroughbred equine – a slicon mold approach. *Okajimas Folia Anat Jpn*, 76, 335-346.
- Mason, M.J. (2006): Evolution of the middle ear apparatus in Talpid moles. *J Morphol*; 267: 678-695.

- Nickle, R., Schummer, A., Seiferle, E. (1973):  
The viscera of the domestic mammals  
(Translation and version by W.O. Sack).  
Berlin: Verlag, Paul Parey 15.09.2009.
- Rossel, S., Marshall, F., Peters, J., Pilgram, T.,  
Adams, M., O'Conno, D. (2008):  
"Domestication of the donkey: Timing,  
processes, and indicators." PNAS  
105(10):3715-3720.
- Sasaki, M., Hayashi, Y., Koie, H., Yamaya, Y.,  
Kimura, J., Manglai, D., Kawashima, S.,  
Endo, H., Yamamoto, M. (1999): CT  
examination of the guttural pouch (auditory  
tube diverticulum) in Przewalski's horse  
(*equus przewalskii*). J Vet Med Sci;  
61:1019-1022.
- Starkey, P., Starkey, M. (2009): Regional and  
world trends in donkey populations. In:  
Starkey, P., Fielding, D., editors. Donkeys,  
People and Development. A Resource Book  
of the Animal Traction Network for Eastern  
and Southern Africa. Wageningen, The  
Netherlands: ACP-EU Technical Centre for  
Agricultural and Rural Cooperation (CTA):  
10–21.
- Waltraud-Kugler, H.P.G., Broxham, E. (2008):  
Donkey Breeds in Europe: Inventory,  
Description, Need for Action, Conservation  
Report 2007/2008. Monitoring Institute.