

EVALUATION OF THE USE OF BONE-BORNE CAD/CAM SURGICAL GUIDES IN ORTHOGNATHIC SURGERY CASES REQUIRING LE FORT I OSTEOTOMY

Haitham M. Abou Eleneen ^{1*} MSc, Ahmed R. Kotb ² PhD, Tarek M. Aly ² PhD, Ossama A. Sweedan ² PhD, Carlos V. Bateman ³ DDS

ABSTRACT

BACKGROUND: Dentofacial deformities have many negative consequences in the form and function of head and neck region. This includes breathing, swallowing, speech and temporomandibular disorders. It is estimated that in about 19% of orthodontic patients, orthognathic surgery is required along with the orthodontic procedure. The introduction of Computer-aided design/ Computer-aided manufacture (CAD/CAM) technology in orthognathic surgery planning has facilitated the procedure and allowed for more predicted results.

AIM OF THE STUDY: The aim of the present study was to propose a new design of the intermediate stent that relates the mobilized maxilla to a fixed anatomical landmark in the skull which would allow for more accurate positioning of the maxilla during orthognathic surgery.

MATERIALS AND METHODS: This study was conducted on sixteen patients who required Le Fort I osteotomy procedure. Eight of them (group A) were treated via a conventional stent while the other eight patients (group B) via a CAD/CAM bone-borne stent. Postoperative patient evaluation was performed by comparing the predicted maxillary position to the resultant position postoperatively. This was done via 3D reconstruction Computerized Tomography (CT) scans.

RESULTS: Sixteen patients were recruited for the study (n=16), 5 males and 11 females, and were randomly allocated into two groups. Age ranged from 16 to 42 years with a mean of 24.31 ± 7.49 . No statistically significant difference was found in the operation time using Independent samples t-test ($p < 0.05$). Pain evaluated by Visual Analogue Scale (VAS) was also found statistically insignificant between both groups using Independent samples t-test and Mann-Whitney U test ($p < 0.05$). Error of superimposition was found to be statistically significant between control group (0.317 ± 0.22) and study group (0.870 ± 0.23) using independent samples t-test ($p < 0.05$).

CONCLUSION: The new intermediate splint design needs further modifications in order to better reproduce the planned maxillary position.

KEYWORDS: Orthognathic Surgery, Virtual Surgical Planning, Le Fort I, Surgery-First Approach.

-
1. Assistant lecturer of Oral and Maxillofacial surgery, Faculty of Dentistry, Alexandria University, Egypt.
 2. Professor Emeritus of Oral and Maxillofacial surgery, Faculty of Dentistry, Alexandria University, Egypt.
 3. Professor of Orthodontics and Maxillofacial surgery, CES University, Colombia
Visiting Professor of Orthodontics, Faculty of Dentistry, Alexandria University, Egypt.

*Corresponding Author:

E-mail: Haitham.abou.eleneen@gmail.com

INTRODUCTION

Mal-positioned teeth and jaw deformities are usually recognized by the patients early in life. Usually, patients seek treatment to have their teeth well-aligned and jaws corrected and consequently improve their overall facial esthetics. In addition to unpleasant facial esthetics, these patients may suffer from impaired function; mastication, temporomandibular joint disorders, nutritional problems, sleep apnea, speech difficulties and psychosocial problems. These deformities cannot be treated through orthodontics only. Hence, a team approach of orthodontics and orthognathic surgery is necessary to provide optimum treatment (1,2).

The first orthognathic surgery was performed by Hüllihen in 1849 when he performed mandibular subapical osteotomy to correct an anterior open bite (3).

Afterwards, René Le Fort (4) described his classic natural planes of maxillary fracture in 1901. Then Wassmund was the first to use Le Fort I osteotomy to correct midface deformities (5).

The traditional Le Fort I osteotomy is horizontal and parallel to the maxillary occlusal plane. Due to the lengthy maxillary canine root, the operator tends to shift the osteotomy more superiorly to avoid root injury. This may cause undesirable movement and asymmetry of the maxillary segment. A variety of modifications were described in the literature to accommodate the planned maxillary movement. Z-shaped osteotomy can be designed to support the rotation of the maxillary segment by increasing or decreasing the steepness of the anterior or posterior cuts.

Stepped osteotomy was proposed to make room for bone graft placement to support maxillary advancement (6–10).

In cases of midface deficiency and when there is a need for correcting the malar prominence deficiency and paranasal hollowing, changing the level of the conventional Le Fort I osteotomy was proposed as a solution for better cosmetic results (11). High Le Fort I below the infraorbital rims, quadrangular Le Fort I extending into the orbital floor, and quadrangular Le Fort I including the lateral orbital rim and zygoma were all modifications introduced to serve this purpose (6–10).

Presurgical records must be acquired preoperatively including standardized intraoral and extraoral photographs, dental impressions, a facebow transfer, and centric relation bite registration. Models are mounted on semi-adjustable articulator using the facebow transfer and centric relation record. In addition, lateral cephalometric and panoramic radiographs are required (1,2,11,12).

Traditionally, orthognathic surgery is planned on dental models mounted on semi adjustable articulator. Several disadvantages were noted by using this technique such as lacking the representation of the maxillofacial bony anatomy, inaccuracy in any of the procedural steps including impression making, facebow transfer, bite registration, mounting or measurements obtained from models will result in errors. Moreover, the whole process is time consuming and labor intensive. Additionally, the procedure does not allow for visualization of the osteotomies and bony segments including soft tissue drape in 3D (11).

Virtual surgical planning (VSP) offered unprecedented abilities to the maxillofacial surgeon. It allowed more precise analysis of the anatomical discrepancies in the three dimensions.

It also allowed the visualization of the bony anatomy and the effect of occlusal movements on the associated skeletal structures. In addition, multiple surgical plans may be simulated and their effect on both hard and soft tissues may be predicted in the three dimensions of space. Moreover, simulated postoperative soft tissues and bony predictions may be utilized for patient education and teaching purposes. It also offers a great and relatively simple and quick method for planning of complex asymmetry cases. Also, computer-aided design and computer-aided manufacture (CAD-CAM) technology may be implemented for creation of stereolithographic bone models on which plates may be adapted, cutting and drilling guides, intermediate and final occlusal splints and custom-made personalized plates (13–17).

Xia and coworkers (18) were the first group to introduce and explain the workflow of the VSP for treatment planning of complex craniofacial deformities and give it the name “Computer-Aided Surgical Simulation” or CASS protocol.

In conventional orthognathic surgery, three stages must be followed in the course of the treatment in order to achieve the desired results. The first stage is presurgical orthodontic phase in which the orthodontist

starts the treatment by positioning the whole dentition in the most favorable position over the corresponding basal bone (11). This includes decompensation of incisors, levelling and alignment of the dentition and arch coordination (19). This phase may last from 15 to 24 months (20–22). During the first phase, the dentofacial deformity is aggravated and becomes more evident. This would lead to a significant decrease in the overall acceptance and satisfaction with the treatment (23). The second phase is the surgical phase in which the orthognathic surgical procedure is performed. The third and last phase is postoperative orthodontics in which the orthodontist aims at finishing and detailing the occlusion of the patient. This phase usually lasts between 7 and 12 months. This approach is called orthodontics-first approach (OFA) (20–22).

Another approach is called Surgery-first approach (SFA) was introduced in order to overcome the disadvantages of OFA. In this approach minimal or no presurgical orthodontics are performed and hence most or all of the orthodontics are done during the postoperative phase. This will significantly decrease the overall treatment time of the dentofacial deformity and increase the acceptance and satisfaction of the patient (23).

The aim of the present study was to propose a new design of the intermediate stent that relates the mobilized maxilla to a fixed anatomical landmark in the skull which will allow for more accurate positioning of the maxilla. The null hypothesis was that there would be no difference between conventional wafer and bone-borne surgical guide.

MATERIALS AND METHODS

The study was a Prospective Clinical Randomized Controlled trial (Clinical Trials.gov Identifier: NCT04224805). It was conducted on a sample consisting of sixteen patients who were randomly allocated to study and control group using a free online service (<https://www.randomizer.org/>). The clinical part of the study was performed after gaining the ethical clearance from the Research Ethics Committee, Faculty of Dentistry, Alexandria University. All patients signed an Informed Consent Form before undergoing the operation to ensure and confirm their understanding of the outcome of the operation and the risks they might be subjected to during the intervention. The informed consent included as well their approval to participate in the study.

All patients requiring Le Fort I osteotomy were selected including those suffering from skeletal malocclusion (Class II or Class III), midface hypoplasia or vertical maxillary excess.

Patients were excluded if they are suffering from cleft lip and palate, skeletal disharmony due to trauma or due to significant medical condition. Participants were selected from both the outpatient clinic of Oral and Maxillofacial surgery department, Faculty of Dentistry, Alexandria University (n=7) and Vibart Dental Clinic, Medellin, Colombia (n=11) and were operated upon in the Oral and Maxillofacial Surgery Department, Faculty of Dentistry, Alexandria

University and different hospitals in Medellin, Colombia. After sample selection according to the inclusion and exclusion criteria, patients were randomly allocated into 2 groups, control group (8 patients) in which conventional interocclusal intermediate stent was used and study group (8 patients) in which the modified bone-borne splint was used.

Comprehensive history and clinical examination were performed for all the patients. Records were collected including intraoral and extraoral photographs (Figure 1 and 3), casts, plain X-rays (Panoramic and Lateral Cephalometry) and Cone Beam Computerized Tomography. VSP was performed (Figure 2 and 4) using Mimics Innovation Suite software (Materialise, Leuven, Belgium) following the protocol of Xia, Gateno and Teichgraber (13). All patients were treated under general anaesthesia. The surgical field was scrubbed with povidone-iodine (Betadine, The Nile Co. for Pharmaceuticals and Chemical Industries, Egypt) surgical scrub solution, followed by draping of the patient with sterile towels exposing only the area of surgery. The surgical procedure of Le Fort I osteotomy was performed in the following sequence external reference marking, incision and subperiosteal dissection, maxillary osteotomy, pterygomaxillary disjunction, septal, vomerine, and lateral nasal osteotomies, down fracture, mobilization of the maxilla, application of the stent, maxillary fixation, occlusal evaluation, wound debridement and closure (Figure 5). Postoperative medication included Amoxicillin + clavulanate 1 gm every 12 hours for the next 5 days (Augmentin, GlaxoSmithKline, UK), Metronidazole 500mg (Flagyl, GlaxoSmithKline, UK.) every eight hours for 5 days. □-chemo-trypsin 5 mg (□-chemo-trypsin, Leurquin, France, packed by Amoun pharmaceutical company, Egypt) ampoules as anti-oedematous once daily for 5 days. Diclofenac potassium 50mg (Cataflam, Novartis, Switzerland) every eight hours for 5 days. All patients were instructed to rinse their mouth using 0.12% Chlorhexidine (Hexitol, ADCO, Egypt) antiseptic mouth. Instructions of soft, fully liquid, high protein, high calorie diet were given for all patients for 4 weeks postoperatively. Patients were instructed to maintain a good oral hygiene.

Parameters for clinical evaluation included the surgery duration in minutes, postoperative pain using Visual Analogue Scale (VAS) on 2 weeks interval, extra-oral photography (Figure 6 and 7), sensory nerve function using Clinical Neurosensory Testing (NST) on 2 weeks and 3 months intervals (11) and wound healing. Radiographic evaluation was performed by comparing the planned maxillary position and the actual maxillary position obtained from CBCT taken 2 weeks postoperatively and the mean error of superimposition was calculated using 3-matic software (Materialise, Leuven, Belgium).

Statistical analysis

All of the obtained data was tabulated, compared and statistically analysed using SPSS software (IBM Corp., NY, USA). VAS was evaluated using independent samples t-test and Mann Whitney U test (p<0.05). Operation duration in minutes was evaluated using

independent samples t-test (p<0.05). Error of superimposition was evaluated using independent samples t-test (p<0.05).

Figure 1: Preoperative photographs of the patient 1 [Study group] (Frontal at rest “A” and smile “B” and Profile at rest “C”) and Occlusion “D”).

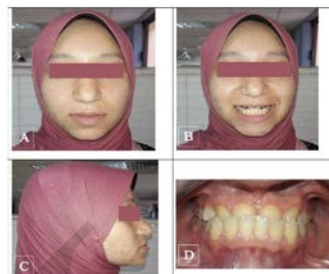

Figure 2: Virtual Surgical Planning with the design of the intermediate splint for the patient 1 [Study group].

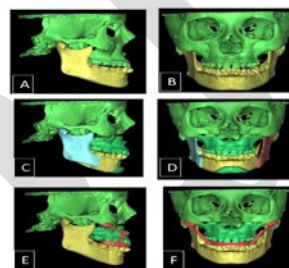


Figure 3: Preoperative photographs of the patient 2 [Control group] (Frontal at rest “A” and smile “B” and Profile at rest “C”) and Occlusion “D”).

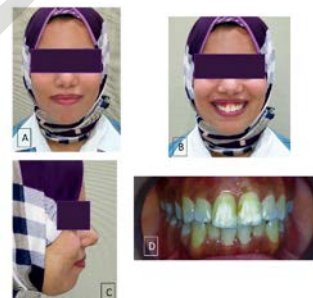

Figure 4: Virtual Surgical Planning with the design of the intermediate splint for the patient 2 [Control group].

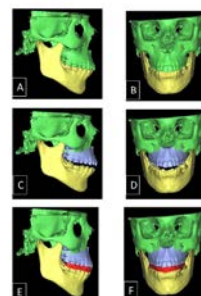


Figure 5: Intraoperative photo of the patient 1 (A and B) and he patient 2 (C and D).

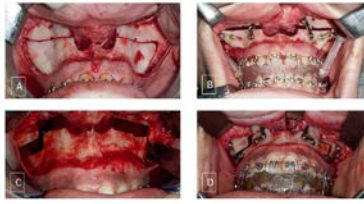


Figure 6: Three-month postoperative photographs of the patient 1 (Frontal at rest “A” and smile “B” and Profile at rest “C”) and Occlusion “D”.

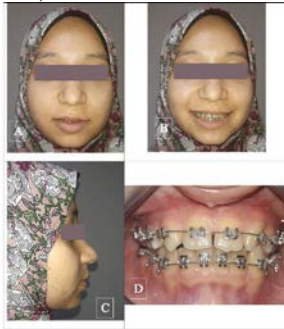
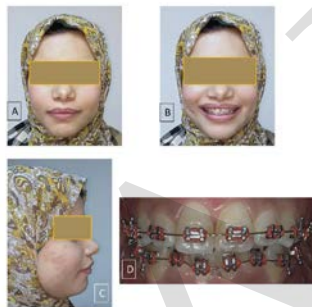
Figure 7: Three-month postoperative photographs of the patient 2 (Frontal at rest “A” and smile “B” and Profile at rest “C”) and Occlusion “D”.



RESULTS

Sixteen patients were enrolled in this study, eight of which were assigned for the control group and eight for the study group. The sample included 5 males and 11 females with age ranging from 16 to 42 years old with a mean of 24.31 ± 7.49 . The deformity ranged from anteroposterior deficiency, vertical maxillary deficiency or excess and the maxillary segment movement was planned accordingly either by translation or rotation in any of the 3 dimensions of space. Two of the patients (12.5%) were class I skeletal patients, 5 were class II (31.25%) and 9 were class III (56%).

All patients were treated via Surgery-first approach except for 1 case who was treated via Orthodontics-First approach. The time taken between performing the incision till completion of plate fixation was measured. The difference between the control group (99.75 ± 13.33 minutes) and the study group (93.75 ± 17.88 minutes) was found to be statistically insignificant using independent samples t-test ($p < 0.05$).

All patients have shown uneventful recovery and postoperative phase except for two patients. One patient has developed unilateral infection that resulted from severe maxillary sinusitis in the 7th postoperative week. The infection has drained spontaneously intraorally and was managed by combination of Amoxicillin-Clavulanic acid (Augmentin, GlaxoSmithKline, UK) with Metronidazole (Flagyl, GlaxoSmithKline, UK). Another patient had an early postoperative open bite in the 5th week that was managed by the application of heavy box elastics in the anterior labial segment.

All patients were tested using NST for any neurosensory injury. All patients were able to detect brush stroke direction over the upper lip, ala of the nose and medial half of the lower eyelid in all the intervals of assessment indicating Level A injury to the infraorbital nerve.

The mean pain assessed by VAS was statistically analyzed between the two groups and the difference between the two groups was found to be statistically insignificant ($p < 0.05$) (Table 1).

The mean error of the superimposition of the prediction 3D model of the maxillary segment and the postoperative 3D model of the maxilla for each case was found to be 0.317313 ± 0.2196 for the control group and 0.869838 ± 0.2295 for the study group. The difference between the two means was found to be statistically significant with independent samples t-test ($p < 0.05$) (Table 2) (Figure 8).

Figure 8: Bar chart showing the mean and standard deviation of the error of the superimposition of the planned and actual maxillary position between control and study groups.

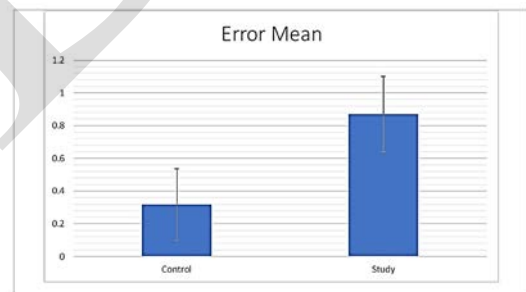

Table 1: Results of VAS in 1 week, 2 weeks and 3 months intervals.

| | | Control | Study | Significance |
|-------|---------------------|---------------|---------------|---------------------|
| VAS 1 | mean±SD | 8.25±0.707 | 7.50±1.414 | 0.201 (p<0.05) |
| | Week | | | Independent-samples |
| | median | 8.00 | 8.00 | t-test |
| | Interquartile range | 1 (8.00:9.00) | 3 (6.25:8.75) | |
| VAS 2 | mean±SD | 5.63±1.061 | 4.38±1.768 | 0.108 (p<0.05) |
| | Weeks | | | Independent-samples |
| | median | 5.50 | 4.00 | t-test |
| | Interquartile range | 2 (5.00:6.75) | 2 (3.25:5.00) | |
| VAS 3 | mean±SD | 0.75±0.886 | 0.63±0.744 | 0.819 (p<0.05) |
| | Months | | | Mann-Whitney U |
| | median | 0.50 | 0.50 | test |
| | Interquartile range | 2 (0:1.75) | 1 (0:1.00) | |

Table 2: Results of the error in the superimposition between the planned and actual maxillary position.

| | Control | Study | Significance |
|---------|------------|------------|-------------------------------|
| Mean±SD | 0.317±0.22 | 0.870±0.23 | 0.000 (p<0.05) |
| N | 8 | 8 | Independent-samples t-test |

DISCUSSION

Dentofacial deformity refers to deviation from the normal maxillomandibular complex proportions that have negative effects both on the relationship of the teeth within each arch and the occlusion (1,24). The consequences of such deformity involve compromise in one or more functions of the head and neck region including breathing, swallowing, speech articulation, mastication, lip posture, temporomandibular joints and periodontium. In addition, such deformities negatively affect psychosocial health and esthetics (1,25,26).

Patients suffering from dentofacial deformities require careful and meticulous preoperative assessment and planning for orthognathic surgery. The preoperative assessment usually entails the quality of the overlying soft tissue envelop, symmetry and harmony of the upper facial skeleton, morphology of unique esthetic units of the face, history of temporomandibular joint disorder, history of cervical spine symptoms, symmetry and harmony of the lower facial skeleton, and dental rehabilitation needs (1,12).

In the present study, the majority of the patients were females (68.75%). In addition, most of the patients aged between 16 and 25 years old. These results are similar to other studies reported in the literature. Younger females usually are usually more aware of their facial esthetics. Additionally, older population is usually well aware of surgical risks and complications

hence they are not inclined to surgical management of their deformities (27–31).

More than half of the patients included in this study (56%) were Class III skeletal deformity. The second prevalent type was Class II skeletal patients (31.25%) and the least prevalent was Class I skeletal patients (12.5%). This is in agreement with other studies which reported the same predominance of skeletal Class III patients who seek surgical correction of their deformities. Patients with Class II deformities usually resort to compensatory orthodontic treatment. On the other hand, patients with Class III deformity most commonly are corrected surgically. This is because a convex profile is more appealing in several cultures than concave profile (31,32). Similarly, a prominent and large mandible is considered very unaesthetic in Japanese population (19). Class II skeletal deformities are more commonly reported in Europe and North America. This can be explained by cultural differences of these populations as well as genetic factors.

The mean accepted error that was previously reported in the literature in multiple studies that defined success criteria of virtual 3D planning in orthognathic surgery was less than 2mm between the planned position and the actual position (16,33,34). In the present study, the control group showed an error of 0.317±0.22 and the study group has showed an error of 0.870±0.23. Although this difference was found to be statistically significant (p<0.05), both groups were found to have less that 2mm error and hence the virtual planning was successful.

Two defects in the design of the current design were noted and require further improvements. First, the extension arms are relatively long and in the current design they were about 2-3mm thick. This resulted in a relative flexibility of the arms which has led to error in the reproduction of the planned maxillary position during the surgery (mean error 0.870±0.23).

Another defect was that the interocclusal splint and the extension arms were constructed as one-piece stent. This has led to the lack of the ability to check the incisal show resulting from the performed surgery prior to the removal of the whole stent. In addition, this had entailed meticulous caution during the application of the stent since the arms were prone to fracture as a result of vigorous manipulation and retraction. A possible solution of this problem would be to construct the stent in three pieces. This design would allow for inspection of any bony interferences without disassembly of the whole stent. Additionally, it would give the operator the opportunity to check for the incisal show prior to removal of the interocclusal wafer.

Regarding the time of the procedure, the difference between the control group and the study group was found to be statistically insignificant (p<0.05). Although in the study group more dissection in the zygomatic buttress area was required to expose the bony part on which the footplate of the stent would be resting, this did not result in any significant increase in the overall time of the procedure.

In addition, more pain would have been expected in the study group as more soft tissue

dissection would result in more trauma to the tissues and hence more inflammation. Unlikely, difference in pain as recorded by VAS between the control group and the study group was insignificant ($p < 0.05$).

Similarly, nerve injury as evaluated through NST was expected to be higher in the study group since more retraction of the tissues that was required for the guide to be inserted may have led to more trauma to the surrounding tissues including the infraorbital nerve. In contrast, similar nerve injury degree (Level A) was noted in both control and study groups.

All patients enrolled in this study were treated via SFA except for only one patient who was treated via OFA. The presurgical orthodontics in OFA aim at providing arch coordination and allow for the intended surgical movement to correct the dentofacial deformity present which would require a lengthy phase of treatment during which facial esthetics significantly deteriorate (11). Since its introduction in 2009 (35), SFA has been adopted by several clinicians and gained widespread popularity due to its numerous advantages which include shortened treatment time, acceleration of tooth movement and immediate improvement in the facial esthetics (19,36–38). The range indications for SFA can be even widened to include uncoordinated arches by the simultaneous use of skeletal anchorage devices which will also aid in further shortening of the duration of the treatment (19).

CONCLUSION

Virtual Surgical Planning is a very predictable and time-efficient method to plan for orthognathic surgery. Although the new design of the intermediate stent was intended to accurately reposition the maxillary segment during orthognathic surgery, it needs further modifications to improve its accuracy. Surgery-First Approach is a very efficient approach to treat patients with dentofacial deformities and significantly decrease the required time for the correction of the deformity.

CONFLICT OF INTEREST

The authors declare that they have no conflicts of interest.

REFERENCES

1. Posnick J. Orthognathic Surgery: Principles and Practice. In Elsevier Saunders; 2014. p. 441–74.
2. Reyneke JP. Essentials of Orthognathic Surgery. In: Second edi. Quintessence Publishing Co Inc; 2010. p. 357–442.
3. Aziz SR, Simon P, Hullihen and the origin of orthognathic surgery. *J Oral Maxillofac Surg.* 2004;62:1303–7. Available from: <http://dx.doi.org/10.1016/j.joms.2003.08.044>
4. Gartshore L. A brief account of the life of Rene Le Fort. *Br J Oral Maxillofac Surg.* 2010;48:173–5. Available from: <http://dx.doi.org/10.1016/j.bjoms.2009.09.003>
5. Yamamoto Y, Tanikawa C, Takada K. Wassmund osteotomy for excessive gingival display: a case report with three-dimensional facial evaluation. *Aust Orthod J.* 2014;30:81–8.
6. Wagner S, Reyneke JP. The Le Fort I downsliding osteotomy: a study of long-term hard tissue stability. *Int J Adult Orthodon Orthognath Surg.* 2000;15:37–49.
7. Bennett MA, Wolford LM. The maxillary step osteotomy and Steinmann pin stabilization. *J Oral Maxillofac Surg.* 1985;43:307–11. Available from: [http://dx.doi.org/10.1016/02782391\(85\)90297-6](http://dx.doi.org/10.1016/02782391(85)90297-6)
8. Kaminishi RM, Davis WH, Hochwald DA, Nelson N. Improved maxillary stability with modified Lefort I technique. *J Oral Maxillofac Surg.* 1983;41:203–5. Available from: [http://dx.doi.org/10.1016/02782391\(83\)90084-8](http://dx.doi.org/10.1016/02782391(83)90084-8)
9. Stringer DE, Boyne PJ. Modification of the maxillary step osteotomy and stabilization with titanium mesh. *J Oral Maxillofac Surg.* 1986;44:487–8. Available from: [http://dx.doi.org/10.1016/s02782391\(86\)80019-2](http://dx.doi.org/10.1016/s02782391(86)80019-2)
10. Bays RA. Maxillary osteotomies utilizing the rigid adjustable pin (RAP) system: a review of 31 clinical cases. *Int J Adult Orthodon Orthognath Surg.* 1986;1:275–97.
11. Miloro M, Ghali GE, Larsen P, Waite P. Peterson's Principles of Oral and Maxillofacial Surgery. In: Miloro M, Ghali GE, Larsen P, Waite P, editors. Third edit. PMPH-USA, Ltd; 2011. p. 1365–89.
12. Fonseca R. Oral and Maxillofacial Surgery. In: Turvey T, Castello B, Ruiz R, editors. Third edit. Saunders; 2018. p. 44–61.
13. Xia JJ, Gateno J, Teichgraeber JF. New clinical protocol to evaluate craniomaxillofacial deformity and plan surgical correction. *J Oral Maxillofac Surg.* 2009;67:2093–106. Available from: <http://dx.doi.org/10.1016/j.joms.2009.04.057>
14. Xia JJ, Gateno J, Teichgraeber JF. Three-dimensional computer-aided surgical simulation for maxillofacial surgery. *Atlas Oral Maxillofac Surg Clin North Am.* 2005;13:25–39. Available from: <http://dx.doi.org/10.1016/j.cxom.2004.10.004>
15. Gateno J, Xia J, Teichgraeber JF, Rosen A, Hultgren B, Vadnais T. The precision of computer-generated surgical splints. *J oral Maxillofac Surg.* 2003;61:814–7. Available from: [http://dx.doi.org/10.1016/s02782391\(03\)00240-4](http://dx.doi.org/10.1016/s02782391(03)00240-4)
16. Hsu SS-P, Gateno J, Bell RB, Hirsch DL, Markiewicz MR, Teichgraeber JF, et al. Accuracy of a computer-aided surgical simulation protocol for orthognathic surgery: a prospective multicenter study. *J Oral Maxillofac Surg.* 2013;71:128–42. Available from: <http://dx.doi.org/10.1016/j.joms.2012.03.027>
17. Xia JJ, Gateno J, Teichgraeber JF. A new paradigm for complex midface reconstruction: a reversed approach. *J Oral Maxillofac Surg.* 2009;67:693–703. Available from: <http://dx.doi.org/10.1016/j.joms.2008.08.024>
18. Xia J, Ip HHS, Samman N, Wang D, Kot CSB, Yeung RWK, et al. Computer-assisted three-dimensional surgical planning and simulation: 3D

- virtual osteotomy. *Int J Oral Maxillofac Surg.* 2000;29:11–7. Available from: <http://dx.doi.org/10.1034/j.13990020.2000.290103.x>
19. Sugawara J, Nagasaka H, Yamada S, Yokota S, Takahashi T, Nanda R. The application of orthodontic miniplates to Sendai surgery first. In: *Seminars in Orthodontics.* Elsevier; 2018. p.17–36. Available from: <http://dx.doi.org/10.1053/j.sodo.2018.01.003>
 20. Diaz PM, Garcia RG, Gias LN, Aguirre-Jaime A, Pérez JS, de la Plata MM, et al. Time used for orthodontic surgical treatment of dentofacial deformities in white patients. *J Oral Maxillofac Surg.* 2010;68:88–92. Available from: <http://dx.doi.org/10.1016/j.joms.2009.07.062>
 21. Dowling PA, Espeland L, Krogstad O, Stenvik A, Kelly A. Duration of orthodontic treatment involving orthognathic surgery. *Int J Adult Orthodon Orthognath Surg.* 1999;14:146–52. Available from: [http://dx.doi.org/10.1016/s0889-5406\(99\)70058-2](http://dx.doi.org/10.1016/s0889-5406(99)70058-2)
 22. Luther F, Morris DO, Hart C. Orthodontic preparation for orthognathic surgery: how long does it take and why? A retrospective study. *Br J Oral Maxillofac Surg.* 2003;41:401–6. Available from: [http://dx.doi.org/10.1016/s02664356\(03\)00163-3](http://dx.doi.org/10.1016/s02664356(03)00163-3)
 23. Kwon T-G, Han MD. Current status of surgery first approach (part II): precautions and complications. *Maxillofac Plast Reconstr Surg.* 2019;41:23. Available from: <http://dx.doi.org/10.1186/s40902-019-0206-4>
 24. Zinser MJ, Mischkowski RA, Sailer HF, Zoller JE, Proffit WR, Fields HWJ, et al. Prevalence of malocclusion and orthodontic treatment need in the United States: estimates from the NHANES III survey. *Oral Surg Oral Med Oral Pathol Oral Radiol.* 2012;113:673–87. Available from: <http://dx.doi.org/10.1016/j.oooo.2011.11.009>
 25. Mohlin B, Thilander B. The importance of the relationship between malocclusion and mandibular dysfunction and some clinical applications in adults. *Eur J Orthod.* 1984;6:192–204. Available from: <http://dx.doi.org/10.1093/ejo/6.3.192>
 26. Motegi E, Hatch JP, Rugh JD, Yamaguchi H. Health-related quality of life and psychosocial function 5 years after orthognathic surgery. *Am J Orthod Dentofacial Orthop.* 2003;124:138–43. Available from: [http://dx.doi.org/10.1016/s08895406\(03\)00391-3](http://dx.doi.org/10.1016/s08895406(03)00391-3)
 27. Chew MT. Spectrum and management of dentofacial deformities in a multiethnic Asian population. *Angle Orthod.* 2006;76:806–9. Available from: [http://dx.doi.org/10.1043/0003-3219\(2006\)076\[0806:SAMODD\]2.0.CO;2](http://dx.doi.org/10.1043/0003-3219(2006)076[0806:SAMODD]2.0.CO;2)
 28. Ong MAH. Spectrum of dentofacial deformities: a retrospective survey. *Ann Acad Med Singapore.* 2004;33:239–42.
 29. Marques CG, Maniglia JV, Molina FD. Perfil do Serviço de Cirurgia Ortognat.ica de uma escola médica. *Braz J Otorhinolaryngol.* 2010;76:6004 Available from: <http://dx.doi.org/10.1590/S1808-86942010000500011>
 30. Castro V, do Prado CJ, Neto AIT, Zanetta-Barbosa D. Assessment of the epidemiological profile of patients with dentofacial deformities who underwent orthognathic surgery. *J Craniofac Surg.* 2013;24:e271-5. Available from: <http://dx.doi.org/10.1097/SCS.0b013e31828f28f3>
 31. Sato FRL, Mannarino FS, Asprino L, de Moraes M. Prevalence and treatment of dentofacial deformities on a multiethnic population: a retrospective study. *Oral Maxillofac Surg.* 2014;18:173–9. Available from: <http://dx.doi.org/10.1007/s10006-013-0396-3>
 32. Phillips C, Broder HL, Bennett ME. Dentofacial disharmony: motivations for seeking treatment. *Int J Adult Orthodon Orthognath Surg.* 1997;12:7–15.
 33. Mazzoni S, Badiali G, Lancellotti L, Babbi L, Bianchi A, Marchetti C. Simulation-guided navigation: a new approach to improve intraoperative three-dimensional reproducibility during orthognathic surgery. *J Craniofac Surg.* 2010;21:1698–705. Available from: <http://dx.doi.org/10.1097/SCS.0b013e3181f3c6a8>
 34. Tucker S, Cevidanes LHS, Styner M, Kim H, Reyes M, Proffit W, et al. Comparison of actual surgical outcomes and 3-dimensional surgical simulations. *J Oral Maxillofac Surg.* 2010;68:2412–21. Available from: <http://dx.doi.org/10.1016/j.joms.2009.09.058>
 35. Nagasaka H, Sugawara J, Kawamura H, Nanda R. “Surgery first” skeletal Class III correction using the Skeletal Anchorage System. *J Clin Orthod JCO.* 2009;43:97. Hernandez-Alfaro F, Guijarro-Martinez R, Peir.-Guijarro MA.
 36. Surgery first in orthognathic surgery: what have we learned? A comprehensive workflow based on 45 consecutive cases. *J Oral Maxillofac Surg.* 2014;72:376–90. Available from: <http://dx.doi.org/10.1016/j.joms.2013.08.013>
 37. Peiro-Guijarro MA, Guijarro-Martinez R, Hernandez-Alfaro F. Surgery first in orthognathic surgery: a systematic review of the literature. *Am J Orthod Dentofac Orthop.* 2016;149:448–62. Available from: <http://dx.doi.org/10.1016/j.ajodo.2015.09.022>
 38. Villegas C, Janakiraman N, Uribe F, Nanda R. Rotation of the maxillomandibular complex to enhance esthetics using a "surgery first" approach. *J Clin Orthod JCO.* 2012;46:85–91.