

## Review Article

## Updates in surgical treatment of vitiligo

Alzahraa M. Gamal<sup>1</sup>, Rasha A. El-Barbary<sup>1</sup>, Nayera H. Mofteh<sup>1</sup>

<sup>1</sup>Dermatology and Venereology Department, Faculty of Medicine for Girls, Cairo, Al-Azhar University, Egypt.

### ABSTRACT

**Background:** Vitiligo is a common cutaneous disorder of depigmentation. Surgical treatment of vitiligo is considered the final resort of repigmentation in lesions failing to respond for various medical and light therapies.

The tissue and cellular graft techniques are used for the successful introduction of melanocytes into the vitiligo lesions. Stability of vitiligo is the cornerstone of evaluation before surgery.

Tissue graft includes various techniques of transferring the healthy pigmented skin as a whole without processing to the vitiliginous skin, while the cellular graft involves further processing of these grafts into cellular components which are then applied on the recipient site after dermabrasion either as such or after multiplication in culture media.

**Aim:** To outline current modalities for surgical treatment of vitiligo.

**Conclusion:** Preparation of recipient-site is considered a crucial step for achieving a successful repigmentation. Multiple promising surgical modalities for vitiligo are continuous in the ongoing research and clinical trials to improve the repigmentation outcomes cosmetically with decreasing the time and the cost.

AM 2021; 2 (1): 118-127

**Keywords:** Vitiligo surgery, tissue graft, cellular graft, non-cultured epidermal cells suspension transplantation (NCES), non-cultured outer root sheath hair follicle cell suspension transplantation (NCORSHFS)

**Submit Date:** 4 October 2020

**Acceptance Date:** 8 November 2020

**Correspondence Author:** Alzahraa Mohammed Gamal, dermatology and venereology department, faculty of medicine for girls, Al-Azhar University, Cairo, Egypt. **Tel.** 01111865689. **Email:** alzahraamg13@gmail.com

**Please cite this article as:** Gamal AM, El-Barbary RA, Mofteh NH. Updates in Surgical Treatment of Vitiligo. AM 2021; 2 (1): 118-127. DOI: 10.21608/jram.2020.44431.1086

### INTRODUCTION

The distribution of vitiligo is estimated to be 0.5% to 2% worldwide [1]. Despite being physically asymptomatic it has a negative impact on the patient's psychological state and quality of life [2]. Surgical treatment is considered a valuable alternative in cases with stable vitiligo that are usually resistant to medical treatment and phototherapy [3]. Vitiligo surgery is based on melanocytes transfer from uninvolved skin to the stable vitiligo patch [4]. Following surgical treatments, repigmentation can improve by  $\geq 68\%$  with one treatment session only [5, 6]. Even though surgery cannot stop disease progression, achieving a cosmetically acceptable repigmentation of the affected area is the primary goal for surgical treatment [7]. Haxthausen and colleagues reported vitiligo surgery in 1947 for the first time. They transplanted thin split-thickness skin grafts from pigmented site to vitiliginous skin to study the disease pathogenesis. Starting then, more complex, and variable surgical techniques have been proposed [8]. The use of epidermal suspensions after

trypsinization was reported first by Gauthier and Surleve-Bazeille in 1992 [9]. Kahn and co-workers in 1996 [10] used short-pulse carbon dioxide laser to prepare the recipient site.

Several mechanisms for the repigmentation after vitiligo surgery are proposed. Being stimulated by the injury and healing process by the mean of recipient site preparation, the melanocytes dissociate from the basal layer, proliferate, migrate, and are repositioned in the basal layer, essentially the normal physiologic process for melanocyte homeostasis. The process of healing encourages the pro-melanogenic factors such as hepatocyte growth factor (HGF), basal fibroblast growth factor (bFGF), and keratinocyte growth factor to create a suitable environment for melanocyte stimulation [11, 12]. The matrix metalloproteinases (MMPs) contribute to migration of melanoblast during the wound healing [13]. Besides the downregulation of adhesion molecule E-

cadherin during wound healing is believed to facilitate melanocyte migration, and it has been demonstrated in repigmented skin post-punch grafting. The increase in heparanase post-grafting level and heparanase-mediated reduction in heparan sulfate at the dermo-epidermal junction (DEJ) is also believed to increase the pro-melanogenic factors [14].

#### Parameters of patient selection for surgery include [15]:

1. Duration of stability
2. Test grafting
3. Koebner's phenomenon
4. Longevity of stability
5. Disease versus lesional stability.

Disease stability must be evaluated before surgery, stability in vitiligo is a controversial subject, and there is no consensus regarding the criteria for defining stability [6,7]. A task force of the Indian Association of Dermatologists, Venereologists, and Leprologists, suggested 1 year as an acceptable period to establish stability, with the following definition: "absence of new lesions, absence of increase in the pre-existing lesions, and absence of Koebner phenomenon for at least 1 year". Spontaneous repigmentation is considered a good sign for vitiligo surgery outcome [3]. Since the period of stability often depends on the history provided by the patient, other methods for stability assessment have been proposed as serial photography, a lack of change in the Vitiligo Area Scoring Index (VASI) [16], Vitiligo European Task Force Assessment (VETF) [17], and a Vitiligo Disease Activity Score (VIDA) of -1 or 0 [18].

A single punch graft in the centre of a stable depigmented lesion to assess the degree of repigmentation is useful [8]. The repigmentation occurring beyond 1 mm from the border of the punch graft is an indicator of stability but it has been seen that even when the mini graft test is positive, the disease itself may be unstable [7]. Disease stability can also be assessed by reflectance confocal microscopy, anti-melanocyte antibody levels, total antioxidant status, measurement other cellular markers, such as interleukin 17, chemokine (C-X-C motif) ligand (CXCL) 9 and 10 [19, 20]. The raised CD8 T cell count in the perilesional skin may be indicative of instability and reactivation of disease [21]. In addition to the disease stability, the lesional stability should be assessed before vitiligo surgeries. Stable lesions are amelanotic with well-defined borders while active unstable lesions are hypomelanotic with poorly defined borders [22].

## PATIENT SELECTION

Surgical treatment is the treatment of choice for segmental vitiligo (SV), as well as for stable non-segmental vitiligo (NSV) that is refractory to medical treatment. Surgery can also be recommended for areas of difficult treatment, including the hands, feet, and mucosa, lesions with leukotrichia [7]. Patients with segmental or focal vitiligo have an extremely favorable response to vitiligo surgery [7, 8]. NSV has a higher

chance of an acceptable repigmentation if the disease is stable for at least 1–2 years [23, 24]. Acrofacial disease and areas over joints respond poorly, possibly because of repetitive motion or friction and injury at these locations [25, 26]. Recipient site with a greater vascular supply and follicular density, such as the head and neck, have a better response to surgery than the extremities [27]. Patients with a family history of vitiligo may be more prone to recurrences [12]. The response is better in younger patients [28]. There is no uniformly accepted age limit for surgery. However, many limitations exist for performing surgery in children, such as the need for general anesthesia and the stability is difficult to predict in children [29]. The need of postoperative medical therapy and phototherapy should be illustrated. Patients follow up after surgery is of utmost importance. Psychological assessment for the patient is better to perform before surgery. Patients with an unrealistic expectation are not a good candidate for surgery. Preoperative preparation should include investigations of complete blood counts, blood sugar evaluation, and bleeding and clotting time [28].

• **Ideal donor site:** The upper lateral aspect of the thigh is the ideal donor site besides, the medial aspect of forearm, arm, abdomen, and gluteal area can be used. For facial lesions, the post-auricular area can be considered an ideal donor site due to the good color match [15].

#### • Recipient-site preparation

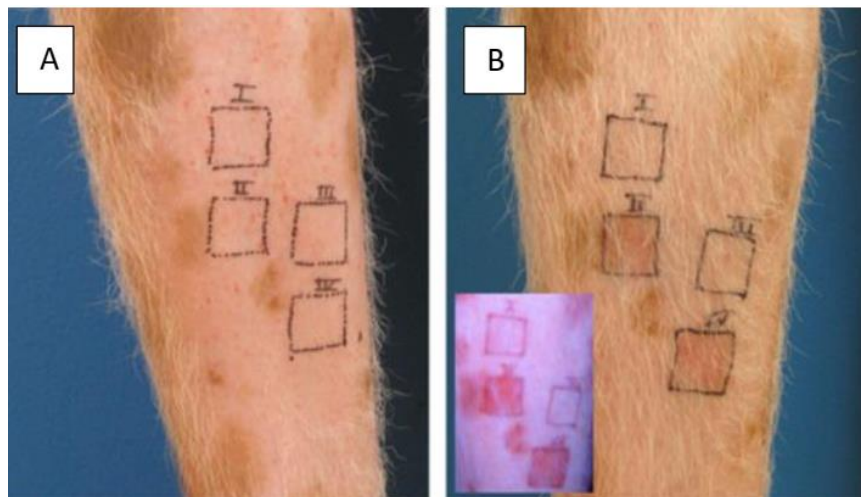
Preparing the recipient site is a fundamental step in achieving a successful repigmentation and accordingly, the techniques that are used in preparing the recipient site are crucial for generating repigmentation that is cosmetically acceptable [30]. Regardless of the method of grafting, recipient-site preparation permits access to the underlying structures essential for melanocyte adherence and nutrition [1]. The different methods for recipient site preparation include:

- **Liquid nitrogen:** Liquid nitrogen is used to create a cryo-blister followed by its de-roofing to expose the recipient site. Complications of this method include peripheral hyperpigmentation or hypopigmentation, perigraft halo and hypertrophic scarring [1].
- **Suction blisters:** Suction blisters have a fewer incidence of complications when compared to liquid nitrogen. It is a suitable method for small recipient sites as harvesting blisters for large sites is time-consuming [8]. Recipient sites can be prepared chemically by psoralen with ultraviolet A (PUVA), phenol, and trichloroacetic acid (TCA) [25]. This method permits rapid preparation of the recipient site with lack of scarring as the reticular dermis is not involved, but some risk for carcinogenesis is present [31]. Eighty-eight percent phenol or 100% TCA may be used also for coagulation of epidermal proteins but controlling the depth is difficult using this method [27].


- **Dermabrasion:** Dermabrasion represents a cost-effective and popular method for recipient site preparation, aiming for pinpoint bleeding as the clinical endpoint. A drawback of manual dermabrasion is being time-consuming with rapid user fatigue and being difficult to apply on large or concave surfaces such as eyelids, neck, axilla, and glans penis. Using motorized dermabrasion is a rapid alternative but requires skill as controlling the depth is more difficult [8, 32].
- **Lasers:** The carbon dioxide (CO<sub>2</sub>) and Erbium-doped yttrium aluminium garnet (Er: YAG) laser are traditionally used for recipient site preparation. The wavelengths emitted by both lasers are absorbed by water leading to tissue heating and consequent destruction by vaporization. The advantages of this method are speed, low user fatigue, and a bloodless field with uniform depth of ablation that is essential for tendinous or concave sites (Figure 1) [27]. The safety endpoint in CO<sub>2</sub> laser resurfacing is the appearance of a “chamois” yellow skin colour that is seen at the reticular dermis [32]. Er: YAG laser penetration depth is one-sixth that of CO<sub>2</sub> lasers

penetration, allowing more effective and precise tissue ablation without accompanying thermal necrosis [33].

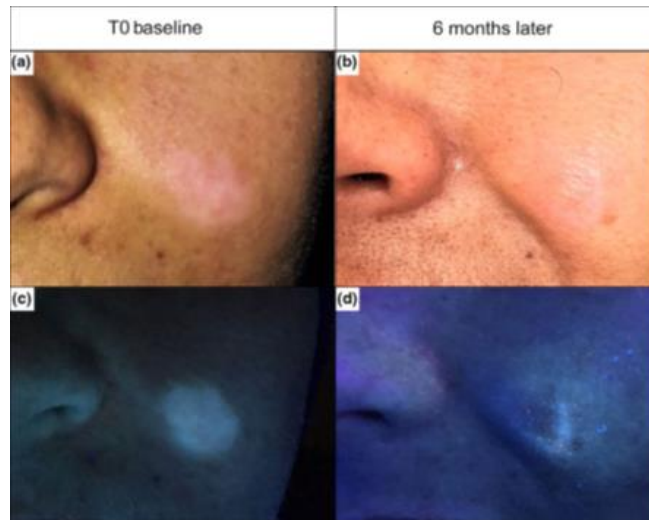
- **Sterile sandpaper (dermasanding):** Sandpaper use for manual dermabrasion has been reported in literature. This is a very simple and cost-effective method for dermabrasion of the skin in vitiligo surgeries (Figure 2) [35].
- **Dermarolling Benzekri and Gauthier:** In 2017 [36], reported the use of a dermaroller with a keratinocyte/melanocyte suspension in five cases. After 6 months, three patients showed excellent repigmentation while it was mild in the other two (Figure 3).
- **Electrofulguration-assisted dermabrasion:** Superficial electrofulguration performed including 1-2 mm of the surrounding normal skin to the vitiligo patch and then performed over the rest of the patch. It results in good margin and depth control and uniform preparation of the recipient site. This method facilitates dermabrasion of concave surfaces with low cost and easy availability [37]. Epidermal coagulation is also reported using radiofrequency [38].



**Figure (1): CO<sub>2</sub> laser for preparation of recipient sites in vitiligo surgeries.** Images of a patient (A): before surgery (B): 6 months after surgery. Recipient site prepared by (I): fractional CO<sub>2</sub> laser, (II): 209-lm full surface CO<sub>2</sub> ablation, (III): control site, (IV): 144-lm full surface ablation. The full surface ablation sites show 100% repigmentation and persistent erythema. After Wood's lamp examination the excellent (100%) repigmentation was confirmed [34].



**Figure (2): Sandpaper for preparation of recipient sites in vitiligo surgeries:** (A) Sandpaper wound around the index finger of the surgeon and fastened by surgical suture material, (B) Sandpaper strip cut to size and affixed to a disposable, sterile tongue depressor, (C) Dermabrasion of the eye lid margin with sandpaper [35].



**Figure (3): Dermarolling for cellular grafting:** Repigmentation of vitiligo lesion after trans-epidermal transplantation by dermarolling (a): at baseline (b): at 6 months. (c): Aspect with Wood's light at baseline (d): at 6 months [36].

### TYPES OF VITILIGO SURGERIES

Vitiligo surgery could be classified according to the type of the graft into tissue grafts and cellular grafts:

**1. Tissue Graft:** Tissue grafts include transferal of tissue to the recipient site without processing and they are suitable for treating small areas, but they are widely replaced by cellular graft.

**1.1 Mini-Punch Grafting (PG)** It is not suitable to be performed on large areas as it may cause pigment and textural variations such as cobblestoning and holds a risk of scarring and keloids [6, 39].

**1.2 suction blisters epidermal grafting (SBEG)** Perigraft halo commonly arise with it due to shrinkage of suctioned donor epidermis after removing the sustained negative pressure and due to the inhibitory effects of liquid nitrogen on the melanocytes of peripheral pigmented epidermis [40].

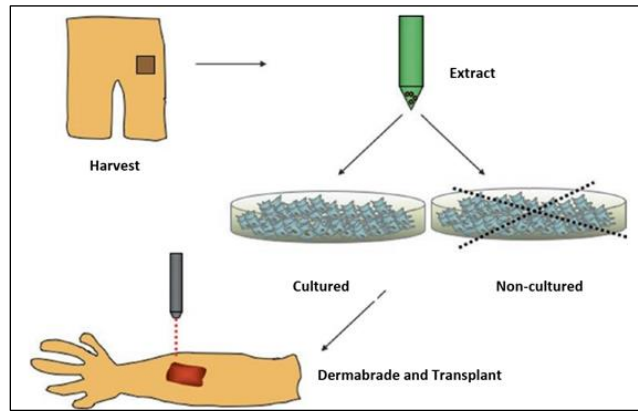
**1.3 Split-thickness skin grafts (STSGs)** are carried out by harvesting a thin or ultrathin layer of epidermis from the donor site that is 10% to 20% larger than the recipient site. Fenestrations are usually made in grafts allowing for the release of exudates and offering flexibility to the tissues. Leukotrichia can be treated by such graft while lesions with uneven surface such as the eyelids, areolae, and genitals are difficult to be treated by it. Potential complications are, hyperpigmentation, peripheral halo secondary to graft contracture, graft rejection, and donor site scarring if the graft is too thick [26, 27].

**1.4 Smash grafting** is a modification of the STSG where the graft is smashed into tiny pieces before being applied over the recipient site. Postoperative phototherapy is required to guarantee pigment spread as the donor site is only one-tenth the size of the recipient site [41].

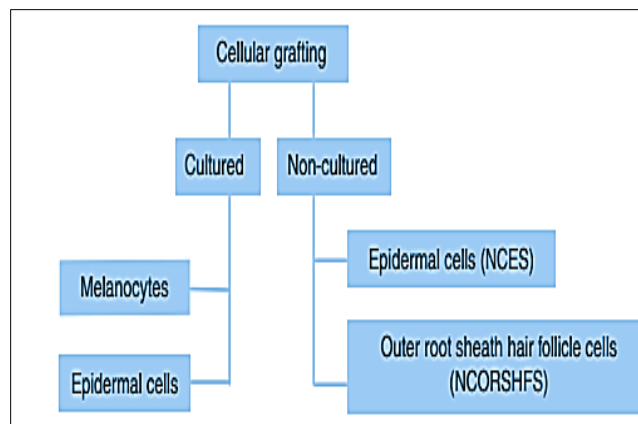
**1.5 Flip-top grafts:** Mini-grafts are placed under a hinged epidermal flap at the recipient site. The epidermal flap acts as a biological dressing and maintains the graft in place [42].

**1.6 Hair follicle grafts:** Its main principle is that the stem cell population in the bulge region of the follicle can lead to repigmentation by retrograde migration. This technique has proven successful in leukotrichia without the need for specific equipment [43].

**2. Cellular Grafts:** Cellular grafting in vitiligo has progressed significantly in the last two decades. Epidermal cells are first harvested from autologous donor skin and then transplanted (with or without prior selective cultivation) onto vitiliginous recipient sites (Figure 4) [44]. Unlike tissue grafts, which are limited by lesions size or the number of grafts, cellular grafts are used to treat large, depigmented areas using a small amount of donor tissue. Furthermore, it can repigment leukotrichia in vitiligo, possibly due to retrograde migration of transplanted melanocytes into the hair follicles [44]. Cellular grafting can be broadly categorized into; cultured and non-cultured cellular grafting (Figure 5).



**Figure (4): Principle of cellular grafting in vitiligo:** Cellular grafting involves harvesting epidermal cells from autologous donor skin and transplanting them (with or without prior selective cultivation) onto vitiliginous recipient sites [44]



**Fig 5: Types of cellular grafting for vitiligo** [44]

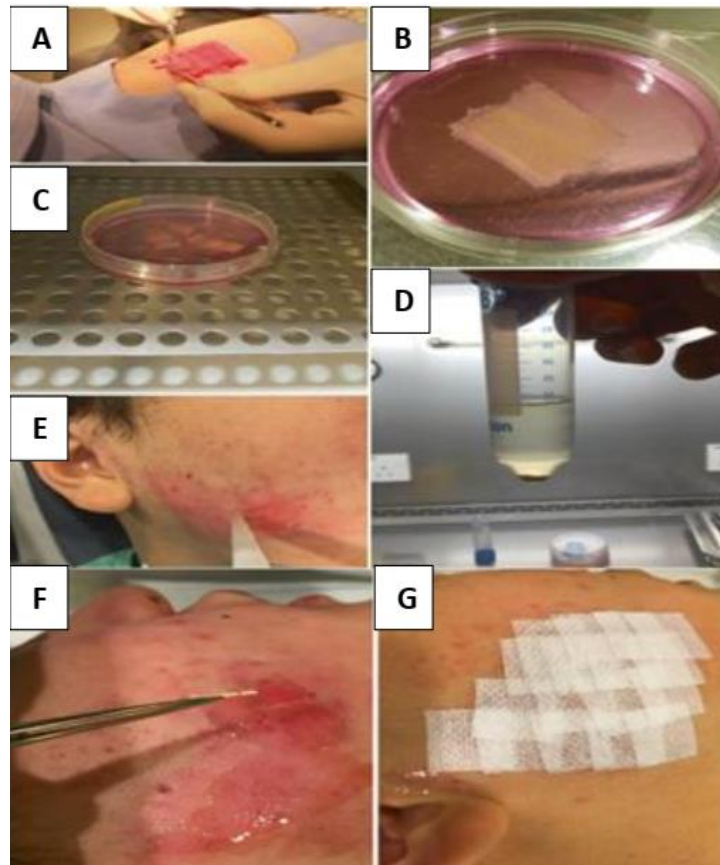
**2.1 Cultured Cellular Grafting**

A major advantage of in vitro culture is that the cells can be expanded and cryopreserved for future use. However, widespread application of cultured cellular grafting is limited by the legislative restriction on cultivating cells for clinical use [44]. It had not been possible to cultivate melanocytes in vitro in large quantities until the 1980s. This was due to the preferential overgrowth of keratinocytes over melanocytes in culture. The introduction of melanocyte mitogens in 1982 was considered a breakthrough. Eisinger and Marko [45] were able to selectively cultivate human melanocytes from neonatal foreskin and adult skin by adding 12-*O*-tetradecanoylphorbol-13-acetate (TPA) into the culture medium. In 1988, it was found that basic fibroblast growth factor (bFGF) is an important keratinocyte-derived factor influencing melanocyte survival and proliferation, a natural mitogen for melanocytes and it

became possible to cultivate human melanocytes in vitro without TPA (a tumour promoter) and fetal calf serum (FCS) [46]. In 1994 reimplantation of cryo-stored melanocytes was done successfully in four patients with vitiligo [47]. Cultured epidermal grafts are performed similarly to cultured melanocyte grafts, but the presence of both cell types prompts them to organize into a sheet similar to the basal layer of the skin [27, 48].

**2.2 Non-Cultured cellular grafting**

**2.2.1 Non-cultured epidermal Cell suspension transplantation (NCES):** In the last years, non-cultured epidermal cell suspension transplantation (NCES) is considered the standard vitiligo surgery [6]. NCES can be performed in 1 day without the need to culture cells with a donor-recipient ratio up to 1:10 (Figure 6) [8].



**Figure (6): Non-cultured epidermal Cell suspension transplantation (NCES) technique:**

(A) Harvesting an ultrathin epidermal graft using a silver dermatome. (B) An ultrathin epidermal graft in a petri dish containing 0.25% trypsin-EDTA. (C) The graft is cut into smaller pieces and incubated in 0.25% trypsin-EDTA at 37 °C. (D) Completion of cellular extraction: a dense cell pellet at the base of the Falcon tube after centrifugation. (E) Application of cell suspension onto laser-ablated vitiliginous recipient site. (F) Placing collagen sheets to hold cell suspension in place and prevent "run-off". (G) Securing suspension and collagen sheets using Hypafix dressings [44].

Disadvantages include the high cost, the need for specialized equipment and a skilled team and the concern of mitogenesis are drawbacks of the usage of the melanocyte medium. The significant run-off of the suspension from the recipient site makes it unsuccessful in difficult-to-treat areas and uneven areas [6, 49].

#### **Modification of non-cultured epidermal suspension surgery**

There are various modifications and innovations from the time that Gauthier and Surleve-Bazeille [9] pioneered NCES till now. These continuous modifications aim to overcome the drawbacks such as the time waste and the high cost of grafting. The pigmented skin was harvested from the occipital scalp with cold trypsinization for 18 hrs. The rapid (hot) trypsinization was developed later that consumed 60 min under 37°C. The melanocyte culture medium was used to stimulate the cell growth [50]. The culture medium was then substituted by the phosphate-buffered saline (PBS). PBS helps the melanocyte to survive through prevention of osmosis-induced cell death. It was also used to get rid of the excess trypsin [49]. To decrease the run of the cell suspension; hyaluronic acid was added to increase the

viscosity [51]. The automatic process by the battery-operated ReCell kit showed an effective repigmentation [52]. The cell suspension was prepared by the '6-well plate' technique later with the use of trypsin inhibitor and three times wash by PBS. The cells separation and filtration were done in the fifth and sixth well [53].

The repigmentation percent was improved by adding the patients' serum to the cell suspension [27]. The non-cultured hair follicular cell suspension was combined to NCES to improve the repigmentation outcome [54]. The four-compartment (4C) method was first published by Kumar and his colleagues [55] to simplify the steps of NCES and to decrease its cost. It included a petri dish divided into 4 partitions in which the graft was processed. In the first partition, the graft was incubated for one hour in 37° c. In partition 2 and 3 the graft was immersed in PBS to get rid of extra trypsin. In the last partition, cells were detached into PBS. The separated melanocytes and keratinocytes were re-suspended in the PBS to prepare homogenous cells suspension. Mrigpuri and colleagues [56] compared the 4C method with the traditional NCES with comparable repigmentation outcome.

### i. Non-cultured outer root sheath hair follicle cell suspension (NCORSHFS) transplantation

The hair follicle is the richest reservoir of the melanocytes and melanoblasts [57]. The mesenchymal stem cells that can differentiate to melanocyte stem cells are present in the perifollicular connective tissue and hair papilla. The follicular-melanin unit ratio of 1:5 which is significantly higher than the epidermal-melanin unit that includes 1 melanocyte to every 36 keratinocytes [58]. Other advantage of the follicular melanocytes over the epidermal melanocyte is that less affected by the autoimmune destruction but they are more affected by ageing and show cyclical activity [8]. This technique does not include the shave biopsy that needs a good, trained personnel to avoid scarring and thick biopsy. NCORSHFS utilizes a few follicles to treat large areas [59]. Hair follicles are extracted from the occipital scalp using small punches ( $\leq 1$  mm), subjected to the same process as NCEs except that the obtained follicles are washed in phosphate-buffered saline three times and are transferred to a new tube of trypsin every 30 minutes for a total of 3 tubes [27, 60].

## SURGICAL TREATMENT OF LEUKOTRICHIA

Repigmentation of leukotrichia that observed after vitiligo surgeries may be due to melanocytes migration from the epidermis to the hair follicle. Repigmentation of hair ranges from 2 months to 2 years after transplantation. The best results are seen over the eyebrows compared with the scalp, beard, and moustache [7, 61].

## SUMMARY

The modifications arsenal of therapeutic techniques in vitiligo surgeries aim to achieve cosmetically acceptable repigmentation with simplified steps and lower cost. It is considered that NCEs transplantation is the cornerstone of vitiligo surgeries in the recent years.

**Financial support and sponsorship:** Nil.

**Conflicts of interest:** There are no conflicts of interest

## REFERENCES

1. Al-Hadidi N, Griffith JL, Al-Jamal MS and Hamzavi I. Role of recipient-site preparation techniques and post-operative wound dressing in the surgical management of vitiligo. *J Cutan Aesthet Surg* 2015; 8: 79-87.
2. Chan MF, Chua TL. The effectiveness of therapeutic interventions on quality of life for vitiligo patients: A systematic review. *Int J Nurs Pract* 2012; 18: 396-405.
3. Parsad D, Gupta S. Standard guidelines of care for vitiligo surgery. *Indian J Dermatol Venereol Leprol* 2008; 74: 37-45.
4. Gauthier Y, Benzekri L. Non-cultured epidermal suspension in vitiligo: from laboratory to clinic. *Indian J Dermatol Venereol Leprol* 2012; 78: 59-63.
5. Huggins RH, Henderson MD, Mulekar SV, Ozog DM, Kerr HA, Jabobsen G, et al. Melanocyte-keratinocyte transplantation procedure in the treatment of vitiligo: the experience of an academic medical center in the United States. *J Am Acad Dermatol* 2012; 66(5): 785-793.
6. Rodrigues M, Ezzedine K, Hamzavi I, Pandya AG and Harris JE. New discoveries in the pathogenesis and classification of vitiligo. *J Am Acad Dermatol* 2017; 77:1-13.
7. Robinson JK, Hanke CW, Siegel DM, Fratila A, Bhatia AC, Rohrer TE. *Surgery of the skin* (3rd ed). China: Elsevier; 2015. 688- 698.
8. Mohammad TF, Hamzavi IH. Surgical therapies for vitiligo. *Dermatol Clin* 2017; 35: 193-203.
9. Gauthier Y, Surleve-Bazeille JE. Autologous grafting with non-cultured melanocytes: a simplified method for treatment of depigmented lesions. *J Am Acad Dermatol* 1992; 26: 191-194.
10. Kahn AM, Ostad A, Moy RL. Grafting following short pulse CO2 laser de-epithelialization. *Dermatol Surg* 1996; 22: 965-967.
11. Kovacs D, Cardinali G, Aspite N, Cota C, Luzi F, Bellei B, et al. Role of fibroblast-derived growth factors in regulating hyperpigmentation of solar lentigo. *Br J Dermatol* 2010; 163: 1020-1027.
12. Muller AK, Meyer M, Werner S. The roles of receptor tyrosine kinase and their ligands in the wound repair process. *Semin Cell Dev Biol* 2012; 23: 963-970.
13. Lei TC, Vieira WD, Hearing VJ. In vitro migration of melanoblasts requires matrix metalloproteinase 2: implications to vitiligo therapy by photochemotherapy. *Pigment Cell Res* 2002; 15: 426-432.
14. Kovacs D, Abdel-Raouf H, Al-Khayyat M, Abdel-Azeem E, Hanna MR, Cota C, et al. Vitiligo: characterization of melanocytes in repigmented skin after punch grafting. *J. Eur Acad Dermatol Venereol* 2015; 29: 581-590.
15. Ashwini PK, Sushmitha DJ, Veeranna S. Vitiligo with special emphasis on vitiligo surgery. *Arch Med Health Sci* 2020; 8: 140- 146.
16. Hamzavi I, Jain H, McLean D, Shapiro J, Zeng H, Lui H. Parametric modelling of narrowband UV-B phototherapy for vitiligo using a novel quantitative tool: the vitiligo area scoring index. *Arch Dermatol* 2004; 140(6): 677-683.
17. Taïeb A, Picardo M. VETF Members. The definition and assessment of vitiligo: a consensus report of the vitiligo European task force. *Pigment Cell Res* 2007; 20: 27-35.
18. Njoo MD, Das PK, Bos JD, Westerhof W. Association of the köbner phenomenon with disease activity and therapeutic responsiveness in vitiligo vulgaris. *Arch Dermatol* 1999; 135: 407-13.
19. Singh RK, Lee KM, Vujkovic-Cvijin I, Ucmak D, Farahnik B, Abrouk M, et al. The role of IL-17 in vitiligo: a review. *Autoimmun Rev* 2016; 15: 397-404.
20. Wang XX, Wang QQ, Wu JQ, Jiang M, Chen L, Zhang CF, et al. Increased expression of CXCR3 and its ligands in patients with vitiligo and CXCL10 as a

- potential clinical marker for vitiligo. *Br J Dermatol* 2016; 174: 1318-1326.
21. **Abdallah M, Lotfi R, Othman W, Galal R.** Assessment of tissue FoxP3+, CD4+ and CD8+ T-cells in active and stable nonsegmental vitiligo. *Int J Dermatol* 2014; 53: 940-946.
  22. **Benzekri L, Gauthier Y.** Clinical markers of vitiligo activity. *J Am Acad Dermatol* 2017; 76: 856-862.
  23. **Faria AR, Tarlé RG, Dellatorre G, Mira MT, and de Castro CS.** Vitiligo -part 2- classification, histopathology and treatment. *An Bras Dermatol* 2014; 89: 784-790.
  24. **Speeckaert R, van Geel N.** Vitiligo: An Update on Pathophysiology and Treatment Options. *Am J Clin Dermatol* 2017; 18(6): 733- 744.
  25. **Gupta S, Goel A.** Suction blister epidermal grafting. In: Gupta S, Olsson MJ, Kanwar A, Ortonne JP, editors. *Surgical Management of Vitiligo*. Oxford: Blackwell Publishing 2007; 96–107.
  26. **Mulekar SV, Isedeh P.** Surgical interventions for vitiligo: an evidence-based review. *Br J Dermatol* 2013; 169: 57– 66.
  27. **Ghia D, Mulekar S.** Surgical management of vitiligo. In: Hamzavi I, Mahmoud B, Isedeh P, editors. *Handbook of vitiligo: basic science and clinical management*. London: JP Medical Publishers 2015; 111–138.
  28. **Mysore V, Koushik L.** Overview of vitiligo surgery. In: Mysore V, editor. *ACS(I) Textbook on Cutaneous and Aesthetic Surgery*. New Delhi: Jaypee Brothers 2017; p: 327-33.
  29. **Sahni K, Parsad D, Kanwar AJ.** Non-cultured epidermal suspension transplantation for the treatment of stable vitiligo in children and adolescents. *Clin Exp Dermatol* 2011; 36(6): 607-612.
  30. **Awad SS.** Dermabrasion may repigment vitiligo through stimulation of melanocyte precursors and elimination of hyperkeratosis. *J Cosmet Dermatol* 2012; 11: 318-22.
  31. **Stern RS.** PUVA Follow-Up Study. The risk of squamous cell and basal cell cancer associated with psoralen and ultraviolet A therapy: A 30-year prospective study. *J Am Acad Dermatol* 2012; 66: 553-562.
  32. **Silpa-Archa N, Griffith JL, Williams MS, Lim HW, Hamzavi IH.** Prospective comparison of recipient-site preparation with fractional carbon dioxide laser vs. dermabrasion and recipient-site dressing composition in melanocyte-keratinocyte transplantation procedure in vitiligo: a preliminary study. *Br J Dermatol* 2016; 174(4): 895-897.
  33. **El Hoseny SM.** Treatment of upper- and lower-extremity vitiligo with epidermal grafts after CO2 laser resurfacing with systemic and topical steroids. *Aesthetic Plast Surg*. 2010; 34: 157-166.
  34. **Lommerts JE, Meesters AA, Komen L, Bekkenk MW, de Rie MA, Luiten RM, et al.** Autologous cell suspension grafting in segmental vitiligo and piebaldism: a randomized controlled trial comparing full surface and fractional CO2 laser recipient-site preparations. *Br J of Dermatol* 2017; 177: 1293-1298.
  35. **Ashique KT, Kaliyadan F, George RR.** Dermabrasion of the recipient skin in vitiligo surgery: An easier way out. *Indian J Dermatol Venereol Leprol* 2018; 84(4): 498-499.
  36. **Benzekri L, Gauthier Y.** The first transepidermal transplantation of non-cultured epidermal suspension using a dermarolling system in vitiligo: A sequential histological and clinical study. *Pigment Cell Melanoma Res* 2017; 30(5): 493-497.
  37. **Bishnoi A, Gupta M, Parsad D, Vinay K.** Electrofulguration-assisted dermabrasion for recipient-site preparation in non-cultured epidermal cell suspension type vitiligo surgery. *J Am Acad Dermatol* 2019; 80(6): 149-150.
  38. **Kaliyadan F.** Using the ball-shaped attachment of a radiofrequency ablation device for preparation of recipient site in vitiligo surgery. *Indian J Dermatol* 2011; 56(4): 459-460.
  39. **Taieb A, Alomar A, Böhm M, Dell'anna ML, De Pase A, Eleftheriadou V, et al.** Guidelines for the management of vitiligo: the European dermatology forum consensus. *Br J Dermatol* 2013; 168(1): 5-19.
  40. **Ebrahimi A, Radmanesh M, Kavoussi H.** Recipient site preparation for epidermal graft in stable vitiligo by a special fraise. *An Bras Dermatol* 2015; 90(1):55-60.
  41. **Krishnan A, Kar S.** Smashed skin grafting or smash grafting - a novel method of vitiligo surgery. *Int J Dermatol* 2012; 51(10):1242-1247.
  42. **Sharma S, Garg VK, Sarkar R, Relhan V.** Comparative study of flip-top transplantation and punch grafting in stable vitiligo. *Dermatol Surg* 2013; 39(9): 1376-1384.
  43. **Thakur P, Sacchidanand S, Nataraj HV, Savitha AS.** A study of hair follicular transplantation as a treatment option for vitiligo. *J Cutan Aesthet Surg* 2015; 8(4): 211-217.
  44. **Picardo M and Taïeb A.** *Vitiligo* (2nd ed). Switzerland: Springer Nature 2019; p: 382-397.
  45. **Eisinger M, Marko O.** Selective proliferation of normal human melanocytes in vitro in the presence of phorbol ester and cholera toxin. *Proc Natl Acad Sci USA* 1982; 79: 2018- 2022.
  46. **Halaban R, Langdon R, Birchall N, Cuono C, Baird A, Scott G, et al.** Basic fibroblast growth factor from human keratinocytes is a natural mitogen for melanocytes. *J Cell Biol* 1988; 107(4):1611- 1619.
  47. **Olsson MJ, Moellman G, Lerner AB, Juhlin L.** Vitiligo: repigmentation with cultured melanocytes after cryostorage. *Acta Derm Venereol* 1994; 74: 226-228.
  48. **Guerra L, Primavera G, Raskovic D, Pellegrini G, Golisano O, Bondanza S, et al.** Erbium: YAG laser and cultured epidermis in the surgical therapy of stable vitiligo. *Arch Dermatol* 2003; 139(10): 1303-1310.
  49. **Holla AP, Kumar R, Parsad D, Kanwar A.** Modified procedure of noncultured epidermal suspension



- transplantation: changes are the core of vitiligo surgery. *J Cutan Aesthet Surg* 2011; 4: 44-45.
50. **Olsson MJ, Juhlin L.** Leucoderma treated by transplantation of a basal cell layer enriched suspension. *Br J Dermatol* 1998; 138: 644-648.
  51. **Van Geel N, Ongenaë K, De Mil M, Haeghen YV, Vervaeet C, Naeyaert JM.** Double-blind placebo-controlled study of autologous transplanted epidermal cell suspensions for repigmenting vitiligo. *Arch Dermatol* 2004; 140:1-6.
  52. **Komen L, Vrijman C, Tjin EP, Krebbers G, de Rie MA, Luiten RM, et al.** Autologous cell suspension transplantation using a cell extraction device in segmental vitiligo and piebaldism patients: A randomized controlled pilot study. *J Am Acad Dermatol* 2015; 73(1): 170-172.
  53. **Goh BK, Chua XM, Chong KL, De Mil M, Van Geel NAC.** Simplified cellular grafting for treatment of vitiligo and piebaldism: the “6-well plate” technique. *Dermatol Surg* 2010; 36: 203-207.
  54. **Razmi T M, Kumar R, Rani S, Kumaran SM, Tanwar S, Parsad D.** Combination of follicular and epidermal cell suspension as a novel surgical approach in difficult-to-treat vitiligo: A randomized clinical trial. *JAMA Dermatol* 2018; 154(3): 301-308.
  55. **Kumar R, Parsad D, Singh C, Yadav S.** Four compartment method: a simplified and cost-effective method of noncultured epidermal cell suspension for the treatment of vitiligo. *Br J Dermatol* 2014; 170: 581-585.
  56. **Mrigipuri S, Razmi TM, Sendhil Kumaran M, Vinay K, Srivastava N, Parsad D.** Four compartment method as an efficacious and simplified technique for autologous non-cultured epidermal cell suspension preparation in vitiligo surgery: A randomized, active-controlled study. *J Eur Acad Dermatol Venereol* 2019; 33(1): 185-190.
  57. **Randall VA, Jenner TJ, Hibberts NA, De Oliveira IO, Vafae T.** Stem cell factor/c-Kit signalling in normal and androgenetic alopecia hair follicles. *J Endocrinol* 2008; 197(1): 11-23.
  58. **Tobin DJ, Paus R.** Graying: gerontobiology of the hair follicle pigmentary unit. *Exp Gerontol* 2001; 36: 29-54.
  59. **Kumar A, Gupta S, Mohanty S, Bhargava B, Airan B.** Stem cell niche is partially lost during follicular plucking: a preliminary pilot study. *Int J Trichol* 2013; 5(2): 97-100.
  60. **Mohanty S, Kumar A, Dhawan J, Sreenivas V, Gupta S.** Non-cultured extracted hair follicle outer root sheath cell suspension for transplantation in vitiligo. *Br J Dermatol* 2011; 164(6): 1241-1246. 59.
  61. **Gan EY, van Geel N, Goh BK.** Repigmentation of leucotrichia in vitiligo with non-cultured cellular grafting. *Br J Dermatol* 2012; 166: 196-9.

## الملخص العربي

### مستجدات العلاج الجراحي للبهاق

الزهراء محمد جمال الدين عبد الله<sup>1</sup>، رشا علي البربري<sup>1</sup>، نيرة حسن مفتاح<sup>1</sup>

<sup>1</sup>قسم الأمراض الجلدية والتناسلية، كلية الطب البنات، القاهرة، جامعة الأزهر، جمهورية مصر العربية

#### ملخص البحث

**الخلفية:** البهاق هو اضطراب جلدي شائع يؤدي إلى فقدان تصبغ الجلد. يعتبر التدخل الجراحي في البهاق هو الحل الأخير لإعادة التصبغ في الأماكن التي لا تستجيب للعلاج الدوائي أو العلاج بالأشعة الضوئية.

لقد شهد التدخل الجراحي في علاج البهاق تطورا ملحوظا في العقدين السابقين، حيث يهدف بالأساس إلي إعادة التصبغ لبقع البهاق عبر نقل نسيج البشرة السليم ككل دون معالجة لمناطق الإصابة بالبهاق أو نقل الخلايا الصبغية والكيراتينة التي يتم معالجتها الى الأماكن المصابة بعد صنفرتها.

كما يعتبر عامل التقييم الرئيسي قبل الجراحة هو خلو حالات البهاق من أي نشاط لفقدان التصبغ.

#### الهدف: الكشف عن مستجدات العلاج الجراحي للبهاق

**الخلاصة:** هناك العديد من الطرق لتحضير المكان المستقبل لجراحات زرع الصبغة حيث يعتبر تحضيره خطوة هامة لنجاح إعادة التصبغ. وكما تجرى العديد من الأبحاث والتجارب السريرية بصفة مستمرة ووتيرة متزايدة هدفا في تحسين نتائج إعادة التصبغ بعد الجراحة وجعلها أقل كلفة و أقل في الوقت المستهلك.

**الكلمات المفتاحية:** جراحة البهاق، ترقيع الأنسجة، التطعيم الخلوي، نقل خلايا البشرة الغير مزروعة معمليا، نقل خلايا بصيلات الشعر الصبغية غير المزروعة معمليا.

#### الباحث الرئيسي

الاسم: الزهراء جمال الدين ، قسم الأمراض الجلدية والتناسلية، كلية طب البنات، القاهرة، جامعة الأزهر، جمهورية مصر العربية

الهاتف: 00201111865689

البريد الإلكتروني: alzahraamg13@gmail.com