

Assessment the Association of Fatty Acid Binding Protein 1 with Hepatocellular Carcinoma

Reda M. Albadawy ^a, Badawy A. Abd El-Aziz ^a, Eman G. Behiry ^b, Maha E. Azzam ^a

^a Department of Hepatology, Gastroenterology and Infectious Diseases, Benha faculty of medicine, Benha University, Egypt. ^b Department Clinical and Chemical Pathology, Benha Faculty Of Medicine ,Benha University, Egypt

Correspondence to: Maha E. Azzam, Department of Hepatology, Gastroenterology and Infectious Diseases Benha faculty of medicine, Benha University, Egypt.

Email:

doctorhepatology@gmail.com

Received: 14 November 2019

Accepted: 19 January 2020

Abstract

Background & Objectives: Hepatocellular carcinoma and its complications with the multiplicity is crucial worldwide health problem especially in the presence of heterogeneous liver. We aimed to assess the value of fatty acid binding protein-1 in the diagnosis of hepatocellular carcinoma in comparison to alpha-fetoprotein.

Methodology: One hundred subjects were enrolled in this observational case-control study who attended the Hepatology, Gastroenterology and Infectious Diseases Department in Benha University Hospitals between January 2018 and January 2019 and divided into 80 patients (40 HCC & 40 LC and 20 healthy subjects). Serum level of fatty acid binding protein-1 was determined by enzyme-linked immunosorbent assay. **Results:** Hepatocellular carcinoma patients were slightly older than healthy subjects as mean age in group I was (56.1±9 yrs) while in group III was (52.9±17.1 yrs). There was a marked increase in hepatocellular carcinoma in males with male to

female ratio 4:1. There was a high prevalence of hepatocellular carcinoma in the rural population.

Fatty acid binding protein-1 was higher in hepatocellular carcinoma compared to liver cirrhosis and the control group, ranged from (107-1224 ng/L, 48-981 ng/L and 34-460 ng/L) respectively. Analysis of ROC curve revealed that at a level 214 ng/L sensitivity, specificity, PPV, NPV and accuracy were 60%, 77.5%, 72.7%, 66% respectively with AUC 0.715 **Conclusion:** The use of fatty acid binding protein-1 especially in multicentric hepatocellular carcinoma will be valuable because the difficulty in most cases to prove the multiplicity of hepatocellular carcinoma.

Key Words: Hepatocellular Carcinoma (HCC), Fatty Acid Binding Protein (FABP-1), liver cirrhosis (LC)

Introduction

Hepatocellular carcinoma (HCC) is the fifth most common tumour worldwide and the second most common cause of cancer-related death (1). It is one of the most common aggressive malignancies worldwide; accounting about two thirds of all primary liver cancer cases (2). Liver fatty acid-binding proteins (LFABPs) are a group of low molecular weight (14-15 kDa) proteins involved in the intracellular transport of long-chain bioactive fatty acids. FABPs should promise to serve as markers of tissue injury. Various FABPs were tested to detect early damage of tissues with probability of its clinical usage (3).

L-FABP is an important endogenous cytoprotectant, minimizing hepatocyte oxidative damage and interfering with ischemia-reperfusion and other hepatic injuries (4).L-FABP has been reported in many metabolic disease processes, such as cholestatic liver disease, cancer, diabetes, obesity and atherosclerosis (5).Over expression of L-FABP has been observed in various cancers, including liver, lung, gastric, and colon cancers (6).L-FABP was highly expressed in the tumor tissue as in HCC malignancy and could serve as a potential target for HCC therapy (7).

We aimed to assess the value of fatty acid binding protein-1 in the diagnosis of hepatocellular carcinoma in comparison to Alpha-fetoprotein.

Subjects and Methods

This observational case-control study was conducted on 100 subjects attending Department of Hepatology, Gastroenterology and Infectious Diseases in Benha University Hospitals during the period from January 2018 to January 2019 and informed written consent was obtained from all patients participating in this study after explaining the study measures in details and divided into three groups Group I Included 40 patients with hepatocellular carcinoma, Group II Included 40 patients with cirrhosis and Group III Included 20 apparently healthy subjects as control group.

Patients with HCC received any type of treatment, patients with malignancies other than HCC, patients with acute kidney injury, heart failure, pneumonia and patient with chronic HBV were excluded. Full history taking and thorough clinical examination and laboratory tests including CBC, blood sugar level, serum ALT, serum AST, serum creatinine, viral markers (HBsAg, anti-HCV

Ab) were assayed using 3rd generation enzyme linked immunosorbent assay (ELISA)Kit, alpha fetoprotein (AFP) (ng/dl) by (ELISA)and serum fatty acid binding protein-1(FABP-1 ng/L): FABP-1 was measured with a sandwich enzyme-linked immunosorbent assay developed in collaboration with Sunshine Biotechnology.

The detection limit of the assay was (8 ng/L-2000ng/L). Imaging by 4-phase multidetector CT scan or dynamic contrast enhanced MRI for diagnosis of HCC by identification of the typical hallmark (hypervascularity in arterial phase with washout in the portal venous or delayed-phases) (**EASL- EORTC, 2012**).

Okuda staging system was used to assess the stage of HCC.

	Points	
	0	1
Tumour size	<50% of liver	>50% of liver
Ascites	No	Yes
Albumin (g/dl)	≥3	<3
Bilirubin (mg/dl)	<3	≥3

Okuda stage I, 0 points; Okuda stage II, 1 or 2 points; Okuda stage III, 3 or 4 points.

Statistical Analysis

The analysis of the data was carried out using SPSS (IBM Corp. Released 2011. IBM SPSS Statistics for Windows, version 20.0. Armonk, NY: IBM Corp.). Categorical data were presented as number and percentages while quantitative data were expressed as mean ± standard deviation Median, Fisher-exact test (FET) was used to analyze categorical variables. Student “t”

test was used to analyze normally distributed variables among 2 independent groups. **Chi-Square test** was used to examine the relationship between two qualitative variables. Difference among 3 independent means was analyzed using ANOVA for parametric variables. The **Mann–Whitney (U-test)** used to compare two nonparametric quantitative variables, p<0.05 was

considered statistically significant. The ROC Curve (**receiver operating characteristic**) provides a useful way to evaluate the sensitivity and specificity for quantitative diagnostic measures that categorize cases into one of two groups. The optimum cut off point was defined as that which maximized the AUC value. The area under the ROC curve (AUC) results were considered excellent for AUC value between 0.9-1, good for AUC values between 0.8-0.9, fair for AUC values between 0.7-0.8, poor for AUC values between 0.6-0.7 and failed for AUC values between 0.5-0.6 .

Results:

The present history and clinical examination were summarized in HCC was significantly associated with weight loss, while LC was significantly associated with history of ascites , HE and edema LL. Otherwise, no significant differences were found between the two groups.

As regard laboratory investigations:

Hemoglobin concentration and platelet count were significantly lower in LC and HCC when compared to healthy control group as mean levels of hemoglobin and platelets were (10.1±3.3, 9.7±1.7, 11.9±0.6), (77.6±17.8 , 77.2±16.7, 283.4±37.2)

respectively. There were significantly higher s. ALT, s. AST, s. bilirubin, INR, PT, s.AFP and significantly lower s.albumin concentration between HCC and LC groups when compared to healthy control group. HCC showed significantly higher concentration of serum alpha-fetoprotein when compared to LC group. Otherwise, no significant differences were found in liver function tests between both groups.

Also, there was a highly statistically significant difference between studied groups as regard fatty acid binding protein-1 level it was significantly higher in LC and HCC when compared to control groups. Moreover, it was higher in HCC when compared to LC groups ranged from (107-1224 ng/l, 48-981ng/l and 34-120 ng/l) respectively.

As regard ultrasonographic examination among LC and HCC groups:

Narrower portal vein diameter, as well as portal vein thrombosis were significantly associated with HCC when compared to LC groups with mean values(9.6±3.1,13.3±2.2) respectively. Otherwise no significant differences were found in liver size, spleen and ascites grades between HCC and LC groups

As regard CT Criteria of hepatic focal lesions in all studied HCC cases:

(87.5%) of focal lesions were single and (12.5%) were multiple. They were located mostly in right lobe in (80%). As regarding size 90% of them were more than 3 cm and 92.5% of them were hypodense in echogenicity.

In the ROC curve Fair AUC for FABP-1 (AUC = 0.715, p=0.001). Best cut off values were 214 ng/L at which, sensitivity was 60%, specificity was 77.5%, PPV was 72.7%, NPV was 66%

Table (1): Comparison of clinical data (present history and clinical examination) among LC and HCC groups

	Group I (HCC)		Group II (LC)		P
	N=40		N=40		
	N	%	N	%	
Abdominal pain	23	57.5	19	47.5	0.370 ^C
Abdominal discomfort	32	80	34	85	0.556 ^C
Weight loss	12	30	1	2.5	0.001 ^C
History of abdominal pain	26	65	25	62.5	0.816 ^C
Bleeding	15	37.5	14	35	0.816 ^C
History of ascites	24	60	33	82.5	0.026 ^C
Encephalopathy	7	17.5	14	35	0.075 ^C
Fever	5	12.5	6	15	0.745 ^C
Sclerotherapy	6	15	6	15	1.000 ^C
Band ligation	17	42.5	16	40	0.820 ^C
Pallor	17	42.5	23	57.5	0.180 ^C
Jaundice	21	52.5	29	72.5	0.065 ^C
	9	22.5	19	47.5	
Hepatic encephalopathy	31	77.5	9	22.5	0.003 ^F
	0	0	1	2.5	
	0	0	1	2.5	
Flapping tremors	8	20	14	35	0.133 ^C
Clubbing	3	7.5	0	0	0.241 ^F
LL edema	26	65	36	90	0.007 ^C

C : chi square test F: Fisher exact test

Table (2): Comparison of laboratory investigations among studied groups.

		Group I	Group II	Group III	P¹	P²	P³	P⁴
		(HCC)	(LC)	(Control)				
		N=40	N=40	N=20				
HB(g/dL)	mean±SD	10.1±3.3	9.7±1.7	11.9±0.6	0.005 ^A	0.001 ^T	0.009 ^T	0.428 ^T
WBCs	mean±SD	7.8±1.2	5.8±1.6	6.4±1.3	0.322 ^A	0.721 ^T	0.390 ^T	0.139 ^T
(X10⁹/L)								
Platelets	mean±SD	77.6±17.8	77.2±16.7	283.4±37.2	<0.001 ^A	<0.001 ^T	<0.001 ^T	0.974 ^T
(x10⁹/L)								
FBG	mean±SD	93±30.1	118.4±32.6	85.8±8.1	0.205 ^A	0.107 ^T	0.641 ^T	0.086 ^T
(mg/dL)								
Creatinine	mean±SD	1.2±0.4	1.2±0.3	0.8±0.1	0.213 ^A	0.104 ^T	0.113 ^T	0.645 ^T
(mg/dL)								
ALT (I/U)	mean±SD	48.3±12.2	52.2±15.5	25.6±2.7	0.013 ^A	0.004 ^T	0.015 ^T	0.597 ^T
AST (I/U)	mean±SD	66.7±20.8	65.4±15.2	24.8±6.1	<0.001 ^A	<0.001 ^T	<0.001 ^T	0.872 ^T
Bilirubin	Median	2	3	0.9	0.001 ^K	<0.001 ^M	0.001 ^M	0.652 ^{T^M}
(mg/dL)	min-max	1-17	1-10	0.8-1.3				
Albumin	mean±SD	2.8±0.7	2.4±0.6	4.4±0.5	<0.001 ^A	<0.001 ^T	<0.001 ^T	0.213 ^T
(g/dL)								
INR	mean±SD	1.6±0.5	1.5±0.5	1±0.2	<0.001 ^A	<0.001 ^T	<0.001 ^T	0.500 ^T
PT (s)	mean±SD	16.7±3	15.9±2.3	12.4±0.5	<0.001 ^A	<0.001 ^T	<0.001 ^T	0.141 ^T
AFP	Median	268	7.5	0.4	0.012 ^K	<0.001 ^M	<0.001 ^M	0.002 ^M
(ng/mL)	min-max	1-13588	1-62	0.05-5				
FABP-1	Median	260.5	171.5	40				
(ng/L)	Minimum	107	48	34	<0.001 ^K	<0.001 ^M	<0.001 ^M	0.001 ^M
	maximum	1224	981	120				

M: Mann Whitney K: Kruskal Wallis test. T: student t test A: ANOVA

Table (3): Comparison of ultrasonographic examination among LC and HCC groups.

		Group I (HCC) N=40		Group II (LC) N=40		P
		N	%	N	%	
Liver size	Enlarged	9	22.5	2	5	0.193 ^F
	Average	23	57.5	19	47.5	
	Shrunken	8	20	9	22.5	
liver texture	Normal	0	0	0	0	0.107 ^F
	Coarse	17	42.5	13	32.5	
	Cirrhotic	20	50	27	67.5	
Spleen	Normal	10	25	4	10	0.139 ^F
	Splenomegaly	30	75	35	87.5	
Ascites	Removed	0	0	1	2.5	<0.001 ^C
	Absent	13	32.5	1	2.5	
	Present	27	67.5	39	97.5	
Ascites grades	minimal	5	12.5	15	37.5	0.179 ^C
	Moderate	14	35	13	32.5	
	tense	8	20	11	27.5	
PV patency	Patent	30	75	40	100	<0.001 ^C
	Thrombosis	10	25	0	0	
PV diameter (mm)	mean±SD	9.6±3.1		13.3±2.2		<0.001 ^T

C : chi square test F: Fisher exact test T: student t test

Table (4): CT Criteria of hepatic focal lesions in all studied HCC cases .

		Group I (HCC) N=40	
		N	%
Multiplicity	Single	35	87.5
	multiple	5	12.5
Site	Right lobe	32	80
	Left lobe	3	7.5
	Both lobes	5	12.5
Size (cm)	<2	2	5
	2-3	2	5
	>3	36	90
Echogenicity	Hyperdense	1	2.5
	Hypodense	37	92.5
	Isodense	2	5
Homogeneity	Non homogenous	12	30
	Homogenous	28	70
Positive rapid wash out		40	100
Arterial phase enhancement		40	100

Table (5): Diagnostic performances of FABP for discrimination between HCC and LC cases.

	AUC	95% CI	P ¹	Cut off	Sensitivity (%)	Specificity (%)	PPV (%)	NPV (%)
FABP-1	0.715	0.603-0.827	0.001	214	60	77.5	72.7	66

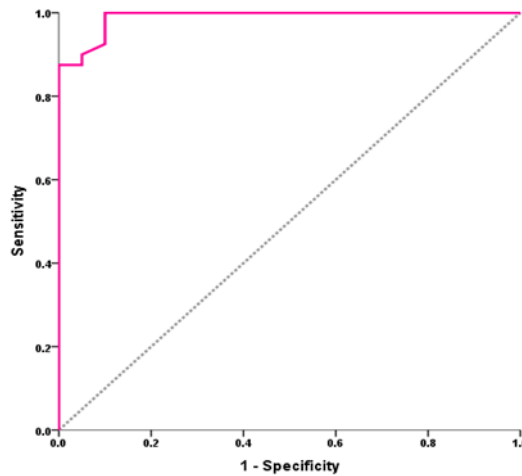


Figure (1): ROC curve of serum FABP for discrimination between HCC cases and control group.

Discussion

In Egypt, liver cancer counts for 11.75% of the malignancies of the digestive organs and 1.68 % of the total malignancies. HCC forms 70.48% of all liver tumors among Egyptians and it is considered the main complication of cirrhosis, and represents a growing incidence in Egypt, which may be due to a shift in the relative importance of (HBV) and HCV as primary risk factors, and advancements in screening programs and

diagnostic materials (8). The present history and clinical examination were summarized in Table 1. HCC was significantly associated with weight loss, while LC was significantly associated with history of ascites. Abdominal pain was found in 57.5% of HCC cases .These results were in agreement with (9) who stated that pain in HCC patients is a frequent complaint and also, (10) found that new onset abdominal

pain in a cirrhotic patient should raise the possibility of HCC. Otherwise, no significant differences were found between the two groups.

Hemoglobin concentration and platelet count were significantly lower in LC and HCC when compared to healthy control group as mean levels of Hemoglobin and platelets were (10.1±3.3, 9.7±1.7, 11.9±0.6), (77.6±17.8, 77.2±16.7, 283.4±37.2) respectively. This was in agreement with (11) who demonstrated that most of patients with HCC were anemic when they are first seen, although severe anemia is rare and should suggest the possibility of intraperitoneal bleeding. Most cases of HCC are accompanied by liver cirrhosis. Liver cirrhosis could ultimately lead to portal hypertension and hypersplenism and cause a subsequent decrease in platelet count (12).

There were significantly higher ALT, AST, bilirubin, INR, PT, AFP and significantly lower albumin concentration between HCC and LC groups when compared to healthy control group. Significant marked increase in bilirubin, mild increase in AST and ALT in HCC patients was explained as being due to the impaired ability of damaged and necrosed hepatocytes to release conjugated bilirubin in addition to the leakage of

hepatic enzymes through its inflamed wall (13). Moreover, serum albumin was significantly lower and PT and INR were significantly higher in HCC patients. This could be attributed to the impaired synthetic ability of the liver for albumin and vitamin K, the co-factor of extrinsic coagulation pathway (14, 15).

FABP-1 level was significantly higher in LC and HCC when compared to control groups. Moreover, it was higher in HCC when compared to LC groups, this was in agreement with (16) who found that serum FABP-1 levels were 2-fold higher in the presence of HCC compared with the absence of HCC.

This also came in agreement with a study where it was reported that FABP-1 was significantly up-regulated in HCC patients with and without cirrhosis. Moreover, in the cirrhosis patients, high FABP-1 expression was related to a higher risk of poor survival (17)

As regard ultrasonographic examination

about 92.5% of the patients with HCC had sonographic evidence of liver cirrhosis. This was in agreement with other studies, who stated that, in all parts of the world HCC frequently coexists with cirrhosis

(18,19) and with another study that stated that liver cirrhosis is a well-known risk factor for the development of HCC (20). This is supported also by other researchers who documented that cirrhosis of the liver is present in 60 to 100% of patients with HCC (21)

Ten patients (25%) in this study were found to have portal vein thrombosis. This finding was in agreement with a study which reported portal vein thrombosis in (11.9%) of cases (22). A higher finding was reported by others who reported (28.2%), (18%) of cases had portal vein thrombosis respectively (23, 24).

In the current study different patterns of focal lesions as regards number, echogenicity and location were detected with no specific predilection. Single hepatic focal lesions were detected in 87.5% of patients and multiple focal lesions in 12.5% of patients. 92.5% of the focal lesions were of hypodense pattern. This was reported before, that the ultrasonographic pattern was hypodense only in 57.5% of patients, (25) and only in 54.1% of patients (26).

Most of the HCC lesions (80%) were found in the right lobe, (7.5%) in the left lobe of the liver and 12.5% were detected in

both lobe. This was in agreement with a study which reported that HCC occurs more frequently in the right lobe of the liver either as a solitary mass or as multiple nodules (27, 28). This may be due to the large size of the right lobe of the liver which is 6 times larger than the left lobe

Concerning tumor size, in the present study (90%) of HCC cases were >3cm and this was not in agreement with other studies who reported that the tumor size tends to be large >5cm in 85.1% and 46.3% of cases respectively, this difference may be due to large sample size in their studies, progression in diagnostic imaging modalities over years (19, 11)

Analysis of ROC curve of serum FABP-1 revealed that FABP-1 at cut off values (214 ng/L) sensitivity was 60%, specificity was 77.5%, PPV was 72.7, NPV was 66% and AUC = 0.715. This came in agreement with study where it was reported that when a cut-off value was 29,0 ng/mL for FABP-1, sensitivity and specificity were 75 and 100%, respectively. Positive and negative predictive values for FABP-1 were 100 and 78%, respectively (3). These results indicate that serum FABP-1 can be used as a new diagnostic marker to detect liver injury and can be used in the diagnosis of chronic

liver diseases, including those coupled with HCC and so, serum FABP-1 can be used as a prognostic factor in chronic liver disease, as LC, and prognostic factor for survival in patients presenting with concomitant HCC.

The results of the current study indicated that serum FABP-1 is a promising sensitive and specific tumor marker that could be added to the current standard tests for diagnosis of HCC and considered as the only predictor for multiplicity which indicate poor prognosis.

References

1. Heimbach Jk, Kulik LM, Finn RS, Sirlin CB, Abecassis MM And Roberts LR (2018): Aasld Guidelines For The Treatment Of Hepatocellular Carcinoma. *Hepatology*; 67 (1): 358-380.
2. Yang J, Li J, Dai W, Wang F, Shen M, Chen K, et al.,(2015): Golgi protein 73 as a biomarker for hepatocellular carcinoma: A diagnostic meta-analysis. *Exp Ther Med*; 9(4):1413-1420.
3. Akbal E, Köklü S , Koçak E, Çakal B, Güneş F And Başar O.(2013): Liver Fatty Acid-Binding Protein Is A Diagnostic Marker To Detect Liver Injury Due To Chronic Hepatitis C Infection. *Official Journal Of The Institute Mexicano Del Seguro Social*; 44 (1): 34.38.
4. Wang G, Bonkovsky HL, De Lemos A And Burczynski J.(2015): Recent Insights Into The Biological Functions Of Liver Fatty Acid Binding Protein 1. *J.Lipid Res.*; 56:2238-2247.
5. Furuhashi M And Hotamisligil GS (2008): Fatty Acid-Binding Proteins:Role In Metabolic Diseases And Potential As Drug Targets. *Nat Rev Drug Disco*; 7(6):489–503.
6. Li J, Dong L, Wei D, Wang X, Zhang S , Li H et al ., (2014): Fatty Acid Synthase Mediates The Epithelial-Mesenchymal Transition Of Breast Cancer Cells. *Int J Biolsci* ; 10:171–180.
7. Ku CY, Liu YH, Lin HY, Lu SC And Lin JY.(2016): Liver Fatty Acid-Binding Protein (L-Fabp) Promotes Cellular Angiogenesis And Migration In Hepatocellular Carcinoma. *Oncotarget.*;7(14):18229-18245
8. Holal NS, El-azab DS and Aiad HA (2015):Hepatocellular carcinoma in Egypt.epidemiologicalandhistopathologicalproperties .*Menoufia Medical Journal* ; 28 (3) :718-724.
- 9.9.Sherlock S and Dooley J (2002): Diseases of the liver and biliary system. 11th ed. , Blackwell S.C. , Oxford London, Eninburgh ; 31: 537 – 561.
10. Sleisenger MF and Fordtran BF (2006): Hepatic tumors and cysts. In: Sleisenger MF and Fordtran BF (eds): *Gastrointestinal and liver disease* (8th edition), published by Philadelphia: W.B. Saunders ; 2(91) : 2007-2028..

11. Atta MM, EL Masry SA, Abdel Hameed M, Baiomy HA and Ramadan NE (2008) :Value of serum anti-p53 antibodies as a prognostic factor in Egyptian patients with hepatocellular carcinoma. *Clinical Biochemistry*; 41: 1131-1139
12. Kew MC (2002):Hepatic tumors and cysts.In:*Gastrointestinal and Liver Disease*. Feldman M, Friedman LS and Sleisenger MH (eds.), WB Saunders, Philadelphia ;56 (8) : 1579.
13. Bolondi L , Sofia S , Siring S, Gaiani S, Casali A, Zironi G, et al., (2001): Surveillance Programme of cirrhotic patients for early Diagnosis and treatment of hepatocellular carcinoma: a cost Effectiveness analysis. *Gut*; 48: 251-259.
14. Franca A V , Elias JJ , Lima B L,Martinelli A and Carrilho FJ (2004): Diagnosis, staging and treatment of hepatocellular carcinoma. *Braz. J. Med. Biol. Res.*; 37: 1689-1705.
15. Grioco A,Pompili M and Caminiti G (2005): Prognostic factors for survival in patients with early intermediate hepatocellular carcinoma undergoing non- surgical therapy: comparison of Okuda, CLIP, and BCLC staging systems in a single Italian center. *Gut.*; 54: 411-418.
16. Eguchi A, Hasegawa H, Iwasa M, Tamai Y, Ohata K, Oikawa T et al ., (2019): Serum Liver-Type Fatty Acid-BindingProtein Is aPossible Prognostic Factor in Human Chronic Liver Diseases From Chronic Hepatitis to Liver Cirrhosis and Hepatocellular Carcinoma *HepatologyCommunications* ; 39(6):825-830.
17. Heindryck and Gerwins P (2015):Targeting the tumor stromainhepatocellular carcinoma. *World J Hepatol* ; 7:165–176.
18. El-Shenawy S, El Sabawi and Sheble N (2012) : Diagnostic Role of Serum Glypican - 3 as a tumor Marker for Hepatocellular Carcinoma. *Nature and Science*; 10(4): 32-38.
19. El-Zayadi AR, Badran HM and Barakat EM (2005): Hepatocellular carcinoma in Egypt: a single center study over a decade. *World J. Gastroenterol.* ; 11(33): 5193-5198.
20. Pang Q, Qu K and Zhang JY (2015): The Prognostic Value of Platelet Count in Patients with Hepatocellular Carcinoma, A Systematic Review and Meta-Analysis, *Medicine (Baltimore).* ; 94(37): 1431.
21. Panteghini M (2006): Enzymes. In: Teitz fundamentals of clinical chemistry, Burtis CA, Ashwood ER , Bruns DE, saunders WB, Philadelphia; (6) : 317-337.
22. LaffanM (2006): Laboratory control of anticoagulant, thrombolytic and anti-platelet therapy. In: Dacie and Lewis practical hematology, S. M. Lewis, B. J. Bain, I. Bates (Eds). Churchill livingstone co. philadelphia ; 10 :465-523.
23. Johnson M (2006) : Amino acids and proteins. In: Teitz fundamentals of clinical chemistry ;(6) : 286-317.
24. Zheng S, Lin J, Attie AD, Keller MP, Bernlohr DA, BlanerWS,et al., (2018): Perilipin 5 and liver fatty acid binding protein function to restore quiescence in mouse hepatic stellate cells. *J Lipid Res*;59:416-428.

25. Darwish AG (2006): Assessment of Clinical Significance of Serum Squamous Cell Carcinoma Antigen in Patients with Liver Cirrhosis and Hepatocellular Carcinoma. M.Sc.Thesis, Tropical medicine, Cairo University ;45(4):167-72.
26. Solmi L, Premerano M and Gandolfi L (1996): Ultrasound follow up of patients at risk of HCC: results of a prospective study on 360 cases. AJG;91:1189-94.
27. Kuntz E and Kuntz HD (2006): Malignant liver tumours. In Hepatology principles and Practice, second edition, published by Springer Verlag, Germany ;2: 771- 809.
28. Portmann B (2004): Liver allograft pathology and biopsy interpretation. VerhDtschGesPathol; 88(12):29-38

To cite this article: Reda M. Albadawy, Badawy A. Abd El-Aziz, Eman G. Behiry, Maha E. Azzam. Assessment the Association of Fatty Acid Binding Protein 1 with Hepatocellular Carcinoma. BMFJ. 2021; 38(1): 1-13. DOI: 10.21608/bmfj.2020.19563.1164