

Comparative Study on the Effect of Silver Nanoparticles versus Silver Sulfadiazine in Diabetic Wound Healing in Albino Rat: a Histological Study

Heba Mohamed Fawzy, Amany El Shawarby, Nagwa Kostandy Kalleney, Safaa M. Shaker

Histology and Cell Biology Department, Faculty of Medicine, Ain Shams University

Corresponding author: Heba Mohamed Fawzy, email:h.dr87@yahoo.com

Abstract

Background: the impairment of wound healing in the diabetic patients is an important clinical problem affecting millions of patients worldwide. This significant health care problem still lacks effective therapy. The ideal wound dressing is resistant to external forces and pathogens. It reduces patient discomfort and achieves good cosmetic results. **Aim of the work:** this study aimed to compare the effect of silver nanoparticles versus silver sulfadiazine on diabetic wound healing in the adult albino rat. **Material and Methods:** twenty adult female albino rats were included in this study. The animals were categorized into four groups, 5 rats each: **group I** (control). **Group II** (untreated diabetic wound): diabetic rats that left untreated for 15 days of wound excision. **Group III:** diabetic rats in which silver sulfadiazine cream was applied on the wound daily for 15 days after thin skin excision. **Group IV:** diabetic rats in which nanosilver-ointment was applied on the wound daily for 15 days after thin skin excision. At the end of the experiment, the specimens were taken and processed for histological and immunohistochemical studies. Morphometric and statistical studies were carried out. **Results:** examination of thin skin sections of nanosilver treated group revealed continuous epidermis with differentiated keratinocytes with proliferating basal layer. The dermis showed increased collagen deposition, decreased p53 and increased VEGF expression compared to SSD treated group.

Conclusion: silver nanoparticles could be more effective than silver sulfadiazine in treatment of the diabetic wound.

Key words: silver nanoparticles, silver sulfadiazine, diabetes, wound

Introduction

Wound healing is a dynamic process consisting of four continuous, overlapping and precisely programmed phases. The events of each phase must happen in a precise and regulated manner. Interruptions or prolongation in the process can lead to delayed wound healing or a non-healing chronic wound. In adult humans, optimal wound healing involves the following events: (1) rapid hemostasis, (2) appropriate inflammation, (3) proliferative phase and (4) remodeling phase^[1]. Diabetes affects hundreds of millions of people worldwide. Diabetic individuals exhibit a documented impairment in the healing of acute wounds. Moreover, this population is prone to develop chronic non-healing diabetic foot ulcers (DFUs), which are estimated to occur in 15% of all persons with diabetes. Diabetic foot ulcers are a serious complication of diabetes and precede 84% of all diabetes related lower leg amputations^[2]. Topical treatment with silver sulfadiazine cream (SSD) is regarded as the gold standard for prevention and treatment of burn wound infection. It has prophylactic and therapeutic efficacy to control wound colonization by

organisms that may delay the healing machinery. It is assumed that these excellent antimicrobial properties are a result of the combination of silver and sulfadiazine^[3]. Nanoparticles (NPs) defined as particles having diameter that range from 1 to 100 nm. Silver NPs (Ag NPs) have been shown to possess unusual physical, chemical and biological properties^[4]. A number of factors affect the antimicrobial activity of nanoparticles, such as shape, size of metal particles which influence the surface properties of the particles and the stabilizer and the pH of the suspension^[5]. **Wong et al.** noticed rapid healing and improved cosmetic appearance occurred in a dose dependent manner. They showed that silver nanoparticles exert positive effects through their antimicrobial properties, reduction in wound inflammation, and modulation of fibrogenic cytokines^[6].

Material and Methods: twenty adult female albino rats of average weight 200-250 grams were included. The animals were divided into four groups: **group I (Control group):** included 5 rats that received only food and water.

Group II (Untreated diabetic wound):

It included 5 diabetic rats that left untreated for 15 days of wound excision.

Group III (Diabetic wound treated with silver sulfadiazine): it included 5 diabetic rats in which silver sulfadiazine cream was applied on the wound daily for 15 days after excision.

Group IV (Diabetic wound treated with silver nanoparticles):

It included 5 diabetic rats in which nanosilver-ointment was applied on the wound daily for 15 days after excision.

Induction of diabetes:

Streptozotocin (STZ) powder supplied by Sigma-Aldrich was used for induction of diabetes. Rats rendered diabetic by a single intra-peritoneal (i.p.) injection of STZ (40mg/kg body weight) dissolved in 1ml of 0.05 M citrate buffer PH 4.5^[7].

Streptozotocin injected rats were allowed to drink 10 % glucose solution for 24 hours following injection to overcome drug induced hypoglycemia^[8].

The wound model:

In each rat under general anesthesia using pentobarbital, the dorsal hair was shaved and 1cm diameter full thickness skin excision was generated in the mid back region using disposable scalpel. The wound was then cleaned with with povidone-iodine^[9].

Silver sulfadiazine dressing

1% silver sulfadiazine cream (Dermazin, Sanoz company) was used. The dressings were applied after silver sulfadiazine cream application and the animals were bandaged^[10].

The silver nanoparticles preparation:

Silver nanoparticles was supplied by Nano stream, 6th october of 20 nm diameter in the form of 10 ml solution.

Ten ml of silver nanoparticle were mixed and homogenized with 5 gm of ointment base (Faculty of Pharmacy, Cairo University).

Histological and immunohistochemical studies:

Paraffin sections of 5 µm were obtained and stained with hematoxylin and Eosin to show the histological details and Masson's trichrome stain to detect collagen fibers. Immuno histochemical staining of P53 to detect apoptosis^[11] and vascular endothelial growth factor (VEGF) to detect proliferation^[12] were done.

Gene expression analysis was done to detect scar formation by reverse transcription Syber green based qPCR for mRNA extraction of TGF-B from paraffin blocks^[13].

Results

Examination of thin skin sections of the control group showed the two layers of the skin: the epidermis and dermis. The epidermis is consisted of stratified squamous keratinized epithelium. The dermis is consisted of the connective tissue .It was divided into two layers without a sharp demarcation between them: a superficial thin papillary layer and a deep thick reticular layer. Hair follicles and sebaceous glands were found in the dermis. Deeper to the dermis hypodermis was found. It consisted of lobules of adipose tissue with connective tissue septa in between (**Figs. IA, IB**).Masson's trichrome stained sections showed thin interlacing bundles of collagen in the papillary dermis while the reticular layer is consisted of coarse, wavy bundles of collagen (**Fig. IC**). Immuno-histochemical stain of P53 showed nuclear positive reaction in few dermal cells of some hair follicle cells (**Fig.ID**).Immuno-histochemical stain of VEGF showed positive brownish reaction in the cytoplasm of many dermal cells mostly fibroblasts and in the cytoplasm of superficial layer of keratinocytes in some areas .Inset showed higher magnification of fibroblasts reaction (**Fig. IE**). Examination of thin skin sections of group II showed loss of the epidermis at the wound area. The scab was widely separated from the wound. An epidermal tongue could be seen projecting beneath the scab (**Fig. IIA**). The granulated tissue appeared fibrous. It contained mononuclear inflammatory cells, congested blood vessels and spindle shaped cells mostly proliferating fibroblasts with appearance of many fat cells (**Fig. IIB**).Epidermal tongue appeared at the wound edge .It contained many spindle shaped migrating cells. Granulated tissue was seen infiltrated with mononuclear inflammatory cells and contained extravasation of blood cells. (**Fig. IIC**).

Examination of Masson's trichrome stained sections showed the granulated tissue was studied by mononuclear inflammatory

cells and fine collagen fibers (**Fig. IID**). Immuno-histochemical stain of P53 showed strong positive nuclear reaction in the different mononuclear inflammatory cells in the granulated tissue. Inset showing higher magnification of this positive reaction (**Fig.IIE**). VEGF Immuno-histochemical stain showed weak reaction in the granulated tissue at the wound area (**Fig. IIF**).

Examination of thin skin sections of **group III** showed newly formed thin epidermis covering the wound area (**Fig. IIIA**). The newly formed epidermis was formed of few layers of flattened, undifferentiated cells. Also there was debris of dead cells of the overlying scab. The dermis was filled of mononuclear inflammatory cells, spindle fibroblasts with few dilated blood vessels (**Fig. IIIB**). Examination of Masson's trichrome stained sections at the wound area showed collagen fibers and fibroblasts with mononuclear inflammatory cells inbetween(**Fig. IIIC**). Immuno-histochemical stain of P53 showed strong positive nuclear reaction in different cells of the newly formed epidermis and dermis as compared to control group (**Fig. IIID**). VEGF Immuno-

histochemical stain showed positive reaction in the cytoplasm of many dermal cells and in the endothelium of blood vessel (**Fig. IIIE**) as compared to **group II**. Examination of skin sections of **group IV** showed that the site of the wound was totally covered by epidermis (**Fig. IVA**). The epidermis covering the wound area showed an apparent increase in its thickness as compared to **group III** with crowdedness of cells at the basal layer of epidermis. The underlying dermis showed abnormal arrangement of collagen at the site of previous wound. It was formed of interlacing collagen fibers. Also, there was cellular infiltration at the dermis, also there was spindle shaped cells mostly fibroblasts (**Fig. IVB**). Examination of Masson's trichrome stained sections at the wound site, the dermis was composed of fine interlacing fibers (**Fig. IVC**). Immuno-histochemical stain of P53 showed weak positive nuclear brownish reaction in few dermal cells compared to untreated group after fifteen days (**Fig.IVD**). VEGF Immuno-histochemical stain showed positive brownish reaction in the cytoplasm of keratinocytes and some dermal cells (**Fig. IVE**).

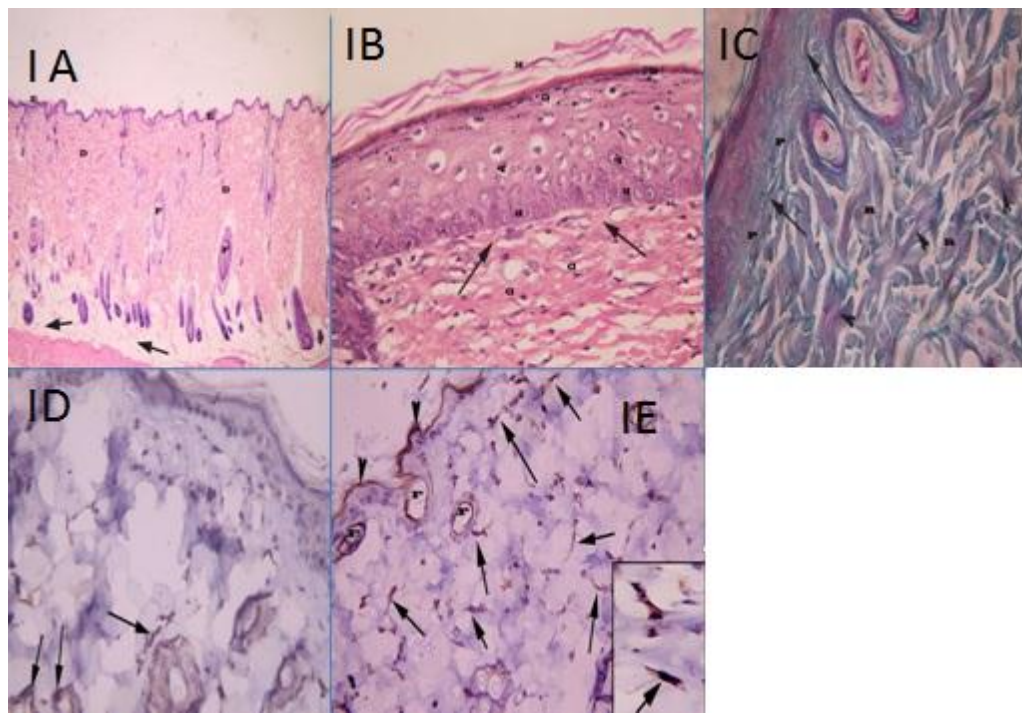


Fig. IA: a photomicrograph of a section in the thin skin of a control rat, showing thin epidermis (E) and the connective tissue of the

dermis (D). Notice the presence of hair follicles (F) and subcutaneous fatty tissue (↑)(H&Ex40).

Fig IB: a photomicrograph of a section in the thin skin of a control rat, showing basal layer (B), Prickle cell layers (P), granular layers with basophilic granules (G) and the horny layers (K) of epidermis. Notice: fine collagen fibers (↑)in the papillary dermis (D) (H&E X400).

Fig. IC: a photomicrograph of a section in the thin skin of a control rat, showing the collagen fibers content of the dermis. The collagen fibers in the papillary dermis (P) appear as thin interlacing bundles (↑) while those in the reticular dermis (R) appear as coarse, wavy bundles(▶)(Masson's trichrome stain X400).

Fig.ID: a photomicrograph of a section in the thin skin of a rat of control group showing p53 positive reaction (↑) in few dermal cells and some hair follicle cells (Immunostaining of P53&Hx X400).

Fig. IE : a photomicrograph of a section in the thin skin of a rat of control group showing VEGF positive reaction in the superficial layers of keratinocytes of epidermis(▶),hair follicles(F) and the cytoplasm of fibroblasts (↑).Inset showing higher magnification of fibroblasts reaction(↑)(Immunostaining of VEGF&Hx X400, Inset X1000).

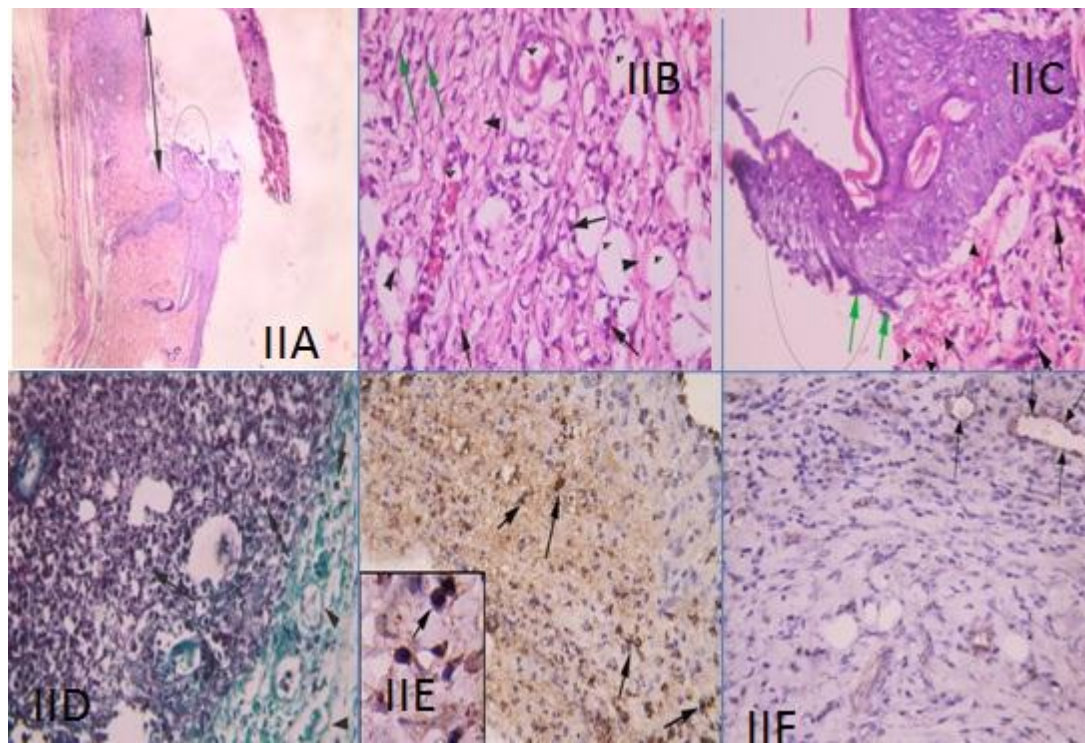


Fig. IIA : a photomicrograph of a section at the junction of wound and intact skin of a rat of group II ,showing absence of the epidermis in the wound area(↔) with apparent epidermal tongue(O).Notice: the scab(S) is wide separated from the wound area H&E x40).

Fig.IIB: a photomicrograph of a section at the wound area of a rat of **group II** showing the granulation tissue formed of fine collagen fibers(▶) ,numerous mononuclear inflammatory cells(↑) and dilated congested blood vessels(v).Notice appearance of many fat cells(F) and spindle shaped cells mostly proliferating fibroblasts(green↑) (H&Ex400).

Fig. IIC: a photomicrograph of a section at of the wound edge of a rat of group II showing

epidermal tongue (O) projecting from the epidermis . The tongue contains many spindle shaped migrating cells (green arrow).Notice the granulation tissue containing mononuclear inflammatory cells (↑) and extravasted blood cells(▶)(H&E X400).

Fig.IID: a photomicrograph of a section at the wound area of a rat of group II showing numerous mononuclear inflammatory cells (↑) and fine collagen fibers (▶)in the granulated tissue (Masson's trichrome stain X400).

Fig. IIE: a photomicrograph of a section at the wound area of a rat of group II showing many p53 positive cells (↑) in the granulation tissue.

Inset showing higher magnification of some positive cells (↑) Immunostaining of P53&Hx X400, insetx1000).

VEGF expression in endothelium of blood vessels(↑) of the granulation tissue (Immunostaining of VEGF &Hx X400) .

Fig.III F : a photomicrograph of a section at the wound area of a rat of group II showing weak

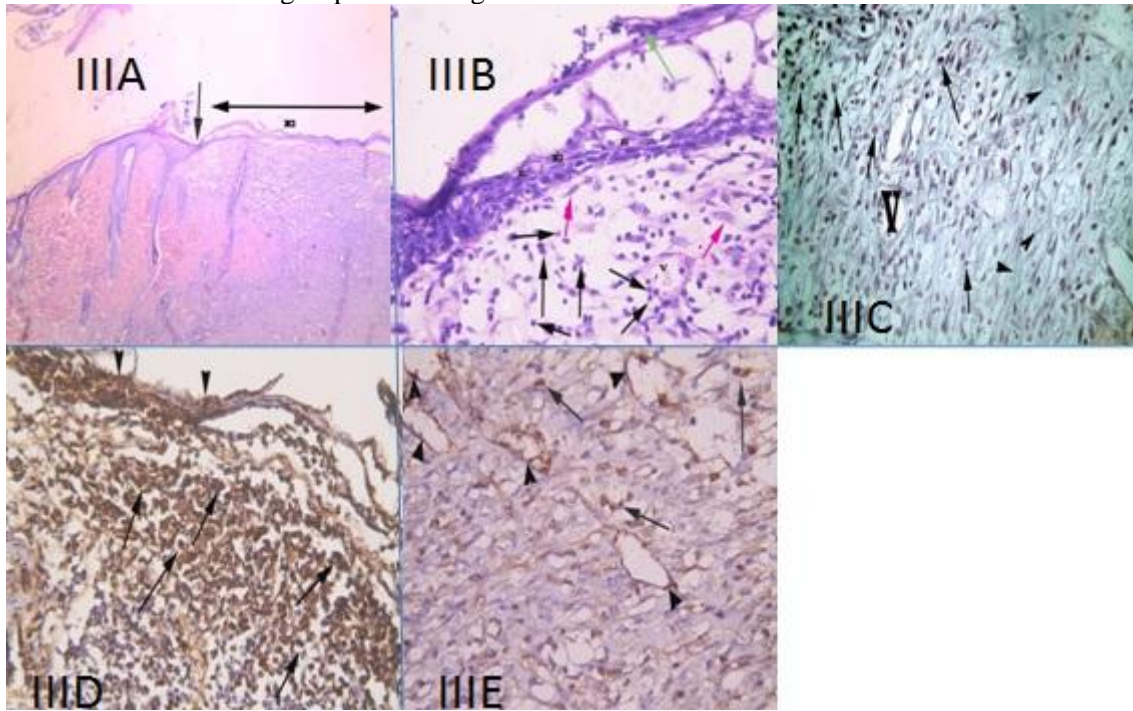


Fig. IIIA : a photomicrograph of a section at the junction(↑) of the wound and intact thin skin of a rat of group III showing wound area(↔) covered by thin epidermis(E) (H&EX40).

Fig.IIIC : a photomicrograph of a section at the wound area of a rat of group III showing collagen fibers (▶) around blood vessels(v) and mononuclear inflammatory cells(↑)(Masson's trichrome stainX400).

Fig.IIIB : a higher magnification of the previous section at the wound area showing thin newly formed epidermis(E) formed of few layers of flattened non differentiated cells with overlying remnant of scab(green ↑).The dermis contains mononuclear inflammatory cells(↑) mostly neutrophils, while some cells appear spindle in shape mostly fibroblasts(pink ↑).Notice dilated blood vessel(V) (H&E X400)

Fig. IIID : a photomicrograph of a section at the wound area of a rat of group III showing strong p53 positive reaction (↑)in the dermis and in the newly formed epidermis(▶) (Immunostaining of P53&Hx X400).

Fig.IIIE: a photomicrograph of a section at the wound area of a rat of group III showing numerous VEGF positive reaction in the endothelium of blood vessels(▶) and in dermal cells(↑)(Immunostaining of VEGF+Hx X400).

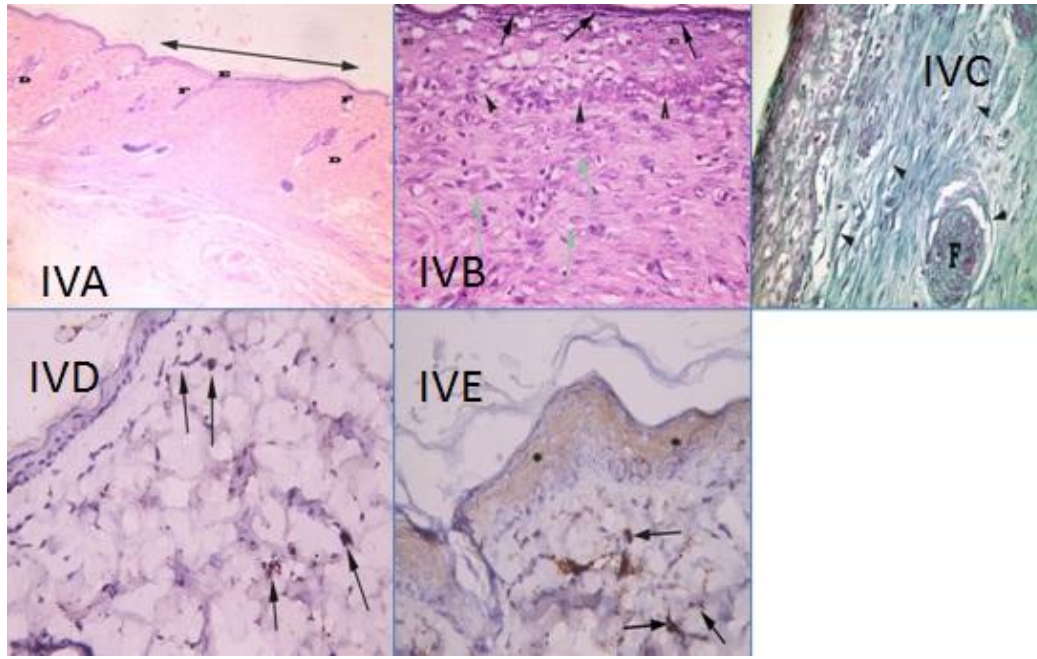


Fig.IVA : a photomicrograph of a section at the previous wound area(↔) of a rat of group IV showing continuous homogenous epidermis (E) and apparent increase of hair follicles(F) as compared to group II(H&E X40).

Fig. IVB : a higher magnification of the previous section showing loss of demarcation between dermis and epidermis with crowdedness of cells in the basal epidermis(▲). There's an apparent increase in the epidermal thickness (E) with apparent basophilic granules in granular layer(↑). The dermis is highly cellular, there are many spindle shaped cells with oval vesicular nuclei(green ↑) (H&E X400).

Fig.IVC : a photomicrograph of a section at the site of previous wound of a rat of group IV showing that the collagen fibers content is

composed of fine interlacing fibers(▲). Notice the presence of hair follicle(F)(Masson's trichrome stain x400).

Fig.IVD : a photomicrograph of a section at the wound area of a rat of group IV showing weak P53 positive nuclear reaction (↑)in few cells in the dermis (Immunostaining of P53&Hx X400).

Fig.IVE: a photomicrograph of a section at the wound area of a rat of group IV showing VEGF positive reaction in the cytoplasm of keratinocytes(*) and in some dermal cells(↑) (Immunostaining of VEGF&Hx X400).

Morphometric and Statistical Results

Table 1: showing differences in the mean of area percentage of collagen fibers, p53, VEGF and Mean TGF-B

Groups	Control(I)	II	III	IV
Mean area percentage of collagen fibers	26.78±9.2	9.09± 1.50 (■)(♣) (×)	24.78± 8.1	26.8± 5.08
Mean area percentage of P53	0.826± 0.978	3.38± .934 (■)(♣)(×)	2.79± .814 (■)(×)	0.889± .66
Mean area percentage of VEGF	2.76± 1.38	0.985± .307 (■)(♣)(×)	2.396± .636	3.289± .826
Mean TGF-B	0.362± 0.281	4.128± 0.132 (■)	1.894± 0 .021 (●)(■)	0.532±. 019 (●)(♣)

Values are means ± SD

(■) significant compared to group I (P < 0.05)

(♣)significant compared to group III(P < 0.05)

(×) significant compared to group IV(P < 0.05)

(●) significant compared to groupII (P < 0.05)

Discussion

The goal of skin wound treatment is the enhancement of wound closure and restoration of skin function with good cosmetic results. Loss of epidermis was detected in untreated diabetic rats after 15 days of wound induction (**Groups II**) The surface of the wound was covered by scab . Also in **groups II** separation of group of keratinocytes from epidermis at the edge of the wound occurred. These keratinocytes formed epidermal tongue or bud. Some keratinocytes of the tongue underwent epithelial mesenchymal transition(EMT) and started to migrate to the wound area ^[14].

Braiman-Wiksman et al. ^[15] stated that keratinocyte migration was independent of granulation-tissue formation and that it was the first step in normal healing . Moreover, **Nagato et al.** ^[16] stated that migration and proliferation of keratinocytes could occur from epidermis and from follicular bulge stem cells.

However, **Cianfarani et al.** ^[17] showed that stem cells in animals and patients with diabetes or chronic wounds were both deficient and defective. Regarding steps of granulation tissue formation, **group II** of the present study revealed an increase in fibrous content of granulated tissue . Appearance of fat cells was detected in the granulation tissue.

Schmidt and Horsley ^[18] recorded that adipocyte lineage cells were activated and function during skin wound healing. They found that adipocyte precursor cells proliferated and mature adipocytes repopulated skin wounds following inflammation and in parallel with fibroblast migration. They concluded that adipocytes were necessary for fibroblast recruitment and dermal reconstruction. So, fat cells could mediate fibroblast function during wound healing.

Neutrophil infiltration in the wound bed at **group II** was recorded. **Schultz et al.** ^[19] concluded that a lengthened inflammatory phase in diabetic mice caused an increase in the levels of proteases. The high levels of these chemicals caused damage to the ECM, which was critical for proper healing. These proteases also damaged the growth factors that were produced in the wound, leading to a chronic state. Immune staining of P53 showed significant increase in group II. **Schultz et al.** ^[20] stated that diabetic wounds were

characterized by senescent cell populations with impaired proliferative and secretory capacities, rendering them unresponsive to typical wound healing signals. Apoptosis signals are also involved in the regulation of collagen degradation by inducing collagenase activity. **Mishra et al.** ^[21] found that p53 binds to the promoter of the human type IV collagenase (matrix metalloproteinase 2) gene. They added that in a diabetic wound, apoptosis was increased throughout the healing process. Also **Shang et al.** ^[22] found that in diabetic patients the fibroblasts were defective due to decrease in their synthesis and increase in their apoptosis. Immune staining of VEGF showed significant decrease in group II. Also, **Abubakar et al.** ^[23] noticed absence of expression of VEGF in the untreated diabetic rats.

Smith et al. ^[24] demonstrated that dermal fibroblasts isolated from diabetic rodent exhibited a reduced rate of migration and increased MMP-9 activity.

The examination of SSD treated group (**Group III**) showed newly formed thin epidermis formed of flattened, undifferentiated keratinocytes covering the wound area. Similar results were detected by **Jiang and Huo,** ^[25] who reported that silver sulfadiazine (SSD) significantly reduced the period of epithelization of the wound in comparison with the diabetic control group. However, **Hassanzadeh et al.** ^[26] stated that Silver sulfadiazine treatment resulted in thin epidermis that lack differentiation (lack stratum corneum and stratum granulosum). Regarding the SSD effect on granulated tissue ,in the present study **group III** revealed granulation tissue with few mononuclear inflammatory cells ,numerous fibroblasts and collagen fibers, while in other specimen granulation tissue was filled with neutrophils and few collagen fibers and fibroblasts. Moreover, cytotoxicity of SSD was a matter of debate among investigators .Keratinocytes cytotoxicity could be the cause of delayed epidermal maturation as mature granulation tissue was apparent when complete epidermis had been formed^[27] . However, **Gomes et al.** ^[28] reported that silver sulfadiazine treatments for 14 days provided better organization of collagen fibers in relation to the untreated group. In the present study, the use of nanoparticles in the treatment of diabetic wound resulted in early closure. The

keratinocytes were arranged in their normal strata. Stratum granulosum was well developed with appearance of keratohyaline granules indicating maturation. **Wong *et al.***^[10] recorded increased rate of keratinocytes proliferation of SNP treated group. Similar results were detected by **Kwan *et al.***^[29] who found that topical application of silver nanoparticles accelerated the healing process, and led to better fibril alignments in healed skin. However signs of proliferative phase appeared in group IV in the form of proliferating basal cells of the hyperplastic epidermis. **Braiman-Wiksman *et al.***^[15] stated that the hyperplastic epidermis at the wound constitutes an essential component of the migrating cell pool which migrates to seal the wound gap. Their experiments demonstrated that this epidermal leading edge is composed mainly of cells with migratory properties rather than proliferating cells.

Braiman-Wiksman *et al.*^[15] recorded that 18 days post wound were needed for full differentiation of the newly formed epidermis as epidermal closure precedes all other parameters. However, matrix formation progresses considerably more slowly. The differentiation process appears to occur concomitantly with the dermal closure. This ensured good quality of wound regaining strength and elasticity of the skin. The dermis of skin of **group IV** showed hypercellularity. **Wong *et al.***^[10] stated that AgNPs was relatively non-toxic to fibroblasts, but could indeed drive the differentiation of fibroblasts into myofibroblasts, thereby help to accelerate wound bed contraction. Furthermore, silver nanoparticles could significantly decrease the production of hydroxyproline and collagen in the ECM. In the present study, VEGF was significantly increased in group IV more than control group. **Wong *et al.***^[6] found high VEGF expression in AgNPs treated diabetic wound and VEGF mRNA (messenger ribonucleic acid) levels were also maintained high especially in the early stage of wound healing. The reduction of collagen production in fibroblasts in late phase of wound healing by silver nanoparticles suggested a role in anti-fibrosis therapy, which could be useful in preventing and perhaps treating keloids and scars^[10]. The present study showed that TGF β was significantly decreased in diabetic skin

wound treated with SNPs examined after fifteen days compared to SSD and untreated groups. Similar results were recorded by **Hendi**^[30] who reported better cosmetic appearance was observed in animals treated with silver nanoparticles. They suggested that TGF β plays an important role in tissue fibrosis and post-injury scarring. They thought that lower levels of TGF β coincided temporally with increased levels of IFN-gamma until wound closure in the silver nanoparticles group. As IFN-gamma had been demonstrated as a potent antagonist of fibro genesis through its ability to inhibit fibroblast proliferation and matrix production. Its control on TGF β production might play a role^[49].

In conclusion: histological examination of an excisional wound model in diabetic rats, revealed rapid healing in AgNPs treated group as compared to SSD and the untreated groups. This was confirmed by relatively normal histological structure in addition to significant increase in VEGF and significant decrease of P53 and TGF β . AgNPs can be used as an adjunctive or alternative agent to existing wound healing therapies in future. However, further studies are certainly needed to spot more light on the healing mechanism of AgNPs and its relation to diabetes.

Recommendations:

- Usage of AgNPs for more prolonged time to achieve full remodeling of the dermis.
- Usage of different sizes and concentrations of silver nano particles and compare their results.

References:

- 1-**Gosain A and DiPietro LA (2004):** Aging and wound healing. *World J. Surg.*, 28:321-326.
- 2-**Brem H and Tomic-Canic M (2007)** :Cellular and molecular basis of wound healing in diabetes. *J. Clin. Invest.*, 117:1219-1222.
- 3-**Atiyeh BS, Dibo SA and Hayek SN (2009):** Wound cleansing, topical antiseptics and wound healing. *Int. Wound J.*, 6:420–430.
- 4-**Nair L S and Laurencin CT(2007)** :Silver nanoparticles: Synthesis and therapeutic

applications. *J. Biomed. Nanotechnol.*, 3: 301–316.

5. Gurunathan S, Park JH, Han JW and Kim J H (2015) : Comparative assessment of the apoptotic potential of silver nanoparticles synthesized by *Bacillus tequilensis* and *Calocybe indica* in MDA-MB-231 human breast cancer cells: Targeting p53 for anticancer therapy. *Int. J. Nanomed.*, 10: 4203–4222.

6- Wong KK, Tian J, Ho CM et al.(2007): Topical delivery of silver nanoparticles promotes wound healing. *Chem. Med. Chem.*, 2(1):129–136.

7- Srinivasan A and Menon VP(2003): Protection of pancreatic cell by the potential antioxidant bis-ohydroxycinnamoyl methane, analogue of natural curcuminoid in experimental diabetes. *J. Pharm. Pharmaceut. Sci.*, 6(3):327-333.

8- Wohaieb SA and Godin DV((1987) : Alterations in free radical tissue-defense mechanisms in streptozocin induced diabetes in rat. Effects of insulin treatment. *Diabetes*, 36: 1014-1018.

9- Kalaivani M, Sundaramoorthi C, Dhivya M M, Palanisamy S, Kalaiselvan V and Rajasekaran A(2009) : Biosynthesis of silver nanoparticles from *Aspergillus niger* and evaluation of its wound healing activity in experimental rat model. *Nanoscale Research L. Aspringer Open J.*, 1(4): 1523-1529.

10- Wong K K Y, Liu X, Lee P, Ho CH, Vincent C H, Chen Y and Paul K H (2010): Silver Nanoparticles Mediate Differential Responses in Keratinocytes and Fibroblasts during Skin Wound Healing *Chem. Med.*, 5: 468 – 475.

11-Etebary M, Jahanzadeh I, Mohagheghi MA and Azizi E(2002):Immuno histochemical analysis of p53 and its correlation to the other prognostic factors in breast cancer. *Acta Medica Iranica*,40(2): 88-94.

12-Bancroft JD and Gamble M (2002): Theory and Practice of Histological Techniques. 5th ed. Churchill Livingstone.

13- Chen BF and Clejan S (1993): Rapid preparation of tissue DNA from paraffin-embedded blocks and analysis by polymerase chain reaction. *Journal of Histochemistry and Cytochemistry*, 41 (5):765-768.

14- Stone R C , Pastar I , Ojeh N , Chen V, Liu S, Garzon KI and Tomic-Canic

M(2016):Epithelial-mesenchymal transition in tissue repair and fibrosis . *Cell Tissue Res.*, 1007:24-34.

15- Braiman-Wiksmann L, Solomonik I, Spira R and Tennenbaum T(2007): Novel insights into wound healing sequence of events. *Toxicologic Pathology*, 35:767–779.

16- Nagato H, Umebayashi Y, Wako M, Tabata Y and Manabe M(2006): collagen poly glycolic acid hybrid matrix with basic fibroblast growth factor accelerated angiogenesis and granulation tissue formation in diabetic mice. *J. Dermatol.*, 33: 670–675.

17- Cianfarani F, Toietta G, Di Rocco G, Cesareo E, Zambruno G and Odorisio T(2013):Diabetes impairs adipose tissue-derived stem cell function and efficiency in promoting wound healing. *Wound Repair Regen.*, 21:545–553.

18- Schmidt BA and Horsley V (2013): Intradermal adipocytes mediate fibroblast recruitment during skin wound healing. *Development*, 140: 1517-1527.

19-Schultz GS, Ladwig G and Wysocki A (2005): Extracellular matrix: review of its roles in acute and chronic wounds. *Wounds (UK)*, 5: 63-66.

20- Schultz GS, Sibbald RG, Falanga V et al.(2003) :Wound bed preparation: a systematic approach to wound management. *Wound Repair Regen.*, 11 (1):1–28.

21- Mishra M, Kumar H and Tripathi K (2008): Diabetic delayed wound healing and the role of silver nanoparticles. *Digest. Journal of Nanomaterials and Biostructures* , 3: 49 – 54.

22-Shang ZG, Gao HL, Ouyang GL, Huang XX, Li NL and Xiao LB(2012):Effect of bushen qiangu decoction on the proliferation of synovial fibroblasts and expression of PCNA and Bcl-2. *Pubmed*, 25(11): 942-945.

23- Abubakar MA, Arulselvan P, cheah PS, Abas F and Fakurazi SH(2016):Evaluation of wound healing properties of bioactive aqueous fraction from *Moringa oleifera* lam on experimentally induced diabetic animal model. *Drug Design Development and Therapy*, 10: 1715–1730.

24-Smith AN, Willis E, Chan VT, Muffley LA, Isik FF, Gibran NS and Hocking AM (2010):Mesenchymal stem cells induce dermal fibroblast responses to injury. *Exp. Cell Res.*, 316(1): 48–54.

- 25- **Jiang La, Li X and Huo Q (2001):** The preparation of collagen burn pellicle of compound sulfadiazine silver and assessment of its efficacy in an animal experiment on deep partial thickness burn wound. *Journal of West China University of Medical Sciences*, 32: 419-423.
- 26- **Hassanzadeh Gh , Hajmanouchehri F, Roi A B, Hassanzadeh N, Shafigh N, Barzroudpour M, Baazm M and Choobineh H (2013):** Comparing effects of Silver sulfadiazine, Sucralfate and Brassica oleracea extract on burn wound healing. *Life Science Journal*, 10(6):254-259.
- 27- **Tarameshloo M, Norouziyan M, Dolab S Z, Dadpay M and Gazor R(2012) :** A comparative study of the effects of topical application of Aloe vera, thyroid hormone and silver sulfadiazine on skin wounds in Wistar rats. *Lab. Anim. Res.*, 28(1): 17-21.
- 28- **Gomes MT, Soeiro GR, Piccolo N, FrançaCM, Guedes GH, lopes F, Belotto RA and Pavani C(2017):** Experimental burns: Comparison between silver sulfadiazine and photobiomodulation. *Med. Bras.*, 63(1):29-34.
- 29- **Kwan KH, Liu X, To MK, Yeung KW, Ho CM and Wong KK(2011):** Modulation of collagen alignment by silver nanoparticles results in better mechanical properties in wound healing. *Nanomed Nanotechnol Biol. Med.*, 7:497-504.
- 30- **Hendi A (2011):** Silver nanoparticles mediate differential responses in some of liver and kidney functions during skin wound healing. *Journal of King Saud University (Science)*, 23: 47–52