

PATHOLOGICAL, BIOCHEMICAL AND TOXICOLOGICAL STUDIES ON METRONIDAZOLE DRUG IN GOATS

Shehata, F. I.* and Soliman, A. S.**

* Animal Health Research Institute (Biochemistry, Department Banha Branch)

** Animal Health Research Institute (Pathology Department, Banha Branch)

ABSTRACT

The metronidazole, one of the 5-nitroimidazole compound, was used as anti-anaerobic protozoa (*Trichomonas vaginalis*, *Entamoeba histolytica* and *Giardia lamblia*) and may used in veterinary medicine for prevention and treatment of coccidiosis in poultry and animals, dog trichomoniasis and anaerobic bacterial diseases. The aim of the present study is a trial to study pathological, biochemical and haematological changes associated with uses of metronidazoles (therapeutic or double therapeutic doses) in goats. Fifteen adult male goats aged five months were divided into 3-equal groups, the 1st group is the control goats, the 2nd group was i.v. injected with 25 mg metronidazole /kg.b.w., once a day, for 5- consecutive days, and the 3rd group was i.v. injected with 50mg metronidazole /kg.b.w. (double therapeutic dose) as the same manner of the 2nd group. Haematological, serum biochemical, protein immunoelectrophoretic and histopathological studies were carried out on blood, serum and organ samples from the slaughtered animals at 6th day of drug treatment. Based on the histopathological, biochemical and haematological results, it could be concluded that the metronidazole injection in goats (especially by 50mg/kg.b.w. dose levels) could induced : anaemia (because of the significant decrease of erythrocytes, leucocytes and blood platelets counts, and haemoglobin concentration), immunosuppression (because of the hypogamma-globulinemia, leucopenia beside degenerative changes and multiple necrosis in the spleen tissue), liver dysfunction (due to the elevated ALT-enzyme activity and serum total bilirubin, and degenerative changes or local and diffuse necrosis in the hepatic tissues), kidney dysfunction (due to the elevated serum creatinine and haemorrhages in renal tissues and degenerative changes, and necrosis of the renal tubular cells).

INTRODUCTION

The Azomycin (2-nitroimidazole) was the first antibiotic isolated from streptomycete. It had a

trichomonocidal activity, and this led to the chemical synthesis of other nitroimidazoles (Cosar and Julou, 1959). From the biologically active nitroheterocyclic compounds are the 2-nitroimidazoles and 5-nitroimidazoles. The latter include : Unidazole, ornidazole, nimorazole, benzoylmetronidazole, secnidazole (Flagentyl) and metronidazole (Flagyl) (Rossignol et al., 1984) as antiprotozoal and antibacterial antibiotics. The mode of their actions is by the reduction of nitroreductase enzyme of the microorganisms, with the consequent inhibition of the microbial DNA causing their death (Sisson and Ingham, 1985).

Metronidazole [1-(2-hydroxyethyl) -2-methyl-5-nitroimidazole] was used in human medicine as antianaerobic protozoa (*Trichomonas vaginalis*, *Entamoeba histolytica* and *Giardia lamblia*) and (Nigro et al., 2003). The drug penetrates the blood brain barrier and goes through hepatobiliary excretion (Tsai and Chen, 2003). It accumulates in patients with liver dysfunction causing peripheral and central nervous disorders (Horlen et al., 2000 and Kim et al., 2004).

Metronidazole induced : anaemia (El-Nahas and El-Ashmawy, 2004), Geno- and cytotoxicities for human peripheral lymphocyte (Nigro et al., 2003, and Carballo et al., 2004), and somatic cells (El-Nahas and El-Ashmawy, 2004), Carcinogenesis in animals (Bendosky et al., 2002), inhibit the tumour necrosis factor (Colpaert et al., 2001), (El-Nahas and El-Ashamwy, 2004), spermatotoxic to rats which may mediated by its lowering the circulating serum reproductive hormones (FSH, LH and testosterone) (Grover et al., 2001), and the drug also increase the frequency of post implantation deaths in female rats (Murdy et al., 2001).

In veterinary practice, metronidazole (Flagyl) was used for treatment of rabbit coccidiosis (Reshetnyak et al., 1970, and Jones et al., 1977), chicken coccidiosis in Egypt (Shakshouk et al., 1995), and lately, the secnidazole (Flagentyl), as one of 5-nitroimidazole compounds, was used also for treatment of rabbit coccidiosis (Helal and Seddek, 2005). Beside the drug is useful for prevention of anaerobic bacterial diseases in animals as tetanus and gas gangrene (Freeman et al., 1968). So that, the objective of the current toxicological study is to examining some biochemical, immunological, haematological and histopathological changes which may be induced in one of ruminant animals (as goats) by metronidazole for the purpose of the safety use of the drug in treatment of coccidiosis and anaerobic infections in Egyptian goats.

MATERIAL AND METHOD

In a private goat farm, fifteen apparently healthy adult male goats aged five months were divided into three equal groups, the first group served as a control group, the goats of the second group were intravenously (i.v.), injected with 25mg /kg.b.w. (therapeutic dose) of the metronidazole drug, (injectable solution, Amryla Pharmacautical Indust. Company, Alex., Egypt) once per

day, for 5 consecutive days. The goats of the third group were i.v. injected with 50mg metronidazol/kg.b.wt for 5-days (as in the 2nd group). At the 6th day of drug injections, all animals were slaughtered and the blood (with heparin-anticoagulant) was collected for haematological (Red and white blood corpuscle counts, haemoglobin concentration and blood platelets count) according to Schalm (1961), blood samples from all slaughtered goats were collected without anticoagulant for obtaining serum samples for serum protein electrophoresis on cellulose acetate (Bierer, 1969), and for estimation of the following serum constituents as : the activities of aspartic aminotransferase (AST) and the Alanine aminotransferase (ALT) enzymes according to Reitman and Frankel (1957), total bilirubin (Jendrassik, 1938), serum creatinine (Henry, 1974) and the serum total protein (Doumas et al., 1971). Also, fresh liver, kidneys and spleen samples were put in 10% neutral formaline - saline then processed for paraffin sections and stained with haematoxylin and Eosin (H & E) stain for histopathological examination (Lille and Fullmer, 1976) and the histological changes were microscopically examined. The data were statistically evaluated using the t student test according to (Snedecor and Cochran, 1969).

RESULTS

A) Serum Protein Fractions :

The serum protein electrophoresis showed the following protein profiles :

1- **Albumin** : There was a significant increase ($P \leq 0.05$) of serum albumin (by dose level of 25mg /kg.b.w.) and significant decrease ($P \leq 0.001$) by the dose level of 50mg/kg.b.w. than that of the control goats.

2- **Alpha-1 (α -1) Globulins** : there were significant decrease of α -1 globulins in goats administered either 25 or 50mg metronidazol/kg.b.w. (at $P \leq 0.01$ and 0.001 respectively) than control goats.

3- **Alpha -2 (α -2) Globulins** : α 2 globulins increased significantly ($P \leq 0.001$) than that of the control goats.

4- **The Beta (β) globulins** : the β -fraction decreased significantly ($P \leq 0.01$) by 25mg/kg., but increased significantly ($P \leq 0.001$) by the double dose (50mg/kg.b.w.) than of control goats.

5- **Gamma (γ) Globulins (Immunoglobulins)** : The immunoglobulins were significantly ($P \leq 0.001$) decreased in goats administered either 25 or 50 mg metronidazol / kg.b.wt. dose levels than that of the control goat.

6- **Total globulins** : the total globulins were equally significantly decreased ($P \leq 0.01$) in the two metronidazol treated groups of goats by (25 and 50mg/kg dose levels) than that of the con-

control animals (Table 1. and Fig.1).

B) Haematological Results :

- 1- White Blood Corpuscles (WBCs) Count :** There was only significant decrease in WBCs count in goat administered 50mg metronidazol /kg,b.w. than that of the control goats.
- 2- Red Blood Corpuscles (RBCs) Count :** The RBCs count of goats administered with either 25 or 50 mg metronidazol/kg,b.wt. were significantly decreased ($P \leq 0.05$) than that of control animals.
- 3- The Haemoglobin (Hb) concentration :** The Hb-concentrations were significantly decreased ($P \leq 0.05$) in goats of both metronidazol treated groups than that of control one.
- 4- Blood Platelets :** Also, the platelets of the blood of metronidazol treated groups of goats were significantly decreased ($P \leq 0.01$ and 0.001) by dose levels of 25 and 50 mg/kg. respectively, than that of control animals (table. 2).

C) The Changes of Some Serum Biochemical Constituents :

- 1- Aspartic Amino Transferase (AST) Enzyme Activity :** The serum AST-enzyme activity was only significantly increased ($P \leq 0.001$) in goats treated with 50mg metronidazole than that of control group.
- 2- Alanine amino transferase (ALT) enzyme activity :** The serum ALT enzyme activity was significantly ($P \leq 0.05$) increased by 25mg/kg.b.wt and significantly ($P \leq 0.001$) increased by 50mg/kg.b.wt in metronidazole treated groups of goats than that of control goats .
- 3- Total Billrubin :** The total billrubin was significantly increased in the serum of metronidazol treated goats by either 25mg/kg. ($P \leq 0.01$) or by 50mg/kg. ($P \leq 0.001$) than control.
- 4- Total cholesterol :** The total cholesterol was not showed any significant change in metronidazol treated groups than that of control group of goats.
- 5- Serum Creatinine :** Creatinine was only increased significantly ($P \leq 0.05$) in treated goats with 50mg metronidazol/kg. than of control group.
- 6- The Total Proteins :** The serum total protein was only significantly ($P \leq 0.001$) decreased in metronidazole treated goats (50mg/kg.b.w) than that of control animals (Table, 3).

D) The Histopathological Changes :

1- Liver :

- a- **25mg metronidazole/kg.b.w. dose level :** The liver showed degenerative changes of hepatocytes, congestions of hepatic blood vessels (Fig.2).
- b- **50mg/kg. metronidazole /kg.b.w. dose level :** The histopathological examination of the liver revealed vacuolation of the hepatocytes and congestion of the central vein (Fig.3).

2- Kidneys :

- a- **25mg/kg.B.W. Dose Level :** The histopathological examination showed vacuolation and slight necrosis of renal tubular cells.
- b- **50-mg/kg.B.W. dose Level :** Swelling of renal tubular cells, vacuolation of renal tubular cells, partial flattening of some tubular epithelium and Intertubular haemorrhages were noticed (Fig. 4).

3- Spleen :

- a- **25mg/kg.B.W. Dose Level :** Slight degenerative changes in the lymphoid cells of the spleen.
- b- **50mg/kg.B.W.Dose level :** Lymphoid depletion of white pulps of the spleen and thickening of the walls of the blood vessels of the spleen were seen (Fig.5).

DISCUSSION

The parasitic illness is increasing all over the world, especially in developing countries. In the veterinary practice, the coccidiosis, the dog trichomonias and the anaerobic bacterial diseases need newer drugs for their treatments, where these agents are susceptible for treatment with the 5-nitroimidazole drugs (especially metronidazole) as previously reviewed. The introduction of such drugs in veterinary medical therapy may be needed for treatment, which may be used also to overcome the drug resistance of the already available drugs, and these drug resistances may be causing serious problems in controlling such diseases (Chapman, 1997).

There was no sufficient available data concerning the use of metronidazole in treatment of goats, so that the current study was essentially conducted to studying the intravenous injections of two doses of metronidazole (injectable solution), as suggestive therapeutic and its double dose (taking in consideration the human therapeutic dose as a guide) through the present biochemical

cal, immunoelectrophoretical, haematological and histopathological changes in the treated goats.

The present study revealed that the serum albumin and AST-enzyme activity were significantly decreased in metronidazole treated goats (by 50mg /kg.b.w., for 5-days), but both the ALT-enzyme activity and the serum total bilirubin were significantly increased in treated goats by either 25 mg or 50mg /kg.b.w. dose levels than control animals, this result may indicated the presence of a certain degree of liver dysfunction, especially by the 50mg/kg.dose level. On the other side, there was degenerative changes in the liver and congestions in the liver tissue, such pathological changes become more prominent and clear by the higher dose (50mg/kg), further study should be needed to determine if these changes are reversible (or not), especially by the lower dose level (25mg/kg.b.w.). Bjornsson et al. (2002) recorded hepatocellular injury and cholestasis in human patients treated with metronidazole for 2-years and suggested the possible relationship between these changes and this drug therapy. The increased activity of ALT-enzyme which was parallel with the increased concentration of the serum total bilirubin, are indicative of liver dysfunction (Kachman and Moss, 1976). But the non-significant change of serum albumin and AST-enzyme activity by the dose level 25 mg metronidazol/kg.b.w., may pointed to that the liver of treated goat was not severely substantially impaired (and probably temporary or transient), as the albumin is synthesized in the liver (McPherson, 1984). The decreased level of albumin in serum of 50mg metronidazole/kg.treated goats may also due to presence of certain degree of kidney dysfunction, where the serum creatinine of treated goats also increased by the same dose level (50mg/kg) by the present study. The serum creatinine increased indicated the possibility of the substantial impairment of kidney to a degree that kidney could permit to the excretion of the albumin (which of small molecular weight protein) to the urine (Hayes, 1989), and this could be confirmed through the present histopathological study, which revealed the presence of necrosis in the renal tissue, and haemorrhagic areas, especially by the dose level of 50mg/kg.b.w.

The present study revealed that α -1-and α -2-globulins were mostly decreased by 50mg/kg.b.w. dose level, but α -2-globulins increased only by 25mg/kg. dose level. Kaneko (1989) reviewed that there are 13-types of α -globulins of diagnostic values, the elevated levels of some of them have reported with some toxic chemicals and drugs (Dolezalova et al., 1983) and with protein catabolism or with adrenal stimulation (Schalm, 1975).

The Beta (β) globulins were significantly decreased (by 25 mg/kg) and increased (by 50 mg/kg) in goat treated with metronidazole drug in the present study. The increased level of β -fractions may be attributed to some immunoglobulins (γ -fractions) which may transferred to the regions of β -globulins in response to hemolytic anaemia, iron deficiency or autoimmune disease (Kaneko, 1989).

The Gamma (γ) globulins (immunoglobulins) were significantly decreased by the two dose levels of metronidazole treatments in goats compared to the untreated control goats. The immunoglobulin decrease is an indicative of the presence of immunosuppression activity of metronidazole drug, as the γ -globulins are the precursors of the specific antibody formation, and they are composed of several immunoglobulins (Ig) such as : IgG, IgM, IgA, IgE and IgD, which are synthesized by the plasma cells, which matured from β -lymphocytes, in the spleen, bone marrow and lymph nodes (McPherson, 1984). The current work revealed also the presence of significant decrease of leucocyte count (leucopaenia), and presence of multiple necrotic areas in the spleen tissue (especially by 50mg metronidazole/kg.b.w.). A transient and reversible neutropenia has been recorded during metronidazole treatment (Sanders et al., 1979) and leucopenia and neutropenia were recorded by Mandal et al. (1987), and lately, the leucopenia in mice, (induced by metronidazole) could be reported by El-Nahas and El-Asbmawy (2004), the latter authors recorded also, that metronidazole induced anaemia in mice (represented by decreased erythrocyte and leucocyte counts, and haemoglobin concentration). Such anaemia could be recorded also in metronidazole treated goats by our study, as a decrease in erythrocytes, leucocytes and platelets counts and haemoglobin concentration.

The immunosuppression effect that induced by metronidazole treatments could be strengthened by other authors. Bamias et al. (2002) revealed the decreased of percentage of lymphocytes in the mesenteric lymph-nodes in metronidazole treated mice, parallel with decreased production of IFN-gamma and inhibition of Th_1 - cytokine production. Carballo et al. (2004) reported a decrease in the replication index in lymphocytes in metronidazole treated women. Also, Colpaert et al. (2001) recorded, in vitro, that the metronidazole suppressed the tumour necrosis factor in rats.

In conclusion, the metronidazole injection (especially by 50mg/kg.b.w.) could induced : anaemia (because of the significant decrease of erythrocyte, leucocytes and platelets counts and haemoglobin concentration and necrosis in spleen), immunosuppression (because of hypogammaglobulinemia and leucopenia), liver dysfunction (due to the elevated ALT-enzyme activity and total bilirubin and degenerative changes in liver tissue), kidney dysfunction (due to elevation of serum creatinine and degenerative changes in renal tissue). Further studies should be done weekly examinations of the all above parameters should be carried out in goats after parenteral (or even oral) administration of 25mg/kg.b.w. to determining if these changes were reversible and transient, or not, before the therapeutic administration of the metronidazole drug in the Egyptian goats.

Table (1): The different protein fractions of the serum protein of Goats (Intravenously injected with metronidazole for 5 days) as determined by the immunoelectrophoresis.

Groups (Doses)	Albumin (A) (g/dl)	Alpha-1 (α -1) globulins (g/dl.)	Alpha-2 (α -2) globulins (g/dl)	Beta (β) Globulins (g/dl)	Gamma (γ) Globulins (g/dl)	Total Globulins (g/dl)	Total proteins (g/dl)
Control Goats (0.00mg/kg)	1.660 \pm 0.078	0.420 \pm 0.045	0.270 \pm 0.012	0.800 \pm 0.033	3.530 \pm 0.170	5.040 \pm 0.319	6.700 \pm 0.385
25mg/kg.B.w. (I/v.inj.)	* 2.230 \pm 0.158	** 0.260 \pm 0.013	*** 0.680 \pm 0.026	** 0.620 \pm 0.036	*** 1.810 \pm 0.137	** 3.370 \pm 0.269	NS 5.600 \pm 0.306
50mg/kg.B.w. (I/v.Inj.)	*** 0.680 \pm 0.064	*** 0.030 \pm 0.004	*** 0.070 \pm 0.004	*** 1.520 \pm 0.107	*** 1.700 \pm 0.095	** 3.320 \pm 0.187	*** 4.000 \pm 0.233

N.B. : NS = Non-significant change between means. * = Significant change between the two means (at $P \leq 0.05$), ** = highly significant change between the two means (at $P \leq 0.01$), *** = very highly significant change between the two means (at $P \leq 0.001$).

Table (2): Some Haematological parameters (white and red blood corpuscle and blood platelets counts, haemoglobin concentration) of goats intravenously injected with metronidazole for 5 days.

Groups (Doses)	White Blood Corpuscles (WBCs) (thousands/cumm)	Red Blood Corpuscles (RBCs) (Millions/cumm)	Haemoglobin concentration (g/dl)	Blood platelets (Thousands /cumm)
Control (0,00 mg/kg.)	4,200 \pm 221	3,700,000 \pm 165,000	8,700 \pm 0,345	860,000 \pm 28,844
25mg/kg.B.w (I/v. inj.)	NS 3,600 \pm 210	* 3,100,000 \pm 127,000	* 7.500 \pm 0.291	** 720,000 \pm 25,298
50mg/kg.B.w. (I/v.inj.)	* 3,500 \pm 139	* 2,400,000 \pm 63,000	* 7,200 \pm 0,295	*** 640,000 \pm 20,396

N.B. : NS = Non-significant change between means. * = Significant change between the two means (at $P \leq 0.05$), ** = highly significant change between the two means (at $P \leq 0.01$), *** = very highly significant change between the two means (at $P \leq 0.001$).

Table (3): Some serum biochemical constituents of goats intravenously injected with metronidazole for 5-days.

Groups (Doses)	Aspartic amino-transferase (AST) Enzyme Activity (IU/L)	Alanine amino-Transferase (ALT) Enzyme Activity (IU/L)	Total Bilirubin (mg/dl)	Total Cholesterol (mg/dl)	Creatinine (mg/dl)	Total Proteins (g/dl)
Control Goats (0.00mg/kg)	41 ± 3.448	8.100 ± 0.753	1.030 ± 0.164	118 ± 8.713	1.100 ± 0.127	6.700 ± 0.385
25mg/kg.B.w. (I/v.inj.)	NS 43 ± 3.162	* 12.200 ± 1.019	*1.500 ± 0.117	NS 130 ± 10.198	NS 1.200 ± 0.134	NS 5.600 ± 0.306
50mg/kg.B.w. (I/v.inj.)	*** 66 ± 3.311	**8 13.700 ± 1.028	**2.300 ± 0.212	NS 143 ± 10.826	* 1.600 ± 0.126	**84.000 ± 0.233

N.B. : NS = Non-significant change between means.

* = Significant change between the two means (at $P \leq 0.05$),

** = highly significant change between the two means (at $P \leq 0.01$),

*** = very highly significant change between the two means (at $P \leq 0.001$).




Fig. (1): The different protein fractions of metronidazole treated goats : (a) control goat (b) goat i.v. injected with 25mg/kg.b.w., and (c) goat injected with 50mg/kg.b.w.



Fig. (2): Liver section of Goat i.v. injected with 25mg metronidazol/ kg.b.w. for 5-days, showing degenerative changes in the hepatocytes and congestion of the hepatic blood vessels (H & E. x 400)

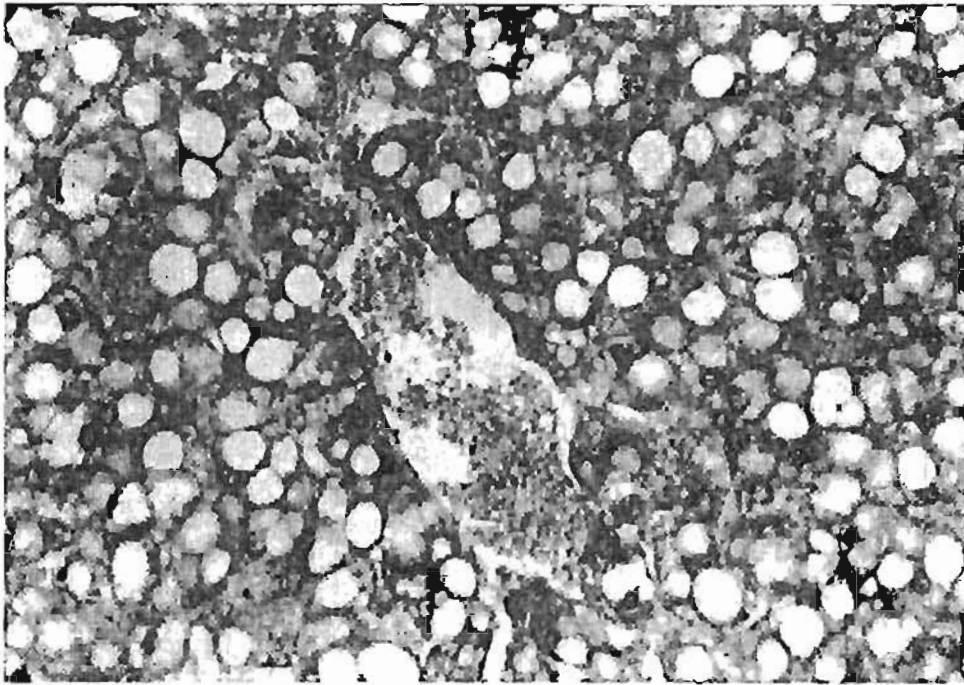


Fig. (3): Liver section of goat. I.v. Injected with 50 mg metronidazol/kg.b.w. for 5-days, showing congestion of the central vein and vacuolations of hepatocytes (H & E., x 400).

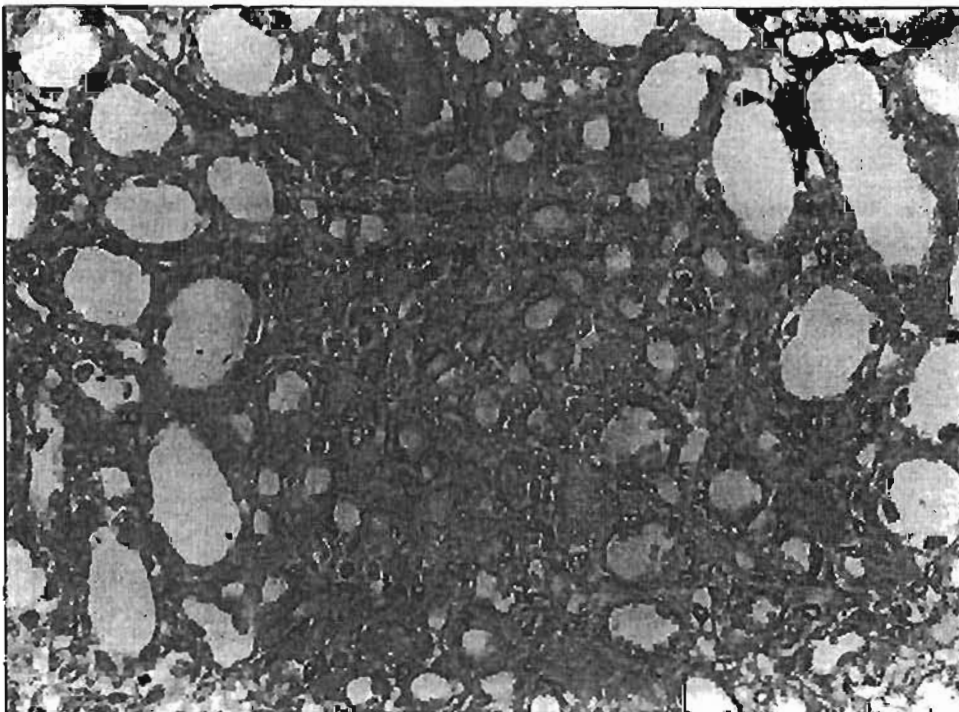


Fig. (4): Kidney section of goat. I.v. Injected with 50mg metronidazol/kg.b.w. for 5-days, showing partial flattening of some tubular epithelium and haemorrhages of the Intertubular spaces (H & E. x 400).

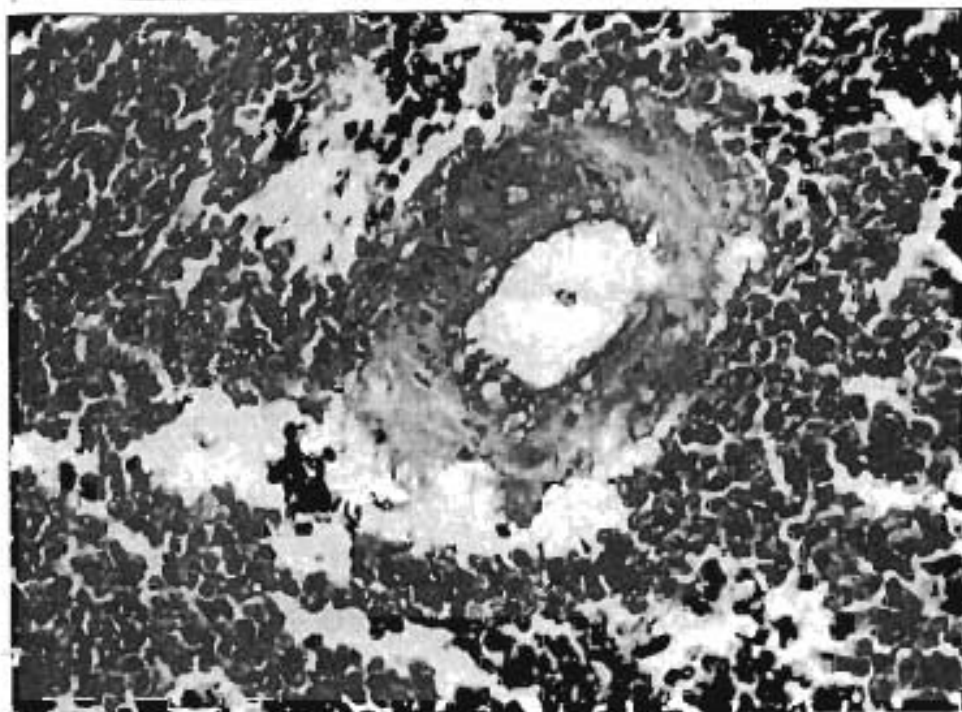


Fig. (5): Spleen section of goat i.v. injected with 50mg metronidazol/kg.b.w. for 5-days, showing lymphoid depletion and thickening of the wall of the blood vessel of the spleen

(H. & E. x 400).

REFERENCES

- Bambas, G.; Marini, M.; Muskaluk, C. A.; Odashima, M.; Ross, W. G.; Rivera, N. J. and Cominelli, F. (2002) : Down-regulation of intestinal lymphocyte activation and Th-1-cytokine production by antibiotic therapy in a murine model of Crohn's disease. *J.Immunol.*; 169(9): 5308-14.
- Bendesky, A.; Menendez, D. and Ostrosky, W. P. (2002) : Is metronidazole carcinogenic ?. *Mutat. Res.*; 511(2): 133-144.
- Bierer, B. W. (1969) : Electrophoresis analysis of blood serum and plasma proteins of normal horses. *Am. J. Vet. Res.* (30): 2237-40.
- Bjornsson, E.; Nordlinder, H. and Olsson, R. (2002) : Metronidazole as a probable cause of severe liver injury. *Hepatogastroenterology*, 49 (43): 252-254.
- Carballo, M. A.; Palermo, A. M. and Mudry, M. D. (2004) : Toxicogenetic evaluation of metronidazole in the treatment of women infected with trichomonas vaginalis. *Ann. Trop. Med. Parasitol.*; 98(2): 139-147.
- Chapman, H. D. (1997) : Biochemical, Genetic and applied aspects of drug resistance in *Elmerr* parasites of the fowl. *Avian Pathology* (26): 221-244.
- Colpaert, S.; Liv, Z.; De-Greef, B.; Rutgeerts, P.; Ceuppens, J. I. and Geboes, K. (2001) : Effects of anti-tumour necrosis factor, Interleukin-10 and antibiotic therapy in the indomethacin induced bowel inflammation rat model. *Aliment. Pharmacol. Ther.*, 15(11): 1827-1836.
- Cosar, C. and Julou, L. (1959) : Activity de L'(Hydroxy-2-ethyl)-1- methyl-2-nitro-5-imidazole (8823R.P.). Vice-avisdes infections experimentales a trichomonas vaginalis. *Ann. Inst. Pasteur. Paris* (96): 235.
- Dolezalova, V.; Stratil, P. and Simeckova, M. (1983) : α -fetoproteins and macroglobulin as a markers of distinct response of hepatocytes carcinogens in the rats carcinogenesis. *Ann. N.Y.Acad. Sci.* (417): 294-306.
- Doumas, B. T.; Watson, W. A. and Piga, H. G. (1971) : Kits used for serum total protein determination. *Clin. Chem. Acta* 31(1) : 87.
- El-Nahas, A. F. and El-Ashmawy, I. M. (2004) : Reproductive and cytogenetic toxicity of metronidazole in male mice. *Basic Clin. Pharmacol. Toxicol.*; (495): 226-231.
- Freeman, W. A.; McPadzeam, J. A. and Whelan, J. P. F. (1968) : Activity of metronidazole against experimental tetanus and gas gangrene. *J. Appl. Bact.*, (31): 443.

- Grover, J. K.; Vats, V.; Srinivas, M.; Das, S. N., Jha, P.; Gupta, D. K. and Mitra, D. K. (2001): Effects of metronidazole on spermatogenesis and FSH, LH and testosterone levels of pre-pubertal rats. *Indian. J. Exp. Biol.*; 39(11): 1160-1162.
- Hayes, A. W. (1989) : Principles and methods of toxicology, 2nd. Ed., Raven Press, New York, pp.485.
- Helal, A. D. and Seddek, Sh. A. (2005) : Toxicological and parasitological studies of the secnidazole drug (compared with amprolium sulphate) as a trial for using It in treatment of *E. stiedae* infection in rabbits. *Zag. Vet. J.* , 23(1): 45-62.
- Henry, R. J. (1974) : Clinical chemistry principles and technics, 2nd. Ed., Harper and Row, PP : 525.
- Horlen, C. K.; Seifert, C. F. and Malou E. C. S. (2000) : Toxic metronidazole -induced MRI changes. *Ann. Pharmacother.*; 34(11): 1273-1275.
- Jendrassiki, G. P. (1938) : Vereinfachte photometrische methoden zur bestimmung de blutbilirubins. *Biochemical J.*, 2(297): 81.
- Jones, L. M.; Booth, N. H. and McDonald, L. E. (1977) : Veterinary pharmacology and therapeutics. 4th. Ed., the Iowa State University Press.
- Kachman, J. F. and Moss, D. W. (1976) : Enzymes in : Fundamentals of clinical chemistry. sounders, W.B., Philadelphia.
- Kaneko, J. J. (1989) : Clinical biochemistry of domestic animals, chapter (6), pp. 142, 4th., Ed., Academic press, Inc.
- Kim, D. W.; Park, J. M.; Yoon, B. W.; Back, M. J.; Kim, J. E. and Kim, S. (2004) : Metronidazole-induced encephalopathy. *J. Neurol.Sci.*; 224(1-2): 107-111.
- Lille, R. D. and Fulmer, H. N. (1976) : Histopathologic technic and practical histochemistry. McGraw Hill Book Comp.
- Mandal, T. K.; Yadava, K. P. and Turkey, K. (1987) : Effect of metronidazole on the haematological parameters in goats. *Indian Journal of animal sciences*, 57(7): 706-708.
- McPherson, R. A. (1984) : Specific protein in : Clinical diagnosis and management by laboratory methods, Edited by Henry. J.B.; Sounders. W.B., Philadelphia.
- Murdy, M. D.; Martinez, F. I.; Palermo, A. M.; Carballo, M. A.; Egozcue, J. and Garcia, C. M. (2001) : Embryo lethality by metronidazole (MTZ) in *Rattus norvegicus*. *Teratog. Carcinog. Mutagen.*; 21(3): 197-205.

- Nigro, L. M. M.; Palermo, A. M.; Mudry, M. D. and Carballo, M. A. (2003) : Cytogenetic evaluation of two nitroimidazole derivatives. *Toxicol. In vitro*: 17(1): 35-40.
- Reitman, S. and Frankel, S. (1957) : Kits for determination of SGOT and SGPT. *J. Clin. Path.*, 28 : 56.
- Reshetnyak, U. Z.; Barteneve, U. S. and Rubanov, A. A. (1970) : trichopol (metronidazole), an effective drug against coccidiosis in Rabbits; *Veterinaria*, (3): 75.
- Rossignol, J. F.; Maisonneuve, H. and Cho, Y. M. (1984) : Nitroimidazoles in the treatment of trichomoniasis, giardiasis and amoebiasis. *International Journal of Clinical Pharmacology, Therapy and Toxicology*, 22(2): 63-72.
- Sanders, C. V.; Hanna, B. J. and Lewis, A. C. (1979) : Metronidazole in the treatment of anaerobic infections. *Amer. Rev. Resp. Dis.* (120): 137.
- Schalm, O. W. (1961) : *Veterinary haematology*, Lea and Febiger, Philadelphia, USA.
- Schalm, O. W. (1975) : *Veterinary Haematology*, Bailliere Tindall and Cassel LTD., 2nd. Ed. London.
- Shakshouk, A. G.; Gomaz, H. E. and Ashmawy, I. E. (1995) : The anticoccidial efficacy of metronidazole in comparison with sulphaquinoxaline and lasalocid in control of coccidiosis in balady chickens. *J. Egypt. Vet. Med. Assoc.*, 55(1-2) : 517-27.
- Sisson, P. R. and Ingham, H. R. (1985) : Action of metronidazole on facultative anaerobes. *J. Infect. Dis.*, (151) : 569.
- Snedecor, G. W. and Cochran, W. G. (1969) : *Statistical methods*, 6th ed. IOWA state university, Ames, IOWA.
- Tsai, T. H. and Chen, Y. F. (2003) : Pharmacokinetics of metronidazole in rat blood, brain and bile studied by microdialysis coupled to microbore liquid chromatography. *J. Chromatogr. A*: 987(1-2): 277-282.

الملخص العربى

دراسات باثولوجية وبيوكيميائية وسمية عن عقار الميترونيدازول فى الماعز

فوزى إبراهيم شحاته

عبدالحفيظ السيد سليمان ناجى*

معهد بحوث صحة الحيوان (فرع بنها - تم الكيبيا، والسرم)

معهد بحوث صحة الحيوان (فرع بنها - تم الباثولوجيا)*

عقار الميترونيدازول (الفلاجيل) هو أحد مركبات 5-نيتروإميدازول واستخدم كمضاد حيوى ضد الطفيليات اللاهوائية وحيدة الخلية (مثل التريكو موناتس فاجيناليز والإنتاميبيا هستوليتيكا والجيارديا لمبليا) وضد البكتريا اللاهوائية سالبة الجرام واستخدام فى مجال الطب البيطرى للوقاية والعلاج لمرض كوكسيدبا الدجاج والحيوانات وضد مرض التريكوموناتس فى الكلاب وضد الأمراض البكتيرية اللاهوائية المختلفة، وكان الهدف من هذه الدراسة محاولة إستخدام عقار الميترونيدازول بالحقن الوريدي فى الماعز المصرى بجرعتين (الجرعة العلاجية وضعفها) مسترشدين بالجرعة المقررة للإنسان لكل كجم وزن، ولهذا الغرض تم تقسيم عدد ١٥ من ذكور الماعز السليمة ظاهرياً بأحد المزارع الخاصة إلى ٣ مجموعات متساوية، المجموعة الأولى سليمة واستخدمت كضابط للتجربة، والمجموعة الثانية تم حقنها وريدياً بجرعة ٢٥مجم ميترونيدازول/كجم وزن حى، والمجموعة الثالثة من الماعز تم حقنها وريدياً بجرعة ٥٠مجم ميترونيدازول/كجم وزن حى، وتم الحقن الوريدي لحيوانات المجموعتين مرة واحدة فى اليوم، ولمدة ٥-أيام متتالية، وفى اليوم السادس تم ذبح الحيوانات كلها وتم أخذ عينات دم (مع مانع التجلط) لإجراء الفحوص الهيماتولوجية، وعينات سيرم لعمل الفحوص البيوكيميائية والمناعية (الفصل الكهربى لبروتين المصل)، وعينات كبد وكلية وطحال لدراسة التغيرات الهستوباثولوجية المصاحبة لحقن العقار. وبناء على نتائج الدراسة أمكن إستنتاج أن عقار الميترونيدازول حقناً فى الماعز (خاصة بالجرعة ٥٠مجم/كجم وزن حى) أحدث أنيميا بالماعز (بسبب حدوث النقص المعنوى فى عدد كرات الدم الحمراء والبيضاء والصفائح الدموية ونقص تركيز الهيموجلوبين)، وأحدث تشييط مناعى (بسبب النقص المعنوى فى كل من الجاما - جلوبيولين وعدد كرات الدم البيضاء ونتج عن الفحص الهستوباثولوجى وجود إنحلال وتتركز متعدد بنسيج الطحال والكبد والكلية)، وأحدث خلل فى وظائف الكبد (بسبب الزيادة المعنوية لإنزيم ALT وتتركز البيلبيريون الكلى وأحدث تغيرات إنحلالية وتتركز بأنسجة الكبد)، وأحدث إضطراب فى وظيفة الكلى (بسبب الزيادة المعنوية فى كرياتينين المصل وتغيرات إنحلالية وأنزفة وتتركز بأنسجة الكبد)، وأحدث إضطراب فى وظيفة الكلى (بسبب الزيادة المعنوية فى كرياتينين المصل وتغيرات إنحلالية وأنزفة وتتركز بأنسجة وأتابيب الكليتين)، ولهذا يوصى بعمل دراسة أخرى لدراسة المعالم السابقة إسبوعياً فى الماعز بعد إعطاء جرعة ٢٥مجم/كجم وزن عن طريق الحقن الوريدي وعن طريق الشرب لمعرفة عما إذا كانت التغيرات السابقة التى حدثت بهذه الجرعة هى تغيرات وقتية ومعكوسة إلى الوضع الطبيعى أم لا وذلك قبل إستخدام عقار الميترونيدازول بهذه الجرعة فى الماعز المصرى.