



EGYPTIAN ACADEMIC JOURNAL OF
BIOLOGICAL SCIENCES
ZOOLOGY

B




ISSN
2090-0759

WWW.EAJBS.EG.NET

Vol. 12 No. 2 (2020)

www.eajbs.eg.net



Effect of Formaldehyde on The Structure of The Lung and Heart and The Possible Protective Effect of Omega- 3 (Histological and immune-histochemical study)

Salwa M. Ouies and Abeer F. Abd El-Naeem

Human anatomy & Embryology Department, Faculty of Medicine, Sohag University

Email: salwaouies@yahoo.com - abeerfareed_2013@yahoo.com

ARTICLE INFO

Article History

Received:20/9/2020

Accepted:27/11/2020

Keywords:

Formaldehyde;
congestion; T.N.F-
a; caspase-3;
Omega-3.

ABSTRACT

Background: Formaldehyde (FA) is a common indoor and outdoor pollutant found in many products. The toxicity of formaldehyde is of concern to all who work closely with it such as embalmers, anatomists, histology technicians, and medical students. Omega-3 in fish oil is one of the most important polyunsaturated fatty acids (PUFA) that have anti-inflammatory and antioxidant activity. **Materials and methods:** Thirty adult male albino rats were divided into three equal groups. Group, I was a control group, Group II rats were exposed to formaldehyde inhalation for 4 weeks. Group III were exposed to formaldehyde inhalation and were administered orally with a 300mg/kg/day Omega-3 for 4 weeks. After 24 hr of the last dose, the animals were dissected. Hearts and lungs were processed for examination after Haematoxylin and eosin, Masson trichome and immunohistochemical stains. **Results:** The rats treated with formaldehyde inhalation showed significant changes in the normal architecture of both lung and heart. The lung showed congestion and mass appeared on one lobe and increase in the area percent of collagen fibers. Immune-expression of tumor necrosis factor-alpha (TNF- α), and caspase- 3 were increased in the lung and heart compared to the control. Omega-3 fatty acids can ameliorate the pathological changes, decrease the fibrosis and the immune-expression in both lung and heart. **Conclusion:** Formaldehyde was associated with many histopathological changes in both lung and heart and the Omega-3 can ameliorate these changes.

INTRODUCTION

Formaldehyde is an organic carbon compound frequently used in occupational environments (hospitals, textiles, paper, resins, and wood composites), house indoor environments (insulating materials, fabrics, chipboard, and cooking emissions), and also in anatomy, pathology, and histology laboratories. (Kim *et al.*, 2002; Nakazawa *et al.*, 2005; Leal *et al.*,2018).

Formaldehyde inhalation inflicts various harms on many systems, not include the respiratory system only but also exerted on a variety of organs of living bodies (Zhou *et al.*, 2006). Exposure of the medical students and instructors to formaldehyde during the gross anatomy laboratory may cause an acute effect on the respiratory system and pulmonary functions (Khaliq and Tripathi, 2009).

Omega-3 fatty acids, both plant-derived (α -linolenic acid, ALA) and forms found

primarily in fish (eicosapentaenoic acid, EPA and docosahexaenoic acid, DHA) (Deckelbaum and Torrejon, 2012) give rise to anti-inflammatory, pro-resolving mediators such as protectins, resolvins, and maresins and protect against pro-inflammatory stimuli (Duvall and Levy, 2016). Previous studies linked between higher dietary intake of omega-3 fatty acids decreases in cardiovascular risk/atherosclerosis (Jain et al., 2015), and the morbidity in asthma (Papamichael *et al.*, 2018).

The aim of the work was to study the different effects of formalin inhalation on the structure of the lung and heart tissues and the possible protective role of omega-3 in experimental rats by histological and immune-histochemical studies.

MATERIALS AND METHODS

Drugs:

Formaldehyde (FA) 10% concentration solution was brought from El Nasr pharmaceutical chemicals Company, Egypt.

Omega-3 is available in the form of liquid syrup; Sigma pharmaceutical industries, (Efalex 120 ml) composition per 5 ml: high DHA Fish oil 640 mg, Rigel evening primrose oil 213 mg, D α -tocopherol acetate, thyme oil 0.40 mg, equivalent to vitamin E 7.82 mg.

Animals:

Thirty adult male albino rats, aging 4 - 6 months and weighing 200 - 250 gm. The animals were obtained from the Animal House, Faculty of Medicine, Assiut University, and were housed in the Animal Facility at Faculty of Medicine, Sohag University, Egypt. All rats were given access to a rodent chow diet and water. The experiment was performed according to the "Guide for the Care and Use of Laboratory Animals" Institute of Laboratory Animal Resources (2011) and in accordance with the guidelines of the University Animal Ethics and approved by the Research Ethics Committee considering care and use of laboratory animals.

Experimental Design:

After a 7-day of acclimatization, rats were equally divided into three groups as follows:

Group I (Control Group): It was composed of 10 adult male albino rats. They were not subjected to any treatment.

Group II (Formaldehyde Exposure Group): It included 10 adult male rats subjected to formaldehyde inhalation released from a cotton piece placed in a small glass box inside the cages and soaked with 10% FA solution. . The cotton piece was replaced every one hour to keep a constant concentration. These animals were subjected to formaldehyde inhalation for 8 hours/day. This was done for 6 days/week for four weeks. (Sayed *et al.*, 2013; Isaac and Saad, 2018).

Group III (Formaldehyde and Omega-3 group): included 10 adult male rats subjected to formaldehyde inhalation as Group II and orally administered with 300 mg/kg/day of Omega-3 for 4 weeks using sterilized rats stomach tube. (El Desouky *et al.*, 2019).

After 24 hours from the last dose, rats were anesthetized using ether inhalation, carefully dissected, and the specimens from the lung and the left ventricle of the heart were taken.

Preparation of The Specimens for Light Microscopic Examination:

Perfusion fixation was used; the specimens were fixed in 10% neutral buffered formalin and processed for light microscopic study. Paraffin sections of 6 μ m thickness were obtained for Haematoxylin, and eosin, Masson trichome, and Immunohistochemical stains (Drury and Wallington, 1980).

Immunohistochemical Methods:

Immunohistochemical staining was carried by avidin biotin peroxidase complex method. The specimens from the lungs and cardiac muscles were processed. Caspase-3,

(mouse monoclonal antibody and anticlaved caspase-3 rabbit polyclonal antibody (Neo Markers Fermont, CA 94539, USA) were used for detection of apoptosis. The reaction appeared brownish either cytoplasmic or nuclear. Sections were then counterstained with Mayer's hematoxylin (HX), dehydrated, cleared, and mounted. Tonsils were used as positive control tissues. Negative control was performed after omitting the primary antibody (Remick *et al.*, 2006).

Paraffin sections were also stained with avidin-biotin-peroxidase for demonstration of cells immunoreactive to TNF- α (Minneapolis, Minnesota, USA), and counterstained with HX. TNF- α expression was a cytoplasmic immunopositive reaction (Dabbs, 2002).

Morphometric Study and Statistical Analysis:

Collagen quantification Semi-automated image analysis was applied (Schipke *et al.*, 2017). From each Masson's trichrome stained section, five random fields for each group were selected and imaged using an objective lens magnification of 10x for lung sections, 20x for heart sections. ImageJ software (version 1.51k, Wayne Rasband, National Institutes of Health, USA) was used for the analysis.

Variables were represented by mean \pm SD (Mean \pm standard deviation of mean). The SPSS program version 16 was used to analyze the differences among all groups in all the data parameters by one-way analysis of variance and a post-hoc test was used to find the statistical difference between the groups when ANOVA was statistically significant (P value ≤ 0.05) (Dean *et al.*, 2000).

RESULTS

Lung Tissue:

Anatomical Results:

The morphological appearance of the lungs of the control group (I) revealed the normal rosy pink color of the examined lobes with regular borders and normal shape. There was no change in size with no air cystic changes or abnormal masses (Fig. A).

The gross morphological changes in the lungs of group II (FA exposed) revealed congestion in all lobes with increased pulmonary vascular marking. The lungs appeared smaller in size with a prominent mass in one of the treated lungs (Fig. B). The gross morphological changes in the lungs of the group III (FA and omega-3 exposed) animals revealed mild congestion in some lobes with no significant changes in the size. The lungs had normal shape and borders with no air cystic changes or abnormal masses (Fig. C).

Histological Results:

Control group (I) revealed normal pulmonary tissue architecture with clear patent bronchial passages and alveolar cavities including the alveolar sacs, the alveolar ducts, and the alveoli. The alveolar septa had normal thickness with no abnormality in alveolar septal blood capillaries. Normal collagen fibers distribution in lung tissues (Figs. 1 & 4).

Group II (four weeks FA exposure) specimens confirmed the gross morphological changes with loss of normal lung architecture and destructed alveoli. There were focal pneumonic granulomas with massive inflammatory infiltrate and apparent hemorrhage in-between alveoli. Massive collagen distribution was found in lung tissues (Figs. 2 & 5).

Group III (FA and omega 3 exposed) showed restoration of normal lung architecture with normal appearance of alveoli and sinuses, Still, inflammatory infiltrate appeared mainly around blood vessels. Minimal collagen deposition appeared in the lung interstitium (Figs. 3 & 6).

Immunohistochemical Reaction:

For TNF- α : a negative reaction in the control group (Fig. 7) whereas in the group II positive immunohistochemical staining of TNF- α observed in alveolar interseptal region,

muscle cells surrounding the bronchi and bronchioles, and the epithelium of the bronchi and bronchioles (Fig. 8) Minimal positive immunohistochemical staining of TNF- α was observed in the alveolar interseptal region in the group III (Fig. 9).

For caspase-3: the control group, showed a mild positive reaction (Fig. 10). In the FA-exposed group, there was a massively positive reaction compared to the control group (Fig. 11). Whereas, FA and omega-3 showed moderate positive reaction (Fig. 12).

Cardiac Muscle:

Anatomical Results:

No gross abnormalities or changes observed between hearts in the three groups

Histological Results:

Control group (I) Light microscope showed cardiac myocytes in a longitudinal section with prominent striations. Cardiac muscle fibers had acidophilic cytoplasm and central, vesicular, and oval nuclei with a rich capillary network (Fig. 13), with scanty collagen fiber (Fig. 16).

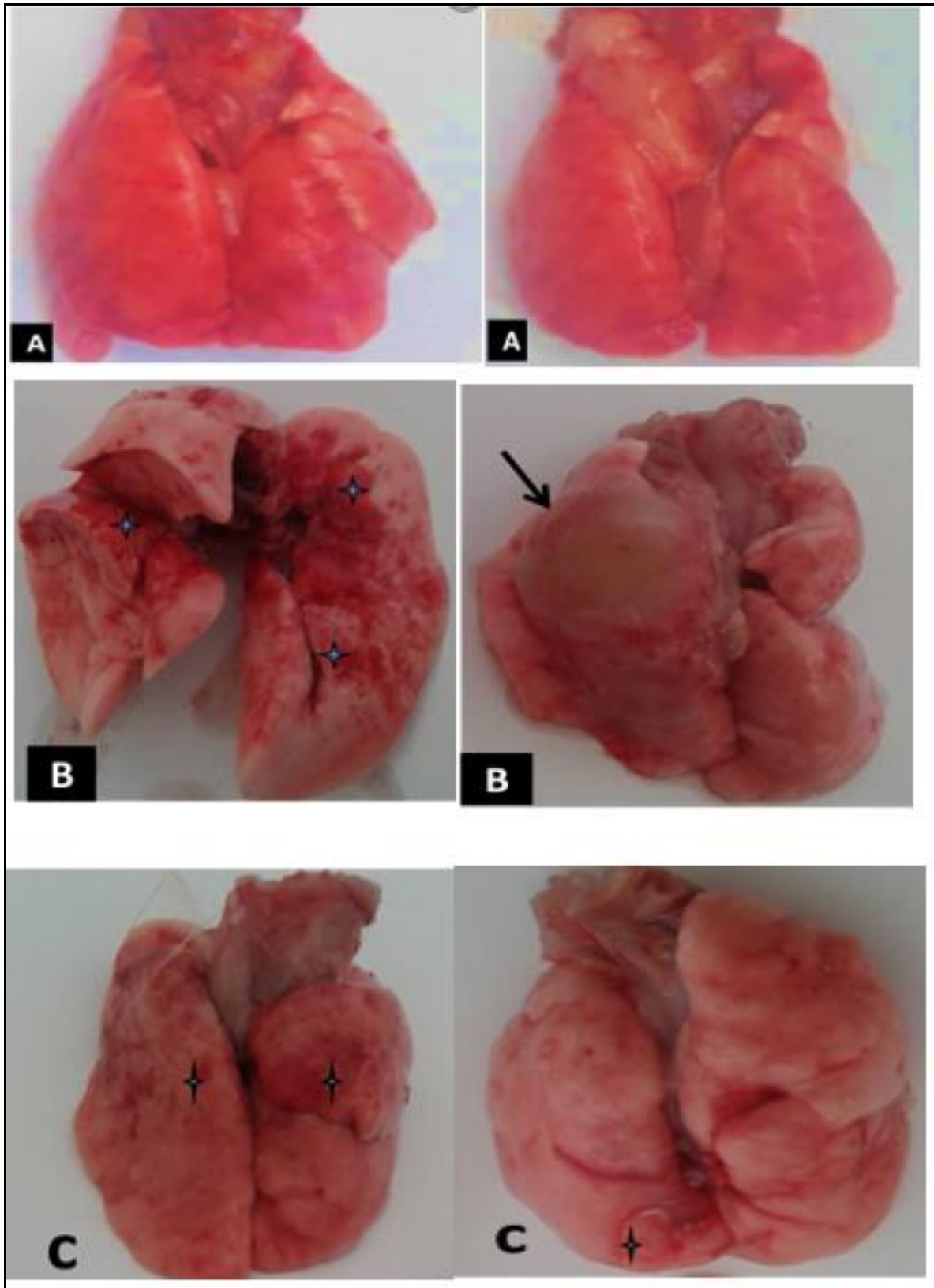
Group II (four weeks FA exposure) showed irregular, shrunken, and widely separated cardiomyocytes with pyknotic nuclei. Hemorrhage and Inflammatory cells infiltration were observed in the widened interstitium (Fig. 14). Abundant collagen fibers were seen in-between the cardiomyocytes (Fig. 17).

group III (FA and omega 3 exposed) showed restoration of the normal picture of the cardiac muscle with acidophilic cytoplasm and vesicular, oval nuclei (Fig. 15), A considerable amount of collagen fibers were seen in-between the cardiomyocytes (Fig. 18).

Immunohistochemical Reaction:

For TNF- α , a negative reaction in the control group (Fig.19), whereas in group II positive immunohistochemical staining of TNF- α was observed in-between cardiac muscle fibers. (Fig. 20) and negative immunohistochemical reaction of TNF- α was observed in group III (Fig. 21).

For caspase- 3, the control group showed a negative reaction (Fig. 22). In the FA-exposed group; there was a positive reaction compared to the control group (Fig. 23). FA and omega 3 showed a negative reaction (Fig. 24).



A: Gross picture of lung of control rats showing normal rosy pink color of the examined lobes.

B: Gross picture of lung of FD treated rats showing marked congestion (**stars**), with prominent mass in one of the treated lungs (**arrow**).

C: Gross picture of lung of FD and Omega treated rats showing mild congestion (**stars**), with normal shape and borders of lungs.

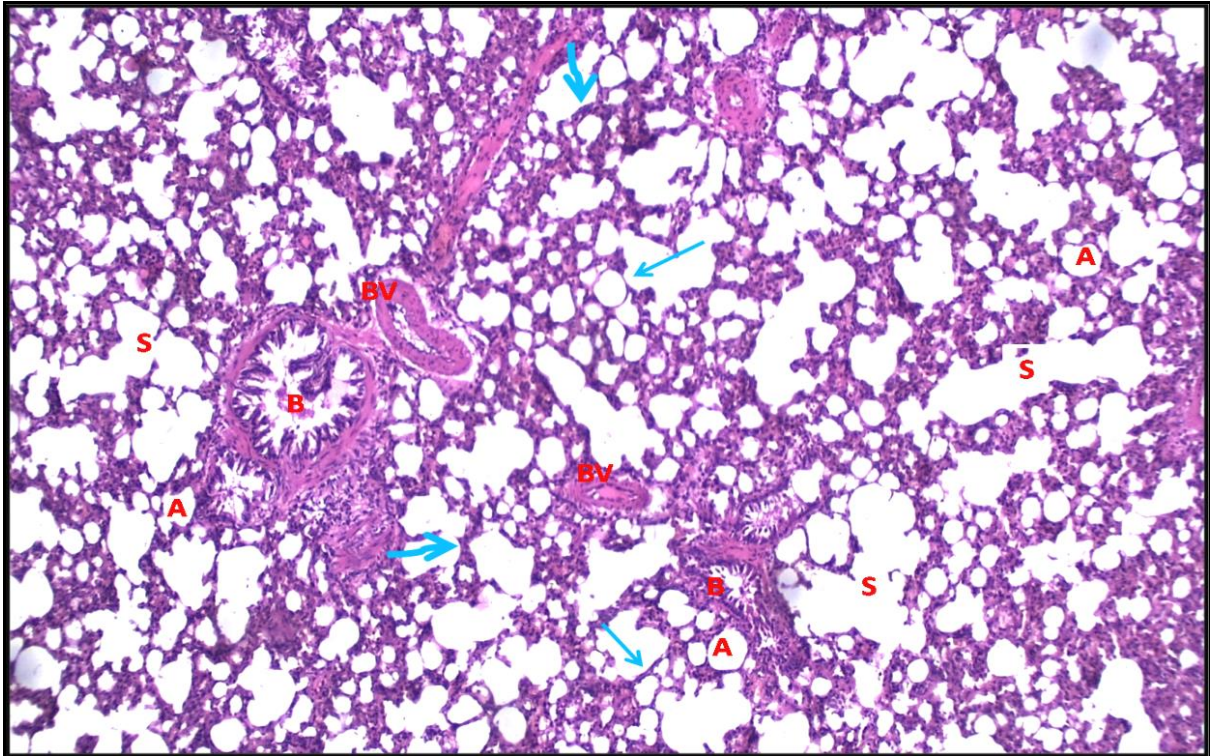


Fig.1: Transverse section of the lung of **Control lung (group I)** showing normal lung architecture with alveoli (A), alveolar sacs (S), thin (thin arrow) and thick (thick arrow) portions of the interalveolar septa, bronchioles (B), and blood vessels (BV). **H&E X 100.**

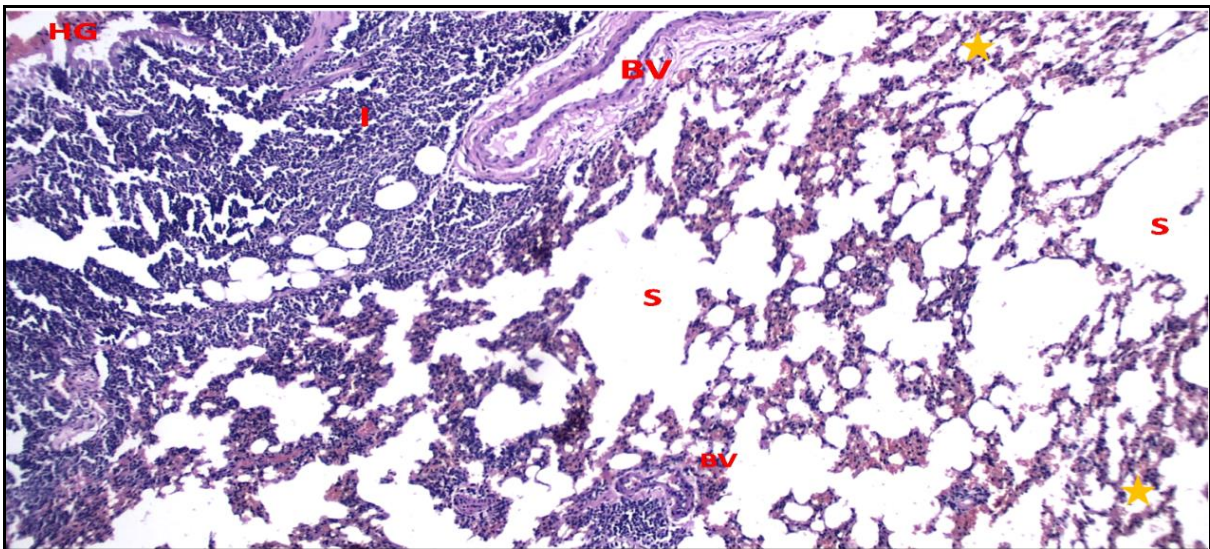


Fig. 2: Transverse section of the lung of group II (treated with formalin only) showing loss of lung architecture and destruction of alveoli (stars), dilated sinuses (S), infiltration of inflammatory cells (I) around the blood vessels, and hemorrhage (HG). **H&EX100.**

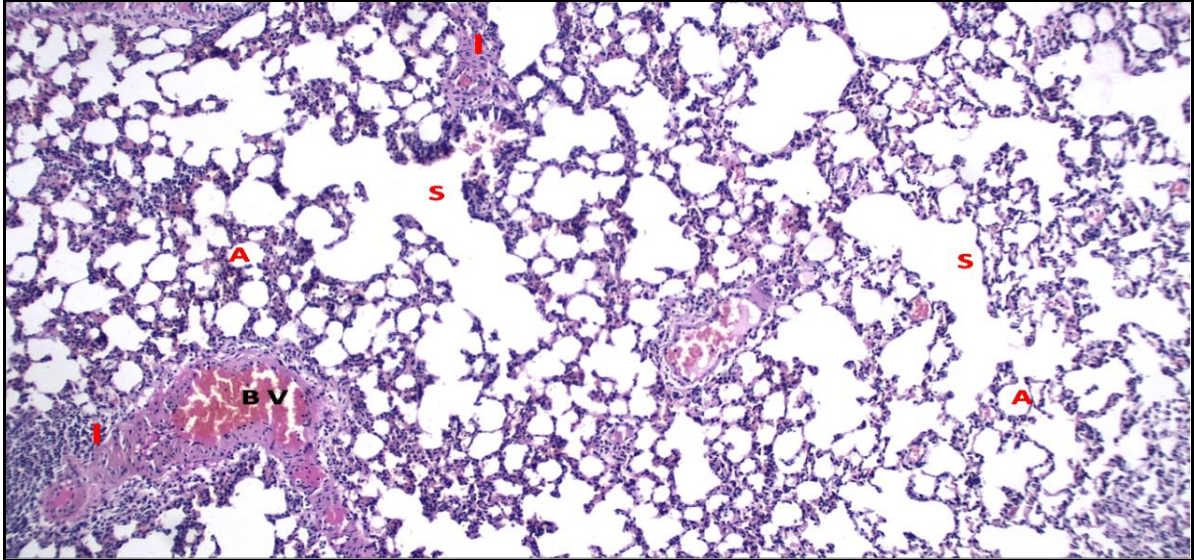


Fig.3: Transverse section of the lung of **group III (treated with Formalin and omega-3)** showing restoration of normal lung architecture with normal appearance of alveoli (A) and sinuses (S), Still Inflammatory infiltrate (I) appears mainly around blood vessels (BV). **H&E X 100.**

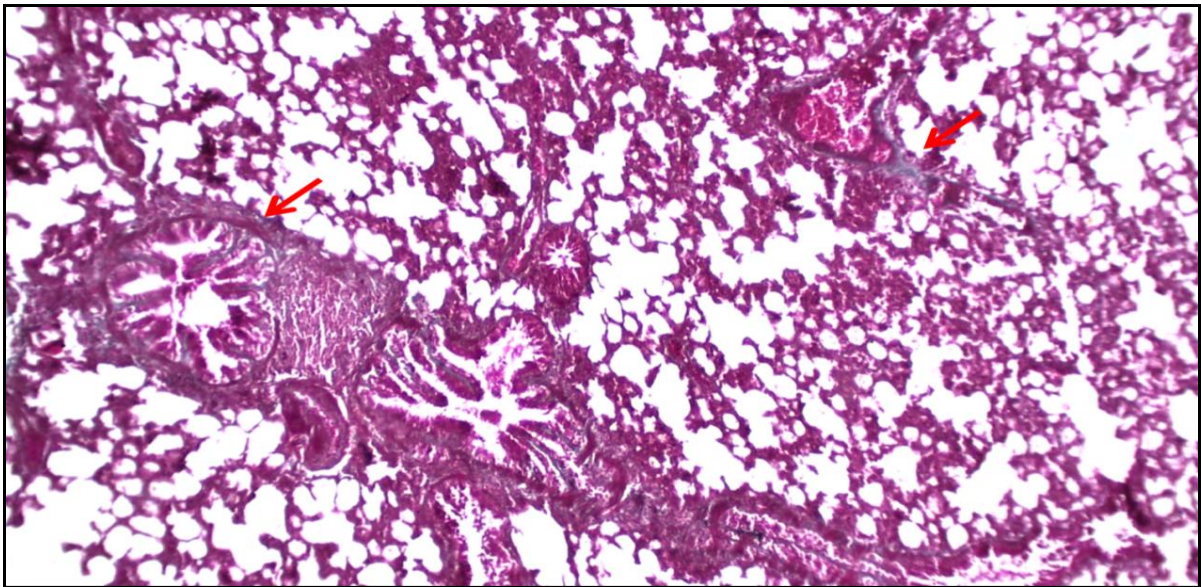


Fig.4: Transverse section of the lung of Control lung (group I) demonstrating normal collagen fibers distribution in lung tissues (arrows). **Masson's trichrome X 100.**

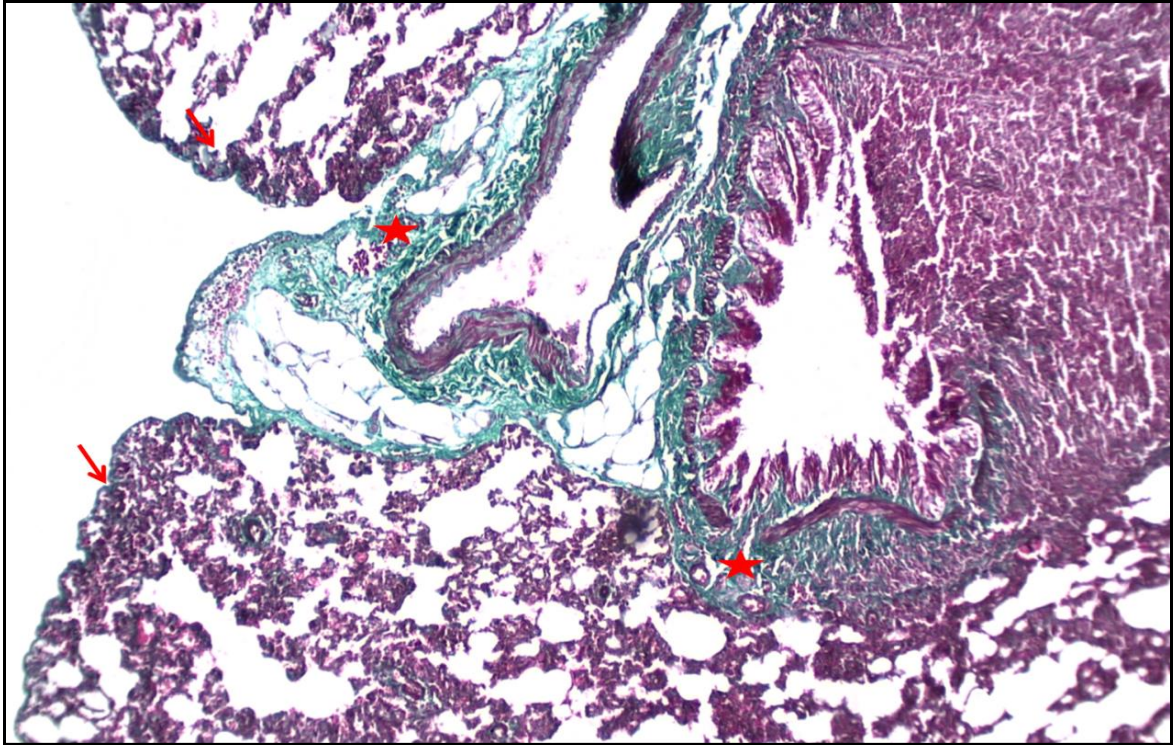


Fig.5: Transverse section of the lung of **group II** (treated with Formalin only) demonstrating extensive collagen deposition are recognized in the lung interstitium (arrows) and around bronchioles (stars). **Masson's trichromex 100**

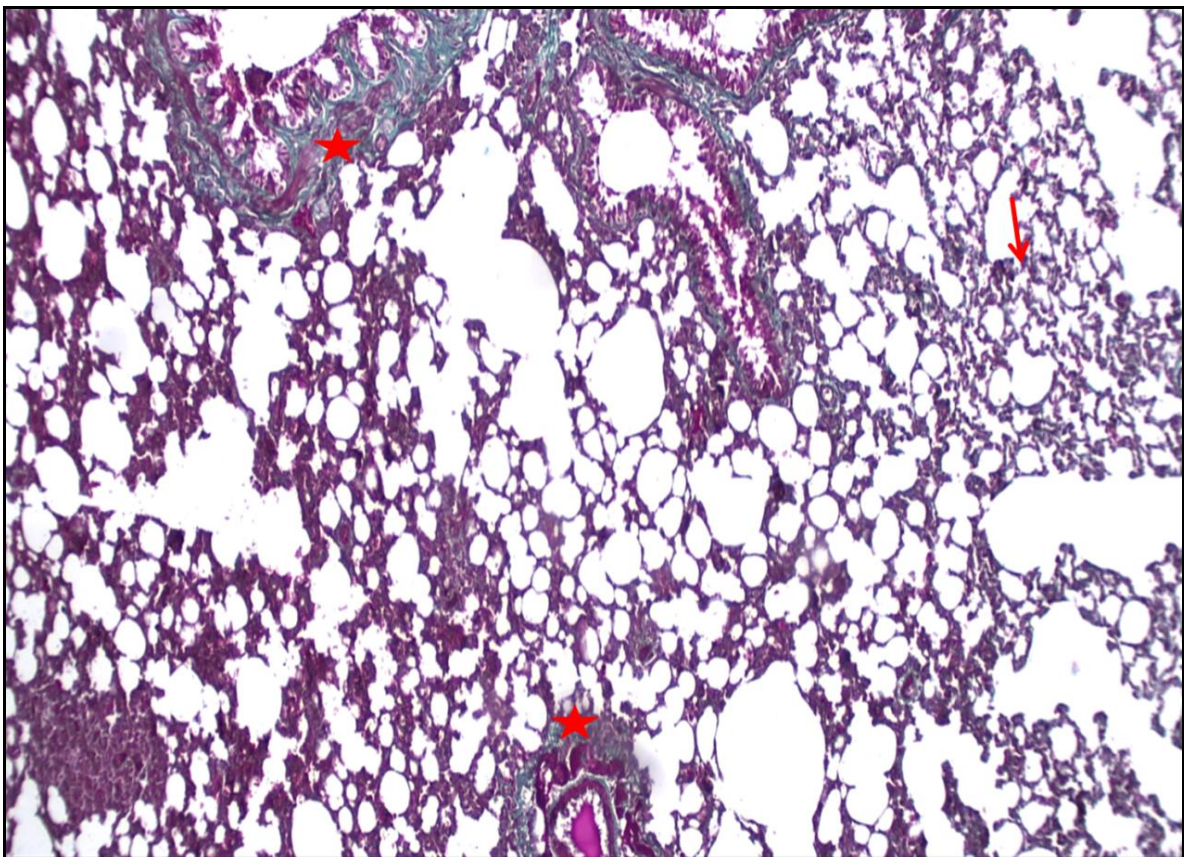


Fig.6: Transverse section of the lung of **group III** (treated with Formalin and omega-3) demonstrating minimal collagen deposition in the lung interstitium (arrow) and around bronchioles (stars). **Masson's trichrome x 100**

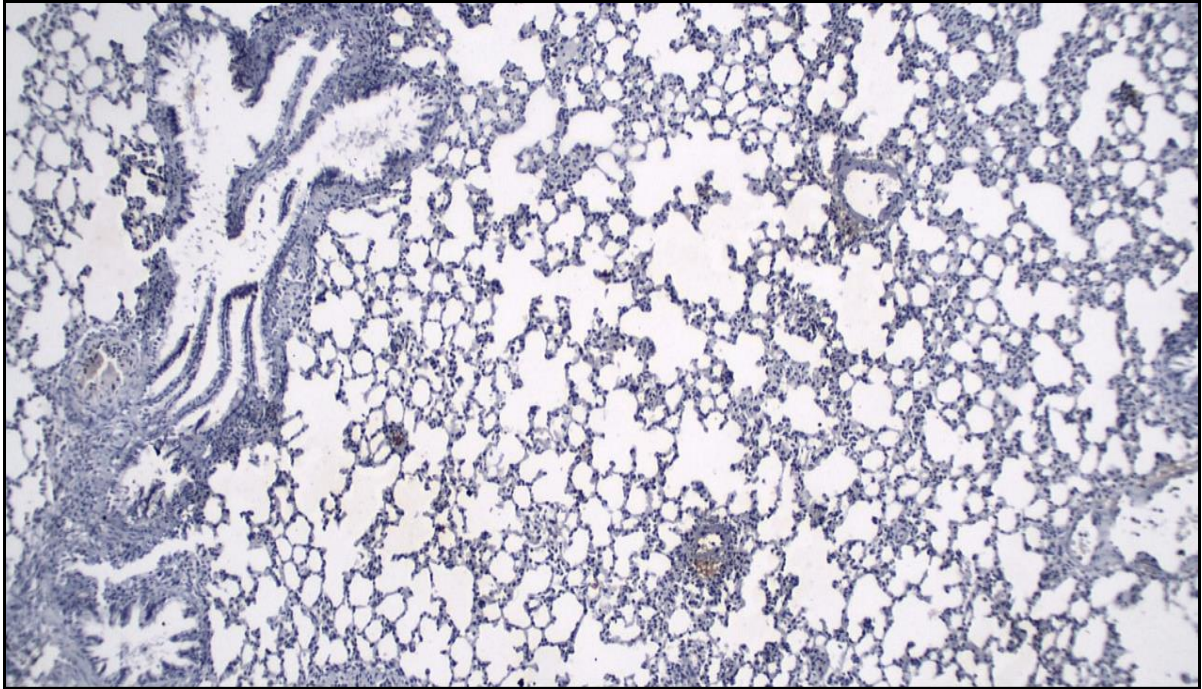


Fig.7: Transverse section of the lung of Control lung (group I) showing negative reaction for TNF- α between lung tissues. TNF- α \times 100

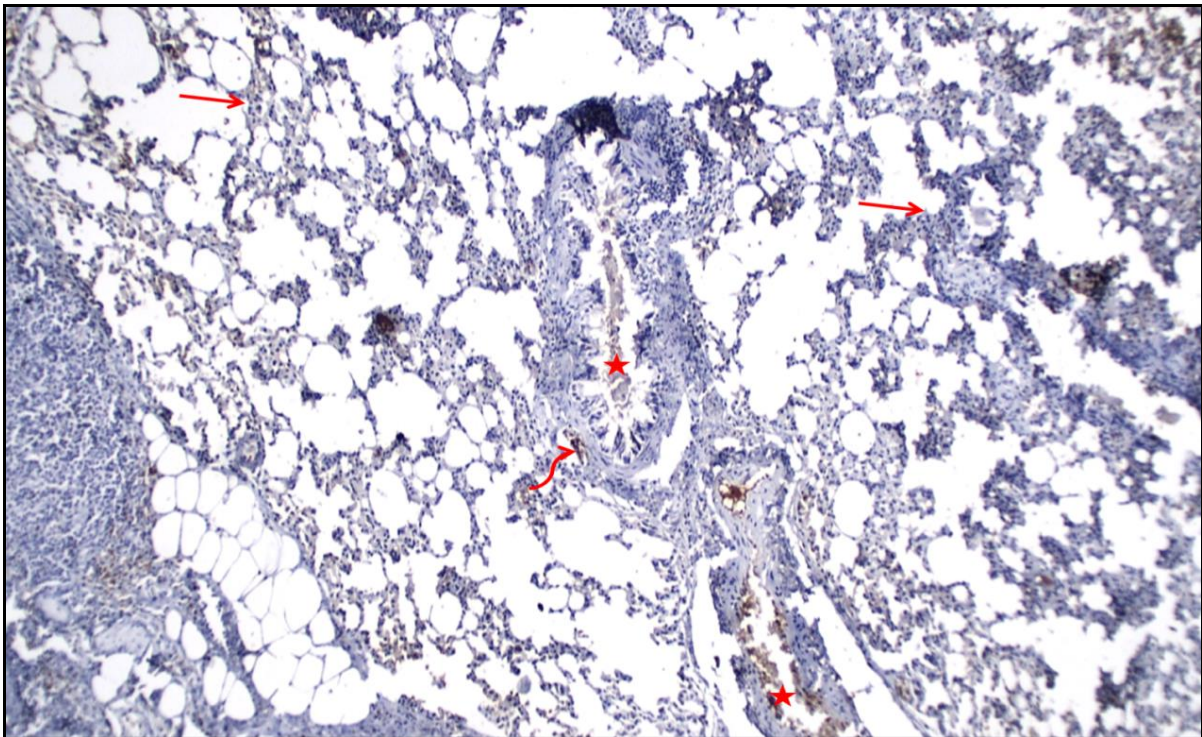


Fig.8: Transverse section of the lung of **group II (treated with Formalin only)** showing a positive immunohistochemical staining of TNF- α observed in alveolar interseptal region (arrows), muscle cells surrounding the bronchi and bronchioles (irregular arrow), the epithelium of the bronchi and bronchioles (stars) TNF- α (\uparrow). TNF- α \times 100

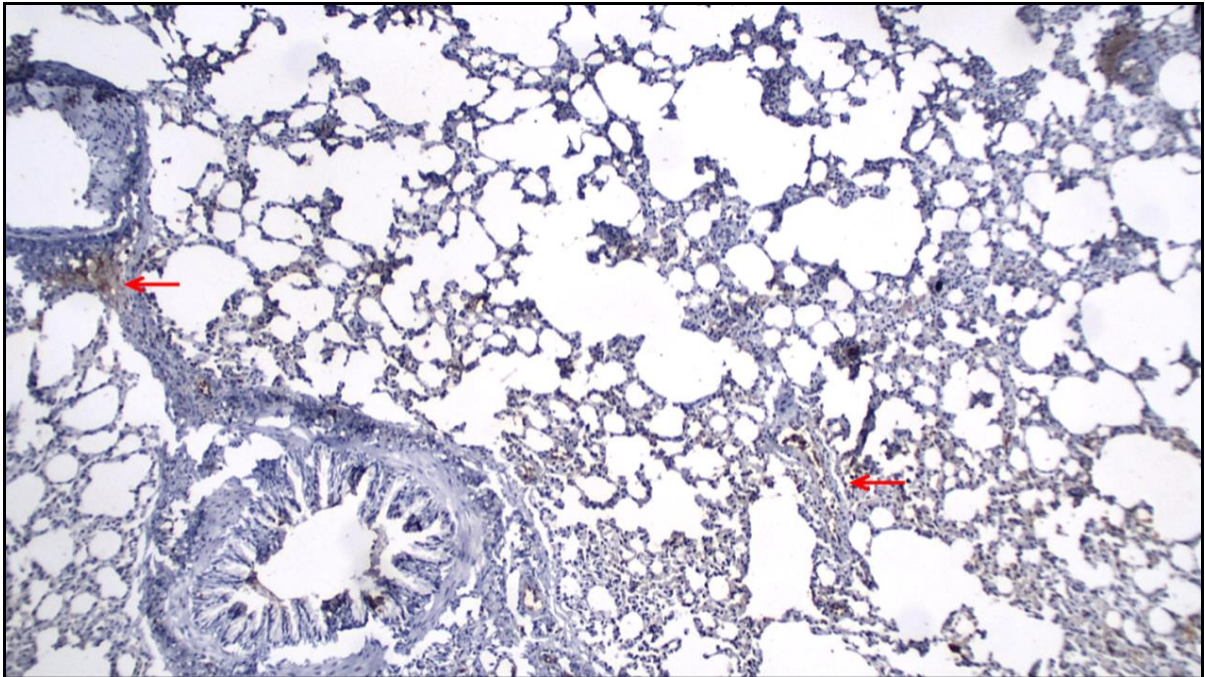


Fig.9: Transverse section of the lung of **group III (treated with Formalin and omega-3)** showing minimal positive immunohistochemical staining of TNF- α observed in alveolar interseptal region(arrows). **TNF- α \times 100**

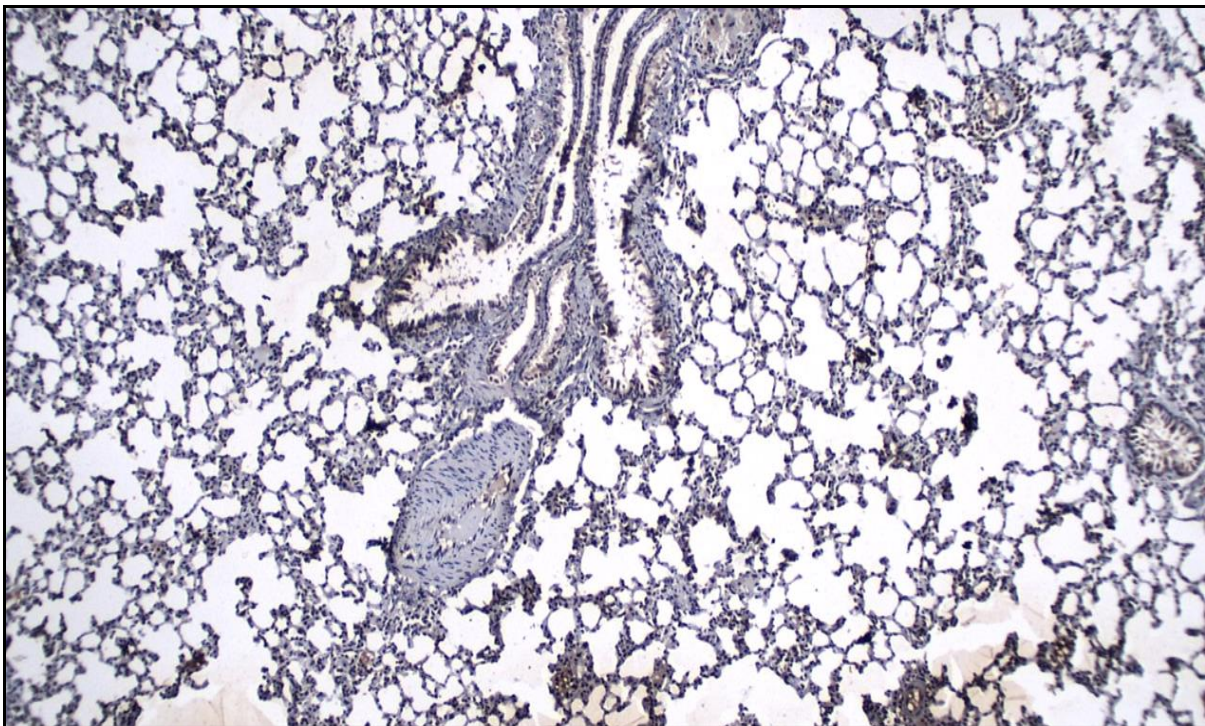


Fig.10: Transverse section of the lung of Control lung (group I) showing mild positive reaction for caspase-3 in the wall of bronchi and alveoli. **Caspase-3 \times 100**

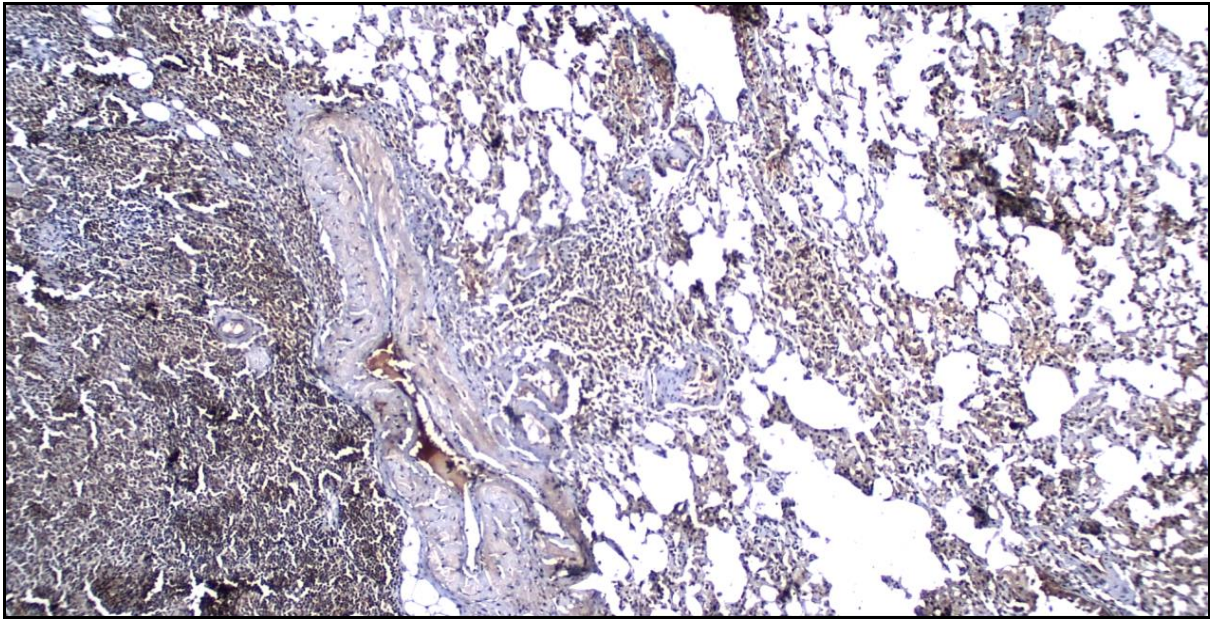


Fig.11: Transverse section of the lung of **group II (treated with Formalin only)** showing Massive caspase-3-positive cells were observed at the walls of bronchi and alveoli.
Caspase-3× 100

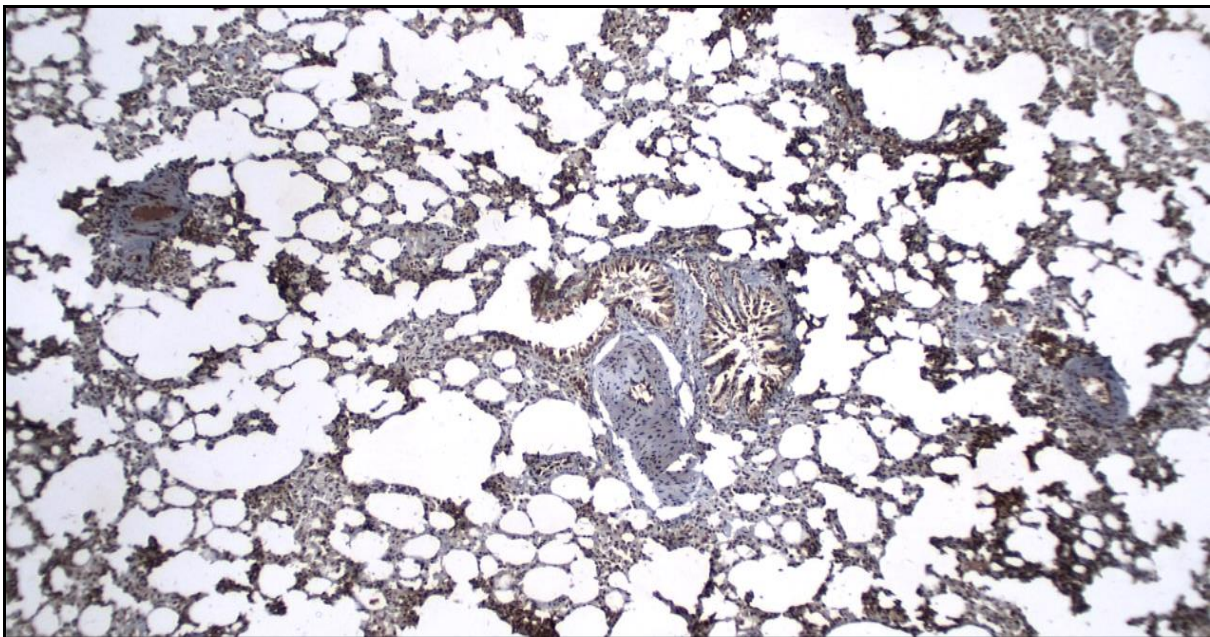


Fig.12: Transverse section of the lung of **group III (treated with Formalin and omega-3)** showing moderate reaction of caspase-3observed at the walls of bronchi and alveoli.
Caspase-3× 100

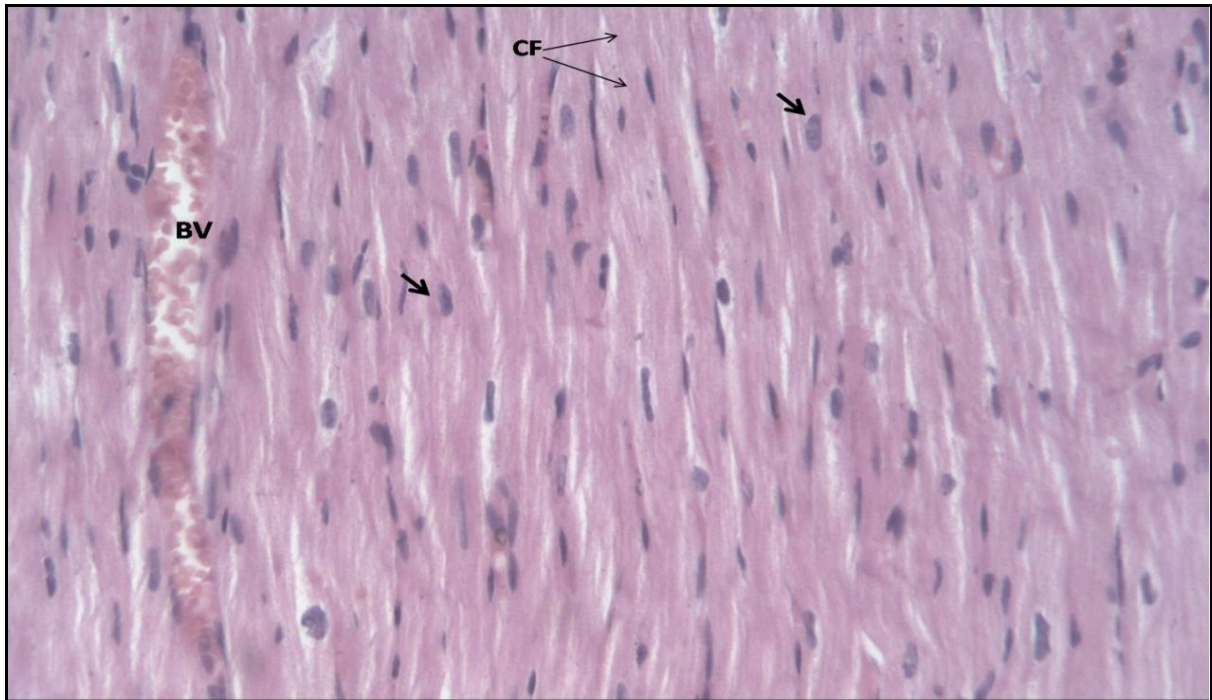


Fig.13: Control heart (group I) showing; longitudinally arranged cardiac muscle fibers which have acidophilic cytoplasm and central, vesicular and oval nuclei (short arrow). They have obvious longitudinal striation cardiac fiber (CF). Note: Blood vessels (BV) are observed. **H&E X 200.**

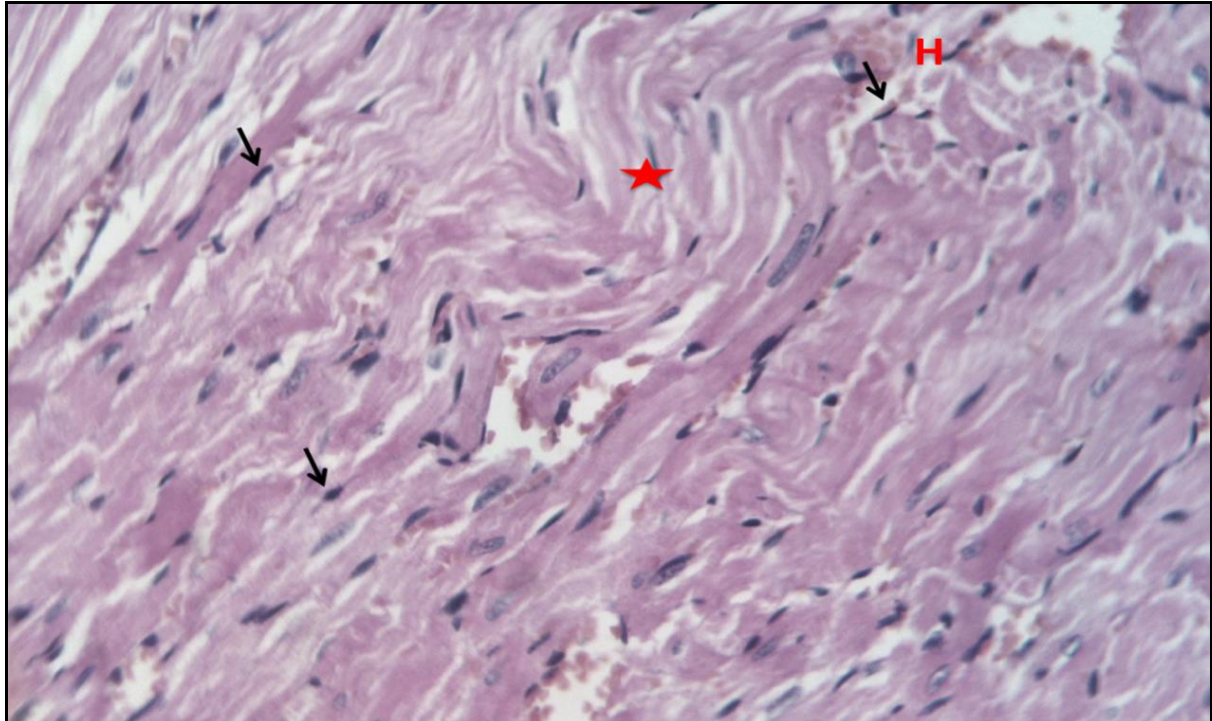


Fig.14: Formalin treated heart (group II) showing shrinkage and irregularity of cardiac fibers (star) which have acidophilic cytoplasm and pyknotic nuclei (short arrow) with hemorrhage in-between cells. **H&E X 200.**

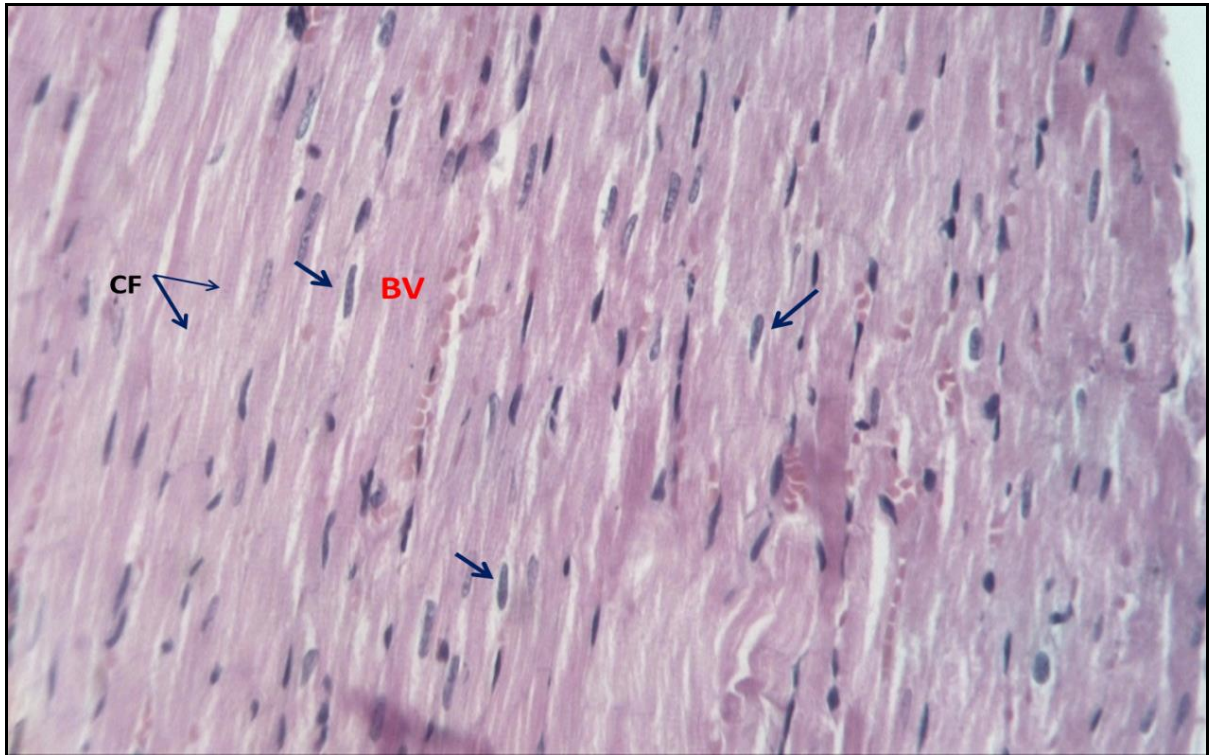


Fig.15: Formalin and omega-3 treated heart (group III) showing longitudinally arranged cardiac muscle fibers which have acidophilic cytoplasm and vesicular, oval nuclei (short arrow) with obvious longitudinal striation cardiac fiber (CF). also with normal appearance of Blood vessels (BV). H&E X 200.

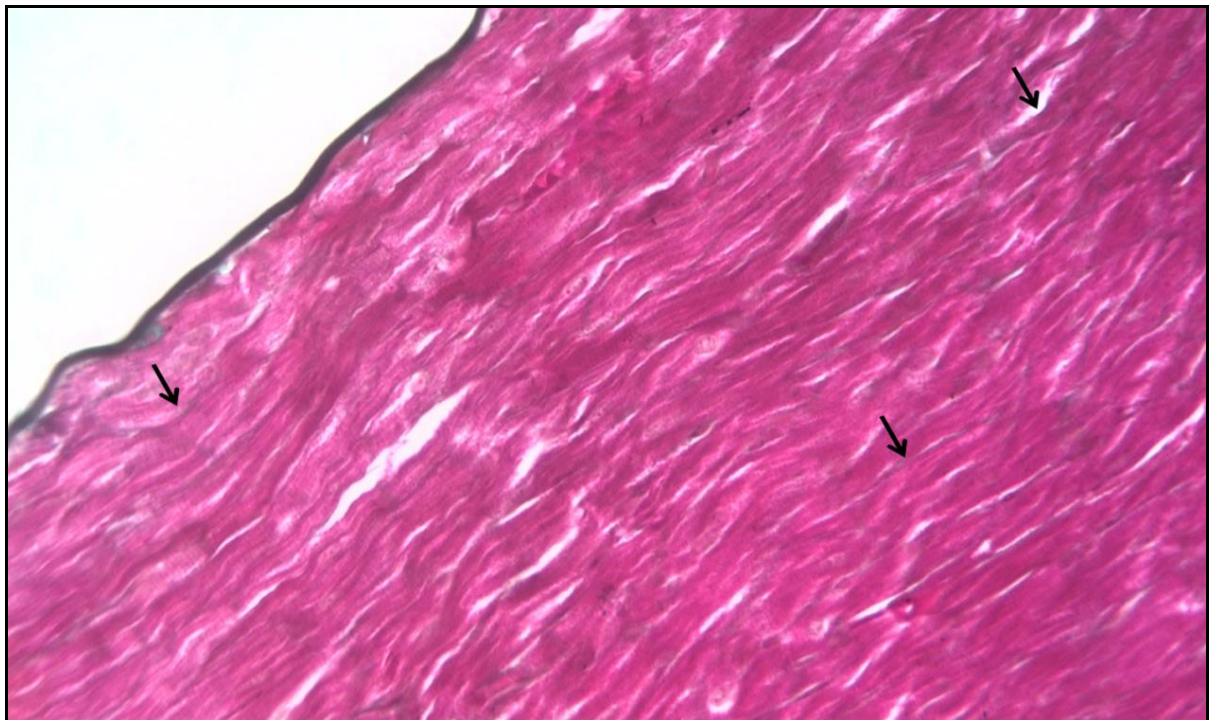


Fig.16: Control heart (group I) showing Scanty content of collagen fibers can be seen in-between the cardiomyocytes (↑). **Masson's trichrome x 200.**

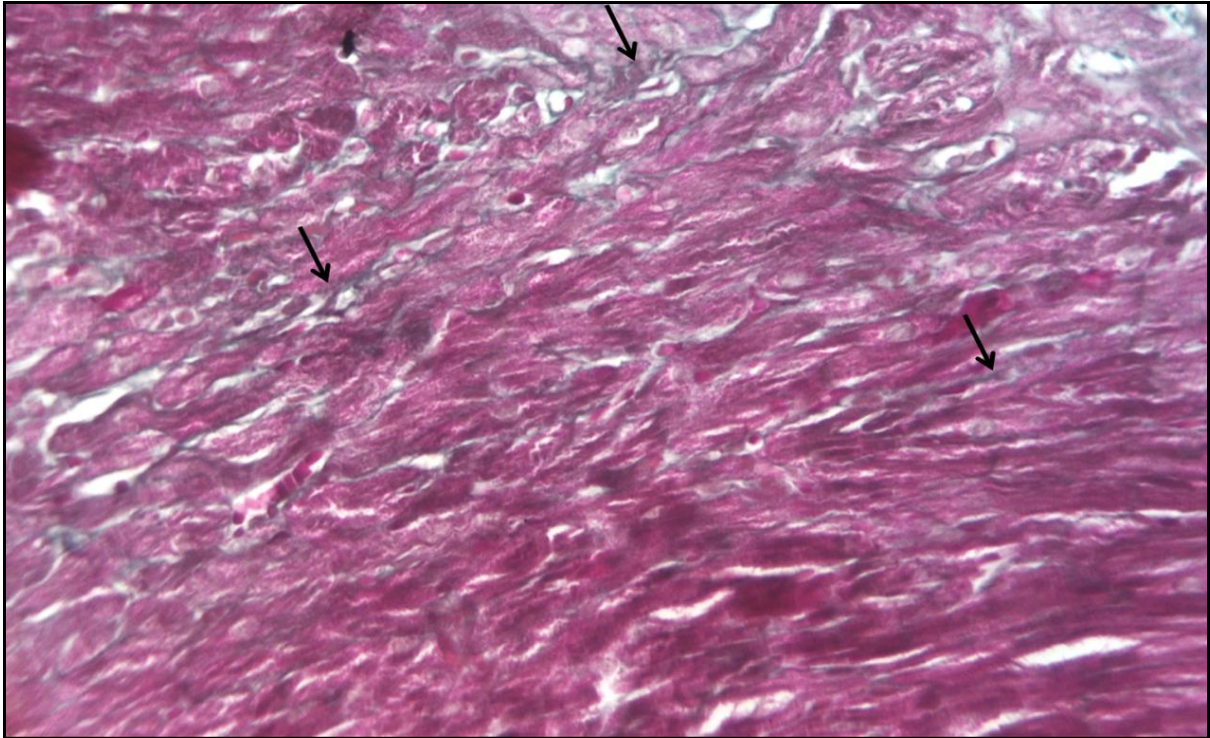


Fig. 17: Formalin treated heart (group II) showing abundant collagen fibers seen in-between the cardiomyocytes (↑) Masson's trichrome x 200.

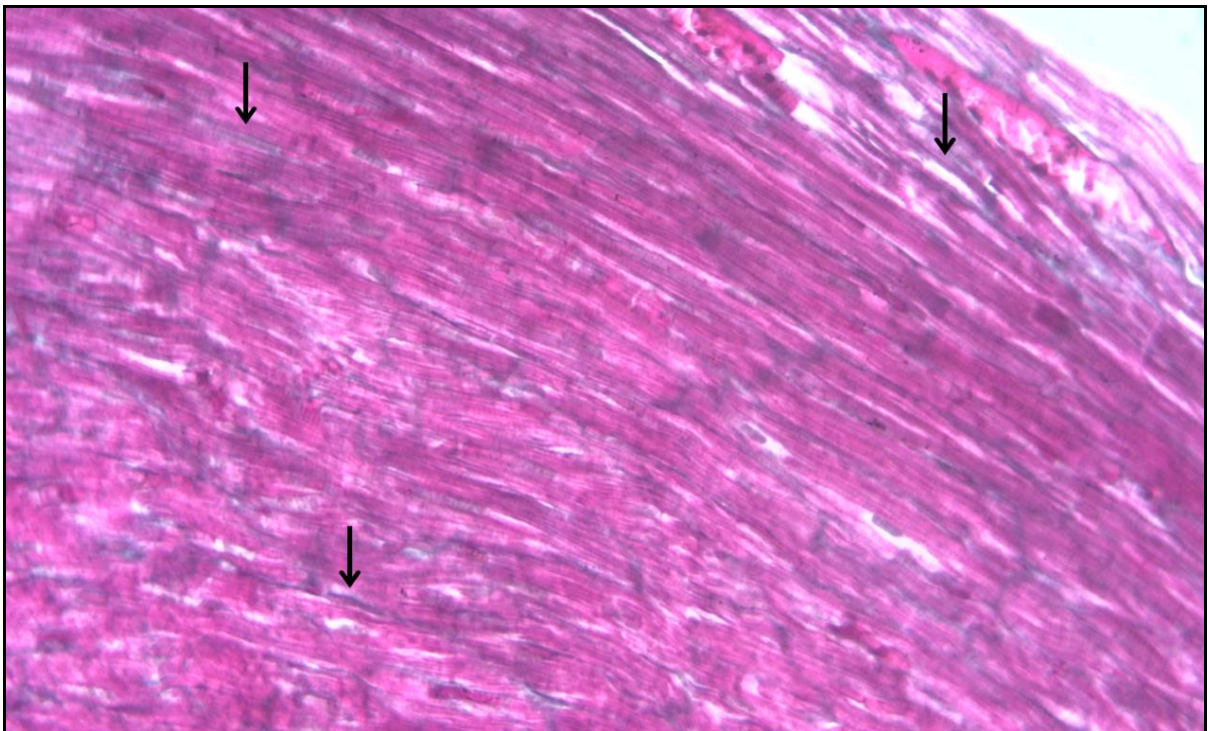


Fig.18: Formalin and omega- 3 treated heart (group III) showing a considerable amount of collagen fibers are seen in-between the cardiomyocytes (↑). Masson's trichrome x 200.

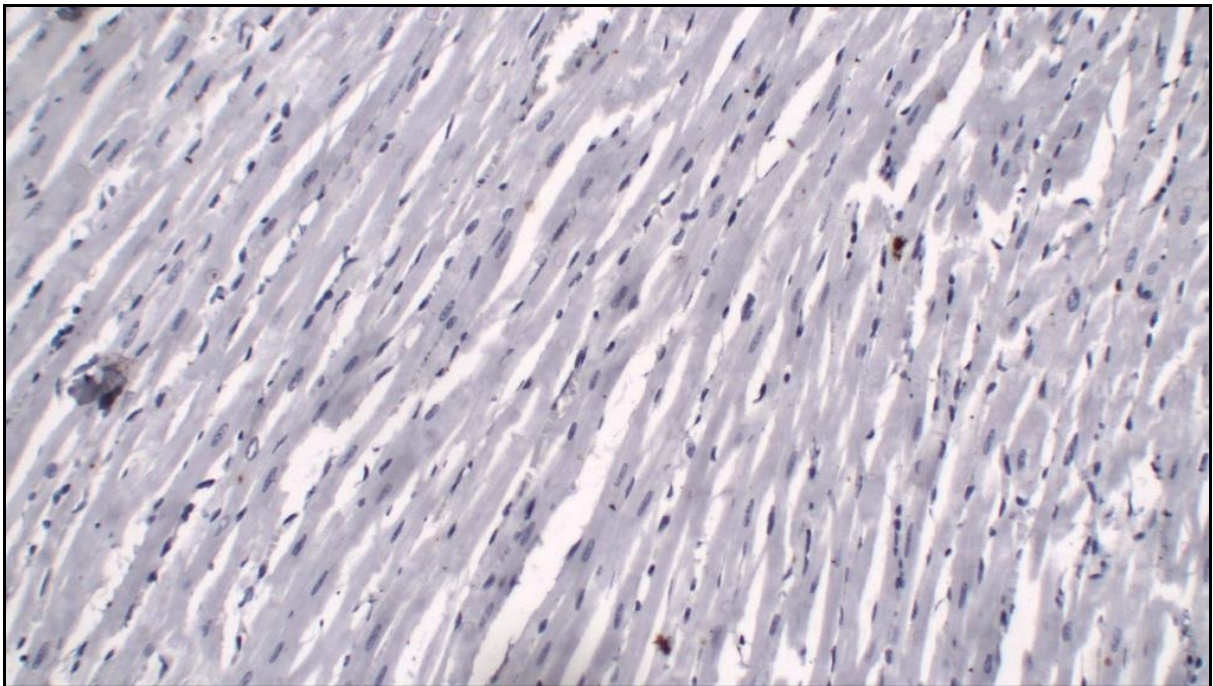


Fig. 19: Control heart (group I) showing negative reaction for TNF- α in-between cardiac muscle fibers (section of cardiac muscles). TNF- α \times 200.

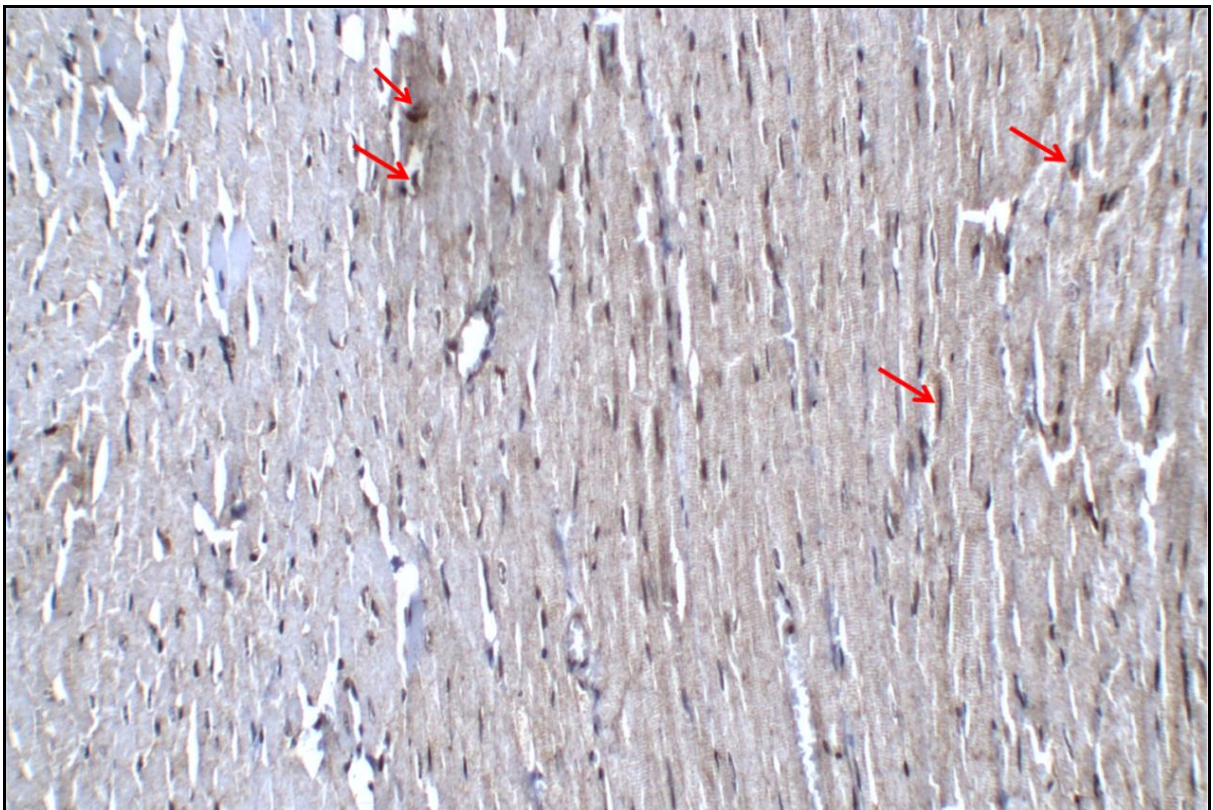


Fig. 20: Formalin treated heart (group II) showing positive immune reaction for TNF- α (\uparrow) (section of cardiac muscles). TNF- α \times 200.

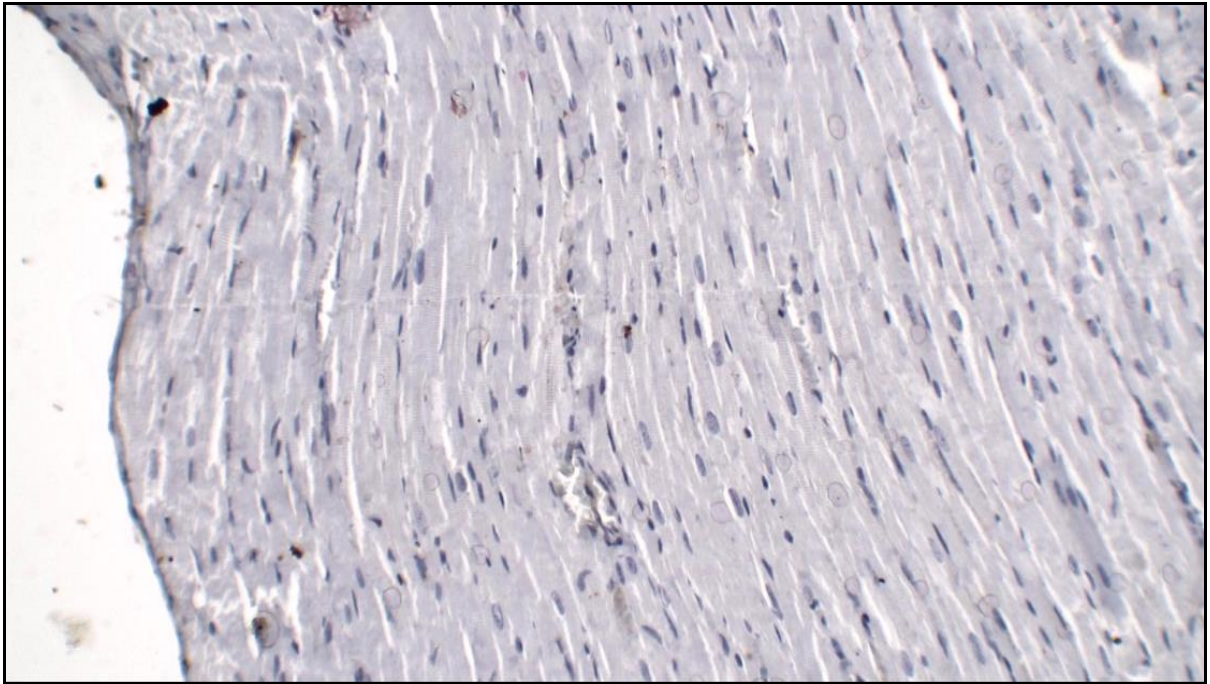


Fig.21: Formalin and omega- 3 treated heart (group III) showing negative reaction for TNF- α between cardiac muscle fibers (section of cardiac muscles). TNF- α \times 200.

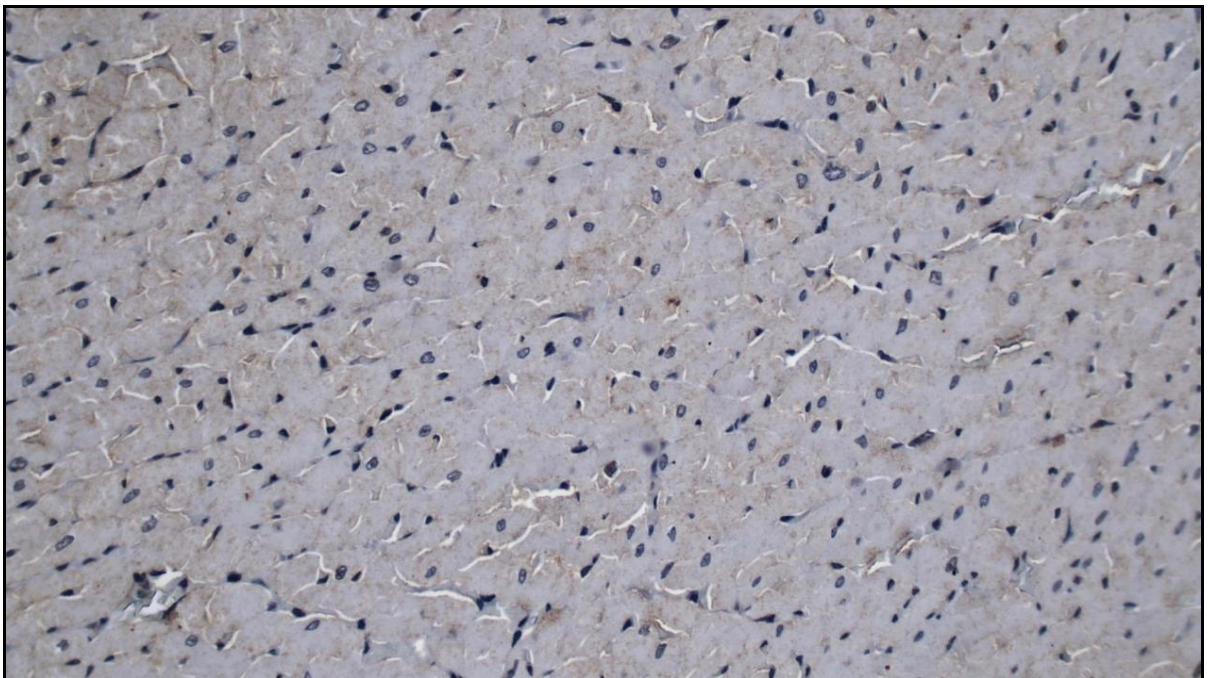


Fig .22: Control heart (group I) showing negative reaction for caspase-3between cardiac muscle fibers (transverse section of cardiac muscles). caspase-3 \times 400.

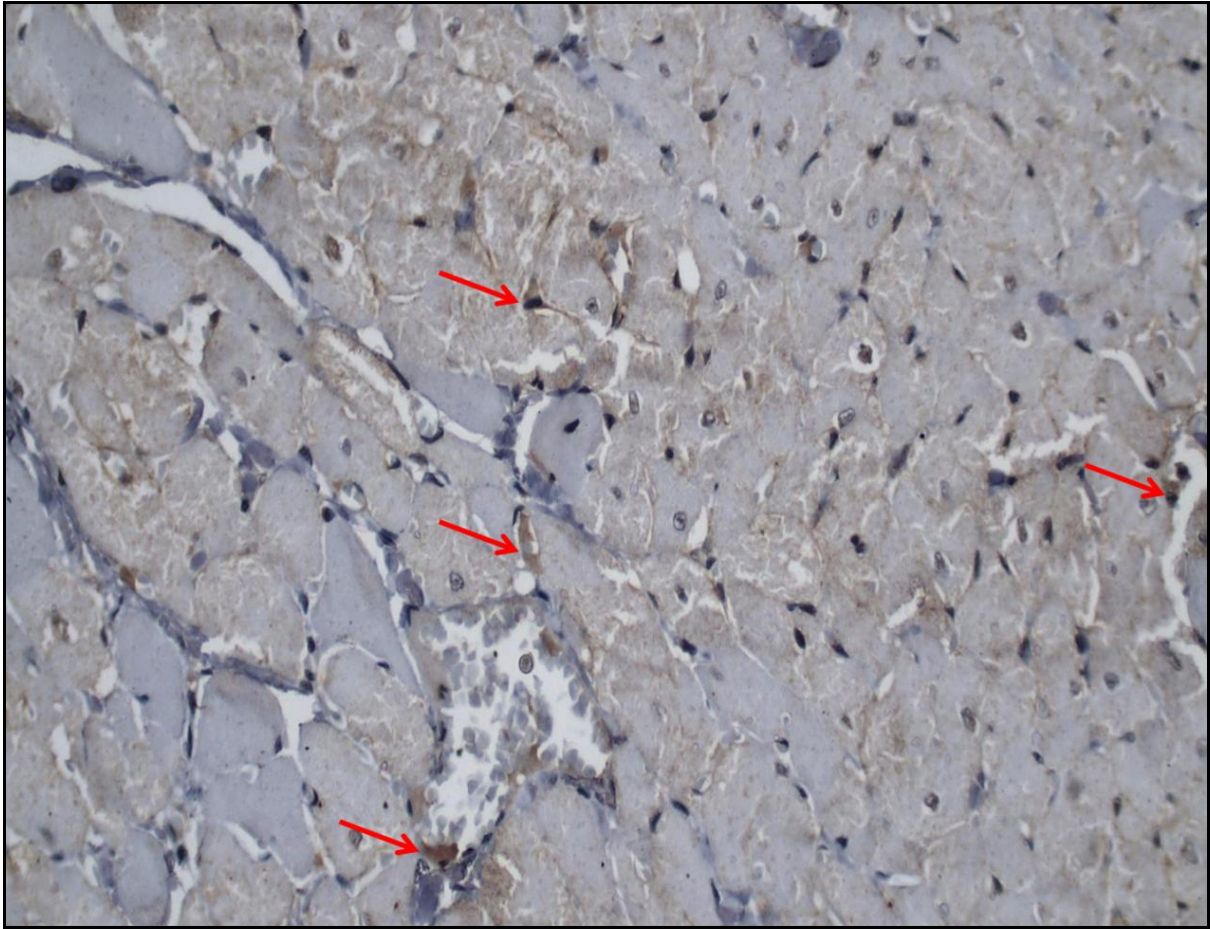


Fig.23: Formalin treated heart (group II) showing positive immune reaction for caspase-3(↑). (transverse section of cardiac muscles) × 400.

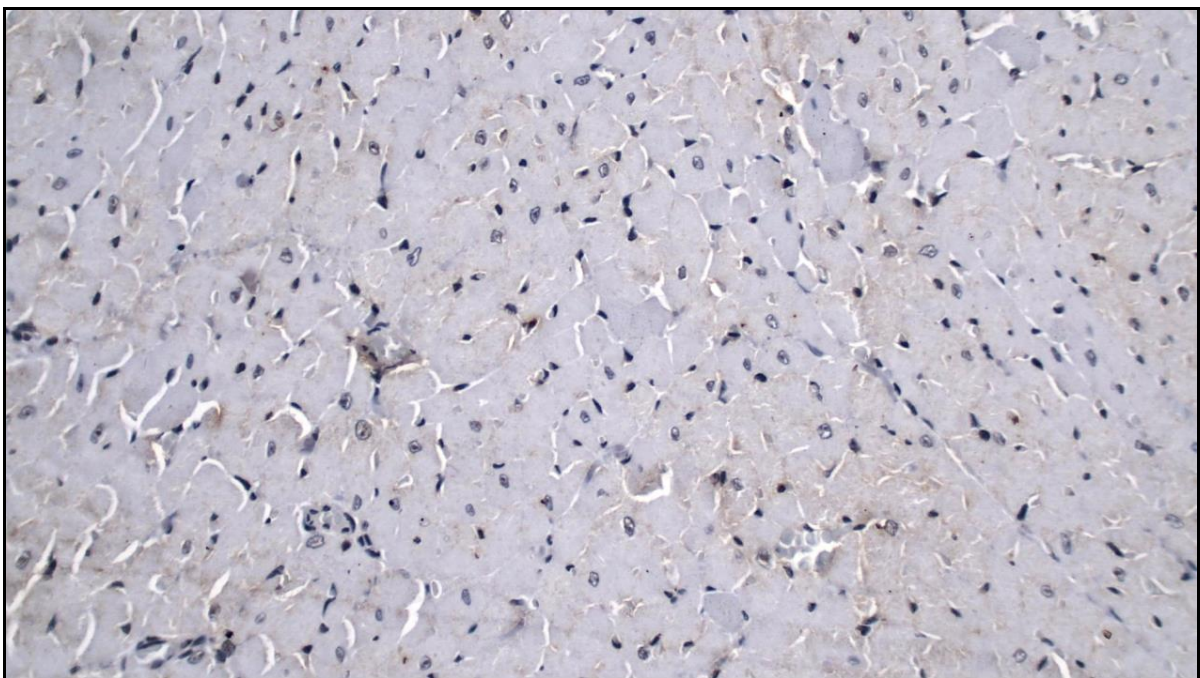


Fig.24: Formalin and omega- 3 treated heart (group III) showing negative reaction for caspase-3between cardiac muscle fibers (transverse section) (transverse section of cardiac muscles). × 400

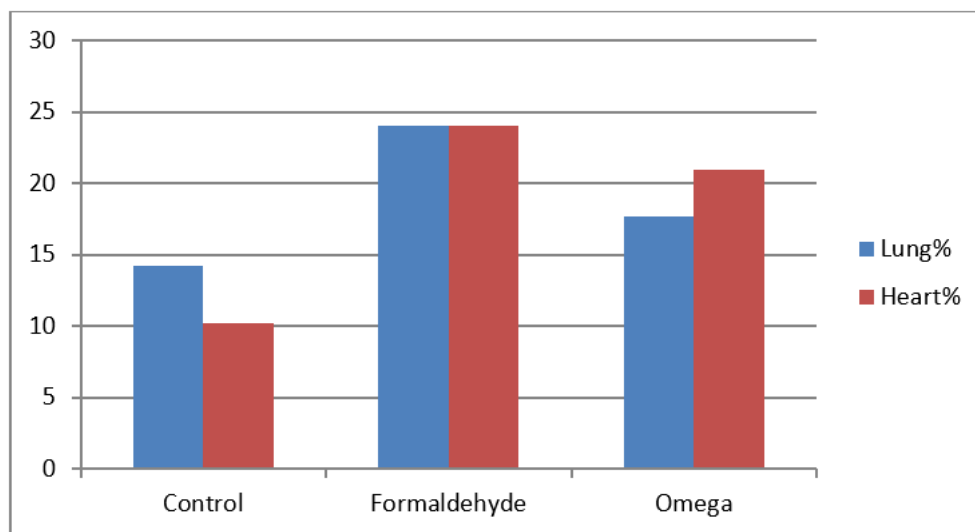
Morphometric Results:

Lung: The mean area percentage occupied by collagen in the formaldehyde group (24 ± 4.8) was a very highly significant increase in comparison to the control group (14.2 ± 3) $p < 0.001$. The mean area percentage occupied by collagen in the formaldehyde +omega group (17.7 ± 3.27) was non-significant changed in comparison to control group $p \leq 0.1$ (Table 1) (Histogram 1).

Heart: The mean area percentage occupied by collagen in the formaldehyde group (24 ± 2.5) was a highly significant increase in comparison to the control group (10.2 ± 4) ($p \leq 0.02$). The mean area percentage occupied by collagen in the formaldehyde +omega group (20.9 ± 3.5) was a very highly significant increase in comparison with control ($p \leq 0.007$). (Table 1) (Histogram 1).

Table 1: showing the mean \pm SD of area percentage of collagen fibers between lung tissue and cardiac myocytes in different groups ($P \leq 0.01$ (**) \rightarrow High significant difference, $P \leq 0.001$ (***) \rightarrow Very high significant difference. ns \rightarrow Non significant).

Groups	Control	Formaldehyde	Omega
lung	14.2 \pm 3	24 \pm 4.8***	17.7 \pm 3.27 ^{ns}
Heart	10.2 \pm .46	24 \pm 2.5**	20.9 \pm 3.5***



Histogram 1: Comparison between the studied groups according to the percentage of the area of collagen in lung and heart tissues

DISCUSSION

The study of the relationship between atmospheric pollution and respiratory health needs to take into account the anatomical, histological, and toxicological effects. Inhalation is the main exposure pathway of these pollutants, which makes the respiratory tract the first target organ of airborne pollutants (Takahashi *et al.*, 2007; Bernstein *et al.*, 2008).

In the present study, the gross morphological study of the lungs exposed to formaldehyde revealed irregular convoluted surfaces of most lungs, increased congestion, and appearance of masses. These results are in agreement with previous studies whereas rats were exposed to formaldehyde for different durations which showed congestion in most lobes and focal pneumonic organization (Khaliq and Tripathi, 2009; Afrin *et al.*, 2016; El Desouky

et al., 2019).

Lung sections from the rats exposed to formaldehyde revealed pulmonary changes in the architecture of the lung and an increase in collagen contents, these changes were consistent with the findings in the rabbit lungs after exposure to 40% formaldehyde (Neelam *et al.*, 2011), also detected in rats (Kamata *et al.*, 1996; Turkoglu *et al.*, 2008; Mehdi *et al.*, 2014) and in mice (YU *et al.*, 2004).

The positive reaction to TNF- α in the present study was confirmed by the previous results which showed that FA exposure mice enhanced TNF- α in the lung and increased the collagen production (Leal *et al.*, 2018)

Increase reaction to caspase-3 in formalin exposed rats in the present study was confirmed by the previous results which improved that inhalation of formaldehyde induces apoptotic cell death in the lung tissues (Sandikci *et al.*, 2009)

Cardiac sections from rats exposed to formaldehyde revealed changes in the architecture of the cardiac muscle and an increase in the collagen contents which was confirmed by the previous results (Afifi and Hanon, 2011) which revealed that rats exposed to oral formalin consumption showed disruption and fragmentation of cardiac myocytes and increased collagen fiber content between the separated cardiac muscle fibers. (Onyeka *et al.*, 2018) showed that Formaldehyde fumes have cardiopulmonary effect on medical students. Formaldehyde caused cardiac failure possibly mediated by impairments of the intracellular Ca²⁺ handling in rat normal and hypertrophic hearts (Takeshita *et al.*, 2009).

The positive reaction to TNF- α in the cardiac sections in the present study was confirmed by the previous results which proved that TNF- α is among the most common pro-inflammatory cytokines observed following cardiac stress (Gullestad *et al.*, 2012; Bartekova *et al.*, 2018).

The positive reaction to caspase-3 in the cardiac sections in formalin exposed rats in the present study was confirmed by the previous results (Yue *et al.*, 1998) which showed that caspase expression and activation were reported in apoptosis of isolated rat cardiomyocytes. Guttenplan *et al.*, 2001 found that caspases can act as effectors, participating in the total disassembly of cell structures and represents the principal form of myocyte death. Caspase-3 activity was proved to be responsible for the cardiomyocyte apoptosis in heart failure rabbit obtained by ventricular pacing (Laugwitz *et al.*, 2001).

The addition of omega-3 in the present study revealed that restoration of the normal lung architecture with the normal appearance of alveoli and sinuses with minimal collagen deposition. These results were confirmed by the previous studies which showed that elevating tissue omega-3 levels can prevent and treat fine particle-induced health problems and suppress fine particle-induced pulmonary and systemic inflammation (Li *et al.*, 2017).

The therapeutic role of omega-3 was confirmed also by (Raafat *et al.*, 2018) who found that the addition of omega-3 has an ameliorating effect on the inflammation caused due to rheumatoid arthritis on the lung tissue by H&E and (TNF- α). The anti-inflammatory effect of omega-3 was studied also by (xu *et al.*, 2011) who said that omega-3 injection effectively reduces destruction and injury in the lung of rats with severe scald.

Omega-3 FAs are pivotal not only for brain function and normal growth and development (Belluzzi, 2002) but also they have many beneficial effects on several health problems including cardiac diseases (Roy and Le Guennec, 2017; Endo and Arita, 2016) which confirm the present results of restoring the cardiac muscle architecture after addition of omega-3.

Omega-3 FAs administration was also proved to prevent pathological alterations in the myocardium from Bisphenol exposure (Bahey *et al.*, 2019).

Conclusion:

Formaldehyde inhalation has a sever destructive effect on both lung and heart tissues, the addition of omega-3 has an ameliorating effect on these effects.

REFERENCES

- Afifi, NM; Hanon, AF (2011): Histological and immunohistochemical study on the possible cardioprotective role of acetylcysteine in oral formalin myocardial toxicity in adult albino rats. *Egyptian Journal of Histology*; 34 (4):859-869.
- Afrin M, Amin T, Karim R and Rafiqul M (2016): Gross and histomorphological effects of formaldehyde on brain and lungs of Swiss albino mice. *Asian Journal of Medical and Biological Research*, 2 (2): 229-235.
- Bahey NG, Abdelaziz HO, and Gadalla KKE . (2019): Potential Toxic Effect of Bisphenol A on the Cardiac Muscle of Adult Rat and the Possible Protective Effect of Omega-3: A Histological and Immunohistochemical Study. *J. Microsc Ultrastruct*, 7(1): 1–8.
- Bartekova M, Radosinska J, Jelemensky M and Dhalla NS. (2018): Role of cytokines and inflammation in heart function during health and disease. *Heart Failure Reviews*, 23(5):733-758.
- Belluzzi A (2002): N-3 fatty acids for the treatment of inflammatory bowel diseases. *Proceedings of The Nutrition Society*, 61:391–5.
- Bernstein JA, Alexis N, Bacchus H, et al. (2008): The health effects of non-industrial indoor air pollution. *Journal of Allergy and Clinical Immunology*, 121: 585–591.
- Dabbs (2002): Diagnostic immunohistochemistry. Churchill Livingstone, 2nd edition.
- Dean AG, Arner TG, Sunki G, Sangam S, Friedman R, Lantinga M, and Diskalkar S. (2000): Epi-info version 1 for the year . A Database and Statistics Program for Public Health Professionals CDC. Georgia, USA. 1-191
- Deckelbaum RJ and Torrejon C. (2012): The Omega-3 Fatty Acid Nutritional Landscape: Health Benefits and Sources. *Journal of Nutrition*, 142(3):587S–591S.
- Drury RAB and Wallington EA (1980): Carleton's histological technique, fifth edition, Oxford University press, New York, Toronto, Hong Kong and Tokyo. 36-125.
- Duvall MG and Levy BD (2016): DHA- and EPA-derived resolvins, protectins, and maresins in airway inflammation. *The European Journal of Pharmacology*, 785:144–155.
- El Desouky AA, Abo Zaid A, El Saify GH and Noya DA (2019): Ameliorative Effect of Omega-3 on Energy Drinks - Induced Pancreatic Toxicity in Adult Male Albino Rats. *Egyptian Journal of Histology*; 42(2): 324-334.
- Endo J, Arita M. (2016): Cardioprotective mechanism of omega-3 polyunsaturated fatty acids. *Journal of Cardiology*; 67:22–7.
- Gullestad L, Ueland T, Vinge LE, Finsen A, Yndestad A and Aukrust P (2012): Inflammatory cytokines in heart failure: mediators and markers. *Cardiology*, 122:23–35.
- Guttenplan N, Lee C, Frishman W H (2001): Inhibition of myocardial apoptosis as a therapeutic target in cardiovascular disease prevention: focus on caspase inhibition. *Heart Disease* (Hagerstown, Md.); 3(5):313-8.
- Institute Of Laboratory Animal Resources (2011): Commission on Life Science, National Research Council of national academies. Guide for the Care and Use of Laboratory Animals. National Academy press, Washington, D.C, 8th Ed. 11-55.
- Isaac MR and Saad SA (2018): Effect of Formaldehyde Inhalation on the Structure of Cerebellar Cortex of Adult Male Albino Rats. *Egyptian Journal of Histology*. 41(4): 520-532.
- Jain AP, Aggarwal KK and Zhang PY. (2015): Omega-3 fatty acids and cardiovascular disease. *European review for medical and pharmacological sciences*; 19(3):441–445.
- Kamata E, Nakadate M, Uchida O, et al. (1996): Effects of formaldehyde vapour on the nasal cavity and lungs of F-344 rats. *The Journal of Environmental Pathology, Toxicology, and Oncology*; 15: 1-8.

- Khaliq F and Tripathi P. (2009): Acute effects of formalin on pulmonary functions in gross anatomy laboratory. *The Indian Journal of Physiology and Pharmacology*, 53(1):93-6.
- Kim WJ, Terada N, Nomura T, et al. (2002): Effect of formaldehyde on the expression of adhesion molecules in nasal microvascular endothelial cells: the role of formaldehyde in the pathogenesis of sick building syndrome. *Clinical & Experimental Allergy*, 32: 287–295.
- Laugwitz KL, Moretti A, Weig HJ et al. (2001): Blocking caspase-activated apoptosis improves contractility in failing myocardium. *Human Gene Therapy*.12:2051–2063.
- Leal MP, Brochetti RA, Ignácio A, Câmara NOS, Palma RK, Oliveira LVF, Silva DFT and Franco ALS. (2018): Effects of formaldehyde exposure on the development of pulmonary fibrosis induced by bleomycin mice. *Toxicology Reports*, 5: 512-520.
- Li X, Hao L, Liu Y, Chen C, Pai V and Kang J (2017): Protection against fine particle-induced pulmonary and systemic inflammation by omega-3 polyunsaturated fatty acids. *Biochimica et Biophysica Acta (BBA) - General Subjects*, (3):577-584.
- Mehdi AH, Saeed AK, Hassan SMA, Salmo NA and Maaruf NA. (2014): Histopathologic changes in rat organs upon chronic exposure to formaldehyde vapor. *Bas. Journal of Veterinary Research*, 1(2):127-140.
- Nakazawa H, Ikeda H, Yamashita T, et al. (2005): A case of sick building syndrome in a Japanese office worker. *Industrial Health*, 43: 341–345.
- Neelam B, Uppal V and Pathak D. (2011): Toxic effect of formaldehyde on the respiratory organs of rabbits: A light and electron microscopic study. *Toxicology and Industrial Health*, 27(6): 563–569.
- Onyeka OC, Chiemezie MS, Ozoemena MS, Nwabunwanne OV (2018): Effects of formaldehyde inhalation on cardiopulmonary functions on medical students of College of Health Sciences, Nnamdi Azikiwe University during dissection classes. *American Journal of Physiology, Biochemistry And Pharmacology*, 7(2) 86–94
- Papamichael MM, Shrestha SK, Itsiopoulos C and Erbas B. (2018): The role of fish intake on asthma in children: a meta-analysis of observational studies. *Pediatric Allergy and Immunology*, 29(4):350–360.
- Raafat MH, Hamam GG, Farhan MS, Sabbagh LM, Abeduldaem NM and Sharaf AM (2018): Evaluation of the possible therapeutic role of omega-3 on ankle joint and lung in a model of rheumatoid arthritis in rats: A histological and immunohistochemical study. *The Egyptian Journal of Histology*, 41(3): 250-263.
- Remick A K, Wood C E, Cann J A, Gee M K, Feiste E A, Kock N D, and Cline J M (2006): Histologic and immunohistochemical characterization of spontaneous pituitary adenomas in fourteen cynomolgus macaques (*Macaca fascicularis*). *Veterinary Pathology Online*, 43(4):484-493.
- Roy J, Le Guennec JY. (2017): Cardioprotective effects of omega 3 fatty acids: Origin of the variability. *The Journal of Muscle Research and Cell Motility*, 38: 25–30.
- Sandikci M, Seyrek K, Aksit H, Kose H. (2009): Inhalation of formaldehyde and xylene induces apoptotic cell death in the lung tissue. *Toxicology and Industrial Health*, 25(7): 455-461.
- Sayed SA, Mahmoud FY, Anwar RI and Abdel Fatah RM (2013): Effect of Formaldehyde Inhalation on the Olfactory Bulb of Adult Rats. *The Journal of American Science*, 9(9):72-82.
- Schipke J, Brandenberger C, Rajces A, Manninger M, Alogna A, Post H et al. (2017): Assessment of cardiac fibrosis: a morphometric method comparison for collagen quantification. *Journal of Applied Physiology*, 122(4):1019-1030.
- Takahashi S, Tsuji K, Fujii K, et al., (2007): Prospective study of clinical symptoms and skin

- test reactions in medical students exposed to formaldehyde gas. *Journal of Dermatology*, 34: 283–289.
- Takeshita D , Nakajima-Takenaka C , Shimizu J , Hiroshi Hattori 1 , Nakashima T, Kikuta A , Matsuyoshi H and Takaki M.(2009): Effects of Formaldehyde on Cardiovascular System in In Situ Rat Hearts. *Basic & Clinical Pharmacology & Toxicology*, 105: 271–280.
- Turkoglu AO, Sarsilmaz M and Colakoglu N (2008): Formaldehyde-induced damage in lungs and effects of caffeic acid phenethyl ester: a light microscopic study. *European Journal of General Medicine*, 5:152-156.
- Xu QL, Cai C, Qi W, Xia ZG and Tang YZ(2011): [Influence of omega-3 polyunsaturated fatty acids on inflammation-related parameters in lung tissue of rats with severe scald. *Zhonghua Shao Shang Za Zhi*, 27(5):358-62.
- Yu G, Ji-fang L, Tie-ji L, et al.(2004): Effects of formaldehyde on lung histomorphology and level of lipid peroxide in mice. *Journal of Jilin University Medicine Edition*, 3: 24-29.
- Yue T-L, Wang C, Romanic AM et al. (1998): Staurosporine-induced apoptosis in cardiomyocytes: a potential role of caspase-3. *Journal of Molecular and Cellular Cardiology*, 30:495–507.
- Zhou DX, Qiu SD, Zhang J, et al. (2006): The protective effect of vitamin E against oxidative damage caused by formaldehyde in the testes of adult rats. *Asian Journal of Andrology*; 8 (5): 584–588.

ARABIC SUMMARY

تأثير الفورمالدهايد على بنية الرئة والقلب والتأثير الوقائي المحتمل لأوميغا 3 (دراسة هستولوجية وهستولوجية مناعية)

سلوى محمد عويس , عبير فريد عبد النعيم
قسم التشريخ وعلم الاجنة , كلية الطب , جامعة سوهاج

مقدمة: الفورمالدهايد هو ملوث داخلي وخارجي شائع يوجد في العديد من المنتجات. إن سمية الفورمالدهايد تثير القلق لجميع الذين يعملون بشكل وثيق معها مثل التحنيط، والتشريح، وفنيي علم الأنسجة وطلاب الطب. أوميغا 3 في زيت السمك هو واحد من أهم الأحماض الدهنية غير المشبعة التي لها نشاط مضاد للالتهابات ومضاد للأكسدة.

الغرض من البحث: دراسة تأثير استنشاق الفورمالدهايد على نسيج الرئة والقلب والتأثير الوقائي المحتمل لأوميغا 3

المواد والأساليب: تم تقسيم ثلاثين من ذكور الفئران البيض إلى ثلاث مجموعات متساوية. المجموعة الأولى (المجموعة الضابطة)، تعرضت للفئران المجموعة الثانية لاستنشاق الفورمالدهايد لمدة 4 أسابيع. المجموعة الثالثة: تعرضوا لاستنشاق الفورمالدهايد كالمجموعة سابقة وأعطوا عن طريق الفم أوميغا 3 بجرعة 300 مغ / كغ / يوما لمدة 4 أسابيع. بعد 24 ساعة من الجرعة الأخيرة، تم تشريح الحيوانات. تمت معالجة القلوب والرئتين من صباغتها بالهيماتكسولين والايوسين والماسون تراكوم والدراسة الهستولوجية المناعية

النتائج: أظهرت الفئران المعالجة باستنشاق الفورمالدهايد تغيرات مهمة في بنية كل من الرئة والقلب، وزادت نسبة ألياف الكولاجين، وزاد التعبير المناعي لكل من TNF- α و caspase-3 مقارنة بالمجموعة الضابطة. يمكن لأحماض أوميغا 3 الدهنية تحسين هذه التغيرات النسيجية وتقليل نسبة ألياف الكولاجين والتعبير المناعي لكل من الرئة والقلب.

الخلاصة: استنشاق الفورمالدهايد يرتبط بتغيرات ميكروسكوبية لكل من الرئة والقلب، إضافة أوميغا 3 يمكن أن تقلل من هذه التغيرات.