

## Optical Coherence Tomography Angiography Findings in Diabetic Patients with Macular Edema

HOSAM M. SALAH ELDEEN ATEF, M.Sc.\*; KARIM M. NAGUIB, M.D.\*; KHALED H. MAHMOUD, M.D.\*; MONA S. ELKODDOUSY, M.D.\*\* and BAHAA-ELDIN A. ALI, M.D.\*

The Departments of Ophthalmology, Faculties of Medicine, Ain Shams\* and Tanta\*\* Universities

### Abstract

**Background:** Diabetic macular edema is one of the most common causes of vision loss in patients with diabetes. Fluorescein Angiography (FA) provides valuable additional information compared to clinical examination or fundus photography but it has many contraindications. It requires venipuncture and intravenous injection of a dye that has a moderate risk of nausea and a rare but well documented risk of anaphylaxis and death. Optical Coherence Tomography Angiography (OCTA) is a non-invasive modality that generates three-dimensional, depth encoded images of blood flow within the eye by using motion contrast. It offers an alternative angiographic technique without the drawbacks of FA. Areas of capillary loss obscured by fluorescein leakage on FA were more clearly defined on OCTA.

**Aim of Study:** To describe the Optical Coherence Tomography Angiography (OCTA) findings in diabetic patients with macular edema.

**Patients and Methods:** A cross sectional study was carried out on 46 eyes of 30 diabetic patients with macular edema diagnosed by Optical Coherence Tomography (OCT). The findings of the OCT and OCTA were correlated. The presence of microaneurysms and neovascularization was studied in OCTA. Macular perfusion was quantified using OCTA images by 3 parameters: Foveal Avascular Zone (FAZ) area and Vascular Area Density (VAD) at 2 levels; Superficial Capillary Plexus (SCP) and Deep Capillary Plexus (DCP) and Vascular Density Map (VDM).

**Results:** There is a statistically significant difference between the number of microaneurysms in the DCP and SCP (more in the DCP). A significant negative correlation between the duration of hypertension and the vascular area density of superficial capillary plexus. There is a significant difference between eyes with normal and eyes with abnormal inner retinal integrity [Disorganization of the Retinal Inner Layers (DRIL)] as regards the FAZ of superficial and deep capillary plexuses (larger in eyes with DRIL), the vascular area density of superficial capillary plexuses (less in eyes with DRIL) and the vascular density map center 3mm (more in eyes with DRIL). Although one of the strengths of the OCTA is its

ability to assess vasculatures and structures of DCP separately from SCP, this is limited by projection artifacts from the superficial structures onto deeper layers.

**Conclusion:** Correlation between OCT and OCTA images is mandatory to explain the OCT and OCTA findings. The presence of microvascular abnormalities, hemorrhages, cotton wool spots and hard exudates gives fallacies in OCTA images interpretation. The significant correlation between the presence of DRIL by OCT and diabetic macular ischemia by OCTA allows for OCT to be sufficient when FFA cannot be done and OCTA is unavailable.

**Key Words:** Optical coherence tomography angiography – Diabetic macular edema.

### Introduction

**VISUAL** impairment due to Diabetic Retinopathy (DR) is a rising world wide problem. Diabetic eye disease is now the fifth most common cause of blindness [1].

DR is a microangiopathy that causes vascular hyperpermeability, capillary occlusion, and neovascularization in the retinal vasculature [2]. One of the most common causes of vision loss in patients with diabetes is Diabetic Macular Edema (DME) [3].

Fluorescein Angiography (FA) provides valuable information and has certain drawbacks. It requires venipuncture and intravenous injection of a dye that has a moderate risk of nausea and may cause anaphylaxis and death [4]. Also, a standard protocol FA acquires images over 10 minutes with repeated exposure to a very bright light source, which can cause significant discomfort for patients [5].

Optical Coherence Tomography Angiography (OCTA) is a new non-invasive modality that generates three-dimensional, depth encoded images

**Correspondence to:** Dr. Hosam M. Salaheldeen Atef,  
[E-Mail: hosamsalaheldeen@gmail.com](mailto:hosamsalaheldeen@gmail.com)

of blood flow within the eye by using motion contrast. It is based on rapid Optical Coherence Tomography (OCT) scanning of the eye and compares repeated scans acquired at the same position in the retina to look for changes in the scan [6]. It offers an alternative angiographic technique without the drawbacks of FA. Areas of capillary loss obscured by fluorescein leakage on FA were more clearly defined on OCTA [7].

#### *Aim of the work:*

The aim of the work is to describe the Optical Coherence Tomography Angiography (OCTA) findings in diabetic patients with macular edema.

### **Patients and Methods**

A cross sectional study was carried out on 46 eyes of 30 diabetic patients with macular edema diagnosed by (OCT). The study excluded patients with hazy media or/and poor fixation interfering with a good quality OCT and OCTA images and images with severe degrees of OCTA artifacts that prevent proper interpretation. This study was conducted in Nour Eldin Center-Tanta from August 2017-August 2018.

*All patients were subjected to:* Detailed history taking, Best Corrected Visual Acuity testing (BCVA) [Snellen visual acuity was converted to Decimal notation VA for the purpose of statistical analysis], comprehensive eye examination including anterior and posterior segment examination and OCT & OCTA imaging.

OCT and OCTA were performed using spectral domain-OCT system (Heidelberg Engineering) and swept source-OCT system (Topcon OCT Triton) respectively.

As regards OCT, spectral domain-OCT system (Heidelberg Engineering) was used using macular line scans analyzed by:

1- *Overview report protocol:* The "inner retina" was defined as the space lying between the inner aspect of the Internal Limiting Membrane (ILM) and the inner border of the Outer Plexiform Layer (OPL), while the "outer retina" was defined as the space lying between the inner border of the OPL and the inner aspect of the Retinal Pigment Epithelium (RPE). The choroid was defined as the space between the outer border of the RPE/Bruch's membrane complex and the inner border of the sclera.

2- Retina single exam report protocol to measure the central fovea thickness.

Regarding OCTA imaging, 6 X 6mm scanning areas centered on the fovea were used. Segmentation of the retina and choroid within the macular area was done into 4 areas: The Superficial Capillary Plexus (SCP) that extends from the ILM to the Inner Plexiform Layer (IPL), the Deep Capillary Plexus (DCP) that extends from the IPL to the (OPL), the outer retina which is normally avascular and extends from the OPL to the Retinal Pigment Epithelium (RPE) and the choriocapillaries: A 20 $\mu$ m thick slab starting 10 $\mu$ m below the RPE-Bruch's Membrane (BM) complex.

The ischemic areas seen by OCT were also evaluated for structural changes using OCT as regard outer retinal and inner retinal changes. Outer retinal changes were defined as any of the following: Interruption or disruption of the External Limiting Membrane (ELM) and/or inner segment-outer segment (IS/OS) junction. While inner retinal changes included thinning, or Disorganization of the Retinal Inner Layers (DRIL) which is defined as an area where any boundaries between Ganglion Cell Layer (GCL), IPL, Inner Nuclear Layer (INL), and OPL were poorly identified in the macular scans.

Using OCTA, macular ischemia was defined as enlargement or irregularity of Foveal Avascular Zone (FAZ) or the presence of areas of capillary non flow within the macular area that are not continuous with FAZ. In order to quantify the OCTA findings within the macula, 3 parameters were used: FAZ area in  $\mu$ m<sup>2</sup>, Vascular area density (VAD) and Vascular Density Map (VDM).

- 1- FAZ area measuring was done by outlining the FAZ in both SCP and DCP images and the area was then estimated by the device.
- 2- VAD is defined as the percentage of the area occupied by vessels in the segmented area (6 X 6 millimeter squares scanned area centered on the fovea). It was then quantified after converting the obtained images into binary forms using Image J software and analyzing its particles (Image J 1.48v; National Institutes of Health, Bethesda, Maryland, USA).
- 3- VDM evaluates the density of vasculature in 1, 3mm zones automatically.

To differentiate between macular edema and ischemia, we used criteria used by de Carlo et al. [8] which defined edema in OCTA as cystic spaces with regular borders completely devoid of OCTA signal and ischemia as grayish hue (decreased signal) with irregular borders. The en face images

were used also for this purpose. Microaneurysms in OCTA appears as hyper-reflective vascular lesions surrounded by an area of non-perfusion. In cases of PDR, we used the slab extending from TOP to ILM to detect neo-vessels within the macular area that appears as hyper-reflective vascular tufts.

*Statistical analysis:*

The collected data were organized, tabulated and statistically analyzed using SPSS version 19 (Statistical Package for Social Studies) created by IBM, Illinois, Chicago, USA. For numerical values the range mean and standard deviations were calculated. The differences between two mean values were used using student's (*t*) test. For numerical data when the normal distribution was not guaranteed, Mann-Whitney test (*Z*) was used to compare difference in mean values instead of (*t*) test. For categorical variable the number and percentage were calculated and differences between subcategories were tested by Monte Carlo exact test. The correlation between two variables was calculated using Pearson's correlation coefficient. The level of significant was adopted at  $p < 0.05$ .

**Results**

The study was conducted on 46 eyes of 30 diabetic patients with macular edema (16 patients with bilateral edema and 14 unilateral). The patients included 17 males (56.7%) and 13 females (43.3%), with a mean age  $\pm$  SD of  $59.28 \pm 7.75$ . The median duration of DM for the patients was 17 years (range 7-25) sixteen of the patients (53.3%) were hypertensive. The mean BCVA for the patients was  $0.24 \pm 0.13$  (range 0.1-0.5 decimal). Fortythree eyes (93.5%) were phakic and only 3 eyes (6.5%) were pseudophakic. Two out of the pseudophakic eyes have Cystoid Macular Edema (CME) with neurosensory detachment and one has CME. According to the grade of retinopathy, 30 eyes (65.2%) were non-proliferative diabetic retinopathy and 16 eyes (34.8%) were proliferative. OCT findings reveal that there is no detectable abnormality at the vitreo-retinal interface in 41 eyes (89.1%) and 5 eyes only (10.9%) show vitreo-retinal traction. Macular edema is diffuse in 9 eyes (19.6%), cystoid in 33 eyes (71.7%) and cystoid with neuro-sensory detachment in 4 eyes (8.7%). The outer retinal integrity is abnormal in 16 eyes (34.8%) and normal in 30 eyes (65.2%). The inner retinal integrity is abnormal in 11 eyes (23.9%) and shows no detectable abnormality in 35 eyes (76.1%). The neovascularization of the disc is present in 9 eyes (19.6%) and absent in 37 eyes (80.4%). The neovasculari-

zation elsewhere is present in 7 eyes (15.2%) and absent in 39 eyes (84.8%).

As regards the duration of diabetes mellitus, there is a significant positive correlation with the vascular density map center 1mm, insignificant negative correlation with the BCVA, number of aneurysms in superficial and deep capillary plexuses, VAD of SCP, FAZ in superficial and deep capillary plexuses and insignificant positive correlation with CFT, VAD of DCP and choio-capillaries and the VDM center 3mm.

Regarding the presence or absence of hypertension in the diabetic patients, there is a significant difference in the number of aneurysms in deep capillary plexus ( $p$ -value=0.001) and the vascular area density of chorio-capillaries ( $p$ -value=0.013) between diabetic non hypertensive and diabetic hypertensive patients; the number of aneurysms in the DCP is more in diabetic non hypertensive patients and the vascular area density of chorio-capillaries is less in the diabetic non hypertensive patients. An insignificant difference in the BCVA, CFT, number of aneurysms in SCP, VAD of superficial and deep capillary plexuses, FAZ in superficial and deep capillary plexuses and VDM center 1mm and 3mm between diabetic and diabetic hypertensive patients.

Concerning with the duration of hypertension (Table 1), there is a significant negative correlation with the vascular area density of superficial capillary plexus Fig. (1), insignificant negative correlation with BCVA, CFT, number of aneurysms in DCP, VAD of choriocapillaries and VDM center 3mm and insignificant positive correlation with the number of aneurysms in SCP, VAD of DCP, FAZ in superficial and deep capillary plexuses and the VDM center 1mm.

Table (1): Correlation between duration of hypertension and BCVA, CFT and OCTA findings.

	Duration of hypertension in years	
	<i>r</i>	<i>p</i>
Visual acuity decimal equivalent	-0.210	0.304
Central foveal thickness	-0.004	0.983
Number of aneurysms in superficial capillary plexus	0.119	0.532
Number of aneurysms in deep capillary plexus	-0.088	0.669
Vascular area density of superficial capillary plexus	-0.465	0.017*
Vascular area density of deep capillary plexus	0.098	0.635
Vascular area density of chorio-capillaries	-0.280	0.166
Foveal avascular zone in superficial capillary plexus	0.326	0.105
Foveal avascular zone in deep capillary plexus	0.154	0.451
Vascular density map center 1mm	0.174	0.395
Vascular density map center 3mm	-0.079	0.702

\*: Significant.

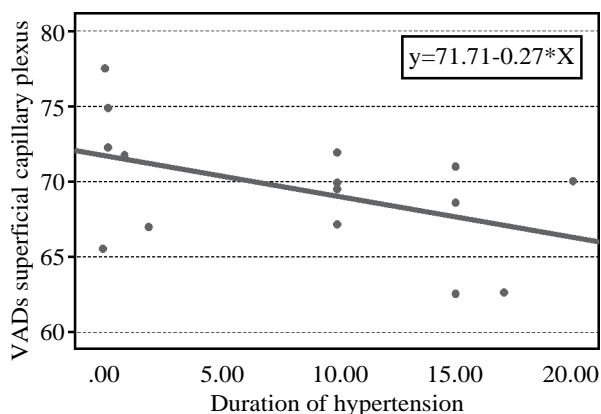


Fig. (1): Correlation between duration of hypertension in years and vascular area density in superficial capillary plexus.

As regards the BCVA, there is in significant correlation between the BCVA and the OCTA findings. Insignificant negative correlation is found between BCVA and the number of aneurysms in deep capillary plexus, VAD of DCP, FAZ in superficial and deep capillary plexuses and VDM center 1mm and 3mm. Insignificant positive correlation is present between BCVA and the number of aneurysms in SCP and the VAD of chorio-capillaries.

There is no significant difference between eyes with Non-Proliferative Diabetic Retinopathy (NPDR) and eyes with proliferative (PDR) regarding the OCTA findings. The FAZ of superficial and deep capillary plexuses is seen larger in NPDR than in PDR but the difference is not significant.

Regarding the correlation between the CFT and the FAZ in superficial and deep capillary plexuses, Figs. (2,3) show a significant positive correlation.

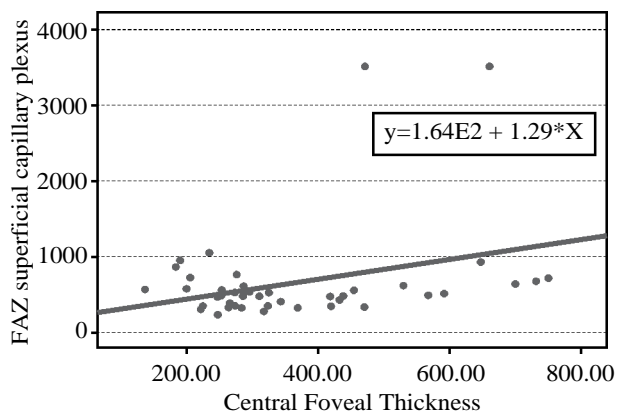


Fig. (2): Correlation between CFT and FAZ in superficial capillary plexus.

As shown in (Table 2), there is no significant difference between eyes with normal and eyes with abnormal outer retinal integrity as regards the

OCTA findings. The number of aneurysms in deep capillary plexus is more in eyes with abnormal outer retinal integrity, FAZ in superficial and deep capillary plexuses is larger in eyes with abnormal retinal integrity and the VAD of superficial and deep capillary plexuses is less in eyes with abnormal retinal integrity. The VDM center 3mm is found to be larger in eyes with abnormal outer retinal integrity.

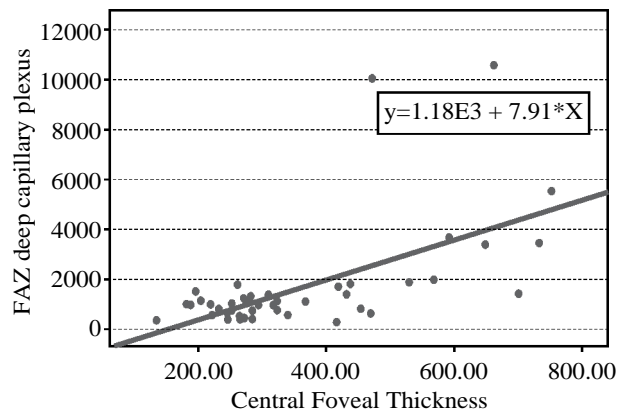


Fig. (3): Correlation between CFT and FAZ in deep capillary plexus.

Table (2): OCTA parameters in eyes with normal and abnormal outer retinal integrity.

OCTA parameters	Outer retinal integrity		Z	p
	Normal	Abnormal		
• Number of aneurysms in superficial capillary plexus	3.13±2.05	3.12±1.96	0.070	0.944
• Number of aneurysms in deep capillary plexus	7.90±3.27	9.00±2.22	1.102	0.270
• Foveal avascular zone of superficial capillary plexus	528±204	799±1061	0.784	0.433
• Foveal avascular zone of deep capillary plexus	1263±881	2299±3338	0.381	0.704
• Vascular area density of superficial capillary plexus	70.22±2.86	68.55±4.15	1.234	0.217
• Vascular area density of deep capillary plexus	68.16±2.15	67.94±2.94	0.819	0.413
• Vascular area density of chorio-capillaries	50.17±3.62	50.29±3.51	0.392	0.695
• Vascular density map center 1mm	18.35±4.53	18.72±5.25	0.669	0.504
• Vascular density map center 3mm	43.33±2.09	44.05±2.08	1.061	0.289

There is a significant difference between eyes with normal and eyes with abnormal inner retinal integrity [Disorganization of the Retinal Inner Layers (DRIL)] as regards the FAZ of superficial and deep capillary plexuses (larger in eyes with DRIL), the VAD of SCP (less in eyes with DRIL) and the VDM center 3mm (more in eyes with DRIL) (Table 3).

Table (3): OCTA parameters in eyes with normal and abnormal inner retinal integrity.

OCTA parameters	Inner retinal integrity		Z	p
	Normal	DRIL		
• Number of aneurysms in superficial capillary plexus	3.09±1.99	3.27±2.10	0.156	0.876
• Number of aneurysms in deep capillary plexus	8.09±3.07	8.91±2.66	0.904	0.366
• Foveal avascular zone of superficial capillary plexus	473±179	1097±1205	2.022	0.043*
• Foveal avascular zone of deep capillary plexus	1037±651	3489±3690	2.073	0.038*
• Vascular area density of superficial capillary plexus	70.48±2.87	66.95±3.75	2.511	0.012*
• Vascular area density of deep capillary plexus	68.13±2.14	67.92±3.28	0.670	0.503
• Vascular area density of chorio-capillaries	50.52±3.62	49.25±3.26	1.069	0.285
• Vascular density map center 1mm	18.92±3.95	17.07±6.73	0.760	0.447
• Vascular density map center 3mm	43.15±2.01	44.95±1.83	2.318	0.020*

\*: Significant.

A case of diabetic retinopathy with hard exudates seen in colored photo Fig. (4A) and pseudo-flow of the hard exudates seen at the level of DCP in OCTA Fig. (4B).

Diabetic hypertensive patient with cotton wool spot seen in colored photo Fig. (5A), hyper-reflective inner retinal infarction with underlying shadowing seen in OCT image Fig. (5B) and areas of devoid flow at the level of SCP corresponding to the cotton wool spots with underlying shadowing at the level of DCP and chorio-capillaries layer Fig. (5C).

Diabetic patient with Disorganization of Retinal Inner Layers (DRIL) seen in OCT image Fig. (6A) corresponding to the areas of devoid flow at the level of Superficial Capillary Plexus (SCP) and Deep Capillary Plexus (DCP) Fig. (6B).

Diabetic hypertensive patient with hard exudates seen in colored photo Fig. (7A), cystoid macular edema and hard exudates in OCT image Fig. (7B) and OCTA images Fig. (7C).




Fig. (4A): Colored photo shows hard exudates.




Fig. (4B): OCTA shows pseudo-flow of the hard exudates seen at the level of DCP.

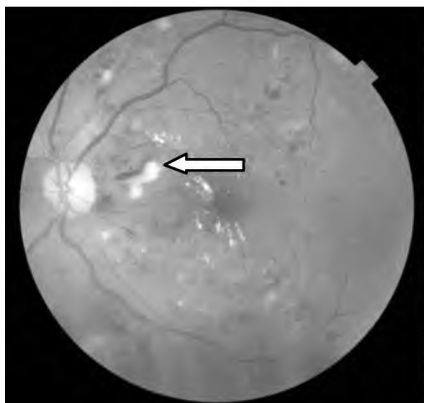


Fig. (5A): Colored photo shows cotton wool spots (arrow).

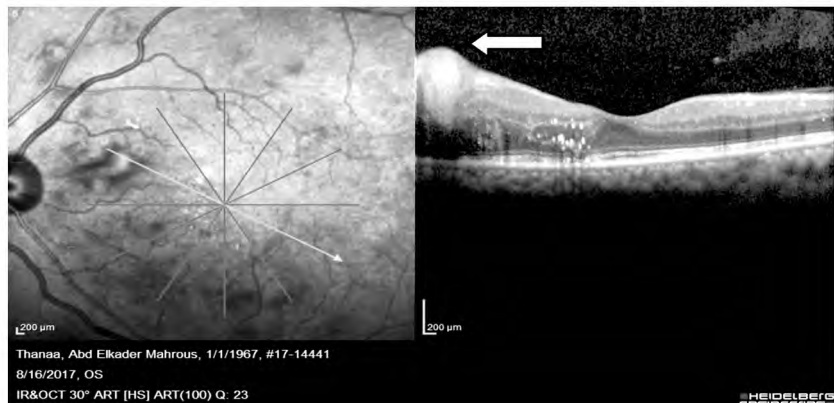


Fig. (5B): OCT shows hyper-reflective inner retinal infarction with underlying shadowing (arrow).

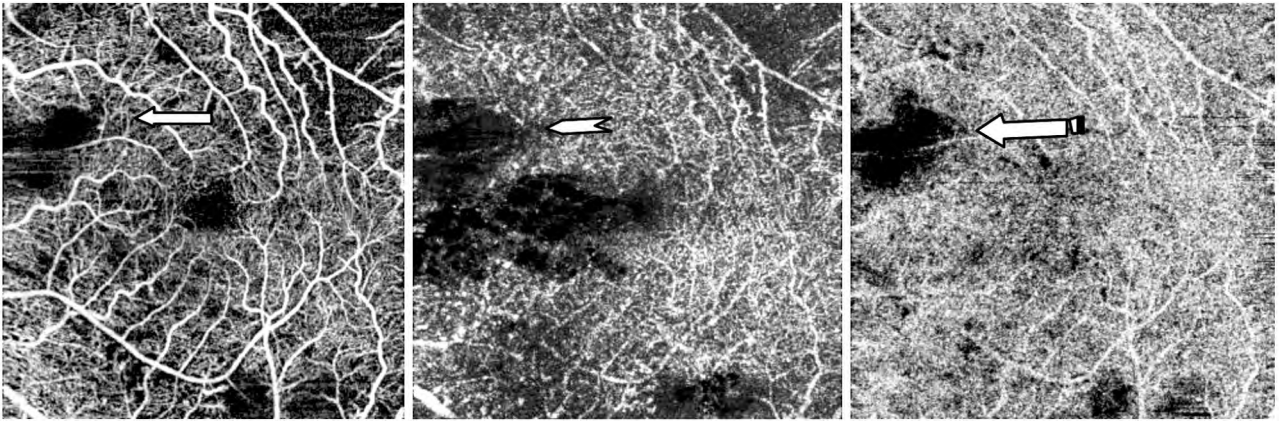


Fig. (5C): OCTA shows areas of devoid flow at the level of SCP corresponding to the cotton wool spots (arrow) with underlying shadowing at the level of DCP (head arrow) and chorio-capillaries layer (striped arrow).

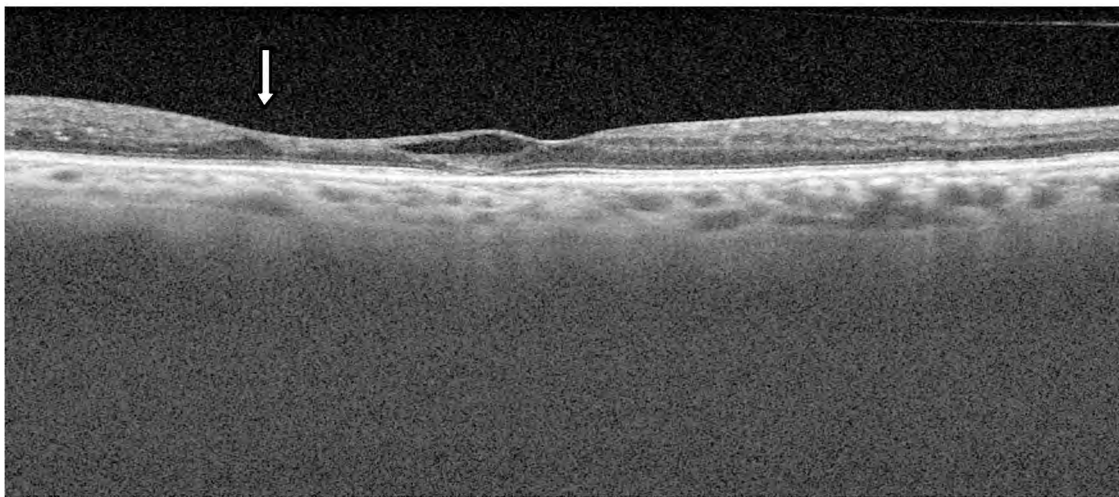
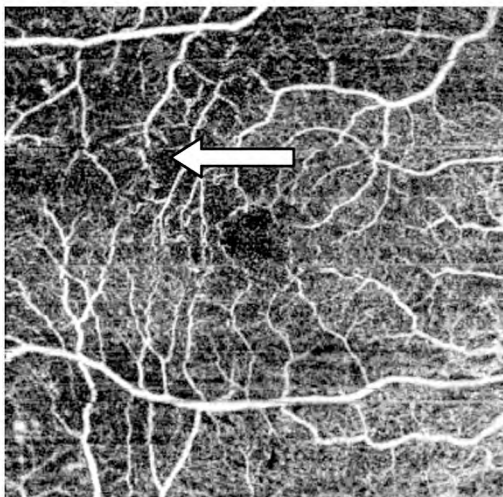
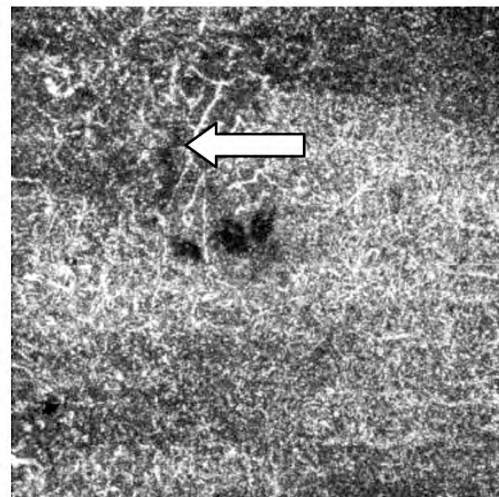


Fig. (6A): OCT shows Disorganization of Retinal Inner Layers (DRIL) (white arrow).



SCP



DCP

Fig. (6B): OCTA shows Ischemia at the level of SCP and DCP (arrow).

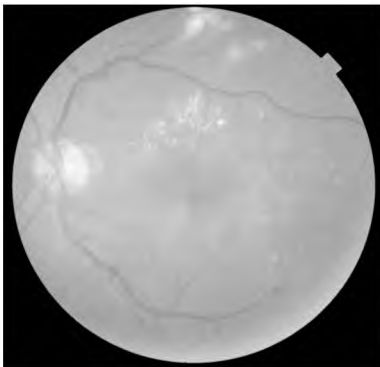


Fig. (7A): Colored photo shows hard exudates.

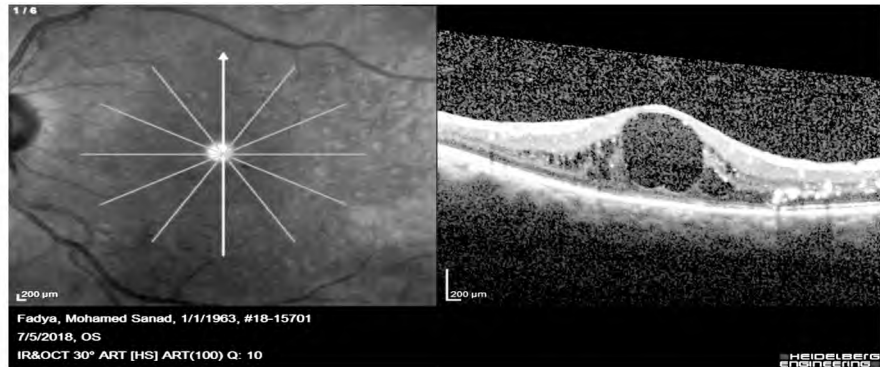
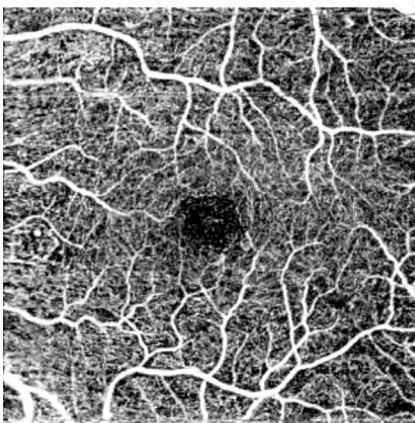
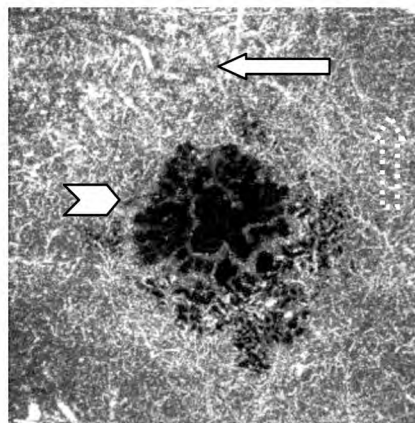



Fig. (7B): OCT shows cystoid macular edema with hard exudates.



SCP



DCP



Chorio-capillaries

Fig. (7C): OCTA images show:

- 1- Areas of pseudoflow correspond to hard exudate at the level of DCP (arrow).
- 2- Shadowing effect to the overlying hard exudates on the chorio-capillaries layer (striped arrow).
- 3- Cystoid macular edema (arrow head) and macular ischemia at the DCP (striped arrow). The former appears as cystic spaces with regular borders completely devoid of OCTA signals and the later appears as greyish hue with irregular borders.

### Discussion

DR and DME are leading causes of blindness in the working-age population of most developed countries. The increasing number of individuals with diabetes worldwide suggests that DR and DME will continue to be major contributors to vision loss and associated functional impairment for years to come. The control of diabetes-associated metabolic abnormalities (i.e., hyperglycemia, hyperlipidemia, and hypertension) is also important in preserving visual function because these conditions have been identified as risk factors for both the development and progression of DR/DME [9].

OCTA is a novel non-invasive imaging modality for 3-dimensional visualization of retinal and optic nerve capillary networks. OCTA was found to detect microvascular changes early in diabetes mellitus, even before they become clinically evident. Morphological and qualitative assessment of vascular changes can help to determine the patho-

physiological processes, activity, treatment, and follow-up of DR [10].

In this study 46 eyes of 30 diabetic patients with macular edema (16 bilateral and 14 unilateral) were included, all of type 2 diabetes. Males were more than female with a mean  $\pm$  SD age of  $59.28 \pm 7.75$ . This is in agreement with Liew study which stated that the mean age of patients with diabetic macular edema was 58.2 and 56.8% of patients were male [11].

*As regards the duration of the diabetes mellitus:*

In this study the significant positive correlation between the duration of diabetes and the VDM center 1mm is not anticipated. This finding can be explained by the presence of microvascular abnormalities as clustered capillaries, dilated capillary segments, tortuous capillaries, abnormal capillary loops, and hard exudates in this zone [12,13]. The pseudo-flow of the hard exudates in this zone can explain this significant positive correlation [14].

In the present study the insignificant correlation between the duration of diabetes mellitus and BCVA and OCTA findings is matched with Ciloglu et al. study [15]. This can be explained by:

- Unreliable patient history should be considered.
- Duration of the diabetes mellitus is one of the risk factors. There are many risk factors as hypertension, dyslipidemia, renal dysfunction and genetic factors. Line of treatment of DM (type of insulin/and or type of hypoglycemic drugs may be a factor.
- Although patients have different duration of diabetes, they have nearly similar clinical findings.

The negative correlation between the duration of diabetes mellitus and the VAD of SCP in this study is anticipated. The insignificant correlation can be referred to the smaller number of the studied patients.

Both hypertension and diabetes may have some underlying causes in common, and they share some risk factors. They also contribute to a worsening of each other's symptoms. The ways of managing both conditions also overlap [16].

In the current study hypertension is present in 53.3% of the diabetic patients. This is consistent with the Sowers study [17] who stated that the hypertension is present in more than 50% of patients with diabetes mellitus. Diabetes and hypertension share several pathophysiologic mechanisms including: Inappropriate activation of the renin angiotensin aldosterone system, oxidative stress secondary to excessive production of reactive oxygen species, inflammation, impaired insulin-mediated vasodilatation, increased sympathetic nervous system activation, dysfunctional innate and adaptive immune responses and abnormal renal handling of sodium [2,3].

As regards the duration of hypertension in diabetic hypertensive patients, there is a significant negative correlation with the vascular area density of SCP and negative correlation with vascular area density of choriocapillaries. This is aligned with Lee et al., who stated that the vascular density is decreased in chronic hypertension [18]. The positive correlation with the VAD of DCP is not anticipated and can be referred to the pseudoflow of the hard exudates present in this zone [14].

In the present study there is a significant difference between the number of microaneurysms in the DCP and SCP (more in the DCP) in all

studied patients. This is matched with Peres et al., study [19]. A significant difference in the number of microaneurysms in DCP between diabetic and diabetic hypertensive patient is present; the number of MAs in the DCP is more in diabetic non hypertensive patients. Estimation of the number of MAs has a prognostic value in the treatment. Fewer MAs in both SCP and DCP is associated with a better response of Diabetic Macular Edema (DME) to anti-vascular endothelial growth factor (anti-VEGF) therapy [20].

In the current study there is a significant difference in the VAD of chorio-capillaries between diabetic and diabetic hypertensive patients; it is less in diabetic non-hypertensive patients. This is not anticipated because hypertensive choroidopathy adds to the non-perfused areas [21]. This may be referred to the shadows from hard exudates which gives false decrease in the VAD in choriocapillaries [22].

In this study FAZ in the SCP and DCP is larger but not significant in diabetic hypertensive patients than diabetic patients only and also the VDM center 1mm is less but not significant in diabetic hypertensive patients. This is consistent with Lee WH et al., study which stated that hypertension affects the OCTA parameters including increase in the FAZ and decrease in VDM [18].

Regarding the correlation of the BCVA and the OCTA parameters, the positive correlation of the BCVA with the VAD of chorio-capillaries and the negative correlation between the BCVA and the FAZ in both SCP and DCP is matched with Lu Y et al., study that established the relation of the FAZ with the foveal ischemia and visual acuity potential [23]. The outer retina including the photoreceptors not only supplied by the chorio-capillaries but also by the DCP [24].

The negative correlation between the VAD of DCP and the BCVA in this study is not anticipated. Although one of the strengths of the OCTA is its ability to assess vasculatures and structures of DCP separately from SCP, this is limited by projection artifacts from the superficial structures onto deeper layers. Projection-Resolved Optical Coherence Tomography Angiography (PR-OCTA) uses a novel Reflectance-Based Projection-Resolved (RBPR) algorithm that augments the flow signal and overcomes projection artifacts [25].

In this study there is no significant difference between eyes with NPDR and eyes with PDR regarding the OCTA findings. This is not anticipated



and can be referred to the limited number of the studied patients. The larger FAZ of the SCP and DCP and the VDM center 1mm zone in NPDR eyes can be explained by the fact that the NPDR eyes with foveal CME give false increase in the FAZ measurements even with good correlation between the OCT and OCTA findings which is a must. The false increase in the FAZ of the DCP is also explained by the projection artifacts of the superficial hard exudates in the foveal zone. CME can be mistaken as a non-perfused area by either its displacement of the surrounding capillary plexuses or the presence of low intensity OCTA signals observed inside cystoid spaces which are due to the presence of corpusculated material pouring out from blood-ocular barrier. The former appears as a well-defined hypo-reflective lesions and the later appears as a grey signals [26].

In the current study the positive correlation between the CFT and the FAZ in the SCP and DCP is in agree with Reznicek et al., study [27] that concluded that retinal thickness is significantly increased in ischemic areas and not in agreement with the study conducted by Sim et al., [28] that reported the association between macular ischemia and macular thinning at different levels. The former study explains macular thickening by the following [27]:

- Thickening of the inner retinal layers (NFL-GCL-IPL) are due to edematous swelling of the non-foveal GCL prior to atrophic damage caused by ischemia.
- Thickening of the middle retinal layers (INL-OPL-ONL) either by DME, CME or exudates are due to accumulation of extra-cellular fluids from leaking ischemic capillaries or/and neo-vessels. Intra-cellular accumulation of fluids in ischemic retinal areas also occurs leads to cellular swelling with consecutive retinal thickening.
- Thickened ischemic retina due to primarily thickened middle retinal layers suggest an edematous process as a possible stage before advanced irreversible atrophic changes occur.

The patients of later study are diabetic population with a greater severity of disease. Macular thinning occurs mainly in the outer retina, RNFL and GCL. Thickening of the Haller's large vessel layer of the choroid is also observed [28].

As regards the correlation between the OCTA parameters and the presence of interruption in the outer retinal layers, the present study shows that the disruption in the outer retinal integrity is related

to the larger FAZ in both SCP and DCP, to the eyes with less VAD in SCP, DCP and eyes with more aneurysms in DCP. This is in agreement with Scarinci et al., who confirm that the DCP ischemia contributes to disruption of the outer retina including thinning of the outer nuclear layer and photoreceptors and establish the role of DCP in the oxygen requirements of the photoreceptors in addition to the chorio-capillaries [24]. Scarinci et al., in their study ruled out the contribution of the chorio-capillaries to the disruption in the outer retinal layers because the OCTA images of the chorio-capillaries are highly subjected to artifacts from inner retinal changes, including retinal vascular shadows or shadows cast by retinal exudates and hemorrhages making it difficult to completely evaluate the chorio-capillaries [24]. The relation of the larger FAZ and less VAD in the SCP to the disruption in the outer retinal layers including the photoreceptor layer can be explained by the recent experimental evidence of Yi et al., who suggest that during systemic ischemia, the inner retinal vascular contribution to the metabolic needs of the outer retina become more significant, as the choroidal vasculature fails to auto-regulate its blood supply in the setting of hypoxia [29]. The previous relation can be also explained by early studies which stated that the Intermediate Capillary Plexus (ICP) and DCP are supplied by vertical anastomoses from Superior Vascular Plexus (SVP) which is supplied by the central retinal artery and composed of large arteries, arterioles, capillaries, venules and veins vessels primarily in the Ganglion Cell Layer (GCL) [30]. The insignificant difference of the OCTA parameters between eyes with and without interruption in the outer retinal layers can be attributed to the small sample of the patients.

Regarding the correlation between the OCTA parameters and the presence of DRIL, the present study shows a statistically significant positive correlation between the FAZ of both SCP and DCP and the presence of DRIL and a statistically significant correlation between the presence of DRIL and the less VAD of the SCP. This is in agreement with the study of Onishi et al., who found a strong correlation between retinal ischemia at multiple levels and DRIL [31]. The term DRIL was first described by Sun et al., as an OCT biomarker and important predictor of vision in eyes with DME [32]. The statistically significant positive correlation between the presence of DRIL and the more vascular density map center 3mm in this study is not anticipated and can be explained by the presence of peri-foveal exudates which gives pseudo-flow [33].

*Conclusion:*

- 1- Correlation between OCT and OCTA images is mandatory to explain the OCT and OCTA findings.
- 2- The presence of microvascular abnormalities, hemorrhages and hard exudates gives fallacies in OCTA images interpretation.
- 3- Although one of the strengths of the OCTA is the ability to access vasculatures and structures of DCP separately from SCP, this is limited by projection artifacts from superficial structures onto deep layers.
- 4- The number of MAs in DCP is more than in SCP on both diabetic and diabetic hypertensive patients.
- 5- The presence of hypertension and its longer duration in diabetic patients increases the ischemic element. This finding must be put into consideration in the management of diabetic hypertensive patients with macular edema.
- 6- The decrease in the VAD of the SCP, DCP and/or in the VDM evidenced by OCTA must be correlated to the OCT images to exclude the presence of CME which gives false decrease.
- 7- The significant correlation between the presence of Disorganization of Retinal Inner Layers (DRIL) by OCT and DMI by OCTA allow for OCT to be sufficient when FFA cannot be done and OCTA is unavailable.

*Recommendations:*

The use of the OCTA in addition to the OCT in diabetic patients because of its value to diagnose the ischemic element especially when FFA is contraindicated.

**References**

- 1- TUCKER M.E.: Blindness due to Diabetic Retinopathy Surges World Wide, August 26, 2016.
- 2- ANTONETTI D., KLEIN R. and GARDNER T.W.: Diabetic retinopathy. *N. Engl. J. Med.*, 366 (13): 1227-39, 2012.
- 3- ROTSOS T.G. and MOSCHOS M.M.: Cystoid macular edema. *Clin. Ophthalmol.*, 2 (4): 919-30, 2008.
- 4- BLOOME M.A.: Fluorescein angiography: Risks. *Vision Res.*, 20 (12): 1083-97, 1980.
- 5- University of Wisconsin Fundus Photograph Reading Center: Standard Fluorescein Angiography (FA-D), pp. 1-10, 2012.
- 6- SPAIDE R.F., KLANCNIK J.M. and COONEY M.J.: Retinal vascular layers imaged by fluorescein angiography and optical coherence tomography angiography. *Jama Ophthalmol.*, 133: E1-E6, 2014.
- 7- HWANG T.S., JIA Y. and GAO S.S.: Optical coherence tomography angiography features of diabetic retinopathy. *Retina*, Nov., 35 (11): 2371-6, 2015.
- 8- De CARLO T.E., CHIN A.T., JOSEPH T., BAUMAL C.R., WITKIN A.J., DUKER J.S., et al.: Distinguishing diabetic macular edema from capillary non perfusion using optical coherence tomography angiography. *Ophthalmic Surgery, Lasers and Imaging Retina*, 47 (2): 108-14, 2016.
- 9- CIULLA T., AMADOR A. and ZINMAN B.: Diabetic retinopathy and diabetic macular edema: Pathophysiology, screening, and novel therapies. *Diabetes Care*, 26 (9): 2653-64, 2003.
- 10- KHADAMY J., AGHDAM K.A. and GHASEN K.: An update on optical coherence tomography angiography in diabetic retinopathy. *J. Ophthalmic. Vis. Res.*, 13 (4): 487-97, 2018.
- 11- LIEW G., WONG V.W., SAW M., TSANG T.E., NOLAN T. and ONG S.: Profile of a population-based diabetic macular edema study: The Liverpool Eye and Diabetes Study (Sydney). *BMJ Open*, January 2019.
- 12- CHOI W., WAHEED N.K., MOULT E.M., ADHI M., LEE B., De CARLO T., et al.: Ultrahigh speed swept source optical coherence tomography of retinal and choriocapillaries alterations in diabetic patients with and without retinopathy. *Retina*, 37: 11-21, 2017.
- 13- MATSUNAGA D.R., YI J.J., De KOO L.O., AMERI H., PULIAFITO C.A., KASHANIB A.H., et al.: Optical coherence tomography angiography of diabetic retinopathy in human subjects. *Ophthalmic Surg Lasers Imaging Retina*, 46: 796-805, 2015.
- 14- HOU K.K., AU A., KASHANI A.H., FREUND K.B., SADDA S.R. and SARRAF D.: Pseudoflow with OCT angiography in eyes with hard exudates and macular drusen. *Trans. Vis. Sci. Tech.*, 8 (3): 50, 2019.
- 15- CILOGLU E., UNAL F., SUKGEN E.A. and KOCLUK Y.: Evaluation of foveal avascular zone and capillary plexuses in diabetic patients by optical coherence tomography angiography. *Korean J. Ophthalmol.*, 33 (4): 359-65, 2019.
- 16- PRELIPCEAN M. and BARHUM L.: The link between diabetes and hypertension. *Medical News Today*, May 28, 2019.
- 17- SOWERS J.R.: Diabetes mellitus and vascular disease. *Hypertension*, 61 (5): 943-7, 2013.
- 18- LEE W.H., PARK J.H., WON Y., LEE M.W., SHIN Y., JO Y.J. and KIM J.Y.: Retinal microvascular change in hypertension as measured by optical coherence tomography angiography. *Sci. Rep.*, 9 (1): 156, 2019.
- 19- PERES M.B., KATO R.T., KNIGGENDORF V.F., COLE E.D., ONAL S., TORRES E., et al.: Comparison of optical coherence tomography angiography and fluorescein angiography for the identification of retinal vascular changes in eyes with diabetic macular edema. *Ophthalmic. Surg. lasers imaging Retina*, 47: 1031-9, 2016.
- 20- LEE J., MOON B.G., CHO A.R. and YOON Y.H.: Optical coherence tomography angiography of DME and its association with anti-VEGF treatment response. *Ophthalmology*, 123: 2368-75, 2016.

- 21- REZKALLAH A., KODJIKIAN L., ABUKHASHABAH A., DENIS P. and MATHIS T.: Hypertensive choroidopathy: Multimodal imaging and the contribution of wide-field swept-source OCT-angiography. *Am. J. Ophthalmol. Case Rep.*, 13: 131-5, 2019.
- 22- CHOI W., WAHEED N.K., MOULT E.M., ADHI M., LEE B., De CARLO T., et al.: Ultrahigh speed swept source optical coherence tomography angiography of retinal and chorio-capillaries alterations in diabetic patients with and without retinopathy. *Retina*, 37: 11-21, 2017.
- 23- LU Y., SIMONETT J.M., WANG J., ZHANG M., HWANG T., HAGAG A.M., et al.: Evaluation of automatically quantified foveal avascular zone metrics for diagnosis of diabetic retinopathy using optical coherence tomography angiography. *Invest. Ophthalmol. Vis. Sci.*, 59: 2212-21, 2018.
- 24- SCARINCI F., NESPER P.L. and FAWZI A.A.: Deep retinal capillary non-perfusion is associated with photoreceptor disruption in diabetic macular ischemia. *Am. J. Ophthalmol.*, Aug., 168: 129-38, 2016.
- 25- SALAS M., AUGUSTIN M., GINNER L., KUMAR A., BAUMANN B., LEITGEB R., et al.: Visualization of micro-capillaries using optical coherence tomography angiography with and without adaptive optics. *Biomed Opt. Express.*, 8: 207-22, 2017.
- 26- FARCI R., SELLAM A., COSCAS F., COSCAS G.J., DIAZ G., NAPOLI P.E., et al.: Multimodal OCT reflectivity analysis of the cystoid spaces in cystoid macular edema. *BioMed Research International*. Volume, Article ID 7835372, 2019.
- 27- REZNICEK L., KERNT M., HARITOGLOU C., KAMPIK A., ULBIG M. and NEUBAUER A.S.: In vivo characterization of ischemic retina in diabetic retinopathy. *Clinical Ophthalmology (Auckland, NZ)*, 5: 31, 2011.
- 28- SIM D.A., KEANE P.A., FUNG S., KARAMELAS M., SADDA S.R., FRUTTIGER M., et al.: Quantitative analysis of diabetic macular ischemia using optical coherence tomography. *Investigative Ophthalmology and visual science*, 55 (1): 417-23, 2014.
- 29- YI J., LIU W., CHEN S., et al.: Visible light optical coherence tomography measures retinal oxygen metabolic response to systemic oxygenation. *Light Sci. Appl.*, 8: 207-22.
- 30- PROVIS J.M.: Development of the primate retinal vasculature. *Progress in Retinal and Eye Research*, 20: 799-821, 2001.
- 31- ONISHI A.C., ASHRAF M., SOETIKNO B.T. and FAWZI A.A.: Multilevel ischemia in disorganization of the retinal inner layers on projection-resolved optical coherence tomography angiography. *Retina (Philadelphia, Pa)*, 2018.
- 32- SUN J.K., LIN M.M., LAMMER J., PRAGER S., SARANGI R., SILVA P.S., et al.: Disorganization of the retinal inner layers as a predictor of visual acuity in eyes with center-involved diabetic macular edema. *JAMA Ophthalmology*, 132 (11): 1309-16, 2014.
- 33- HOU K.K., AU A., KASHANI A.H., FREUND K.B., SADDA S.R. and SARRAF D.: Pseudoflow with OCT angiography in eyes with hard exudates and macular drusen. *Trans. Vis. Sci. Tech.*, 8 (3): 50, 2019.

## موجودات التصوير المقطعي الضوئي الترابطي للأوعية الدموية لحالات إرتشاح الماقولة فى مرضى السكرى

إعتلال الشبكية السكرى هو إعتلال الأوعية الدقيقة الذى يسبب إنسداد الشعيرات الدموية، فرط النفوذية الوعائية، وتكوين أوعية دموية جديدة فى شبكية العين. واحد من أكثر الأسباب شيوعاً لفقدان البصر عند مرضى السكر هو إرتشاح الماقولة السكرى.

التصوير المقطعي الضوئي الترابطي للأوعية الدموية بالشبكية هو طريقة جديدة ينتج عنها صور ثلاثية الأبعاد لتدفق الدم داخل العين بإستخدام التباين الحركي. فهو يعتمد على مسح العين بالأشعة المقطعية الضوئية الترابطية ومقارنة تكرار المسح فى نفس المكان. وبإستخدام هذا النوع من التصوير، تظهر أجزاء الشبكية الخالية من الشعيرات الدموية أكثر وضوحاً من التصوير بالصبغة.

هدفت الدراسة إلى وصف موجودات التصوير المقطعي الضوئي الترابطي للأوعية الدموية فى حالات إرتشاح الماقولة فى مرضى السكرى.

الدراسة تضمنت ٤٦ أعين لعدد ٣٠ مريض سكر يعانون من إرتشاح الماقولة تم تشخيصهم بالأشعة المقطعية الضوئية الترابطية.

فى هذه الدراسة يوجد علاقة بين طول فترة إرتفاع ضغط الدم ونقص كثافة الأوعية الدموية بشبكية الشعيرات الدموية السطحية.

مساحة منطقة النقرة اللاوعائية لشبكة الشعيرات الدموية السطحية والعميقة فى الأعين التى بها عدم إنتظام الطبقات الداخلية للماقولة أكبر من الأعين ذات إنتظام الطبقات الداخلية. وكثافة الأوعية الدموية لشبكة الشعيرات الدموية السطحية أقل فى الأعين التى بها عدم إنتظام للطبقات الداخلية.

الربط بين التصوير المقطعي الضوئي الترابطي والتصوير المقطعي الضوئي الترابطي للأوعية الدموية يكون أساسى لتوضيح المتواجدة فى كل منهما.

وجود عيوب فى الأوعية الدموية الدقيقة، نزيف إفرازات صلبة بالماقولة تتسبب فى وجود أخطاء فى ترجمة صور الأشعة المقطعية الضوئية الترابطية للأوعية الدموية.

على الرغم من قدرة الأشعة المقطعية الضوئية الترابطية للأوعية الدموية على تحديد مستوى شبكة الشعيرات الدموية السطحية والعميقة إلا أن تأثير المتواجدات فى الطبقات السطحية على الطبقات العميقة يحد من هذه القدرة.

وجود وطول فترة إرتفاع ضغط الدم فى مرضى السكر يزيد من نقص تروية الماقولة.

نقص كثافة الأوعية الدموية فى شبكية الشعيرات الدموية السطحية والعميقة وفى خريطة كثافة الأوعية الدموية المبينة بصور الأشعة المقطعية الضوئية الترابطية للأوعية الدموية يجب ربطها بصور الأشعة المقطعية الضوئية الترابطية لإستبعاد وجود إرتشاح الماقولة التكييسى الذى يعطى نقص خاطئ.

العلاقة ذات الدلالة الإحصائية بين وجود عدم إنتظام بالطبقات الداخلية للماقولة المبينة بالأشعة المقطعية الضوئية الترابطية ونقص التروية الدموية المبينة بالأشعة المقطعية الضوئية الترابطية للأوعية الدموية تسمح للأشعة المقطعية الضوئية الترابطية بأن تكون كافية عندما يكون تصوير قاع العين بإستخدام صبغة الفلوريسين غير مسموح به والأشعة المقطعية الضوئية الترابطية للأوعية الدموية غير متواجدة.