

Effects of Administration of Sildenafil Citrate on the Histological Structure of the Testis and the Possible Protective Rule of Selenium in Adult Albino Rat by Histological and Immuno-Histological Methods

DORREIA A.M. ZAGHLOL, M.D.*; SALWA M. OUIS, M.D.**; WAIL M. GAD EL-RAB, M.D.*** and SAFAA M. EL-MAHDY, M.Sc.**

The Department of Human Anatomy & Embryology, Faculties of Medicine, Assuit, Sohag** Universities and Al-Azhar*** University, Assiut*

Abstract

Background: Sildenafil citrate is used for the treatment of erectile dysfunction as it maintains a long lasting erection. This drug causes nitric oxide release from the penile tissue as it acting as phosphodiesterase-5 inhibitor causing erection. Selenium plays an essential micronutrient for humans and animals acting as anti-oxidant.

Aim of Study: To study the possible protective effects of selenium on the testis of the albino rats treated with sildenafil citrate by light microscopic examination and immuno-histological study.

Material and Methods: Thirty adult albino rats were obtained and isolated at Faculty of Medicine, Assuit University in 2017. The animal were divided into three equal groups: group I (control group), group II; received sildenafil citrate orally in a dose of 10mg/kg body weight for 8 weeks, group III: Received selenium in a dose of 10 microgram/kg orally 8 weeks before the treatment with sildenafil citrate. Sildenafil was obtained in the form of commercially packed tablets (Viagra). Each tablet contains 100mg of sildenafil. The tablet was grinded and dissolved in 50ml saline; hence each ml of the solution contains 2mg of the drug. Each rat received 1.25ml of the prepared solution. Selenium was obtained in the form of commercially packed tablets (selenium). Each tablet contains 60 micro-grams. The tablet was grinded and dissolved in 30ml of saline, hence each ml of the solution contains 2 microgram of the drug. Each rat received 1.25ml of the prepared solution. At the end of the experiment, the testes were obtained and subjected to the light microscopic and immuno-histochemical studies using Fas-Ligand stain for detection of apoptotic cells.

Results: Administration of sildenafil citrate results in loss of the normal pattern of the germinal epithelium, thickening of the connective tissue capsule and loss of some of the germinal cells. The spermatogonia appear away from the basement membrane with pyknotic nucleus and vacuolated cytoplasm. The spermatogenic cells appear with pyknotic nuclei and vacuolated cytoplasm. The interstitial tissue shows

acidophilic exudates, congested blood vessels and some of the tubules appear empty. With the usage of the immuno-histochemistry, there is an increase in the number of apoptotic cells. Addition of selenium partially restored the normal contour of the tubules and normal distribution of the germinal epithelium. The thickness of the connective tissue capsule appears nearer to the normal thickness. With the usage of the immuno-histochemistry, there is a decrease in the number of apoptotic cells.

Conclusion:

- Sildenafil citrate has a toxic effect on all of the germinal cells.
- Administration of selenium partially improves these toxic effects.

Key Words: Testis – Sildenafil citrate – Selenium.

Introduction

THE recreational use of sex stimulants has been reported to be on the rise [1]. The desire to achieve a harder and long lasting erection, the need to delay ejaculation and the quest to increase genital size all are reported as reasons why young men resort to take sex stimulants recreationally [2,3]. Sildenafil citrate is a water soluble citrate salt that was firstly synthesized by Pfizer in United Kingdom to treat hypertension and angina pectoris. Interestingly, this drug exhibited different pharmacological effects & a marked penile erection [4,5]. It acts as a corpus cavernosum vasodilator, increase blood flow and improve erectile function in human [6]. Selenium is an essential trace nutrient for humans and animals. It is required for normal testicular development and spermatogenesis in rats. Serum selenium is reported to be lower in men with oligospermia and azospermia than in controls [7]. Selenium is regulating the process of spermatogenesis so it is involved in the process of male pro-

Correspondence to: Dr. Dorreia A.M. Zaghlol,
The Department of Human Anatomy & Embryology,
Faculty of Medicine, Assuit University

duction [8]. Selenium deficiency has been linked to the reproductive problems in rats, mice, pigs, sheeps and cattles. Supplementation with selenium has been reported to improve reproductive performance in mice and sheeps [9].

Aim of the work:

The aim of the work is to study the possible protective effects of Selenium on the testes of the adult albino rats treated with sildenafil citrate by light microscopic examination and immuno-histochemistry.

Material and Methods

Animals used:

Thirty adult male albino rats, weighing 200-250g, the animals were isolated and housed in the animal house at Faculty of Medicine, Assuit University in 2017. The animals were divided into three equal groups; each of them consists of 10 rats.

The groups:

Group I (control group): Includes 10 control rats. Group II (experimental group): Includes 10 of treated rat with sildenafil citrate. Group III (treated group): Include 10 of treated rat with sildenafil citrate + selenium.

Drug, dosage and administration:

1- Sildenafil citrate was given daily by oral tube in a dose of 10mg/kg body weight for 8 weeks [10]. Sildenafil was obtained in the form of commercially packed tablets (Viagra). Each tablet contains 100mg of sildenafil. The tablet was grinded and dissolved in 50ml saline; hence each ml of the solution contains 2mg of the drug. Each rat received 1.25ml of the prepared solution.

2- Selenium was given daily by oral tube in a dose of 10 microgram/kg body weight for 8 weeks before the treatment with sildenafil citrate [11]. Selenium was obtained in the form of commercially packed tablets (selenium). Each tablet contains 60 micro-grams. The tablet was grinded and dissolved in 30ml of saline, hence each ml of the solution contains 2 microgram of the drug. Each rat received 1.25ml of the prepared solution.

At the end of the experiment the animals were anaesthetized. The Scrotums were opened and the testis of animals were extracted, cut, and processed for light microscopic and immuno-histochemical studies. Monoclonal antibodies to Fas or Fas Ligand

were applied and the slides were incubated for 60 minutes, washed in PBS, incubated with the biotinylated antibody for 30 minutes, rinsed in PBS, incubated with ABC reagent for 45 minutes and washed again in PBS and the reaction product will be developed with hydrogen peroxide in AEC containing acetate buffer and counterstained with Hematoxylin. Apoptotic cells are stained dark brown [12].

Morphometric and statistical analysis:

Estimation of the diameter of the seminiferous tubules and the number of Leydig cells, in control and treated animals were done. Student *t*-test was used to compare the means of these variables between different groups. Finally the significance was considered according to the level of *p*-value significance as follows:

- $p > 0.05$ non significant.
- $p \leq 0.05$ significant *.
- $p \leq 0.01$ highly significant**.
- $p \leq 0.001$ Very high significant difference***.

Results

No deaths were recorded among the animals of all groups.

Light microscopic examination:

Group I (The Control Group):

1- Results observed by Hematoxylin and Eosin stain:

The seminiferous tubules with rounded, regular outline and lined by stratified germinal epithelium. Aggregation of spermatozoa which has whorly appearance is seen in their lumina. The interstitial spaces show Leydig cells with oval nuclei and acidophilic cytoplasm and normal blood capillaries. The tubules is lined by different layers of spermatogenic cells; spermatogonia appear as small rounded darkly stained cells with spherical nuclei resting on the basement membrane, primary spermatocytes appear relatively larger in size with large rounded nuclei, spermatids are small rounded cells with pale nuclei and spermatozoa are observed in the lumina of the tubules. Sertoli cells are detected in between the spermatogenic cells as pyramidal cells with pale basal oval or triangular nuclei with prominent nucleoli (Figs. 1,2).

Results observed by Toluidine blue stain:

The seminiferous tubules appear lined by spermatogonia, primary spermatocytes and spermatids. Sertoli cells appear pale resting on the basement membrane (Fig. 3).

Results observed by Masson's Trichrome stain: Shows thin layer of collagen fibers in the connective tissue capsule of the testis, basement membrane of the tubules (Fig. 4).

Results of Immuno-Histochemistry of the control group: Shows normal spermatogenic cells with minimal reaction (Fig. 5).

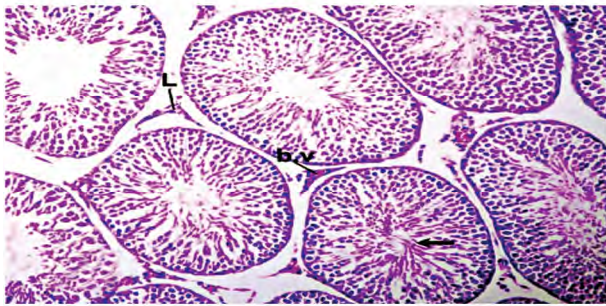


Fig. (1): A photomicrograph of a transverse section in the testis of control group showing normal seminiferous tubules with rounded, regular outline. The interstitial spaces show Leydig cells (L) and normal blood capillaries (b.v). Notice the whorly appearance of sperm flagella (↑). (H&E X 200).

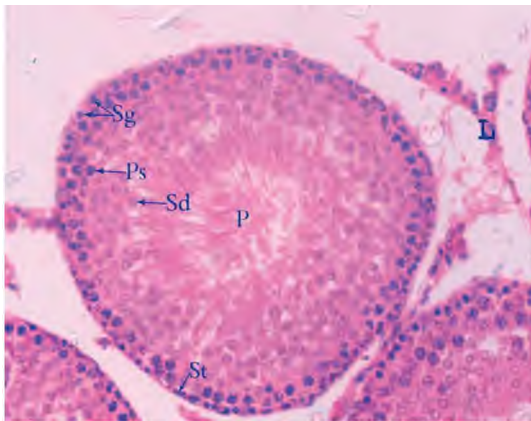


Fig. (2): A photomicrograph of a section in the testis of a control adult albino rat showing different types of spermatogenic cells; spermatogonia (Sg), primary spermatocytes (PS), spermatids (Sd) and spermatozoa (p). Sertoli cells (St) are seen resting on the basement membrane. (H&E x400).

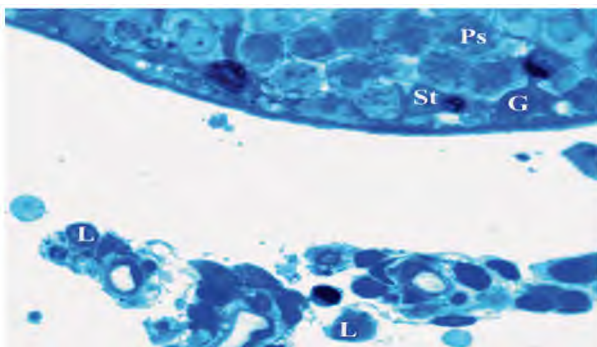


Fig. (3): A photomicrograph of a semithin section in the testis of a control adult albino rat showing a seminiferous tubules lined by spermatogonia (G), primary spermatocytes (Ps) and spermatids (Sd). Sertoli cells (St) appear pale resting on the basement membrane. Interstitial cells of Leydig (L) are also noticed. (Toluidine blue x 1000).

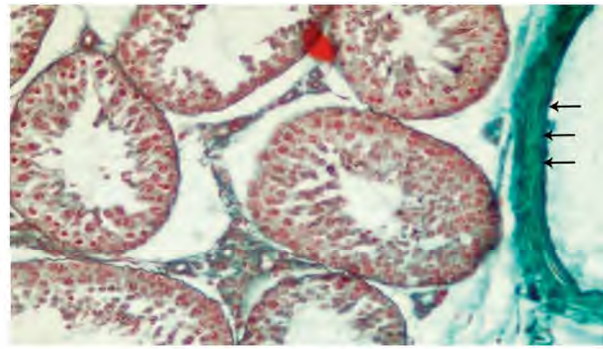


Fig. (4): A photomicrograph of transverse section in the testis of a control group showing thin layer of collagen fibers in the connective tissue capsule (↑). (Masson's Trichrome X 200).

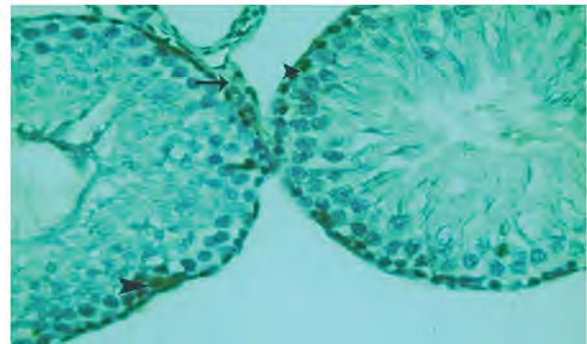


Fig. (5): A photomicrograph of a transverse section from the testis of a control group showing normal spermatogenic cells with minimal reaction (↑). (Fas-Ligand X400).

Group II:

Light microscopic examination:

Group II (The Sildenafil Citrate Group):

1- Results observed by Hematoxylin and Eosin stain:

Examination of the sections obtained from this group reveals marked disturbance in the spermatogenic epithelium. The tubules appear with irregular outline. There is a congested blood vessel and acidophilic exudates (Figs. 6,7).

Results observed by Toluidine blue: The spermatogonia appear with small pyknotic nuclei, mislocated sertoli cells with vacuolated cytoplasm, vacuolated primary spermatocytes and early spermatids. There is some areas of cellular loss (Fig. 8).

Examination by Masson's Trichrome stain: Reveals an increase in the amount of collagen fibers in the connective tissue capsule, basement membrane and in the interstitium (Fig. 9).

Examination by Immuno-Histochemical study: Shows multiple apoptotic germinal cells with positive Fas-Ligand reaction (Fig. 10).

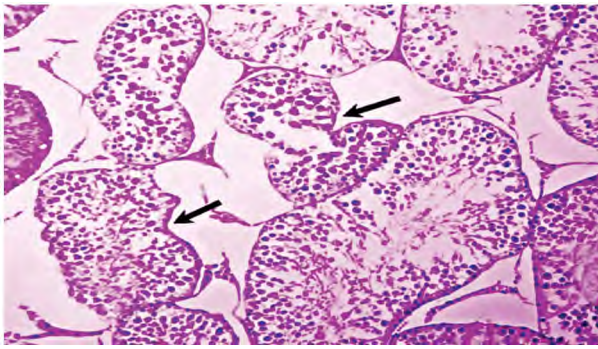


Fig. (6): A photomicrograph of a transverse section from the testis of an experimental animal showing seminiferous tubules with irregular outline (↑) with disturbance in the spermatogenic epithelium (G). (H&E X 200).

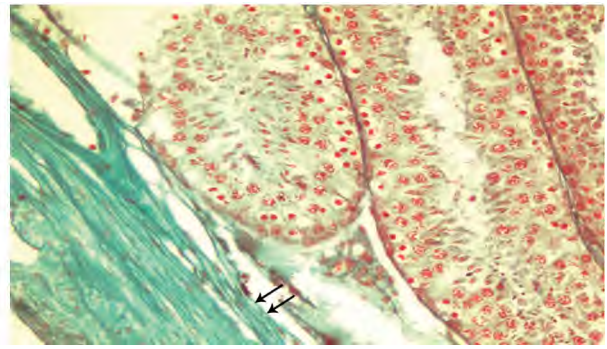


Fig. (9): A photomicrograph of a transverse section from the testis of an experimental animal showing increase in the amount of collagen fibers in the connective tissue capsule (↑). (Masson's Trichrome X 200).

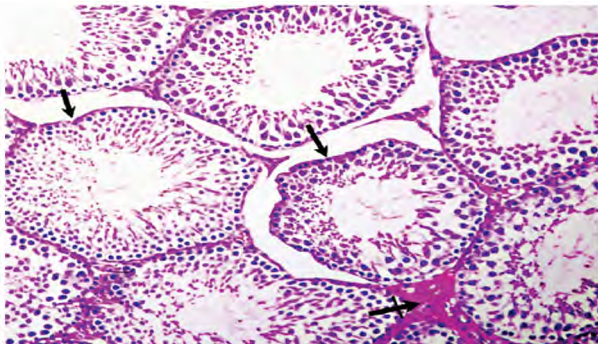


Fig. (7): A photomicrograph of a transverse section from the testis of an experimental animal showing seminiferous tubules with irregular outlines (↑). The interstitial spaces shows acidophilic exudates (crossed arrow). (H&E X 200).

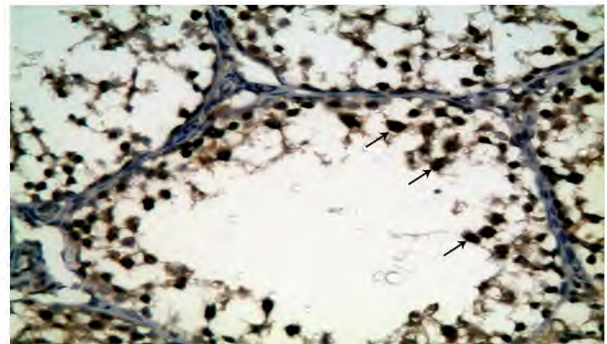


Fig. (10): A photomicrograph of a transverse section from the testis of an experimental animal showing multiple apoptotic germinal cells (↑) with +ve Fas-Ligand reaction. (Fas-Ligand X 400).

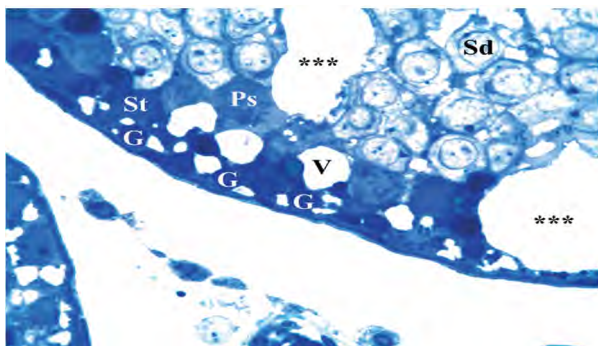


Fig. (8): A photomicrograph of a transverse section from the testis of an experimental animal showing spermatogonia cells (G) with small pyknotic nuclei, mislocated sertoli cells (St) with vacuolated cytoplasm (V), vacuolated primary spermatocytes (Ps) and early spermatids (Sd). Notice some areas of cellular loss (***) (Toluidine blue X 1000).

Group III:

Group III (The Sildenafil Citrate+Selenium Group):

1- Results observed by Hematoxylin and Eosin stain:

Examination of a section from the testis of an experimental adult albino rat (group III) is showing apparently normal seminiferous tubules with abundant whorly appearance of sperm flagella filling their Lumina. The interstitial space shows Leydig cells. Few tubules show separation of spermatogenic cells from the basement membrane. Other tubules appear empty (Fig. 11). There is a restoration of the normal appearance of the germinal epithelium, There are spermatogonia with rounded nuclei resting on regular basement membrane. Normal primary

spermatocytes with large rounded nucleus, spermatids. Spermatozoa are aggregated in the lumen of the tubule (Fig. 12).

Result observed by Toluidine blue: The seminiferous tubules appear with different stages of spermatogenesis, spermatogonia, Sertoli, primary spermatocytes and early spermatid which are apparently normal (Fig. 13).

Examination by Masson's Trichrome stain: Is showing a marked decrease in the amount of collagen fibers in the connective tissue capsule, basement membrane and in the interstitium (Fig. 14).

Examination by Immuno-Histochemical study: Is showing few scattered apoptotic germinal cells with positive Fas-Ligand reaction (Fig. 15).

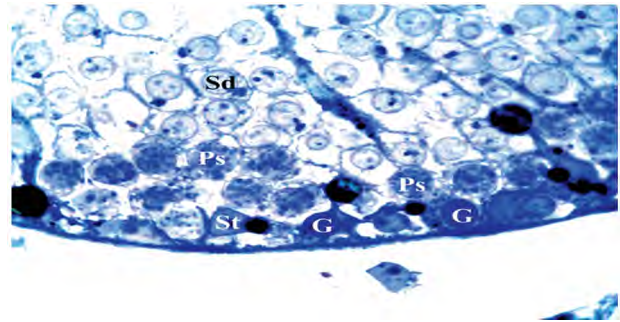


Fig. (13): A photomicrograph of a section from the testis of an experimental adult albino rat group (III) is showing an apparently normal seminiferous tubule with different stages of spermatogenesis, spermatogonia (G), Sertoli (St), primary spermatocytes (Ps) and early spermatid (Sd). (Toluidine blue X 1000).

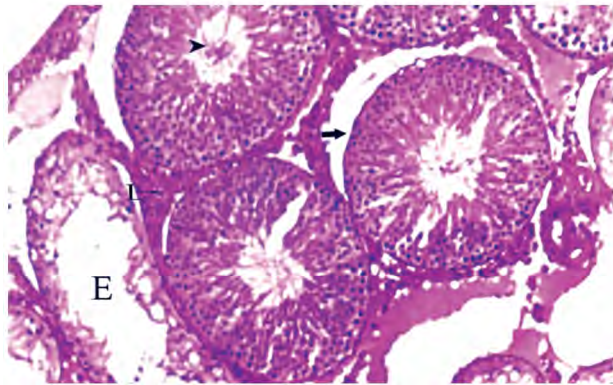


Fig. (11): A photomicrograph of a transverse section from the testis of an experimental animal (group III) is showing rounded seminiferous tubules with abundant whorly appearance of sperm flagella (arrow head) filling their Lumina. The interstitial space shows Leydig cells (L). Few tubules show separation (↑) of spermatogenic cells from the basement membrane. Other tubules appear empty (E). (H&E X 200).

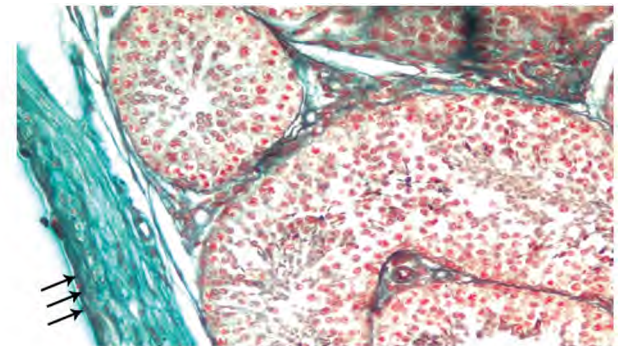


Fig. (14): A photomicrograph of a transverse section from the testis of an experimental animal (group III) is showing a marked decrease in the amount of collagen fibers in the connective tissue capsule (↑↑↑). (Masson's Trichrome X 200).

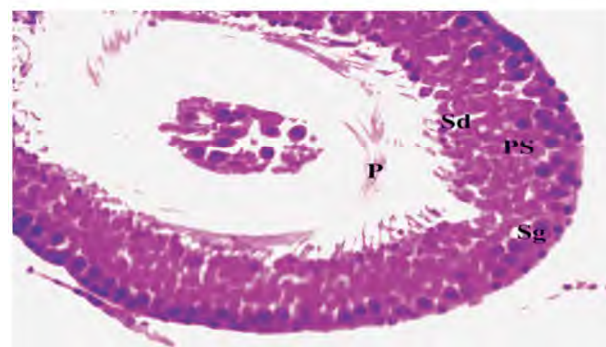


Fig. (12): A photomicrograph of a section from the testis of an experimental adult albino rat (group III) is showing restoration of the normal appearance of the germinal epithelium, There are spermatogonia (Sg) with rounded nuclei resting on regular basement membrane. Normal primary spermatocytes (Ps) appear with large rounded nucleus, spermatids (Sd). Spermatozoa (P) are aggregated in the lumen of the tubule. (H&E X 400).

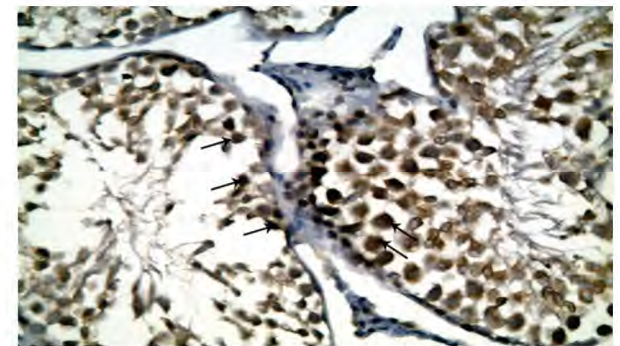


Fig. (15): A photomicrograph of a transverse section from the testis of an experimental animal (group III) showing few scattered apoptotic germinal epithelium (↑) with +ve reaction. (Fas-Ligand x 400).

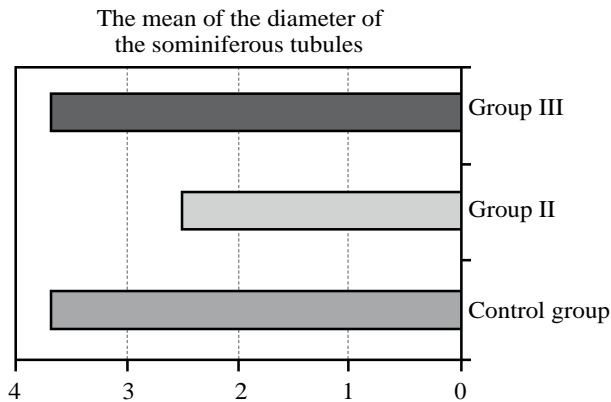
Morphometric study:

1- *Diameter of the seminiferous tubules:* (Table 1, Diagram 1):

Mean diameter of the seminiferous tubules in group II (2.5) showing a highly significant decrease ($p=0.000$) when compared with group I (3.7). The mean diameter in group III (3.7) showing non significant decrease ($p=0.000$) when compared with group I.

Table (1): Shows mean values (\bar{x}) & standard deviation (SD) and standard error of mean (SEM) of the diameters of seminiferous tubules.

	Control group	Group II	Group III
($\bar{X} \pm SD$)	3.7±0.3	2.5±0.4	3.5±0.2
SEM	0.06	0.08	0.04
p-value		0.000***	0.456NS




2- The mean of the number of the Leydig cells: (Table 2, Diagram 2):

Mean number of the Leydig cells in group II (2.5) is showing a highly significant increase ($p=0.000$) when compared with group I (5.6). The mean diameter in group III (4) showing non significant increase ($p=0.000$) when compared with group I.

Table (2): Shows mean values (\bar{x}) & standard deviation (SD) and standard error of mean (SEM) of number of Leydig cells.

	Control group	Group II	Group III
($\bar{X} \pm SD$)	3.75±0.9	5.6±1.2	4±0.8
SEM	0.2	0.3	0.18
p-value		0.000***	0.249NS



• *t*-Test between control group and group II:

	p-value
Diameter of seminefrous tubules	0.000***
Number of Leydig cells	0.000***

NB (***): Very highly significant.

• *t*-Test between control group and group III:

	p-value
Diameter of seminefrous tubules	0.456NS
Number of Leydig cells	0.249NS

NB (***): Very highly significant & (NS) not significant.

Discussion

In the present work we investigated the toxic effect of administration of the drug on the seminiferous tubules by light microscopic examination and immunohistochemical study.

In the present study, by light microscopic examination of group (II) there were impaired spermatogenesis, detached and mislocated germ cells, necrosis of the seminiferous tubules, increase in the thickness of the basement membrane, widened interstitial tissue with the deposition of acidophilic materials, vacuolation of the cytoplasm, congestion and dilatation of the blood vessels.

More over this study reported attenuated germinal epithelium and this in accordance with [13] who reported that administration of sildenafil citrate in a impaired the spermatogenesis, decreased the spermatogenic layers, arrested the spermatogenesis at the level of primary spermatocytes. There was a necrosis of seminiferous tubules, widening in the interstitial space and increasing in the thickness of the basement membrane.

In this work the tubules are separated and the interstitial blood vessels are congested and this in agreement with [14] who found that sildenafil citrate treated mice the seminiferous tubules are widely separated from each other, the volume and diameter of seminiferous tubules were decreased. The inter-tubular oedema disturbed the seminiferous epithelium nutrition and caused lysis of spermatogenic cells.

Administration of sildenafil citrate resulted in altered situation in trace element environment which may culminate in enhanced peroxidase activity, growth retardation, tissue damage and struc-

tural deformities. The spermatogenesis are also getting drastically affected [15].

[16] reported that Selenium decreased the thickening in the capsule, vacuolation, congestion, oedema.

[15] reported that treatment with Sildenafil citrate leads to distorted histoarchitecture of the seminiferous tubules, interstitial space dilatation, thickening in the basement membrane.

Light microscopic examination of group III (selenium treated group) the tubules appear with normal germinal epithelium, decrease the intercellular vacuolations and decrease the thickness of the basement membrane.

Selenium in a dose of (0.5mg/kg) reduced the oxidative stress and apoptosis caused by testicular injury in rats by its anti-oxidant and anti-apoptotic effects [17].

[18] reported that the histological architecture of the testes of selenium treated rats in a dose of (300 microgram/kg) and atrazine showing that the seminiferous tubules with normal spermatogenesis this in agreement with our study that revealed normal spermatogenic cells at different stages of maturation.

Selenium in a dose of (0.5mg/kg) decreased the developmental testicular toxicity induced by di-n-butyl phthalate in pre-pubertal male rats by restoration of the normal diameters of the seminiferous tubules and by decreasing necrosis and desquamation of Leydig and Sertoli cells [19].

[20] found that selenium in a dose of (0.5mg/kg) decreased sodium azide toxicity in kidney and liver as it acts as anti-oxidant and improved the oxidative stress in the damaged tissues in mice.

Conclusion:

- Sildenafil citrate has a toxic effect on all of the germinal cells.
- Administration of selenium partially improves these toxic effects.

Recommendation:

More researches on the antioxidant effect of selenium on different types of tissues in the human body and against different toxic drugs.

References

- 1- NNA V.U., OFEM O.E. and OSIM E.E.: Prevalence of sex stimulants abuse among male subjects in Calabar, Cross River State, Nigeria, following perceived beneficial effect in increasing genital size. *The Journal of Sexual Medicine*, 13 (5) Suppl: 545-555, 2016.
- 2- BECHARA A., CASABE A., De BONIS W., HELEIN A. and BERTOLINO M.V.: Recreational use of phosphodiesterase type 5 inhibitors by healthy young men. *The Journal of Sexual Medicine*, 7 (11): 3736-3742, 2010.
- 3- NNA V.U., ANI E.J., OFUTET E.O., IROH C.E. and OSIM E.E.: Recurrent side effects following chronic recreational use of sex stimulant among male subject in Calabar, Cross River Nile State' Nigeria. *Der Pharmacia Lettre*, 6 (2): 56-61, 2014.
- 4- KALSI J.S. and KELL P.D.: Update on oral treatment for male erectile dysfunction. *J. Eur. Acad. Dermatol. Venerol*, 18 (3): 267-274, 2004.
- 5- UTHAYATHAS S., KARUPPAGOUNDER S.S., THRASH B.M., PARAMESHWARAN K., SUPPIRAMANIAM V. and DHANASEKARAN M.: Versatile effects of Sildenafil: Recent pharmacological applications. *Pharmacological report Journal*, 59 (2): 150-163, 2007.
- 6- MICHEL T.: Treatment of myocardial ischemia. *The Pharmacological basis of therapeutics*. Goodman and Gilman's, 11th ED, London, 2006.
- 7- MAIORINO M., ROVERI A. and URSINI F.: Selenium and male reproduction, Ch (28), (3rd) Ed In: Hatfield D.L., Berry M.J., Gladyshev. *Selenium and its molecular biology and role in human health*. Springer Science + Business Media, New York, pp: 323-331, 2006.
- 8- SHALINI S. and BANSAL M.P.: Role of selenium in regulation of spermatogenesis. *Biofactors*, 23 (3): 151-162, 2005.
- 9- SANTOS R. and TAKAHASHI C.: Anticlastogenic and antigenotoxic effects of selenomethionene on doxorubicin induced damage in vitro in human lymphocytes. *Food Chem. Toxicol.*, 46 (2): 671-677, 2008.
- 10- NNA V.U. and OSIM E.E.: Testicular toxicity following separate and combined administration of PDE5 inhibitors and opioid: assessment of recovery following their withdrawal. *Andrologia*, 49 (6): 1111-12669, 2016.
- 11- MOHAMED S.A.: Histopathological and ultrastructural effects of methyl parathion on rat testis and protection by selenium. *Journal of Applied Pharmaceutical Science*, 3 (2): 53-63, 2013.
- 12- GRIFFITH T.S., BRUNNER T., FLETCHER S.M., GREEN D.R. and FERGUSON T.A.: Fas ligand-induced apoptosis as a mechanism of immune privilege. *Science*, 270 (5239): 1189-1192, 1995.
- 13- EZZ-ELDIN E., ZIENAB M., ABD-ELGHANY A. and IBRAHIM M.: Evaluation the effect of sildenafil citrate (SC or Viagra) on senile albino rat testis (histological and biochemical study). *Egyptian Journal of Hospital Medicine*, 49 (4): 911-932, 2012.
- 14- SURIYAKUMARI K. and UDAYAKUMAR R.: Histological studies on testis of albino mice treated with Sildenafil citrate. *International Journal of Basic and Applied Medical Science*, 5 (3): Pp. 77-82, 2015.
- 15- SURIYAKUMARI K., UDAYAKUMAR R. and SAVITHA D.: Trace element and light microscopic studies on testis of albino rat treated with sildenafil citrate. *International Journal of Anatomy and Research*, 3 (2): pp. 1168-1172, 2015.

- 16- BINSAWAD A. HANADI, ABDUL HAKEEM M. KEL-ANY, FATMA M. EL QUDSI, HANAN A. AMEEN and SALAH A. EL KARIUM: The possible protected effects of selenium and vitamin E in reducing smoking effects on testes of albino rats. Ass. Univ. Bull. Environ. Res., 14 (1): 61-76, 2011.
- 17- KARA O., SARI H., AKSIT H., YAY H.A., ASKIT D. and DONMEZ M.: Effects of selenium on ischemia-reperfusion injury in a rat testis model. Andrologia, 48 (10): 1267-1273, 2016.
- 18- HEBA F., DESOUKY H., ELDEBAKY A. and SHALABY S.: Protective role of selenium against adverse effects of atrazine toxicity. Global Veterinarian Journal, 15 (4): 357-365, 2015.
- 19- MAHA M., MONA K., KHALED S., ADEL M., EMAN M. and SAID Z.: Selenium attenuates the developmental testicular toxicity induced by di-n-butyl phthalate in per-pubertal male rats. Biomedicine and Pharmacotherapy Journal, 107: 1754-1762, 2018.
- 20- REHAM Z., MOHAMMED S. and NAHLA S.: Ameliorative effects of vitamin E and selenium against oxidative stress induced by sodium azide in liver, kidney, testis and hearts on male mice. Biomedicine and pharmacotherapy Journal, 91: 602-610, 2017.

التأثيرات الوقائية المحتملة لعقار السيلينيوم على الخصى المعالجة بالسيلدينافيل سترات في الفئران البيضاء البالغة

لقد أصبح السيلدينافيل سترات واحد من أهم الأدوية التي شاع وصفها وتعاطيها. لقد أصبح من أهم المواد المستخدمة لعلاج مشاكل الضعف الجنسي. ولقد أعلنت الدراسات أن الآثار الجانبية لهذا العقار بسيطة أو متوسطة.

الهدف من الدراسة: هو دراسة التأثيرات الوقائية المحتملة للسيلينيوم على خصى الفئران المعالجة بعقار السيلدينافيل باستخدام الميكروسكوب الضوئي وباستخدام كيمياء النسيج المناعية.

لقد أجريت الدراسة الحالية على ٤٥ من الفئران البالغة ولقد تقسيمهم إلى ثلاث مجموعات كل مجموعة تحتوى على ١٥ فأر.

المجموعات هي:

- المجموعة الأولى تحتوى على ١٥ فأر وقد تم إعطائهم محلول ملح بجرعة ٢٥ مللى جرام / كيلو جرام.
- المجموعة الثانية تحتوى على ١٥ فأر تم معالجتهم باستخدام السيلدينافيل سترات.
- المجموعة الثالثة تحتوى على ١٥ فأر تم معالجتهم باستخدام السيلدينافيل سترات + السيلينيوم.

وقد تم إعطاء السيلدينافيل عن طريق الفم بجرعة ١٠ مللى جرام / كيلو جرام لمدة ٨ أسابيع.

وقد تم إعطاء السيلينيوم عن طريق الفم بجرعة ١٠ ميكروجرام / كيلو جرام لمدة ٨ أسابيع قبل إعطاء السيلدينافيل.

وفى نهاية التجربة تم تخدير الفئران باستخدام الأثير وتم فتح كيس الصفن وإستخراج الخصى ثم تم تحضير العينات و معالجتهم باستخدام الطرق الهستولوجية وباستخدام الميكروسكوب الضوئي.

باستخدام السيلدينافيل سترات: قد أدى إضافة إلى حدوث فقد فى النمط الطبيعي للبطانة المنبته، زيادة فى سمك النسيج الضام المغلف للخصية وزيادة فى سمك وعدم إنتظام الغشاء القاعدى للأنبوبات المصابة مع وجود فقد فى بعض الخلايا المنبته. لقد ظهرت أمهات الخلايا المنوية بعيداً عن الغشاء القاعدى مع وجود إنكماش فى الأنوية وحدث فجوات فى السيتوبلازم. أما بالنسبة للخلايا المتبقية لوحظ وجود إنكماش فى الأنوية مع وجود فجوات فى السيتوبلازم. كما لوحظ وجود إرتشاح فى النسيج البيئى مع وجود أوعية دموية محتقنة. وقد ظهرت بعض الأنبوبات فارغة.

بإضافة السيلينيوم مع السيلدينافيل سترات: بإضافة السيلينيوم حدث إستعادة جزئية للشكل الطبيعي والتوزيع الطبيعي للخلايا فى البطانة المنبته. وقد ظهر سمك النسيج الضام المغلف للخصية والغشاء القاعدى للأنبوبات المنوية أقرب للطبيعي.

الخلاصة:

- السيلدينافيل سترات له تأثيرات سامة على كل الخلايا المنوية المنبته.
- تقل هذه التأثيرات جزئياً مع إضافة السيلينيوم.

التوصيات: نوصى بالمزيد من الأبحاث على التأثيرات السامة للسيلدينافيل على مختلف أنواع الأنسجة وبمختلف الجرعات فى جسم الانسان وعلى مختلف العقاقير السامة الأخرى.