

## Role of Trans-Arterial Embolization in Management of Bone Tumors

WALAA MAHMOUD, M.D.\*; MOHAMMED A.A. ELHAWARY, M.D.\*; AHMED G. SADEK, M.D.\*; MOHAMED A. BORG, M.D.\* and MOHAMED F.M. MOSTAFA, M.D.\*\*

*The Departments of Diagnostic and Interventional Radiology\* and Orthopedic Surgery\*\*, Faculty of Medicine, Mansoura University, Mansoura, Egypt*

### Abstract

**Background:** Trans-arterial embolization (TAE) is a promising less aggressive modality in either primary treatment or adjuvant to surgical management of bone tumors. The main aim is to induce necrosis and decrease bleeding and therefore facilitate resection. Palliation of compression manifestation of inoperable bone neoplasm is another indication of TAE. Frequent tumors selected to this modality include vascular tumors (particularly metastases), aneurysmal bone cysts (ABC), giant cell tumor (GCT), and osteosarcoma.

**Aim of Study:** Our aim is to assess the role of embolization in management of bone tumors.

**Patients and Methods:** The current study prospectively evaluated 33 patients (23 males and 10 females). Their age ranged from 9 to 69 years (mean age of  $43.246 \pm 19.65$ ). Extremities, hip, vertebrae, and skull were involved by variety of bony tumors. Sixteen patients were affected by primary osseous tumors, while 17 patients had metastases. A transarterial embolization was done in all patients as a preoperative procedure in 15 patients, definite treatment of primary benign inaccessible tumors in 6 patients, prebiopsy embolization in 6 patients, and as a palliative treatment in 6 patients.

**Results:** Technical success was obtained in 30 out of 33 cases with percentage of 90.9%. All benign and primary malignant bony tumors showed technical success while, 82.4% of metastatic lesions did.

Clinical success was achieved in 73.3% cases of first group, 83.3% of second group, 100% of third group and 66.7% of fourth group. Four patients (12.1%) showed no clinical improvement with 9% lost follow-up.

Five out of 6 benign tumors showed clinical success (83.3%) as the sixth case lost follow-up (16.7%). Embolization of 9 of primary malignant lesions was clinically successful (90%), whereas 12 out of 17 metastatic lesions were improved clinically (70.6%), 3 cases showed no clinical success (17.6%), and 2 cases were lost at follow-up (11.8%).

**Conclusion:** A high consideration should be given to transarterial embolization in the algorithmic treatment strategy of bone tumors as it is much safer and effective tool when diminution of bleeding and compression manifestations is to be specifically aimed.

**Key Words:** Transarterial – Embolization – Bone tumors – Microcatheters – PVA – Gelfoam.

### Introduction

**DIFFERENT** lines of treatment of bone neoplasms are employed according to type of the tumor either primary or metastatic. Surgery is the conventional line of treatment with other additional therapies. Very large tumors, high vascularization, or proximity to important structures may lead to difficult and hazardous surgeries. Recently, transarterial embolization (TAE) is considered the most effective preoperative procedure with subsequent rapid relief in pain and tumor shrinkage in the majority of bone neoplasms. It could be a definite treatment especially in benign tumors such as haemangioma and giant cell tumors [1,2]. Palliation of pain and neurological symptoms and, thereby improving life quality could be achieved successfully in those with irresectable bone neoplasia [3,4].

Promising results of TAE could be obtained when the bone tumor is hypervascular in nature such as giant cell tumors (GCT), aneurysmal bone cysts (ABC), haemangiomas, arterio-venous malformations, osteoblastoma, osteosarcomas and highly vascular metastases (renal cell or thyroid carcinomas) [5-8].

In this study, we aim to evaluate the efficacy of embolization as an initial preoperative, curative or palliative treatment modality in bone tumors either primary or metastatic.

**Correspondence to:** Dr. Walaa Mahmoud, The Department of Diagnostic and Interventional Radiology, Faculty of Medicine, Mansoura University, Mansoura, Egypt

### Patients and Methods

Institutional Review Board (IRP) of our institution approved this prospective study and informed consents were obtained from all patients. The present study was conducted on cases referred to Department of Radiology, Mansoura University Hospitals from July 2017 till February 2020. The study enrolled 33 patients (23 males and 10 females) with vascular bone tumors. The participants ranged from 9 to 69 years (mean age of  $43.246 \pm 19.65$ ).

According to the purpose of the embolization the included patients were categorized into 4 groups; preoperative embolization (n=15, 45.5%), definite treatment (n=6, 18.2%), pre-biopsy embolization (n=6, 18.2%), and palliative embolization (n=6, 18.2%).

Benign tumors were found in 6 cases (18.2%; aneurysmal bone cyst in 5 cases and vertebral hemangioma in one case). Primary malignant bone tumors were found in 10 cases (30.3%; osteosarcoma in 6 cases, plasmacytoma in 2 cases, chondrosarcoma and recurrent sacral sarcoma in one case each). Seventeen patients (50.1%) were diagnosed with metastatic bony lesions (HCC in 6 cases, RCC in 4 cases, pancreatic and thyroid cancers in 2 cases for each, colonic, breast, and chondrosarcoma in one case for each). Pre-procedural pathological diagnosis was obtained in all patients except in patients referred for pre-biopsy embolization.

The most common encountered affected bone was humerus (n=8; 24.2%), followed by iliac bone (n=5; 15.2%), and sacrum (n=5; 15.2%). Other sites are illustrated in (Table 1).

Table (1): Demonstrating anatomical sites of bony lesions in included 33 cases.

Tumor site	Number (%)
Scapula	3 (9.1%)
Humerus	8 (24.2%)
Femur	3 (9.1%)
Acetabulum	2 (6.1%)
Clavicle	3 (9.1%)
Iliac bone	5 (15.2%)
Pubic bone	2 (6.1%)
Tibia	1 (3%)
Skull	1 (3%)
Sacrum	5 (15.2%)

Pre-procedural laboratory investigations were done to guarantee safe embolization. CTA and/or MRA were done to assess the feeding vessels and mapping the treatment strategy.

### Technique:

Embolization and pre-procedural angiography both were done using either (Phillips - AlluraXper FD20/20 X-ray system) or (Philips BV pulsera C-arm W/9"i/Flat panels-Vascular Package), under local anesthesia. Common femoral artery approach was used in all procedures. Initial flush arteriogram was performed to map out arterial anatomy. For spinal and pelvic tumors, an aortogram is performed initially; however, for peripheral tumors, an arteriogram of the main extremity artery was performed. When stable selective catheterization was accomplished, a microcatheter was used to target the direct supplying arteries of the tumor.

Selective catheterization was achieved using either copra, angled catheter, rim, Mani or glide catheters, while coaxial microcatheterization was done in 29 patients (87.9%) using Progreat (in 25 cases; 75.8%), Renegade was used alone in 2 cases (6.1%) and in conjugation with Marathon in one case, whereas Merit catheter was used in only one case.

Twenty eight embolizations were performed using single embolic material (gel-foam in 18 cases; 54.5% and polyvinyl alcohol in 10 cases; 30.3%). In 4 cases we used a mixture of PVA and Gel-foam, while PVA with gel-foam and pushable coil were used in the remaining case.

Reaching the angiographic endpoint could be achieved by loss of blush in vascular bed of the tumor; however, any reduction in antegrade blood flow could be considered a successful technical outcome (Fig. 1). It was performed before 24h of surgery to avoid formation of collateral vessels in the interval between the embolization and surgery.

Patients comprised in the pre-operative embolization group (45.5%) were compared with additional randomly chosen group (no TAE was done) with no statistically different mean age, tumor size, vascularity, bleeding tendency measurement and operating team. Technical success (regarding intra-operative blood loss) was evaluated in both groups. Peri-operative blood loss was quantified by measuring blood in the suction machine, weighting the operative sponges during surgery, measuring irrigation fluid, and from the postoperative suction drainage.

In definitive treatment embolization group (18.2%), serial follow-up radiological studies were done for monitoring devascularization degree, increased CT density (due to sclerosis) or debulking of the tumor as well as decreased threshold and frequency of pain.

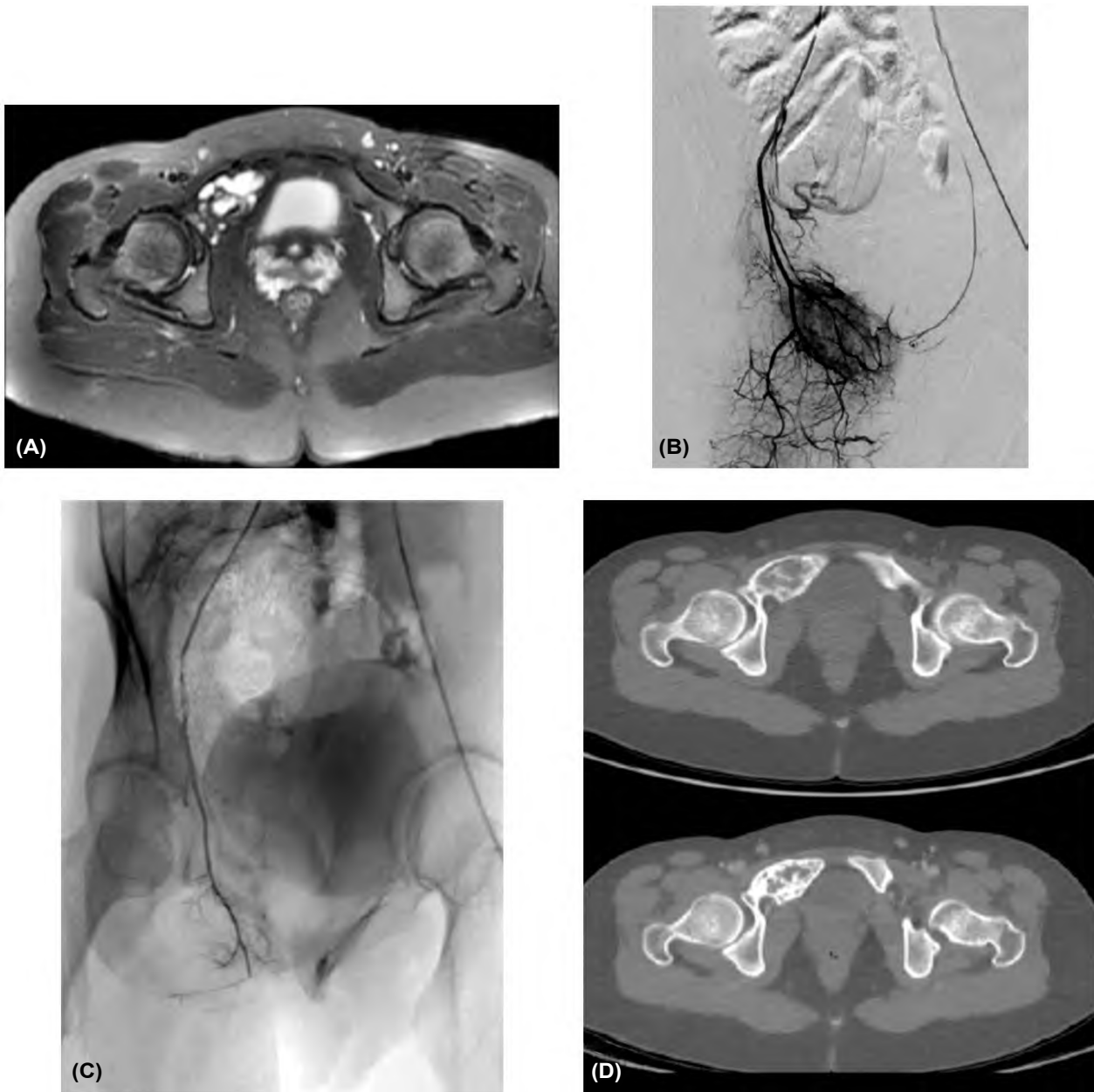


Fig. (1): Female patient 17 years old with right pubic ABC. (A): MRI pelvis revealed multilocular right pubic bone benign looking lesion with fluid fluid levels on T2 (ABC). (B): Pre-embolization significant Tumor blush. C: Post-embolization no blush. (D): 6 months interval CT revealed significant increased sclerosis and mild regression in size.

In pre-biopsy embolization group (18.2%), intra-procedure blood loss monitoring was done. In palliative embolization group (18.2%), clinical outcome was assessed by regression of either degree or frequency of hemorrhage, pain, and compression manifestations. Two doctors' reviews were obtained. If obviously opposing reviews; higher staff consultation was requested.

*Statistical analysis:*

The collected data was coded, processed and analyzed using SPSS program (version 21) for

windows. The appropriate statistical tests were used when needed. *p*-value less than 0.05 will be considered to be statistically significant.

**Results**

Technical success reflected immediate results of embolization and is typically evaluated with completion of angiography. It was monitored by evaluation if selective access of all feeders was done and subjective evaluation of devascularization rate.

Technical success was obtained in 30 out of 33 cases with percentage of 90.9% (in 80% of pre resection embolization, in all patients of definitive treatment, pre-biopsy and palliative embolization groups (Table 2).

All benign and primary malignant bony tumors showed technical success while, 82.4% of metastatic lesions did.

The technical success of our procedure is dependent upon the superselective catheterization of every single feeder and degree of devascularization which was obtained after TAE. Our subjective cut offpoint was 80%. Only 4 cases had less than 80% with percentage about 12.1%. In the other 29 cases, 80% devascularization or more was obtained.

As regard the clinical success of embolization procedure in the first group (Table 3), the mean tumor diameter did not differ significantly between those patient who underwent TAE before surgery and the other group with no pre-operative embolization ( $p=0.924$ ). Although less intra-operative blood loss was observed after embolization 840ml vs. 1080ml without embolization but with no statistical significance ( $p=0.133$ ).

Regarding the 6 patients for whom TAE was performed for curative intention, the number of embolization sessions ranged between 1-3 sessions. CT angiography was used for follow-up. The follow-up period ranged between 3 and 12 months. However, one case was lost during follow-up. Apart from that case, decreased vascularity and increased density were detected in other lesions after intervention (83.3%). Moreover, clinical improvement and decreased tumor size was also reported in that 5 cases.

Concerning the 6 patients who were referred for TAE as pre-biopsy tool, all cases showed no significant blood loss, smooth procedure and were discharged in same day without significant complication.

The remaining 6 cases who were referred for TAE as palliative treatment, clinical success was detected in all cases apart from two cases who were lost during follow-up (66.7%). Clinical success was measured by symptom improvement and it was judged by two different observers.

Our procedure was accomplished without any significant complications in about 21 cases (63.6%). But puncture site and local tumor pain were the main complications and they were noted in 7 cases (21.2%). It was managed by simple analgesics in

all cases. Broken catheter (copra) tips, dissection of the feeding branch, rupture of small parietal branch were noticed in single case for each.

Five out of 6 benign tumors showed clinical success (83.3%) as the sixth case lost follow-up (16.7%). Embolization of 9 (out of 10) primary malignant lesions was clinically successful (90%), whereas 12 out of 17 metastatic lesions were improved clinically (70.6%), 3 cases showed no clinical success (17.6%), and 2 cases were lost at follow-up (11.8%). (Fig. 2).

Table (2): Technical success according to Trans-Arterial Embolization indication.

	Preoperative (n=15)	Definitive (n=6)	Pre-biopsy (n=6)	Palliative (n=6)	Total (n=33)
No	3 (20%)	0 (0%)	0 (0%)	0 (0%)	3
Yes	12 (80%)	6 (100%)	6 (100%)	6 (100%)	30 (80%)

Table (3): Comparison between operative cases with and without preoperative embolization.

Parameter	Operated cases without pre-operative TAE	Operated cases with pre-operative TAE	t / Z
Max diameter	10.2±2.8	10.1±2.9	t=0.096
Intra-operative blood loss	1080±289	840±528	t=1.545
Units of blood transfusion needed	2 (1-2)	1 (0-2)	Z=-1.493

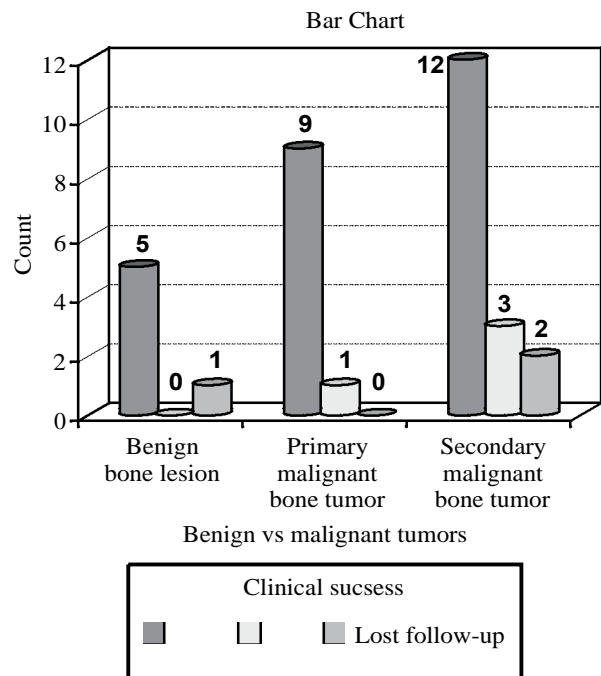


Fig. (2): Column chart demonstrating achieved clinical success according to tumor classification.

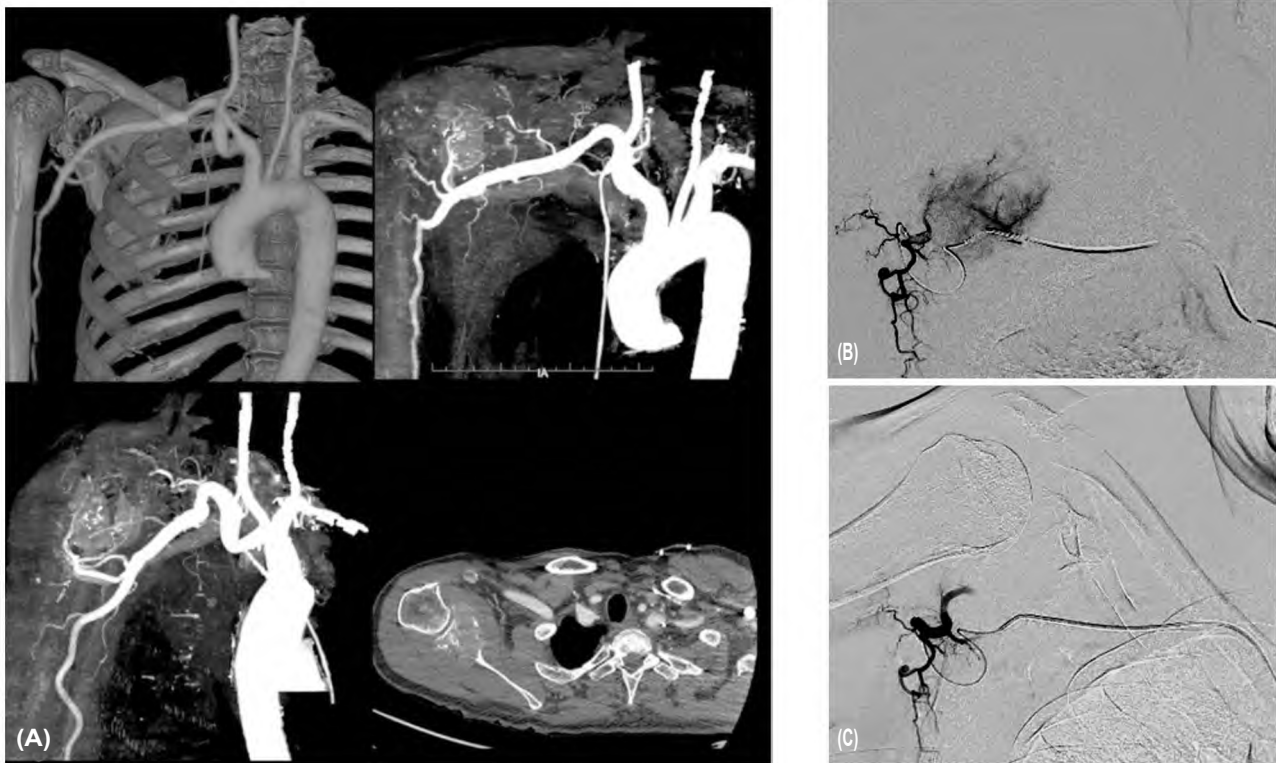

Fig. (3): Male patient 62 years old with a well-defined destructive bony lesion seen at the right glenoid with extensive large extra-osseous soft tissue component. (A): CT angiography of the right upper limb revealed the previously described pathologically proven plasmacytoma. (B): Pre-embolization run (DSA) after super-selective catheterization of the main feeding artery using merit microcatheter revealed significant tumor blush. (C): Post-embolization run (DSA) after super-selective catheterization of the main feeding artery using merit microcatheter revealed no significant tumor blush.

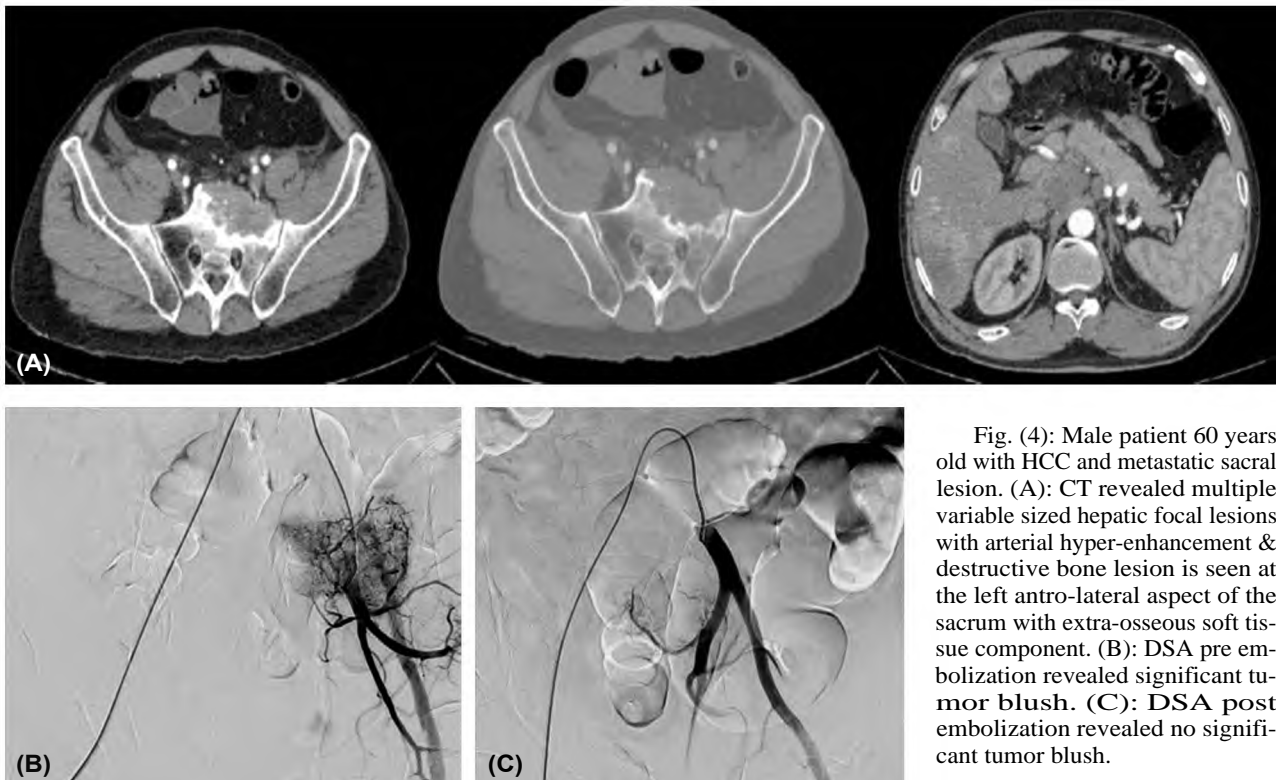


Fig. (4): Male patient 60 years old with HCC and metastatic sacral lesion. (A): CT revealed multiple variable sized hepatic focal lesions with arterial hyper-enhancement & destructive bone lesion is seen at the left antro-lateral aspect of the sacrum with extra-osseous soft tissue component. (B): DSA pre embolization revealed significant tumor blush. (C): DSA post embolization revealed no significant tumor blush.

## Discussion

Therapeutic embolization could be carried out with different intentions. It may be utilized as an operative adjuvant aiming to diminish the potential hazard of hemorrhage, better delineation of tumor margins and thereby, simplification of surgery especially in highly vascularised lesions. Also, it could be employed as a relatively less aggressive palliative procedure in a patient with poor condition or when surgical intervention is hazardous. Moreover, pain palliation, relief of fever and hypercalcemia are considered valuable indications of TAE in the setting of bone tumor management. Embolization may enhance response of tumor cells to radiation or chemotherapy [7,9,10].

Embolization aims to keep up ischemia and necrosis within the center of the tumor, by occluding small distal feeders inside the tumor. Thus, a tumor will shrink, borders between the tumor and the surrounding tissue will become distinct, improving ability of the surgeon to control bleeding leading to easier surgical excision and manipulation [11].

Vast majority of the similar previous studies suggested that TAE was performed under local anaesthesia as done in our study.

In our study, only 5 cases had  $\geq$  1000ml intra-operative blood loss (metastatic HCC, breast carcinoma, RCC, osteosarcoma and recurrent sacral sarcoma) with devascularization less than 80% in four of them. The degree of devascularization which was obtained after TAE was 80% or more in 29 cases.

In the same context, Sun and Lang's [12] reported in their experiences with 16 patients that bleeding reduces significantly in lesions of  $>70\%$  devascularization degree on follow-up angiographies.

Wirbel et al. [13] agreed that hypervascular bony metastatic lesions represent a surgical challenge. In their study of 32 patients with a preoperative TAE, there was a significant difference in blood loss and transfusion requirements compared with non embolized controls. The operation time was shorter yet with no statistical significance. There were no attributable neurological deficits.

In another study, Chu et al. [14] used chemo-embolic combination and found that application of transarterial chemoembolization (TACE) appears to enhance tumor cell necrosis and lead to decrease incidence of local recurrence.

In this work, all cases were operated 1 day after embolization apart from one case operated 3 days

after the embolization session. Barton [15] reported that an interval of 3 or more days between embolization and surgery had raised the risk of blood loss in those patients because of rapid revascularization of tumors.

In the current study, embolization was employed as a definitive treatment of 6 benign tumors (5 ABC and one vertebral haemangioma). Three cases of ABCs were embolized twice, one case three times and the last one was embolized only one time. Technical success was achieved in all cases (100%), while clinical success was experienced in 5 cases as one case lost follow-up. CTA revealed decreased vascularity, significant increased density of the lesion with mild regression in size was noted in 4 cases.

Guzey et al. [16] reported that embolization, in addition to radiation therapy and cryotherapy, had been used for management of recurrent or inaccessible aneurysmal bone cyst either as a primary or a preoperative procedure instead of surgical resection alone which used to be the treatments of choice but with increased risk of local recurrence.

In similar studies, Börüban et al., Yildirim et al., and Rossi et al. [17-19] found that embolization of ABC, either alone or followed by resection, and curettage improved resolution of lesions with no recurrence.

Lin et al. [20] had similar results in their study done for 18 GCT with 50% of patients showed durable response and 31% showed local recurrence at 10 years and 43% at 15 years. Börüban et al. [17] used TAE in two cases of haemangioma with less satisfactory results.

A preoperative biopsy precipitated massive hemorrhage in vascular bone tumors which could be managed with TAE [21]. This was in agreement with our 6 cases referred for a pre-biopsy embolization who showed devascularization rate more than 80%. The procedure was smooth with insignificant blood loss.

In this study; six cases were embolized as a palliative treatment. They were referred for intolerable pain (5 cases), limited movement (5 cases), and significant increased lesional growth rate with intra-tumoral hemorrhage (2 cases). One of them lost follow-up while other cases show subjective clinical improvement.

Targeted occlusion of the feeding vessels after embolization will reduce the volume of a tumor; thus, compression on the elevated periosteum will



be revoked and contributes to pain alleviation. The pain-free period may be variable and re-embolization may be needed in some cases. In the literature, reported pain-free periods are between 2 and 8 months [2,9,22,23,24].

In the current study, TAE procedure was completed with usage of coaxial system in 29 cases. The most used microcatheter was Progreat, which was used in 25 cases (75.8%).

Usage of microcatheters is considerably advantageous as they provide target delivery of the embolic agent further from the parent vessel to smaller feeding branches and therefore doubt less cut back the possibility of non-target embolization (Fig. 3) [9,24].

More recently, the development of upgraded coaxial microcatheters, guidewires, and digital angiographic equipment have enabled more peripheral superselective catheterization of distal vessels, allowing more selective vascular interventions [25-28].

In our study, gel foam was the most common used embolic material (18 cases-54.5%), followed by PVA (10 cases-30.3%).

The chosen embolic material should suit the catheter size and diameter of targeted vessels. Familiarity with the unique pharmaceutical properties of each embolic agent, desired outcome of embolization procedures, flow characteristic and expected complication should be considered [7,29].

There are few published comparative studies about technical results of different embolic material (particles, gel-foam, liquids, coils). Liquid embolics (absolute alcohol, N-butyl cyanoacrylate, ethylene vinyl alcohol) may provide more tumor necrosis than particules (e.g. PVA). This is to be advantageous where definite treatment is desired but carries an increased potential accidental non-target embolization and necrosis and thus require more experience [18,30,31,32].

In this study, significant numbers of bony tumors managed with TAE was in the appendicular skeleton (n=26, 79%) with metastases were the commonest pathological entity (n=17). In contrast, to others similar studies, spinal column was the most common site, especially for metastases [33,34]. However, results of Jha et al. [7], Shimohira et al. [24] and Suster et al. [35] agreed with ours. In the study of Geraets et al. [36], RCC metastases were the most frequent lesion on the contrary of our study where HCC metastases were the most fre-

quent (n=6, 35% of metastatic lesions) as demonstrated in Fig. (4) [36].

The findings of this study have to be seen in light of some limitations. The first is the short term follow-up of the patients. The long term monitoring of the clinical outcome of the procedure (by serial X-ray and CT) is crucial particularly if embolization is used as a curative method of treatment. The second is the relative small patients group. Larger number of patients is required for confirmation of the reliability and efficacy of the technique.

## References

- 1- GUPTA P. and GAMANAGATTI S.: Preoperative transarterial embolisation in bone tumors. *World J. Radiol.*, 4 (5): 186-92, 2012.
- 2- ABD EL-KHALEK, AHMED M., et al.: "Outcomes of embolization of bone tumors in the pelvic and shoulder girdles: Initial experience. *The Egyptian Journal of Radiology and Nuclear Medicine*, 49.1: 85-91, 2018.
- 3- MARCIEL, ANN MARIE, BRYAN L. VAN ZANDT and AARON J. BAXTER: Transcatheter arterial embolization for the palliation of painful bone lesions. *Techniques in Vascular and Interventional Radiology*, 14.3: 141-149, 2011.
- 4- MAVROGENIS, ANDREAS F., et al.: Palliative embolization for osteosarcoma. *European Journal of Orthopaedic Surgery & Traumatology*, 24.8: 1351-1356, 2014.
- 5- SIMPSON A.H., PORTER A., DAVIS A., GRIFFIN A., McLEOD R.S. and BELL R.S.: Cephalad sacral resection with a combined extended ilioinguinal and posterior approach. *J. Bone Joint Surg. Am.*, 77: 405-411, 1995.
- 6- CHU J.P., CHEN W., LI J.P., ZHUANG W.Q., HUANG Y.H., HUANG Z.M. and YANG J.Y.: Clinicopathologic features and results of transcatheter arterial chemoembolization for osteosarcoma. *Cardiovasc. Intervent Radiol.*, 30: 201-206, 2007.
- 7- JHA R., SHARMA R., RASTOGI S., KHAN S.A., JAYASWAL A. and GAMANAGATTI S.: Preoperative embolization of primary bone tumors: A case control study. *World Journal of Radiology*, 8 (4): 378, 2016.
- 8- MAVROGENIS, ANDREAS F., et al.: "Embolization of bone tumors". *Orthopedics*, 34.4: 303-310, 2011.
- 9- OWEN R.J.: Embolization of musculoskeletal bone tumors. *Semin Intervent Radiol.*, 27 (2): 111-23, 2010.
- 10- ROSSI G., MAVROGENIS A., RIMONDI E., CICCARESE F., TRANFAGLIA C., ANGELELLI B. and RUGGERI P.: Selective arterial embolisation for bone tumours: Experience of 454 cases. *La radiologia medica*, 116 (5): 793-808, 2011.
- 11- GUZMAN R., DUBACH-SCHWIZER S., HEINI P., LOVBLAD K.-O., KALBERMATTEN D., SCHROTH G. and REMONDA L.: Preoperative transarterial embolization of vertebral metastases. *European Spine Journal*, 14 (3): 263-268, 2005.
- 12- SUN S. and LANG E.V.: Bone metastases from renal cell carcinoma: Preoperative embolization. *Journal of Vascular and Interventional Radiology*, 9 (2): 263-269, 1998.

- 13- WIRBEL R.J., ROTH R., SCHULTE M., KRAMANN B. and MUTSCHLER W.: Preoperative embolization in spinal and pelvic metastases. *Journal of Orthopaedic Science*, 10 (3): 253-257, 2005.
- 14- CHU J.-P., CHEN W., LI J.-P., ZHUANG W.-Q., HUANG Y.-H., HUANG Z.-M. and YANG J.-Y.: Clinicopathologic features and results of transcatheter arterial chemoembolization for osteosarcoma. *Cardiovascular and interventional radiology*, 30 (2): 201-206, 2007.
- 15- BARTON P.P., WANECK R.E., KARNEL F.J., RITSCHL P., KRAMER J. and LECHNER G.L.: Embolization of bone metastases. *Journal of Vascular and Interventional Radiology*, 7 (1): 81-88, 1996.
- 16- GUZEY F.K., EMEL E., AYCAN A., BAS N.S., SEYITHANOGLU M.H., OZKAN N. and KARABULUT C.: Pediatric vertebral and spinal epidural tumors: A retrospective review of twelve cases. *Pediatric Neurosurgery*, 44 (1): 14-21, 2008.
- 17- BÖRÜBAN S., SANCAK T., YILDIZ Y. and SAGLIK Y.: Embolization of benign and malignant bone and soft tissue tumors of the extremities. *Diagnostic and Interventional Radiology*, 13 (3): 164, 2007.
- 18- YILDIRIM E., ERSÖZLÜ S., KIRBAS I., ÖZGÜR A.F., AKKAYA T. and KARADELI E.: Treatment of pelvic aneurysmal bone cysts in two children: Selective arterial embolization as an adjunct to curettage and bone grafting. *Diagnostic and Interventional Radiology*, 13 (1): 49, 2007.
- 19- ROSSI G., RIMONDI E., BARTALENA T., GERARDI A., ALBERGHINI M., STAALS E.L. and MERCURI M.: Selective arterial embolization of 36 aneurysmal bone cysts of the skeleton with N-2-butyl cyanoacrylate. *Skeletal Radiology*, 39 (2): 161, 2010.
- 20- LIN P.P., GUZEL V.B., MOURA M.F., WALLACE S., BENJAMIN R.S., WEBER K.L. and YASKO A.W.: Long-term follow-up of patients with giant cell tumor of the sacrum treated with selective arterial embolization. *Cancer*, 95 (6): 1317-1325, 2002.
- 21- HANSCH A., NEUMANN R., PFEIL A., MARINTCHEV I., PFLEIDERER S., GAJDA M. and KAISER W. A.: Embolization of an unusual metastatic site of hepatocellular carcinoma in the humerus. *World Journal of Gastroenterology: WJG*, 15 (18): 2280, 2009.
- 22- TAM, ALDA and AHRAR, KAMRAN: Palliative interventions for pain in cancer patients. In: *Seminars in Interventional Radiology*. Thieme Medical Publishers, 419, 2007.
- 23- VAN TOL K., HEW J., JAGER P., VERMEY A., DULLAART R. and LINKS T.: Embolization in combination with radioiodine therapy for bone metastases from differentiated thyroid carcinoma. *Clinical Endocrinology*, 52 (5): 653-659, 2000.
- 24- SHIMOHIRA M., NAGAI K., HASHIZUME T., NAKAGAWA M., OZAWA Y., SAKURAI K. and SHIBAMOTO Y.: Preoperative transarterial embolization using gelatin sponge for hypervascular bone and soft tissue tumors in the pelvis or extremities. *Actaradiologica*, 57 (4): 457-462, 2016.
- 25- SHIMOHIRA M., OGINO H., KAWAI T., KUSHITA A., WATANABE M., KAWAGUCHI T. and SHIBAMOTO Y.: Use of the triaxialmicrocatheter method in superselective transcatheter arterial chemoembolisation for hepatocellular carcinoma. *The British Journal of Radiology*, 84 (998): 184-187, 2011.
- 26- TROJANOWSKI P., JARGIEL L O T., TROJANOWSKA A. and KLATKA J.: Epistaxis in patients with hereditary hemorrhagic telangiectasia treated with selective arterial embolization. *Actaradiologica*, 52 (8): 846-849, 2011.
- 27- SHIMOHIRA M., OGINO H., KAWAI T., SAKURAI K., NAKAGAWA M. and SHIBAMOTO Y.: Clinical usefulness of the triaxial system in superselectivetranscatheter arterial chemoembolization for hepatocellular carcinoma. *Actaradiologica*, 53 (8): 857-861, 2012.
- 28- ZUO, MENGXUAN, et al.: Superselectivetranscatheter arterial embolization to control renal hemorrhage after partial nephrectomy for renal tumors: A report of 9 cases and a literature review. *Journal of Interventional Medicine*, 2.3: 134-138, 2019.
- 29- AHMAD, SAIMA: Endovascular embolization of highly vascular head and neck tumors. *Interdisciplinary Neurosurgery*, 19: 100386, 2020.
- 30- BASILE A., RAND T., LOMOSCHITZ F., TOMA C., LUPATTELLI T., KETTENBACH J. and LAMMER J.: Trisacryl gelatin microspheres versus polyvinyl alcohol particles in the preoperative embolization of bone neoplasms. *Cardiovascular and Interventional Radiology*, 27 (5): 495-502, 2004.
- 31- MUNK P.L. and LEGIEHN G.M.: Musculoskeletal interventional radiology: Applications to oncology. *Semin-Roentgenol*, 42 (3): 164-74, 2007.
- 32- LORD J., BRITTON H., SPAIN S.G., et al.: Advancements in the development on new liquid embolic agents for use in therapeutic embolisation. *J. Mater Chem. B.*, 8 (36): 8207-8218, 2020.
- 33- KOIKE Y., TAKIZAWA K., OGAWA Y., MUTO A., YOSHIMATSU M., YAGIHASHI K. and NAKAJIMA Y.: Transcatheter arterial chemoembolization (TACE) or embolization (TAE) for symptomatic bone metastases as a palliative treatment. *Cardiovasc. Intervent Radiol.*, 34: 793-801, 2011.
- 34- THIEX R., HARRIS M.B., SIDES C., BONO C.M. and FRERICHS K.U.: The role of preoperative transarterial embolization in spinal tumors. A large single-center experience. *Spine J.*, 13: 141-149, 2013.
- 35- SUSTER, DAVID, HUNG, YIN PUN and NIELSEN G. PETUR: Differential Diagnosis of Cartilaginous Lesions of Bone. *Archives of Pathology & Laboratory Medicine*, 144.1: 71-82, 2020.
- 36- GERAETS S.E.W., BOS P.K., van der STOK J.: Preoperative embolization in surgical treatment of long bone metastasis: A systematic literature review. *EFORT Open Rev.*, 5 (1): 17- 25, 2020.



## دور الانصمام عن طريق الشرايين فى علاج أورام العظام

هو طريقة واعدة أقل عدوانية سواء فى العلاج الأولى أو مساعد (TAE) الانصمام عبر الشرايين لإدارة الجراحية لأورام العظام. الهدف الرئيسى هو إحداث النخر وتقليل النزيف وبالتالي تسهيل الاستئصال. التخفيف من مظاهر الانضغاط لأورام العظام غير الصالحة للعمل هو مؤشر آخر على تشمل الأورام المتكررة التى يتم اختيارها لهذه الطريقة أورام الأوعية الدموية (خاصة (TAE)، وورم الخلايا العنقودية، (ABC) النقائل)، وكيسات عظام تمدد الأوعية الدموية وساركوما العظام.

الهدف من العمل: قد أجريت الدراسة الحالية للكشف عن فعالية الانصمام قبل الجراحة، والعلاج ب ه ا و تقيف الآلام من العظام الحميدة والخبيثة وغيرها من أورام الأنسجة الرخوة والعظام.

كشفت هذه الدراسة النتائج التالية:

فيما يتعلق بمجموعة الانصمام قبل العملية، فإن ٨٠٪ من الحالات (١٢ حالة) أظهرت نجاحاً تقنياً فى حين ٢٠٪ من الحالات المتبقية لم تظهر نجاحاً تقنياً (٣٪) وفيما يتعلق بالانصمام كعلاج نهائى، فقد أظهرت جميع الحالات (٦ حالات) نجاحاً تقنياً (١٠٠٪) بالنسبة إلى مجموعة الانصمام قبل أخذ العينات، أظهرت جميع الحالات (٦ حالات) نجاحاً تقنياً (١٠٠٪) بالنسبة إلى الانصمام كعلاج مسكن للآلام، فقد أظهرت جميع الحالات (٦ حالات) نجاحاً تقنياً (١٠٠٪) فيما يتعلق، بتقييم النجاح السريرى وفقاً للهدف الرئيسى للانصمام: أولاً الانصمام قبل الجراح ه بمقارنة بين (الأورام العظمية فى هذه المجموعة التى خضعت للانصمام قبل العملية) و (أورام عظمية أخرى مماثلة خضعت لعملية جراحية دون الانصمام قبل الجراحة) فيما يتعلق بمتوسط القطر، وفقدان الدم ووحدات نقل الدم اللازمة وجد إن متوسط قطر الورم لا يختلف اختلافاً كبيراً بين المجموعتين (ع=٠.٩٢٤) على الرغم من أن هناك انخفاضاً فى فقد الدم أثناء العمليات الجراحية بعد الانصمام ٨٤٠ مل مقابل ١٠٨٠ مل بدون إنصمام. لم يكن هذا الاختلاف ذا دلالة إحصائية بين المجموعتين (ع=٠.١٣٣) وبالتالي، عملية نقل الدم أثناء العملية لا تختلف بين المجموعات. فيما يتعلق بالحالات الست ه التى أجريت فى ه ا الانصمام كعلاج رئيسى، تراوح عدد جلسات الانصمام بين جلسة واحدة إلى ثلاث جلسات. تم استخدام تصوير الأوعية المقطعية للمتابعة. تراوحت فترة المتابعة بين ٣ و ١٢ شهراً . ومع ذلك، فقدت حالة واحدة أثناء المتابعة. بصرف النظر عن هذه الحالة، تم الكشف عن انخفاض الأوعية الدموية وزيادة الكثافة فى جميع الأورام بعد التدخل. علاوة على ذلك، تم الإبلاغ عن تحسن سريرى فى جميع الحالات. فيما يتعلق بتقلص حجم الورم فى جميع الحالات بصرف النظر عن حالة واحدة فقط.

فيما يتعلق بالمجموعة ج ، يهدف الإجراء إلى تقليل فقد الدم. المتابعة أثناء إجراء عملية الفحص عن طريق تقييم فقد الدم، أظهرت جميع الحالات عدم وجود فقدان كبير فى الدم وس ه ل ه فى الإجراءات. تم سماح لجميع المرضى بالخروج اليوم دون مضاعفات حدوث مضاعفات.

بالنسبة للحالات التى عولجت من أجل تخفيف الألم، تم إكتشاف نجاح سريرى فى جميع الحالات باستثناء حالتين فقدتا أثناء المتابعة، تم قياس النجاح السريرى من خلال تحسن الأعراض وحكم على ه اثنان متخصصون. وقد تم تقييم ه بشكل شخصى على أن ه لا تحسن، تحسن جزئى أو كامل.

فيما يتعلق بالمضاعفات، تم إجراء الإنصمام دون أى مضاعفات كبيرة فى حوالى ٢١ حالة (٦٣.٦٪) وحوالى ٧ حالات فقط كان هناك ألم بسيط مكان الحقن (٢١.٢٪) وعولجت بالمسكنات البسيطة.

المضاعفات النادرة الأخرى التى شوهدت فقط فى حالة واحدة لكل مضاعفات (٣٪) بما فى ذلك: طرف القسطرة المكسورة (copra) وتمزق فرع من الشريان المغزى وتجمع دموى فى موقع البثور مع احتشاء الدماغ القشرى.

فيما يتعلق بالنجاح التقنى فى الأورام الحميدة والخبيثة: تم الحصول على نجاح الفنى فى ٣٠ حالة (٩٠.٩٪) ولم يتم الحصول على ه فى ٣ حالات فقط (٩.١٪).

بخصوص المجموعات المرضية:

- ستة مرضى لديهم أورام عظمية حميدة، كلهم أظهروا نجاحاً تقنياً (١٠٠٪).
- كان لدى عشرة مرضى أورام عظام الأولية، وأظهرت جميع الحالات نجاحاً تقنياً (١٠٠٪).
- سبعة عشر مريضاً أصيبوا بأورام عظمية ثانوية، وأظهرت ١٤ حالة نجاحاً تقنياً (٨٢.٤٪).