

Surgical Management of Middle Cranial Fossa Meningiomas: Experience of 35 Cases

HESHAM A. ELSHITANY, M.D.; EHAB A. ABDELSALAM, M.D. and MOHAMED I. REFAAT, M.D.

The Department of Neurosurgery, Faculty of Medicine, Cairo University

Abstract

Background: Meningiomas are the most common tumors of the middle cranial fossa. Different surgical approaches have been described for excision of these tumors. Common approaches are the pterional, subtemporal, and the subfrontal approaches. These tumors are challenging in their management due to the variability of their surgical routes, and due to their close proximity to the cavernous sinus, carotids, optics, and other cranial nerves.

Aim of Study: Discussing our experience in surgical excision of middle cranial fossa meningiomas, discussing different surgical routes and incidence of morbidities and mortalities.

Patients and Methods: This is a retrospective observational study conducted on the data of 35 cases with middle cranial fossa meningiomas between January 2016 and July 2017. We included data of cases with outer (Pterional), middle and inner sphenoid wing (clinoidal), suprasellar, and cavernous sinus meningiomas. The Simpson grading system was utilized for assessment of the extent of tumor excisions; while the Karnofsky performance scale as well as the comparison between the pre and the postoperative clinical examination was utilized for assessment of the functional outcomes.

Results: 6 convexity meningiomas, 12 suprasellar meningiomas, and 17 middle and inner sphenoid wing meningiomas (clinoidal) including cavernous sinus extension were included in the study. Simpson grade 1 excision was achieved in 34%, grade 2 in 46%, grade 3 and 4 in 20%. Visual functions improved in 57% of cases. The most common complication was cranial nerve affection. We didn't detect any cases with tumor recurrences.

Conclusion: Middle cranial fossa meningiomas are challenging cases that are becoming possible for gross total surgical excision with minimal complications. Cranial nerves palsies are the most common morbidities specially the optic nerve and the cranial nerves in the region of the cavernous sinus. The pterional approach is considered to be the key approach for most types.

Key Words: *Visual outcome – Middle cranial fossa Meningioma – Pterional approach – Simpson grading – Karnofsky performance score.*

Correspondence to: Dr. Hesham A. Elshitany, The Department of Neurosurgery, Faculty of Medicine, Cairo University

Introduction

THE middle cranial fossa is a common site for growth of meningiomas. These tumors are usually excised via the frontotemporal (Pterional) approach and its variants, the subtemporal approach, or the subfrontal approach. The middle cranial fossa is formed by the squamous temporal and the greater wing of sphenoid bones; bounded anteriorly by the anterior clinoid process and the sphenoid wing; and bounded posteriorly by the dorsum sellae and the superior edge of the petrous bone [1,2].

Meningiomas are the most common tumors of the middle cranial fossa; other tumors could be trigeminal neuromas, chordomas and chondrosarcomas, gliomas, and metastatic tumors. Middle cranial fossa meningiomas are classified according to the site of their dural attachment into: Outer sphenoid wing, clinoidal, en plaque meningiomas of the sphenoid wing, cavernous sinus, and suprasellar meningiomas [3,4].

Sphenoid wing meningiomas can present with signs of increased intracranial pressure, motor weakness, seizures, or disturbed conscious level. Clinoidal and suprasellar meningiomas in addition can present with ocular manifestations and visual loss. Cavernous sinus meningiomas can present with ocular manifestations and facial hyposthesia [5].

Meningiomas are slowly growing benign tumors; the mainstay treatment of meningiomas is to excise it totally without morbidity or mortality in addition to removal of the affected dura and bone to reduce the incidence of tumor recurrences. However dura and bone removal can be established in majority of skull base meningiomas, and radiotherapy and radiosurgery could be used as adjuvants in treatment of these lesions [6].

Middle cranial fossa meningiomas are challenging in their management due to the variability of their surgical routes, and due to their close proximity to the cavernous sinus, carotids, optics, and other cranial nerves [7].

In this study, we are discussing our experience in surgical excision of middle cranial fossa meningiomas, discussing different surgical routes and incidence of morbidities and mortalities.

Patients and Methods

This study is a retrospective analysis of the data of patients who were operated upon for excision of middle cranial fossa meningiomas in the Neurosurgery Department of Cairo University Hospitals between January 2016 and July 2017. We included data of cases with outer (Pterional), middle and inner sphenoid wing (clinoidal), suprasellar, and cavernous sinus meningiomas. We excluded recurrent cases, cases with multiple meningiomas, as well as other middle fossa lesions other than meningiomas.

All cases had a full history taken, full neurological examination both pre and postoperatively, and full preoperative laboratory investigations. All patients had a CT and MRI brain with contrast done preoperatively; lesions were evaluated for site, size, shape, consistency, enhancement, calcification, and extension, the presence of associated edema, midline shift or hydrocephalus. Multi axial cuts were essential for planning, and inclusion. 24 hours postoperatively follow-up CT scans were done for the cases and MRIs within 3 days. Tumor recurrences were investigated by a late follow-up MRI after a period of 12 to 18 months.

Operative management: Cases included in this study were operated upon via one of the following surgical approaches; (i) Classic frontotemporal (Pterional), (ii) Frontoorbitozygomatic, (iii) Mini pterional, and (iv) Subfrontal approach. The different approaches were selected according to the anatomical region and origin, size and extension of the lesion. A complete neurological evaluation was performed for evaluation of consciousness, visual functions, cranial nerve affection, hypothalamic manifestations or other neurological deficits. Morbidity in the form CSF rhinorrhea, wound infection, neurological deficits, and endocrinopathies were recorded. Mortality causes and timing were also accounted for.

The Simpson grading system [8] was utilized for assessment of the extent of tumor excisions; while the Karnofsky performance scale (KPS) [9]

as well as the comparison between the pre and the postoperative clinical examination was utilized for assessment of the functional outcomes.

Results

Data of thirty five cases with middle cranial fossa meningiomas was analyzed in this study. **Incidence:** During the period of this study (18 months) 250 cases with cranial meningiomas were managed in our center. Middle fossa meningiomas represented 14% of all meningioma cases. **Age and Sex:** Patients in this study ranged from 22 to 65 years, with a mean age of 48.4 years (SD=10.7). A significant female predominance was noticed among the cases as 80% of the cases were females. **Clinical presentation:** Headache and manifestations of increased intracranial pressure were the main clinical presentation in 32 patients (91%). Cranial nerve affection (occulomotor, trigeminal and abducent) was found in 7 cases (20%). Fits was present in 8 patients (23%), visual affection in 15 patients (43%), a single case of disturbed conscious level and a single case with behavioral changes (2.8%) and 4 cases with proptosis (11.4%). Papilloedema was detected in 19 cases (54.3%) while optic atrophy was detected in 4 cases (11.4%).

Location of the tumors: We had 6 convexity meningiomas (pterional) (17%), 12 suprasellar meningiomas (34%), and 17 middle and inner sphenoid wing meningiomas (clinoidal) including cavernous sinus extension (49%). **Radiologic appearance:** Among all the tumors middle and inner sphenoid wing ones were the largest in size (mean diameter 5.7 ± 1.2 cm), followed by pterional ones (mean diameter 4.6 ± 0.9 cm), and suprasellar tumors came at last (mean diameter 3.2 ± 0.4 cm). Hyperostosis was seen in 3 cases (8.6%). Intratumoral calcification was found in 5 cases (14.3%), vascular encasement in 14 cases (40%), and cavernous sinus invasion in 6 cases (17%).

Surgical approach: The most common utilized approach was the pterional (frontotemporal) in 22 cases, followed by the subfrontal in 8 cases then and mini pterional (temporal) in 5 cases. Pterional approach was used in 17 cases of middle and inner sphenoid wing including cavernous sinus extension, single cases of temporal convexity and 4 cases of suprasellar meningiomas. The subfrontal approach was used in the other 8 suprasellar cases and the mini pterional in 5 cases of temporal convexity meningiomas.

Extent of tumor removal: According to Simpson grading system 12 cases (34%) were Grade 1 (total removal), 16 cases (46%) were Grade 2 (due to

inability to remove basal dura but all mass removed), 6 cases (17%) were Grade 3 (subtotal removal) and a single case (3%) aborted due to carotid injury. The most common Histopathologic type in this study was the transitional type in 29% of cases; followed by the fibroblastic type in 23%; the mixed type in 20%; the meningiothelial type in 14%; the psammomatus type in 11%; and then atypical meningioma in 3% of cases.

Post-operative complications: Cranial nerve affection was the most common complication observed. Trigeminal affection was observed in 5 patients (3 cases were temporary and 2 cases were permanent affection) Oculomotor affection was seen in 6 cases (2 cases were permanent and 4 cases were temporary and improved within 2 months post-operative). Vascular injury was observed in 4 cases (two cases of internal carotid artery injury in a clinoidal meningioma operated

by pterional approach and middle cerebral artery in a case of pterional meningioma, and frontopolar branch of anterior cerebral artery in a suprasellar meningioma. Wound infection seen in 2 cases, one case was operated upon by debridement and post-operative antibiotics and the second case was managed conservatively. Death was reported in 4 cases, two cases due to post-operative stroke; one case due to post-operative chest infection; and one case due to pulmonary embolism.

Clinical outcome: The visual functions improved in 8 cases (57%), no change was detected in 6 cases (43%), and couldn't be assessed in a single case due to the deteriorated conscious level. Follow-up and recurrences: The follow-up period in this study ranged from 8 to 16 months, mean duration was 12 months. None of the cases experienced any tumor recurrences in the short follow-up period.

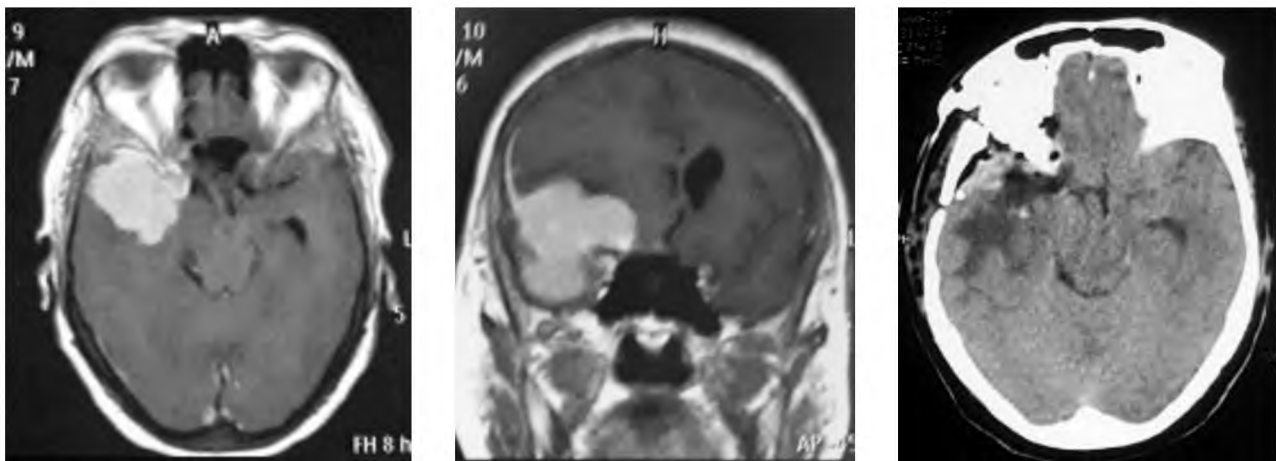


Fig. (1): Images of a 50 years old female, presenting with headache and blurriness of vision. Tumor was operated upon via the pterional approach. Post operative CT shows gross total excision.

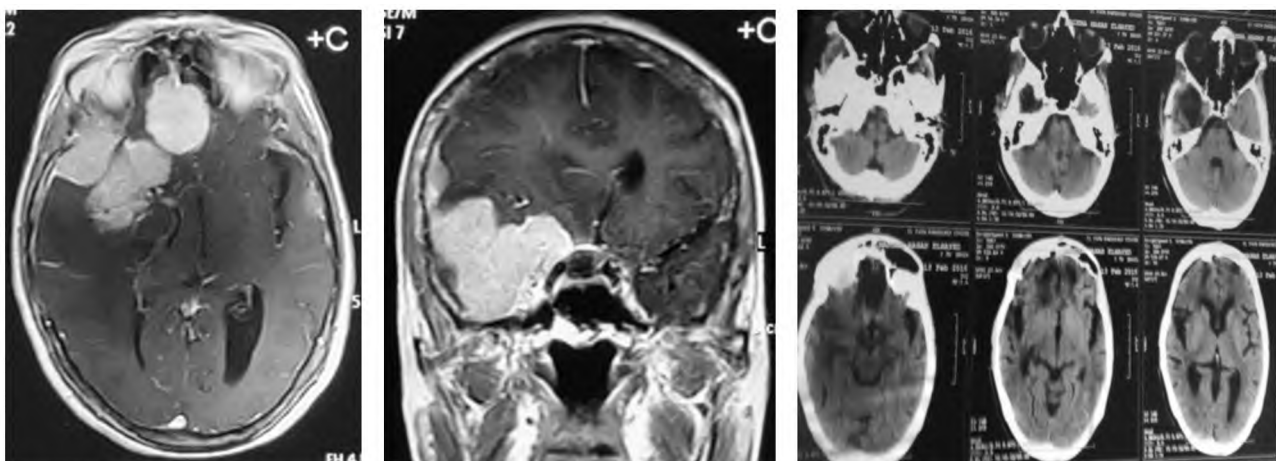


Fig. (2): Preoperative MRI and postoperative CT of a 58 years old male patient, presenting with headache and diminution of vision. Postoperative CT showing total tumor excision. The pterional approach was utilized for this case.

Discussion

Total surgical excision remains the only treatment for middle cranial fossa meningiomas; the main challenge for neurosurgeons is the radical excision while minimizing the postoperative morbidities and mortalities. Introduction of the surgical microscope with improvement of the microsurgical skills, in addition to the variability of surgical routes this challenge easy in most cases. We have used different surgical routes in this study in order to identify the best surgical approach for excising these tumors.

The mean age of the cases in our study was 48.4 years. 80% of our cases were females. These facts were consistent with several published studies [10,11]. Headache, visual affection, seizures, and cranial nerve affection were the most frequent clinical symptoms in our cases. This was also consistent with the presenting clinical manifestations of most published studies about these tumors. Visual affection was first in order in studies published by Attia M et al., and Balaşa A et al., [12,13].

Various surgical approaches were described for excision of middle cranial fossa meningiomas; each approach has its difficulties, complications, limitations, as well as its benefits. The tumor size, direction of growth, location, dural attachments are the factors that affect the choice of the surgical approach. In this study, we used one of the following surgical approaches; (i) Pterional approach in 22 cases, (ii) Subfrontal approach in 8 cases (iii) Mini pterional in 5 cases. We didn't find a significant difference between the probabilities of total tumor excisions between the three main approaches. A total tumor removal was achieved in 28 cases (80%). In the study by Attia M et al., fronto-orbital craniotomy was the most frequent approach where total resection was achieved in 30.4%, subtotal in 30.4% and partial resections were achieved in 39.2% of cases [12]. While Balaşa A et al. operated upon 18 patients of tuberculum sellae meningiomas using pterional craniotomy on the side with the most visual deficit with gross total removal 77.7% of cases and subtotal resection in 22.3% [13].

As regards the outcome and complications; 53% of cases with visual impairment showed postoperative improvements. Trigeminal affection was observed in 14% of cases, Oculomotor nerve palsy occurred in 17% of cases. Wound infection occurred in 5%. We had four cases (11%) of intraoperative vascular injury (two cases of internal carotid artery injury in a clinoidal meningioma operated by pterional approach and middle cerebral artery in a

case of pterional meningioma, and frontopolar branch of anterior cerebral artery in a suprasellar meningioma operated by subfrontal approach. Death was reported in 11% of cases, causes of death were post-operative infarction, chest infection, and pulmonary embolism.

The study published by Russell SM et al., showed visual affection improvement in 63% of cases, unchanged in 31%, and worsened in 6%. As regards the complications visual loss occurred in 6% of cases, other complications were oculomotor nerve palsy, brain edema, epidural hematoma, and temporary hemiparesis in 3% of cases for each [14]. In the study by Mariniello G et al., 56.7% of patients experienced visual deficit improvement, 40% remained unchanged, and 3.3% worsened. Higher rates of visual improvement were found in cases operated upon by extended skull base approach, rather than pterional approach [15].

While in the series of Attia M. et al., the most common postoperative complication was temporary pseudomeningocele in 34.8% of cases. Other complications were cranial nerve deficits, hemiparesis, intracerebral hemorrhage, and hydrocephalus in 26.1%, 13%, 4.5%, and 9.1% of cases respectively. Vision improved after surgery in 66.7% of cases, stationary in 22.2%, and visual deterioration in 11.1% of cases [12].

Conclusion:

Middle cranial fossa meningiomas are challenging cases that are becoming possible for gross total surgical excision with minimal complications. Cranial nerves palsies are the most common morbidities pre and post-operative, specially the optic nerve and the cranial nerves in the region of the cavernous sinus. The pterional approach is considered to be the key approach for most types.

Proper knowledge of the microsurgical anatomy of this region and applying different surgical maneuvers as wide exposure, proper brain relaxation techniques as CSF draining (through cisterns or through lumbar drain) and applying microsurgical techniques helps so much in achieving radical tumor removals and improving the outcome.

References

- 1- DELFINI R.: Management of Tumors of Middle Fossa. In: Sindou M. (eds) Practical Handbook of Neurosurgery. Springer, Vienna, pp. 599-613, 2009.
- 2- AL-MEFTY O.: Clinoidal meningiomas. J. Neurosurg., 73: 840-849, 1990.
- 3- CHAMPAGNE P.O., LEMOINE E. and BOJANOWSKI M.W.: Surgical management of giant sphenoid wing

- meningiomas encasing major cerebral arteries. Neurosurg. Focus, 44 (4): E12, 2018.
- 4- ABDEL-AZIZ K.M., FROELICH S.C., DAGNEW E., JEAN W., BRENNEMAN J.C., ZUCCARELLO M., et al.: Large sphenoid wing meningiomas involving the cavernous sinus: Conservative surgical strategies for better functional outcomes. Neurosurgery, 54: 1375-1384, 2004.
 - 5- FORSTER M.T., DANESHVAR K., SENFT C., SEIFERT V. and MARQUARDT G.: Sphenoorbital meningiomas: Surgical management and outcome. Neurol. Res., 36: 695-700, 2014.
 - 6- IVAN M.E., CHENG J.S., KAUR G., SUGHRUE M.E., CLARK A., KANE A.J., et al.: Association of morbidity with extent of resection and cavernous sinus invasion in sphenoid wing meningiomas. J. Neurol. Surg. B Skull Base, 73: 76-83, 2012.
 - 7- NAKAMURA M., ROSER F., JACOBS C., VORKAPIC P. and SAMII M.: Medial sphenoid wing meningiomas: Clinical outcome and recurrence rate. Neurosurgery, 58: 626-639, 2006.
 - 8- SIMPSON D.: The recurrence of intracranial meningiomas after surgical treatment. J. Neurol. Neurosurg. Psychiatry, 20: 22-39, 1957.
 - 9- KARNOFSKY D.A. and BURCHENAL J.H.: The clinical evaluation of chemotherapeutic agents in cancer. In MacLeod C.M. (Ed), Evaluation of Chemotherapeutic agents. Columbia Univ Press, Page 196, 1949.
 - 10- OJEMANN R.: Congress of neurological surgeons honored guest presentation originally published Clinical Neurosurgery, Volume 40, Chapter 17, 321-383, 1992.
 - 11-SEKER A., MARTINS C. and RHOTON A.L.: Meningeal anatomy In Meningiomas: A Comprehensive Text. Saunders, an imprint of Elsevier Inc., pp. 19-44, 2010.
 - 12- ATTIA M, UMANSKY F., PALDOR I., et al.: Giant anterior clinoidal meningiomas: Surgical technique and outcomes. J. Neurosurg., 117: 654-665, 2012.
 - 13- BALASA A., CHINEZU R. and GHERASIM D.N.: Surgical management of tuberculum sellae and planum sphenoidale meningiomas, Romanian Neurosurgery XX, 1: 92-99, 2013.
 - 14-RUSSELL S.M. and BENJAMIN V.: Medial sphenoid ridge meningiomas: Classification, microsurgical anatomy, operative nuances, and long-term surgical outcome in 35 consecutive patients. Neurosurgery, 62 (1): 265-277, 2008.
 - 15- MARINIELLO G., De DIVITIIS O. and MAIURI F.: Classical pterional compared to the extended skull base approach for the removal of clinoidal meningiomas. J. Clin. Neurosci., 19 (2): 1646-50, 2012.

الطرق الجراحية لعلاج الأورام السحائية الواقعية في الحفرة القحفية المتوسطة: خبرة ٣٥ حالة

الأورام السحائية هي الأورام الأكثر شيوعاً في الحفرة القحفية المتوسطة. قد وصفت أساليب جراحية مختلفة لاستئصال هذه الأورام. هذه الأورام صعبة في علاجها بسبب تباين طرقها الجراحية، ونظراً لقربها من الجيب الكهفي، العصب البصري، الشريان السباتي، والأعصاب القحفية الأخرى.

تم إجراء هذه الدراسة لمناقشة تجربتنا في علاج هذه الأورام ومناقشة الطرق الجراحية المختلفة ووقوع الأمراض والوفيات.

هذه دراسة رصدية استعادية أجريت على بيانات ٣٥ حالة مصابة بأورام سحائية في الحفرة القحفية المتوسطة ما بين يناير ٢٠١٦ و يوليو ٢٠١٧. تم استخدام نظام سيمبسون لتصنيف نسب استئصال الورم وفي حين تم استخدام مقياس أداء كارنوفسكي، وكذلك المقارنة بين الفحص السريري ما قبل الجراحة وما بعد الجراحة لتقييم النتائج الوظيفية. تحسنت الوظائف البصرية في ٥٧٪ من الحالات. المضاعفات الأكثر شيوعاً كانت إصابات الأعصاب القحفية. لم نواجه أي حالات مع ارتجاع الأورام.

الأورام السحائية في الحفرة القحفية المتوسطة من الحالات الصعبة التي أصبحت ممكنة للاستئصال الجراحي الكلي مع الحد الأدنى من المضاعفات. شلل الأعصاب القحفية هي أكثر المضاعفات الجراحية شيوعاً، خصوصاً العصب البصري والأعصاب القحفية في منطقة الجيب الكهفي. ويعتبر النهج التريوني هو النهج الرئيسي لمعظم الأنواع.