

Intracranial hemorrhage with COVID 19 patient; case report

Abelmoneim Elhadidy^{1*}, Mohammad Elmoghazy², Emad Balah¹, Nasser Mousa³

¹Damietta Fever and Gastroenterology hospital, Egypt.

²Gastroetetrology and Hepatology dept., Damietta Cardiology and gastroenterology center, Egypt.

³Tropical Medicine dept., Mansoura Univ., Egypt.

*abdelmoneimelhadidy@yahoo.com

Received: 19-10-2020

Accepted: 14-11-2020

Abstract:

Coronavirus disease is caused by the severe acute respiratory syndrome coronavirus 2 (SARS-CoV-2). Although the majority of patients with COVID-19 typically have characteristic respiratory presentations, a large number of patients were presented with multi-system affection included central nervous system. The neurotropic features of SARS-CoV-2 account for the damaging effects of this virus on the central nervous system. This was initially evidenced by reports from Beijing Ditan Hospital of the first case of viral encephalitis due to COVID 19. A growing number of case reports and series have been published describing the clinical characteristics of patients with ischemic strokes and COVID-19. These emerging reports, including large vessel occlusion, brain infarcts, venous thromboembolism and raised inflammatory markers. We reported a case of an intracranial hemorrhage (ICH) in our hospital in diabetic hypertensive patients infected with confirmed COVID 19.

Keywords: Coronavirus disease, SARS-CoV-2, bilateral ground glass opacity's, intracranial hemorrhage.

Case scenario

A 59-year-old man had a good-controlled diabetes mellitus and hypertension (Blood pressure was 140/75 mm Hg) was admitted to hospital with disturbed consciousness and motor weakness with no signs of increased intracranial tension or meningitis. During hospitalization, the body temperature was 40 °C, CT chest revealed bilateral ground glass opacity's consistent with COVID 19, fig. (1). The patient was investigated by PCR for COVID19, which was positive. CT brain revealed interventricular hemorrhage, fig. (2). Laboratory finding were, CRP 50 mg/dl, D-dimer 0.44 mg/ml, serum albumin 2.8 gm/dl, serum bilirubin 1.8 mg/dl, ALT 81 IU/l, AST 119 IU/l, serum creatinine 0.5 mg/dl, platelets $119 \times 10^9/l$, Hg 12 gm/dl, WBC $7.3 \times 10^9/l$, lymphocyte 12.4 %, ESR 88 in 1st hour, INR 1.5. The patient was managed as case of COVID19 according to our hospital protocol with Tinam, clexan, steroid, azithromycin, chloroquine, zinc and paracetamol plus anti-hemorrhagic measures as treatment of stroke. The patient improved after 7 days and dis-

charged from the hospital by right sided hemiplegia under outpatient treatment, physiotherapy and for follow up. Seven days later, the patients were readmitted to the hospital due to recurrent fever and dyspnea. The oxygen saturation deteriorated to 60-80% and respiratory rate 33/min. The patient condition deteriorated and transferred to another hospital ICU to the possibility for intubation and to receive tocilizumab (actimra) humanized mAb targeting interleukin-6 receptor, to control the possibility of cytokine release syndrome observed in, he received two doses but the condition deteriorated then patient intubated and mechanically ventilated for four days and lastly the patient died.

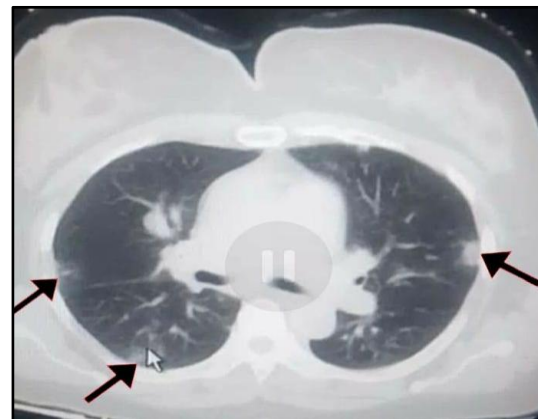


Figure 1. Spiral lung CT scans revealed ground-glass opacity in the lung.

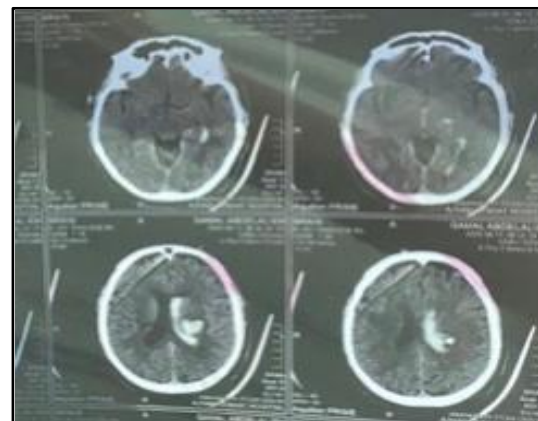


Figure 2. Brain CT scan revealed intracerebral haemorrhage.



Discussion

SARS-CoV-2 has been reported to gain cellular entry via the surface angiotensin converting enzyme 2 (ACE2) receptor, which is known to be expressed in the vascular endothelium¹. The neurotropic features of SARS-CoV-2 account for the injurious effects of this virus on the central nervous system. This was initially evidenced by reports from Beijing Ditan Hospital of the first case of viral encephalitis due to a new coronavirus, subsequently confirming the causative pathogen to be SARS-CoV-2 via genome sequencing of cerebrospinal fluid². Further support was provided by another published article also regarding cases of acute viral necrotizing encephalitis related to SARS-CoV-2 infection. The patient verified hemorrhagic rim-enhancing lesions within the bilateral thalami, medial temporal lobes, and subinsular regions on brain MRI. Non contrast CT images demonstrated symmetric hypoattenuation within the bilateral medial thalami with a normal CT angiogram and CT venogram³. Neurotropism of SARS-CoV-2 in the current COVID-19 pandemic is suggested to be attributed to its furin-like cleavage site. Furin and furin-like proteases resulted in cleavage of viral S protein, thereby influencing invasion and virulence properties as well as determining host specificity and tissue tropism of SARS-CoV and MERS-CoV⁴. However, recently some suggest the possible mechanisms of ICH in COVID-19 deriving from endothelial injury⁵. It has been suggested that COVID-19 infection may be complicated by vascular endothelial dysfunction and coagulopathy⁶. Affection of the endothelium, leads to vasodilation, anti-aggregation abilities and fibrinolysis may lead to a systemic state of endothelial dysfunction⁷. There is mounting evidence that COVID-19 infection leads to various types of thrombotic events^{8,9}. Ultimately, disruption of tight junction protein complexes would occur, leading to blood brain barrier compromise and ICH¹⁰. ACE II is highly expressed in lung alveolar type 2 cells and epithelial cells of gastrointestinal system¹¹. Angiotensin II receptors are also expressed in circum-ventricular organs and in cerebrovascular endothelial cells, which play a role in the regulation of multiple functions in the brain, including vascular auto regulation and cerebral blood flow¹². Thus, it is reasonable to hypothesize that brain ACE II could be involved in COVID-19 infection and its dysfunction, leading to disruption of auto regulation as well as blood pressure spikes due to arterial wall rupture¹³. Also, some suggest that, disruption of the renin-angiotensin system (RAS) may also play a role in COVID-19-mediated ICH. The RAS has distinct regulatory pathways in both the periphery

and the brain, which could be impacted by SARS-CoV-2 via down regulation of endothelial ACE2 receptors, leading to cerebral blood flow dysautoregulation¹¹.

Conclusion

Although it remains to be confirmed whether there is a causal relationship between ICH and COVID-19 or whether it is a coincidental event with ICH, this case report motives clinicians to have a low threshold for suspicion and investigation in such patients, particularly those with diabetes mellitus and hypertension. Further research is required to determine the incidence and characteristics of ICH and COVID-19.

References

1. Sahin A, Erdogan A, Agaoglu P, et al. 2019 novel coronavirus (COVID-19) outbreak: A review of the current literature. **EJMO** 2020; 4: 1-7.
2. Xiang P, Xu X, Gao L, et al. First case of 2019 novel coronavirus disease with Encephalitis. **ChinaXiv**. 2020; T202003:00015.
3. Ye M, Ren Y, Lv T. Encephalitis as a clinical manifestation of COVID-19. **Brain Behav Immun**. 2020; 88: 945-946
4. Millet J, Whittaker G. Host cell proteases: Critical determinants of coronavirus tropism and pathogenesis. **Virus Res**. 2015; 202: 120-134.
5. Bengler M, Williams O, Siddiqui J, et al. Intracerebral haemorrhage and COVID-19: Clinical characteristics from a case series. **Brain Behav Immun**. 2020; 88: 940-944.
6. Zhou F, Yu T, Du R. Clinical course and risk factors for mortality of adult in patients with COVID-19 in Wuhan, China: A retrospective cohort study. **Lancet**. 2020; 395 (10229): 1054-1062.
7. Avogaro A, Albiero M, Menegazzo L, et al. Endothelial dysfunction in diabetes: The role of reparatory mechanisms. **Diabetes Care**. 2011; 34 (Suppl 2): S285- S290.
8. Bikdeli B, Madhavan V, Jimenez D, et al. COVID-19 and thrombotic or thromboembolic Disease: Implications for prevention, antithrombotic therapy, and Follow-up. **J. Am. Coll Cardiol**. 2020; 17: 27284.
9. Klok A, Kruip M, van der Meer N, et al. Confirmation of the high cumulative incidence of thrombotic complications in critically ill ICU patients with COVID-19: An updated analysis. **Thromb Res**. 2020; 191: 148-150.



10. Ronaldson P, Davis T. Mechanisms of endothelial injury and blood-brain barrier dysfunction in stroke. In primer on cerebrovascular diseases: 2nd Ed. Elsevier Inc. 2017. p. 220-226
11. Zhang H, Penninger M, Li Y, et al. Angiotensin-converting enzyme 2 (ACE2) as a SARS-CoV-2 receptor: Molecular mechanisms and potential therapeutic target. **Intensive Care Med.** 2020; 46 (4): 586-590.
- Divani A, Andalib S, Di Napoli M, et al. Coronavirus disease 2019 and stroke: Clinical manifestations and pathophysiological insights. **J Stroke Cerebrovasc Dis.** 2020; 29 (8): 104941.
12. Sharifi-Razavi A, Karimi N, Rouhani N. COVID-19 and intracerebral haemorrhage: Causative or coincidental? **New Microbes New Infect.** 2020; 35: 100669-100669.