

## MR Imaging Features of Chemotherapeutic Neurotoxicity in Cancer Patient

Salwa Taha Ahmed Ismail, Mohammad Sobhi Hassan, Ahmed Mohamed Bassiouny,  
Ayda Aly Youssef, Amr Mostafa Elkatatny, Dina Mahmoud Al Najjar

Department of Radiology, Faculty of Medicine, Ain Shams University, Cairo, Egypt  
Corresponding author: Dina Alnajjar, email: dm.egyptian@gmail.com

### ABSTRACT

**Aim of the work:** this study aimed to display the role of imaging by MRI in early detection and accurate diagnosis of chemotherapeutic neurotoxicity in neoplastic patients under chemotherapy.

**Patients and methods:** this study included 50 cases of different cancers with CNS radiological manifestations. It included any cancer patient, regarding the age, sex and primary cancer and received any type of chemotherapy. The entire patients were evaluated by CEMRI technique, MR venography as well as diffusion weighted MRI.

**Results:** our result showed different forms of neurotoxicity that occur in cancer patients due to the effect of chemotherapy such as posterior reversible encephalopathy syndrome and cerebral venous sinus thrombosis.

**Conclusion:** all survivors of cancer patients should have lifelong follow-up, preferably with magnetic resonance imaging which provided greater anatomic detail and early detection of any abnormality.

**Keywords:** PRES, CVST, MTX neurotoxicity, MRI & Diffusion MRI.

### INTRODUCTION

The breadth of chemotherapeutic agents is vast and adverse effects are unfortunately common. Distinguishing disease pathology from the adverse chemotherapeutic effects remains challenging <sup>(1)</sup>.

Chemotherapeutic agents cause both central and peripheral neurotoxicity. Central neurotoxic side effects of chemotherapy are the main reason to limit the dose of chemotherapy in many patients, despite the protective role of the blood-brain barrier (BBB) <sup>(2)</sup>.

Cancer patients may experience a wide range of neurological symptoms due to chemotherapy. The development of these harmful effects may have an acute, sub-acute, or delayed course, and may be reversible or (partially) irreversible <sup>(2)</sup>. Seizures, focal symptoms like aphasia or hemiparesis, and cortical blindness may occur as isolated symptoms <sup>(3)</sup>.

Magnetic resonance imaging (MRI) is a sensitive modality for evaluation of leukoencephalopathy <sup>(4)</sup>.

One of the most common MR finding features of neurotoxicity post chemotherapy is PRES which is a posterior reversible encephalopathy syndrome in which there is vasogenic edema within the occipital and parietal regions (~95% of cases), The edema is usually symmetrical <sup>(5)</sup>.

Methotrexate is often implicated as the major cause of acute neurotoxicity, in which there is

damage to the CNS white matter, termed leukoencephalopathy (LEP). On MR imaging, the hallmark of LEP is T2 hyper-intensities typically located in the periventricular white matter, particularly in the centrum semiovale <sup>(6)</sup>.

Cerebral venous sinus thrombosis (CVST) is a feature of Asparaginase-related thrombosis. MRV is now the method of choice for diagnosis of CVST <sup>(1)</sup>.

### PATIENTS AND METHODS

This prospective study was carried out on 50 patients 38 males and 12 females, their age ranged from 2 to 61 years. Patients were selected from Radiology Department in National Cancer Institute (NCI) - Cairo University in the period from December 2015 to April 2017. They were presented with neurological complains such as headache, nausea, emesis, lethargy, blurred vision, aphasia, hemiparesis, paresis or convulsions.

### MRI Technique

All patients were subjected to the following:

#### 1. Conventional contrast enhanced MRI (CEMRI):

1.5 Tesla units were used (Achieva, Philips Medical System, Best and The Nether Lands).

The used protocol basically was consisted of:

- Axial T1WI (450 / 12 ms) TR/TE spin echo.
- Axial T2WI (4540 / 96 ms) TR/TE spin echo.
- Axial FALIR (9000 / 116/ 2500 ms)

TR/TE/TI).

- Sagittal T1WI (430 / 10 ms) TR/TE spin echo.  
5 mm section thickness were done and 256 x 256 matrix size.

After intravenous administration of Gadolinium- DTPA (0.3 mg/kg), contrast enhanced T1WI in axial, sagittal and coronal planes were obtained.

**2. MR Venography is added according to the clinical suspicion:**

Time-of-flight MR venography was performed in 16 patients with cerebral venous sinus thrombosis. The parameters used with this technique were as follows: 30/9/1; field of view, 22–25 cm; matrix, 219X250; flip angle, 50°; section thickness, 3 mm; section slab thickness, 3–7.5 cm.

**3. MR Diffusion Imaging**

Axial DW imaging was performed by using a single-shot T2-weighted echo planar spin-echo sequence with the following parameters: 1600/107; diffusion gradient encoding in three (x, y, z) orthogonal directions; *b* values of 500 and 1000 sec/mm<sup>2</sup>; field of view, 24 - 24 cm; matrix size, 128 - 128; section thickness, 7.5 mm; section gap, 0 mm; and one signal acquired. At each *b* value, x, y, and z single-direction DW images and a baseline image (*b* = 0 sec/ mm<sup>2</sup>) were acquired; combined [(x + y + z)/3] DW imaging was calculated and performed automatically by the MR instrument.

10 sections with 50 images were obtained at each *b* value in 13 seconds (10 images of combined [(x + y + z)/3] DW imaging, 10 images of the baseline image, and 10 images each of the x-, y-, and z-direction DW images). Therefore, each DW imaging study yielded a total of 200 images.

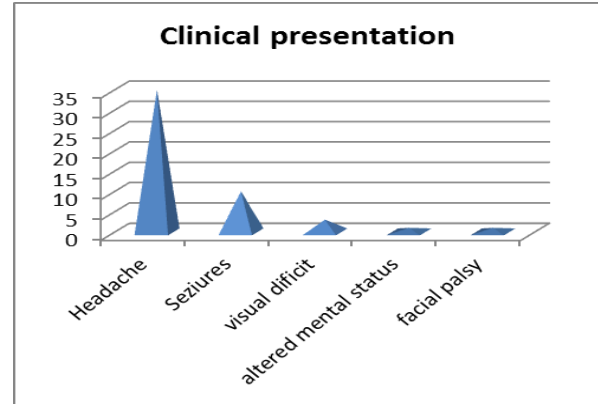
All DW imaging data were transferred to a computer workstation for determination of the signal intensity and ADC. Each image used for the creation of the ADC maps was obtained with one signal acquired.

The study was approved by the Ethics Board of Ain Shams University.

**RESULTS**

The hematological cancers were the commonest primary cancers among the patients in our study representing 90% of the cases and the most common cancer among them was ALL (54%) (N= 27)

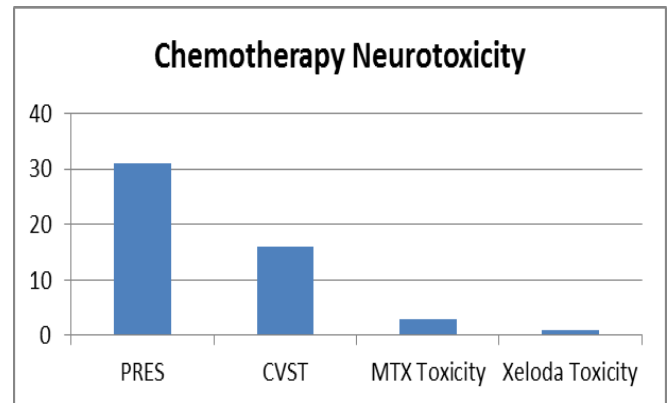
In our study, the most common presenting symptom was severe persistent headache that present in (35/50) (70%), followed by seizures, that present in (10/50)(20%) of patients. The other associated symptoms were visual deficit (3/50) (6%), altered mental status and facial palsy.



**Fig 1: column chart shows clinical presentation of the patients**

**Types of chemotherapeutic neurotoxicity:**

PRES (31/50) was the most common CNS abnormality found, followed by sinus thrombosis (16/50), 2 had methotrexate toxicity and 1 had xeloda toxicity.



**Fig. 2: column chart showing chemotherapeutic neurotoxicity**

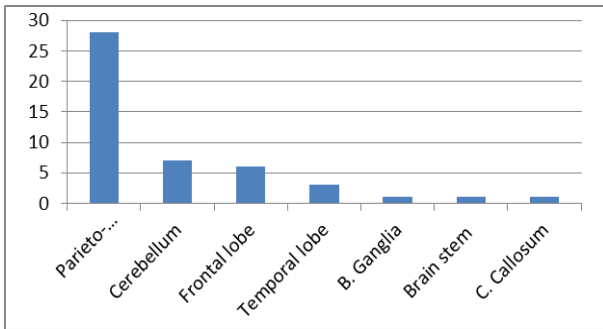


**Posterior Reversible Encephalopathy Syndrome**

In our study, the most commonly involved locations were the parieto-occipital lobes (28/31) (90.3%). These locations are considered the typical distribution of PRES.

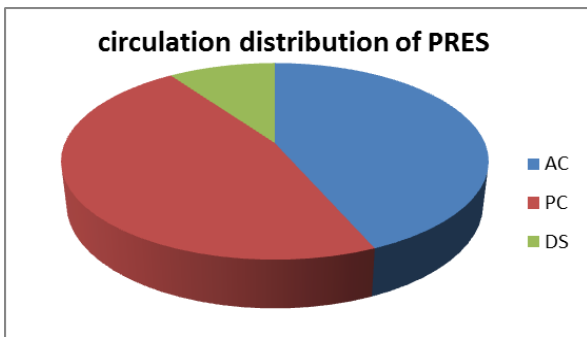
The less commonly affected regions were the cerebellum (7/31) 22.58%, frontal lobe (6/31) 19.35%, temporal lobe (3/31) 9.6%, basal ganglia (1/31) 3.2%, brain stem (1/31) 3.2% and corpus

callosum (1/31) 3.2%. These regions are considered the atypical distribution of PRES.



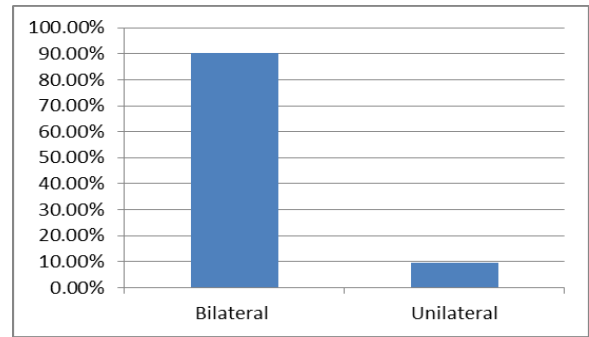
**Fig 3: column chart showing location distribution of PRES**

According to the division of the brain regions, it is divided into three parts anterior circulation (AC), posterior circulation (PC) and deep structure (DS). AC includes frontal lobe, temporal lobe and parietal lobe; PC includes occipital lobe, cerebellum and brain stem and DS includes basal ganglia, deep white matter and corpus callosum, AC regions were involved in 87.09% of cases and PC regions were involved in 93.5%, as well as DS in 19.35%.



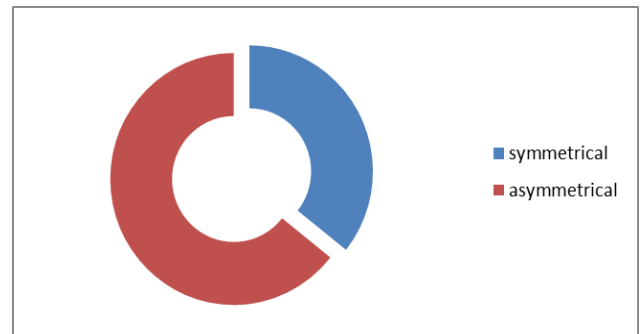
**Fig 4: Pie chart showing circulation distribution of PRES.**

Lesions were seen bilateral in 90.3% (28/31) and unilateral in 9.6% (3/31) of the patients (Fig.5).



**Fig. 5: the side of brain affected by PRES lesion**

In our study 28 patients showed bilateral distribution of the Lesion classified as 64.28% (18) were asymmetrical and 35.7% (10) were symmetrical as seen in fig.6.

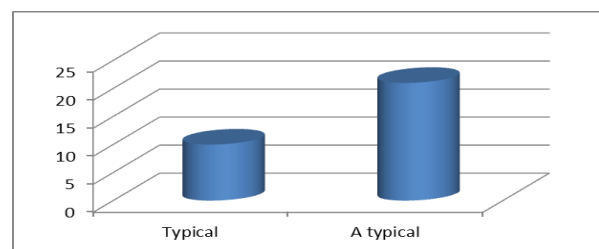


**Fig. 6: Doughnut chart shows symmetry of PRES lesions**

**Typical versus atypical MRI findings:**

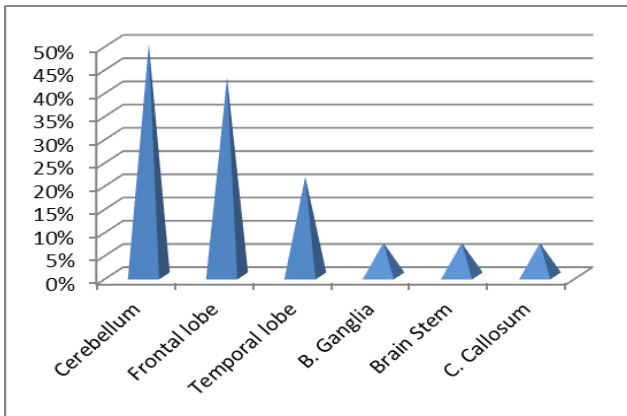
We considered the PRES to be typical if the MRI shows symmetrical distribution of vasogenic edema, predominantly within the parieto-occipital regions, with no evidence of enhancement, diffusion restriction or hemorrhage. It represented 32.25% (10/31) in our study.

The atypical PRES represents 67.74% (21/31) in our study, being classified as atypical location and atypical presentation.



**Fig.7: column chart showing typical versus atypical PRES**

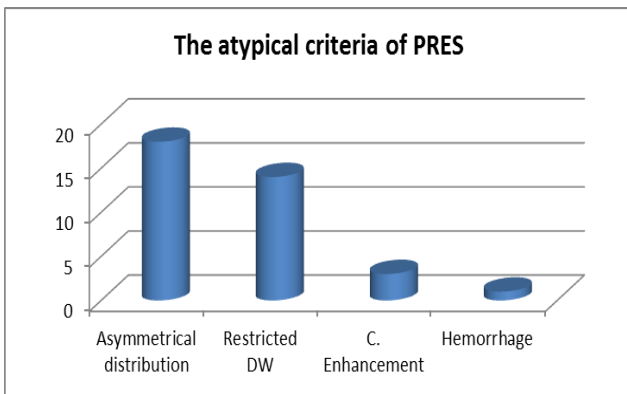
The atypical location was considered if there is involvement of any area of the brain unless the parieto- occipital regions. It represented 66.6% (14/21) in our study as described in **fig. 8**.



**Fig. 8: column chart shows atypical distribution of PRES**

The atypical presentation was considered if there was asymmetrical distribution of the lesion, contrast enhancement, restricted diffusion or hemorrhage.

The most common atypical criteria of PRES presented in our study was asymmetrical distribution of the lesion which was found in 85.7% (18/21), followed by diffusion restriction which was found in 66.6% (14/21) cases, then contrast enhancement which was depicted in 14.2% (3/21) cases, finally is the presence of hemorrhage which appeared in just one case of our study (4.7%).

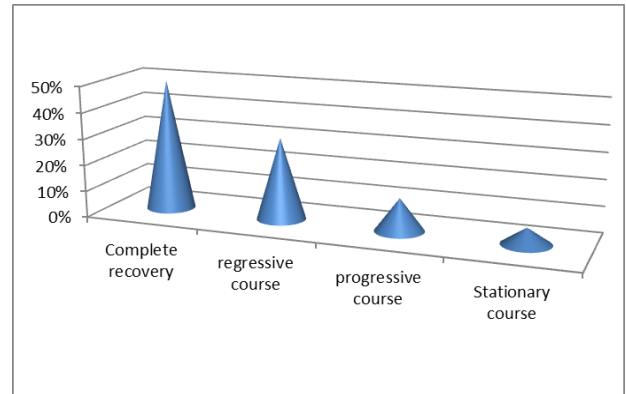


**Fig. 9: column chart showing the atypical criteria of PRES**

**Follow up MRI**

51.6% (16/31) of patients followed up MRI and 48.38% (15/31) of them didn't. As

demonstrated in (**Fig.10**), out of the 16 patients who underwent follow up MRI 50% (N=8) of them showed complete resolution and 31.25% (N=5) patients showed regressive course of the disease, 2 cases (12.5%) shows progressive course and just one case (6.25%) showed stationary course.



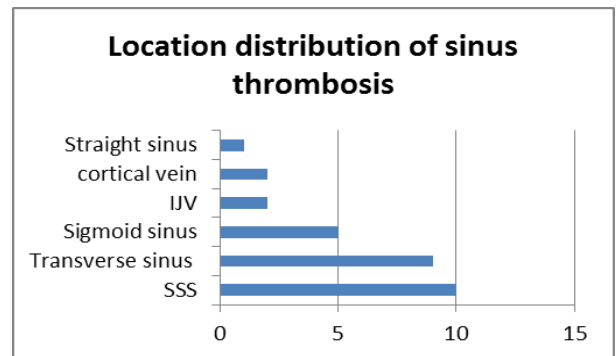
**Fig. 10: result of follow up MRI**

**Cerebral Venous Sinus Thrombosis:**

There were 16 patients with cerebral sinus thrombosis in our study, are classified as: 87.5% pediatric (<18 year old) and 12.5% adult (>18 year), 75% males and 25% females

**Location distribution of Sinus Thrombosis**

The most commonly involved location was superior sagittal sinus 62.5% (10/16) followed by transverse sinus 56.62% (9/16), sigmoid sinus 31.25% (5/16), IJV as well as the cortical veins (12.5% each) (2/16) and straight sinus 6.25% (1/16).



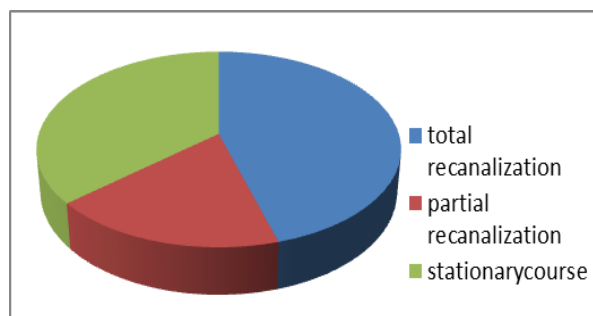
**Fig 11: bar chart showing location distribution of cerebral venous thrombosis**

### Parenchymal changes associated with sinus thrombosis:

8/16 patients developed infarction; 6 of them had hemorrhagic venous infarction associated with cerebral sinus thrombosis.

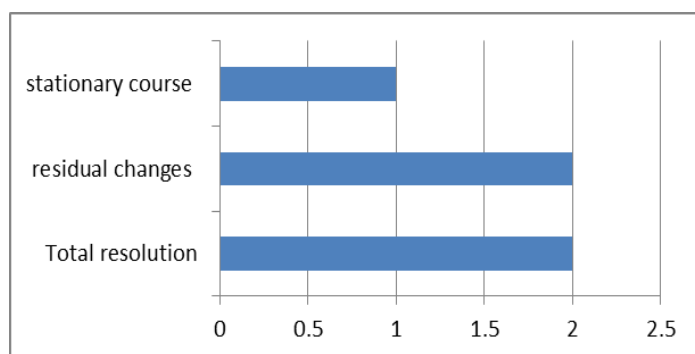
### Follow up MRI

11 out of 16 patients underwent follow up MRI, (5/11) 45.45% showed total recanalization of the venous thrombus, (2/11) 18.18% showed partial recanalization, yet (4/11) 36.36% appeared stationary with no definite changes.



**Fig 12: Pie chart shows follow up of venous thrombosis**

Regarding the 8/16 cases that show parenchymal changes, only 5 cases underwent follow up MRI, (2/5) 40% showed total resolution of the venous infarction, (2/5) 40% showed residual parenchymal changes, yet only one case (1/5) 20% appeared stationary with no significant changes.



**Fig. 13: bar chart shows follow up of parenchymal changes associated with venous infarction**

### ❖ Methotrexate neurotoxicity

Two cases of MTX neurotoxicity were included in our study; MRI showed bilateral symmetrical areas of restricted diffusion

at the centrum semi-ovale, these areas were hardly appreciated at the other pulse sequences.

### Xeloda Toxicity

Our study included just one case of xeloda toxicity in which the MRI showed increased signal on T2 & FLAIR as well as restricted diffusion. It typically involved the periventricular regions, the corpus callosum as well as the posterior parietal and anterior thalamic regions.

### DISCUSSION

This study showed that CNS complications were significantly higher with hematological malignancy (either leukemia or lymphoma) yet there was no significant difference according to gender of patients.

The most common complication found in our study was PRES (62%) followed by cerebral sinus thrombosis (32%). PRES and cerebral sinus thrombosis typically presented with signs and symptoms of increased intracranial pressure, including headache, nausea and vomiting, irritability, lethargy, seizures, disorientation and speech impairment.

The most common presenting symptom that appeared in our study was headache followed by seizures. This is in agreement with results of **Alvis et al.**<sup>(7)</sup> who reported that headache is the most common presenting symptom. It was present in almost 90% of patients.

In our study, the most commonly involved typical locations were the parieto-occipital lobes (28/31, 90.3%). However the most commonly affected atypical location is the cerebellum (7/31, 22.58%), followed by frontal lobe (6/31, 19.35%), then temporal lobe (3/31, 9.6%). Basal ganglia, brain stem and corpus callosum are also affected at lesser degree (1/31, 3.2% each). That is in agreement with results of **Raman et al.**<sup>(8)</sup> who reported that the most commonly involved typical locations were the parieto-occipital lobes (n=92; 100%). However, other atypical regions involved were the frontal lobes (30.4%), temporal lobes (8.69%), basal ganglia (22%), cerebellum (17.39%), brainstem (9%) and thalamus (4%).

Our study showed that the percentages of involvement of anterior circulation and posterior circulation regions were significantly higher than that of deep structures, although no significant

difference was found between the former two regions.

In the study of **Gao *et al.*** <sup>(9)</sup> there were 35 patients with PRES. There were 85.7% had AC regions involved and 94.3% had PC regions involved, as well as 62.9% in DS. The percentages of involvement of AC and PC regions were significantly higher than that of DS although no difference was found between the former two regions. The white matter abnormal signal intensity of PRES may be unilateral or bilateral. Our study showed that the lesion was more commonly to be bilateral. However it was more common to be asymmetrical. This study showed that typical PRES represented 32.25% of cases, yet the atypical PRES represented 67.74% being classified as atypical location and atypical presentation.

The pattern of typical PRES identified in our study was bilateral and symmetrical white-matter abnormalities in vascular watershed areas in the posterior regions of both cerebral hemispheres, affecting mostly the occipital and parietal lobes. The atypical PRES was considered if there was involvement of any area of the brain unless the parieto-occipital regions, lesion asymmetry, hemorrhage, restricted diffusion or contrast enhancement.

This study showed that 14 out of 31 patients showed distribution of the lesion in atypical location, classified as follow: 7/14 (50%) of cases showed involvement of the cerebellum, 6/14 (42.8%) of cases involved the frontal lobe, 3/14 (21.4%) of cases involved the temporal lobe. Other atypical locations present in our study included brain stem, basal ganglia and corpus callosum, in which only 1 case present in each place (7.1% each).

In our study, 21 out of 31 patients were described as atypical PRES. The most common atypical presentation reported was asymmetrical distribution of the lesion (18/21) (85.7%), followed by restricted diffusion (14/21) (66.6%), then contrast enhancement (3/21) (14.2%) and hemorrhage (1/21) (4.7%).

**Raman *et al.*** <sup>(8)</sup> has also reported some cases with restricted diffusion (43%) and others with hemorrhage (9%).

In our study, we found that cerebral venous sinus thrombosis was the second common complication of chemotherapy on CNS following PRES. The most commonly involved location was

superior sagittal sinus (SSS) (62.5%) followed by transverse sinus (56.62%), sigmoid sinus (31.25%) IJV as well as the cortical veins (12.5% each) and straight sinus (6.25%).

A review of the MR imaging literature published by **Nahid *et al.*** <sup>(10)</sup> showed the general description of the anatomic distribution of thrombosed cerebral venous structures identified primarily at MR imaging. Multiple locations of thrombosis, particularly in the contiguous superior sagittal sinus, with or without lateral sinuses, were the most involved area (70.96%). Hemorrhagic venous infarction was considered as the most common complications of venous sinus thrombosis that was better to be depicted on MRI than on CT

In our study, we found 37.5% (6/16) of patients with hemorrhagic venous infarction, this is the same that has been reported by **Alvis *et al.*** <sup>(7)</sup> who found that parenchymal hemorrhage was seen in up to 30% of cases.

Acute lymphocytic leukemia was the most common malignancy associated with MTX neurotoxicity in which the patients received high dose of methotrexate; this is similar to what has been published by **Bhojwani *et al.*** <sup>(11)</sup>.

In our study, diffusion-weighted imaging was considered as the most sensitive imaging modality in the diagnosis of MTX neurotoxicity during the hyper-acute phase, as T2-weighted images and FLAIR images were often appeared to be normal at this stage. **Ayda *et al.*** <sup>(12)</sup> demonstrated abnormal restriction in the centrum semi-ovale.

Regarding xeloda toxicity the MRI showed increased signal on T2 and FLAIR as well as restricted diffusion. It typically involved the periventricular regions, the corpus callosum as well as the posterior parietal and anterior thalamic regions as detected in our study.

## REFERENCES

1. **Wang TY, Yen HJ, Hung GY *et al.*** (2011): A rare complication in a child undergoing chemotherapy for acute lymphoblastic leukemia: superior sagittal sinus thrombosis. *Journal of the Chinese Medical Association*, 74(4):183–187.
2. **Sioka C and Kyritsis AP** (2009): Central and peripheral nervous system toxicity of common chemotherapeutic agents. *Cancer Chemoth. Pharmacol.*, 163: 761-767.
3. **Richards A, Marshall H and McQuary A** (2010): Evaluation of methylene blue, thiamine and/or albumin in the prevention of ifosfamide-related neurotoxicity. *J. Oncol. Pharm. Pract.*, 17(4):372-380.



4. **Jaggi AS and Singh N (2012):** Mechanisms in cancer-chemotherapeutic drug-induced peripheral neuropathy. *Toxicology*, 291:1-9.
5. **Fugate JE, Claassen DO, Cloft HJ et al. (2010):** Posterior reversible encephalopathy syndrome: associated clinical and radiologic findings. *Clin. Proc.*, 85 (5): 427-432.
6. **Haykin ME, Gorman M, van Hoff J, Fulbright RK and Baehring JM (2006):** Diffusion-weighted MRI correlates of subacute methotrexate-related neurotoxicity. *J. Neurooncol.*, 76: 153-157.
7. **Alvis-Miranda H R, Milena Castellar-Leones S, Alcalá-Cerra G et al. (2013):** Cerebral venous sinus thrombosis. *J. Neurosci. Rural Pract.*, 4:427-438.
8. **Raman R, Devarmane R, Jagadish GM et al. (2017):** Various imaging manifestations of posterior reversible encephalopathy syndrome (PRES) on magnetic resonance imaging (MRI). *Pol. J. Radiol.*, 82:64-70
9. **B. Gao, Liu Feng-lib, Zhao Bina et al. (2011):** Association of degree and type of edema in posterior reversible encephalopathy syndrome with serum lactate dehydrogenase level: Initial experience. *European Journal of Radiology*, 56:316-320.
10. **Ashjazadeh N et al. (2011):** Cerebral venous-sinus thrombosis: a case series analysis. *Iranian Journal of Medical Sciences*, **Volume 36**:178-182.
11. **Bhojwani D, Sabin ND, Pei D et al. (2014):** Methotrexate-induced neurotoxicity and leukoencephalopathy in childhood acute lymphoblastic leukemia. *J. Clin. Oncol.*, 32(9):949-959.
12. **Ayda A, Youssef T, Raafat A and Madney Y (2015):** Child with acute methotrexate related neurotoxicity. *The Egyptian Journal of Radiology and Nuclear Medicine*, 46 (4):1149-1153.