

## 3D Ultrasonography Compared with Magnetic Resonance Imaging for the Diagnosis of Adenomyosis

Ahmed M. Hashad, Nashwa E. Hassan, Ahmed E. Elbohoty,  
Omnia B. Bakr, Ibrahim M. Ibrahim

Obstetrics and Gynecology Department, Faculty of Medicine, Ain-Shams University

**Corresponding author:** Omnia B. Bakr, email: dr.omnia.bakr@gmail.com, Mobile, 01205566692

**Background:** Adenomyosis is a common benign gynecological affecting premenopausal woman, in which there is increased overgrowth of the endometrium with invasion of the underlying myometrium. The precise pathogenesis of adenomyosis remains unknown with many theories being proposed that consider it to be a pathology that initially affects the endomyometrial junctional zone (JZ). **Aim of the Work:** The study aims to compare 3D transvaginal ultrasound with MRI in diagnosing adenomyosis in comparison with the gold standard histopathology. **Patients and Methods:** This cross-sectional study was carried out on 77 patients who were recruited from women presenting to the outpatient clinic at Ain Shams University Maternity Hospital planned to undergo hysterectomy (abdominal, vaginal or laparoscopic assisted hysterectomy) for adenomyosis according to the inclusion/ exclusion criteria. **Results:** Out of 77 patients included in the study, 67(87%) were +ve for adenomyosis by 3D TVUS, confirmed in 46(59.74%) by histopathology, while 52(67.53%) were +ve by MRI, confirmed in 39(50.64%) by histopathology. 3D transvaginal US was able to diagnose adenomyosis in 67(87%) patients and fibroid in 23(29.9%) patients, while MRI was able to diagnose adenomyosis in 52(67.5%) and fibroid in 36 (46.8%). **Conclusion:** our study results indicated that, 3D transvaginal ultrasound is highly accurate as MRI in diagnosing adenomyosis and leiomyoma as a preoperative diagnostic tool. **Recommendations:** As the 3D ultrasonography is more available, cheaper, less time consuming and easier technique, it is recommended to be used in every day clinical practice, helping the clinicians to reach an accurate diagnosis, select an appropriate treatment, and individualize management for each patient to reach the best outcome therapeutic rates.

**Keywords:** ultrasonography, magnetic resonance imaging, adenomyosis.

### INTRODUCTION

Adenomyosis refers to a disorder in which endometrial glands and stroma are present within the uterine musculature (uterine adenomyomatosis) <sup>(1)</sup>.

It is a condition that causes heavy menstrual bleedings, painful menstruation (dysmenorrhea), chronic pelvic pain, subfertility and infertility, in which the uterus gets larger than normal too <sup>(2,3)</sup>. Its incidence is estimated to be 25% to 35% in women undergoing hysterectomy because of benign gynecologic conditions, although in some studies, it has been reported to be as high as 70% <sup>(4)</sup>. Approximately 50 percent of affected women have co-existent fibroids <sup>(5)</sup>.

The diagnosis of adenomyosis is still a challenging problem, until recently; the criterion standard for a definitive diagnosis of adenomyosis was histopathologic analysis of hysterectomy specimens <sup>(6)</sup>. The only proven treatment for adenomyosis is surgery to remove the uterus, called a hysterectomy <sup>(7)</sup>. However, a recent meta-analysis has demonstrated that both US and MRI may enable accurate non-invasive diagnosis <sup>(8)</sup>.

Magnetic resonance imaging (MRI) seems to be a highly accurate tool in the preoperative diagnosis of adenomyosis; however, the combination of transvaginal ultrasound and MRI

(especially T2-weighted images) offers the highest sensitivity for preoperative diagnosis of adenomyosis <sup>(9)</sup>. In a review of 23 articles, the sensitivity and specificity of MRI for diagnosing adenomyosis was 77% and 89%, as compared with 72% and 81% for ultrasound <sup>(8)</sup>. For 2D-TVS and 3D-TVS, respectively, the overall accuracy for diagnosis of adenomyosis was 83% and 89%, the sensitivity was 75% and 91%, the specificity was 90% and 88%, the positive predictive value was 86% and 85% and the negative predictive value was 82% and 92% <sup>(10,11)</sup>. Although it is more expensive than ultrasonography, MRI can be employed in cases with indeterminate sonographic results for adenomyosis. Thin-section, high-resolution MRI scans obtained with a pelvic multicoil array are optimal for diagnosing adenomyosis. The uterine zonal anatomy is best seen on T2-weighted images <sup>(12)</sup>. On sonograms, the most common appearance of adenomyosis is areas of decreased echogenicity or heterogeneity in the myometrium, including irregular, myometrial, cystic spaces predominantly involving the posterior uterine wall; an enlarged uterus with a widened posterior wall; an eccentric endometrial cavity; and decreased uterine echogenicity without lobulations, contour

abnormality, or mass effects (which is more commonly seen with leiomyomas) <sup>(13)</sup>.

Visual evidence for adenomyosis with both modalities includes (1) asymmetric thickening of the myometrium (with the posterior myometrial typically thicker), (2) myometrial cysts, (3) linear striations radiating out from the endometrium, (4) loss of a clear endomyometrial border, and (5) increased myometrial heterogeneity. With MRI, some quantitation of the thickening of the junctional zone is possible with >12 mm generally considered diagnostic of the disease and <8 mm excluding adenomyosis <sup>(14)</sup>. The presence of myometrial cysts was the most specific 2D-TVS feature (specificity, 98%; accuracy, 78%) and heterogeneous myometrium was the most sensitive (sensitivity, 88%; accuracy, 75%). The 3D-TVS markers JZ dif >4 mm and JZ infiltration and distortion had high sensitivity (88%) and the best accuracy (85% and 82%, respectively) <sup>(11)</sup>.

The normal appearance of the JZ has been described on TVS or MRI as a regular inner layer of the myometrium, measuring 5mm or less in thickness <sup>(15)</sup>. Some two dimensional (2D) sonographic studies report only the subjective impression of a poorly defined JZ as a diagnostic criterion for adenomyosis, but with low sensitivity <sup>(16)</sup>. However, it has recently been observed that on the coronal section of the uterus, obtained with three-dimensional (3D) TVS, it is possible to visualize the JZ more clearly with certain postprocessing arrangements <sup>(17)</sup>.

#### **AIM OF THE WORK**

The study aims to compare 3D transvaginal ultrasound with MRI in diagnosing adenomyosis in comparison with the gold standard histopathology.

#### **PATIENTS AND METHODS**

##### **Study setting**

Ain Shams University Maternity Hospital

##### **Study design**

Cross sectional study

##### **Study duration**

The study was carried out during the period from September 2015 to September 2017.

##### **Study population**

77 patients were recruited from women presenting to the outpatient clinic at Ain Shams University Maternity Hospital planned to undergo hysterectomy (abdominal, vaginal or laparoscopic assisted hysterectomy) for adenomyosis according to the inclusion/ exclusion criteria.

##### **Sample size justification**

A meta-analysis reported that sensitivity and specificity of sonography in the diagnosis of adenomyosis was 82.5% and 84.6%, respectively

<sup>(18)</sup>. For the same purpose sensitivity and +specificity of MRI was found to be 77.8% and 92.5%, respectively <sup>(19)</sup>. Based on the specificity of the two techniques, for paired comparison, the minimum required sample is 77 patients at an alpha level of 0.05 and a power of 80%.

#### **Inclusion criteria**

- 1- Premenopausal women aged 40-55 years old.
- 2- One or more of the following clinical symptoms: bleeding disorders (menorrhagia, irregular bleeding, hyper-menorrhoea), chronic pelvic pain, dysmenorrhoea, or dyspareunia.
- 3- 2D ultrasonography suggestive for adenomyosis.
- 4- Junction zone definable (it is a region representing the inner myometrium consists of closely packed compact smooth muscle cells with little extracellular matrix and water content and it should be clear and obvious in imaging modalities).
- 5- Bulky uterus (larger than 10 weeks' gestational size) with no history of previous histologic investigation.

#### **Exclusion criteria**

- 1- Postmenopausal women.
- 2- Pregnancy.
- 3- Gynecological cancer.
- 4- GnRH analog therapy or systemic hormone therapy in the last three months prior to hysterectomy.
- 5- History of minimally invasive treatment of menorrhagia (e.g., endometrial ablation or endometrial resection).
- 6- Medical contraindications to surgery e.g. (advanced liver or cardiac disease).

#### **Intervention:**

Signed informed consent was obtained from all patients. All patients were given a detailed medical and gynecologic history, and had pelvic examination.

#### **All patients were subjected to the following:**

##### **Consent:**

The study and procedures were explained to the patients before entering the study, and consents were obtained from patients participating in the study.

#### **HISTORY**

##### **Complete history taking with special emphasis on:**

- Personal history including age.
- Patient menstrual history, including date of last menstrual period to exclude pregnancy, regularity and amount.
- Parity, number and mode of deliveries, as well as contraceptive method currently used.

- Menopausal status.
- History of drug intake, especially hormonal treatment or anticoagulant therapy.
- Patient's complaint and presence of vaginal bleeding.
- Past and family history (e.g., cancer, bleeding disorders ...etc.)

**Examination:**

- **General examination** including vital signs as pulse, temperature, blood pressure, pallor, cardiac examination with the presence of thrills or murmurs, limb clubbing, abdominal examination including ascites, presence of scars of previous operation, and determination of uterine fundal level.
- **Local examination** including inspection of external genitalia, digital examination including pervaginum and bimanual examination to detect the size of the uterus, its position, mobility, any cervical masses, any adnexal masses, speculum examination and rectal examination if necessary.

**Investigation:**

Routine preoperative investigations were done in addition to a serum pregnancy test if pregnancy was clinically suspected.

Results of any previous investigation; namely 2D transvaginal ultrasound, hysteroscopy, hysterosalpingography or endometrial biopsy were received and data registered in the patients record.

3D Doppler ultrasonography, Magnetic Resonance Imaging, surgery, and histopathological analysis were performed independently and without knowledge of the other investigators' diagnosis. When the preoperative investigations were completed, the patients were consenting for total hysterectomy and further histopathological examination of the uterine specimens.

All 3D Doppler ultrasonography was done by senior sonographers at the ultrasound fetal special care unit at Ain Shams maternity hospital, MRI interpretation was performed by Radiology department at Ain Shams university doctors, all operations were performed in a standard fashion by expert gynecologists, and hysterectomy specimens were examined by pathologists.

**3D Doppler ultrasound examination:**

Three-dimensional transvaginal ultrasonography examination was done to all patients using Voluson E6 BT12 3D system. 3D ultrasound was done with a 4D endocavity probe RI. Once the B-mode had been completed, three dimensional volumes were recorded. The volumes were generated by the automatic rotation of the mechanical transducer 360 degrees. The probe was kept steady, the patient was asked to hold breath and volume mode was switched on.

With the use of the medium line density, the typical acquisition time was between 4 and 10 seconds, the acquired volume was in the shape of a truncated cone, the typical depth of the truncated cone was 4.3-8.6 cm and the angle aloha was 90 degrees. Relation of any focal lesion to the myometrium was taken in the three planes with their dimensions. During each sonographic examination, the uterine borders (regular or irregular), uterine size, myometrial echotexture and the presence of associated abnormalities (including myomas) were noted.

**We determined the presence of certain TVS features associated with adenomyosis:**

1. Myometrial cysts and heterogeneous areas
2. Myometrial hypoechoic linear striations,
3. Diffuse vascularity
4. Asymmetry of the myometrial wall.

**Asymmetrical myometrial walls** were defined as a regular enlarged uterus with asymmetry unrelated to leiomyoma, heterogeneous myometrium as an indistinctly defined myometrial area with decreased or increased echogenicity, myometrial hypoechoic linear striations as a pattern of thin acoustic shadowing not arising from echogenic foci and/or leiomyoma, and myometrial cyst as a round anechoic area within the myometrium.

Ultrasound digital and photographic images were saved and stored on a USB drive for subsequent retrieval. Using 3D-TVS, volume of the uterus was then acquired in order to obtain uterine axial, sagittal, and the coronal view. Two to four static gray-scale volumes of the uterus were obtained from the sagittal plane and from the transverse plane. The volume acquisition technique was standardized according to the following criteria: frequency, 6–9 MHz; magnification of the uterus up to half of the screen; sweep angle, 120°; sweep velocity, adjusted from medium to maximum quality; 3D volume box exceeding the uterus by 1 cm on each side. The coronal view reconstruction technique involved placing a straight or curved line (OmniView or rendering mode) along the endometrial stripe on the sagittal and transverse views (Panel A and B of the multiplanar view). The multiplanar view was then manipulated until a satisfactory coronal image was obtained of the uterine external profile and the cavity, with visualization bilaterally of the interstitial portion of the Fallopian tube. Volume contrast imaging (VCI) was applied (2–4 mm slice thickness) with volume rendering (mixed light surface and gradient light). Following acquisition, ultrasound volumes were stored on the hard drive of the machine and retrieved subsequently for offline analysis.

**On the coronal view the JZ appeared as a hypoechoic zone around the endometrium.**

Using VCI modality with 2–4-mm slices it could be viewed clearly in all planes of the multiplanar view. Disruption and infiltration of the hypoechoic JZ by the hyperechoic endometrial tissue was described and the JZ thickness was measured as the distance from the basal endometrium to the internal layer of the outer myometrium. We determined: JZmin (which can be considered the normal JZ thickness during any phase of the cycle not affected by adenomyosis), JZ max, the maximum myometrial thickness, presence of JZ alteration, presence of myometrial cysts, asymmetry of the myometrial wall and presence of myometrial heterogeneous areas. JZmax and JZmin were defined as the largest and smallest JZ thickness measured on coronal section or longitudinal section at any level of the uterus (fundus or anterior, posterior or lateral walls), maximum myometrial thickness as the diameter from the basal endometrium to the uterine serosa measured at the same level as that of JZmax, and alteration of the JZ as distortion and infiltration of the hypoechoic inner myometrium by hyperechoic endometrial tissue or ill-defined JZ. Using vaginal 3D transducer (Voluson 730 pro), we obtained a 3 dimensional box from the uterus. With a sweeping angle of 90 degrees, the acquisition box of 3 dimensional volumes was placed over the power Doppler window. The patients remain as still as possible, and volume acquisition was made during a time interval that varied from 15-20 seconds. Volume acquisition was repeated when artifacts flash-type appeared because of respiratory or intestinal movements. Volumes was stored and evaluated later with the virtual organ computer aided analysis program, myometrial area was evaluated manually in the coronal or C plane. With a rotational technique with a 9-degree step, 20 myometrial slices were obtained that outlined the myometrium at the myometrial-endometrial junction from the fundus to the internal cervical os. The VOCAL program automatically calculates the myometrial volume and the 3D-Power Doppler indices.

**These indices measure vascularization (1) or blood flow (2) or both (3):**

- (1) Vascularization index (VI)
- (2) Flow index (FI)
- (3) Vascularization–flow index (VFI)

VI measures the number of color voxels in the volume, which represents the vessels in the tissues and expressed as a percentage. FI is the mean color value in the color voxels, which indicates the average intensity of blood flow and is expressed as an entire number from 0-100. VFI is the mean color value in all the voxels in the volume, which represents both vascularization and

blood flow and is also expressed as an entire number from 0-100.

3D Doppler ultrasonography will be done by senior sonographers in the special care unit fetal special care unit at Ain Shams University Maternity Hospital.

**Magnetic Resonance Imaging:**

All patients did MRI of the lower abdomen and pelvis (Philips Chivia Sense XL Torso with power 1.5Tesla). During MRI, the following sequences were obtained: intermediate- to high-signal intensity T1-weighted image, to indicate the borders and the anatomy of the internal organs; low-signal intensity T2-weighted image, to differentiate the layers of the uterus and enable diagnosis of any abnormalities; sections after intravenous administration of Ultravist (Iopromide), to differentiate the layers of the uterus. During MRI, longitudinal, axial, and oblique sections were routinely obtained. Each examination was completed within 30 to 45 minutes. For diagnosis of adenomyosis, the junctional zone contours were reported as uniform or not uniform in so far as thickness. The thickness was measured at the anterior and posterior walls at the thickest part of the zone. When the thickness is 12 mm, focal or diffuse not well-demarcated low signal intensity areas are present in the myometrium, and the junctional zone is non-uniform, adenomyosis was diagnosed.

Four criteria were evaluated on T2-weighted sequences: (i) borders, size and uterine symmetry, (ii) maximal junctional zone ( $JZ_{max}$ ) thickness and/or presence of an ill-defined, relatively homogeneous, low-signal-intensity myometrial area (IDMA), (iii) maximal JZ thickness to myometrial thickness ratio ( $ratio_{max}$ ), using the maximal thickness of the JZ and the corresponding thickness of the entire myometrium obtained at the same level, and (iv) high-intensity spots within the myometrium. Leiomyoma, adnexal masses, and endometrial or cervical abnormalities were also recorded. Also on contrast enhanced T1-weighted images, (iopromide scan) small hypointense myometrial spots were indicative of adenomyosis. Adenomyosis was defined by: (i) a large, regular, asymmetric uterus without leiomyomas, (ii)  $JZ_{max}$  of at least 12 mm and/or an ill-defined, low-signal-intensity myometrial area distinguished from well-circumscribed masses related to myoma, (iii)  $ratio_{max} >40\%$  and (iv) punctate high-intensity myometrial foci. MRI interpretation was performed by Ain Shams University Radiology Department staff. In all patients, hysterectomy was performed in a manner appropriate for their clinical

condition (laparotomic, laparoscopic or vaginal hysterectomy). The entire uterus was sent to the pathologist. Pathologists in the pathology department at Ain Shams University Maternity Hospital examined the surgical specimens. Adenomyosis was defined histopathologically by the presence of endometrial glands and stroma in the myometrium, located >2.5 mm beyond the endomyometrial junction, in some cases it remained diffuse pathology, in others it was seen as a circumscribed nodular lesion mimicking an intramural myoma, which was defined as adenomyoma.

For the purposes of statistical analysis in this study, we considered only the presence or absence of adenomyosis. The results were used to confirm the 3D Doppler US and MRI findings for the presence of adenomyosis using the histopathology as the gold standard by today.

**Statistical Methodology**

Data were analyzed using SPSS© Statistics version 21 (IBM© Corp., Armonk, NY, USA). Categorical variables were presented as number and percentage or ratio, and numerical data as mean and SD, range, and percentiles.

Normality of numerical data distribution was examined using the Shapiro-Wilk test. Non-normally distributed numerical variables were presented as median and interquartile range and intergroup differences were compared using the Mann-Whitney test. The diagnostic accuracy of 3DTVUS or MRI was examined versus histopathology as the gold-standard for diagnosis. The diagnostic value of either tool was expressed in terms of sensitivity and specificity, positive and negative predictive value, positive and negative likelihood ratio, and correct classification and misclassification rates.

Receiver-operating characteristic (ROC) curve analysis was used to examine the diagnostic (or predictive) value of subendometrial Doppler indices. Areas under ROC curves were compared using the DeLong method. The area under the ROC curve (AUC) is interpreted as follows:

Area under ROC curve (AUC)	Diagnostic / predictive value
.9 – 1.0	Excellent
.8 – .89	Good
.7 – .79	Fair
.6 – .69	Poor
<.6	Fail

**The study was approved by the Ethics Board of Ain-Shams University.**

**RESULTS**

A total of 77 patients were enrolled into this study with mean age 46(range, 40–55) years. Major symptoms; abnormal uterine bleeding in 48

(62.33%) patients, pain in 14 (18.18%) and both in 15 (19.48%). Hysterectomy was performed by laparotomy (total abdominal hysterectomy, TAH) in 25 (32.5%), vaginal hysterectomy (VH) in 38 (49.4%) and laparoscopic (laparoscopic assisted vaginal hysterectomy, LAVH) in 14(18.2%). The mean JZ-max was significantly greater in patients with adenomyosis than in those without adenomyosis, whereas the JZ-min mean value was similar between the groups and it was almost the same for both 3D TVUS and MRI for the diagnosis of adenomyosis.

**Table (1):** Demographic data of the included women

Age	46±4(40-55)
<b>Presenting History</b>	
Bleeding	48 (62.33%)
Pain	14 (18.18%)
Both	15 (19.48%)
<b>Method of hysterectomy</b>	
TAH	25 (32.5%)
VH	38 (49.4%)
LAVH	14 (18.2%)
<b>Junctional Zone</b>	
TVUS	25.9±12.0 (7-56)
MRI	24.3±15.0 (7-57)

**Data presented as range, mean ± SD Percentage % or number.**

**Table (2):** Result of histopathological examination of excised uteri

Histopathology	Adenomyosis	3	44.15
		4	%
Fibroid	2	2	28.57%
Adenomyosis + Fibroid	1	4	18.18%
Normal	7	9	9%

**Data presented as percentage % or number.**

Histopathology of the removed uteri revealed adenomyosis in 34 patients (44.15%), fibroid only in 22 patients (28.57%), adenomyosis + fibroid in 14 patients (18.18%) and normal uterus in 7 patients(9%), so histopathology confirmed adenomyosis in 62.3% (48 patients) and declined it in37.7% (29 patients).

**Table (3):** Results of 3DTVUS and MRI examination

3DTVUS	Adenomyosis Associated fibroid	67	87.0%
		23	29.9%
MRI	Adenomyosis	52	67.5%

3D Ultrasonography Compared...

Associated fibroid	36	46.8%
--------------------	----	-------

52(67.53%) were +ve by MRI, confirmed in 39(50.64%) by histopathology.

3D transvaginal US was able to diagnose adenomyosis in 67(87%) patients and fibroid in 23(29.9%) patients, while MRI was able to diagnose adenomyosis in 52(67.5%) and fibroid in 36 (46.8%).

**Data presented as percentage % or number.**

Out of 77 patients included in the study, 67(87%) were +ve for adenomyosis by 3D TVUS, confirmed in 46(59.74%) by histopathology, while

**Table (4):** Diagnostic accuracy of MRI / 3DTVUS for detection of adenomyosis

	MRI/Histopathology			3DTVUS/Histopathology		
	Adenomyosis	No Adenomyosis	Column total	Adenomyosis	No Adenomyosis	Column total
Adenomyosis	39	13	52	46	21	67
No Adenomyosis	9	16	25	2	8	10
Row total	48	25	77	48	29	77
	95% CI			95% CI		
Sensitivity	55.2%	(37.6%–71.5%)		95.8%	(85.1% –99.6%)	
Specificity	81.3%	(67.7%–89.9%)		87.6%	(14.6% –46.0%)	
False positive rate	44.8%	(27.9%–61.8%)		72.4%	(57.2% –87.7%)	
False negative rate	18.8%	(8.1%–29.4%)		4.2%	(0.0% –9.6%)	
Prevalence	62.3%	(51.5%–73.2%)		62.3%	(51.5% –73.2%)	
Positive predictive value (PV+)	75.0%	(63.2%–86.8%)		68.7%	(57.5% –79.8%)	
Negative predictive value (PV-)	64.0%	(45.2%–82.8%)		80.0%	(55.2% –100.0%)	
Positive likelihood ratio (LR+)	1.81	(1.18–2.78)		1.32	(1.05 –1.67)	
Negative likelihood ratio (LR-)	0.34	(0.17–0.67)		0.15	(0.03 –0.66)	

Of the 67 patients who were positively diagnosed with adenomyosis by 3DTVUS, 46 of the patients' diagnoses were confirmed by the histopathological findings. The other 10 patients had a negative histopathological diagnosis. While of the 52 patients who were positively diagnosed with adenomyosis by MRI, 39 of the patients' diagnoses were confirmed by the histopathological findings. The other 25 patients had a negative histopathological diagnosis. These data concludes that 3D TVUS is found to be sensitive 95.8 % (95% CI 85.1%-99.6%) compared to MRI 81.3 % (95% CI 67.7%-89.9%) but not specific 27.6 % (95% CI 14.6%\_46.0%) compared to MRI 55.2 % (95% CI 37.6%-71.5%) in diagnosis of adenomyosis.

**Table (5):** Diagnostic accuracy of MRI/3DTVUS for detection of fibroid

	MRI/Histopathology			3DTVUS/Histopathology		
	Fibroid	No fibroid	Column total	Fibroid	No fibroid	Column total
Fibroid	24	12	36	21	2	23
No fibroid	12	29	41	15	39	54
Row total	36	41	77	36	41	77
	95% CI			95% CI		
Sensitivity	70.7%	(55.4%–82.4%)		95.1%	(82.8% –99.4%)	
Specificity	66.7%	(50.2%–79.8%)		58.3%	(42.2 % –72.8%)	
False positive rate	29.3%	(16.0%–42.6%)		4.9%	(0.0% –11.2%)	
False negative rate	33.3%	(18.7%–47.9%)		41.7%	(26.4% –56.9%)	
Prevalence	46.8%	(35.6%–57.9%)		46.8%	(35.6% –57.9%)	
Positive predictive value (PV+)	66.7%	(51.3%–82.1%)		91.3%	(79.8% –100.0%)	
Negative predictive value (PV-)	70.7%	(56.8%–84.7%)		72.2%	(60.3% –84.2%)	
Positive likelihood ratio (LR+)	2.28	(1.34–3.87)		11.96	(3.01 –47.51)	

Negative likelihood ratio (LR-)	0.47	(0.29–0.78)	0.44	(0.30 –0.65)
---------------------------------	------	-------------	------	--------------

Of the 23 patients who were positively diagnosed with fibroid by 3DTVUS, 21 of the patients' diagnoses were confirmed by the histopathological findings. The other 54 patients had a negative histopathological diagnosis. While of the 36 patients who were positively diagnosed with fibroid by MRI, 24 of the patients' diagnoses were confirmed by the histopathological findings.

The other 41 patients had a negative histopathological diagnosis. These data concludes that 3D TVUS is found to be specific 95.1% (95% CI 82.8%-99.4%) compared to MRI 70.7 % (95% CI 55.4%-82.4%) but not sensitive 58.3 % (95% CI 42.2%-72.8%) compared to MRI 66.7 % (95% CI 50.2%-79.8%) in diagnosis of fibroid.

**Table (6):** Comparison of 3D transvaginal U/S Doppler indices in patients with or without adenomyosis

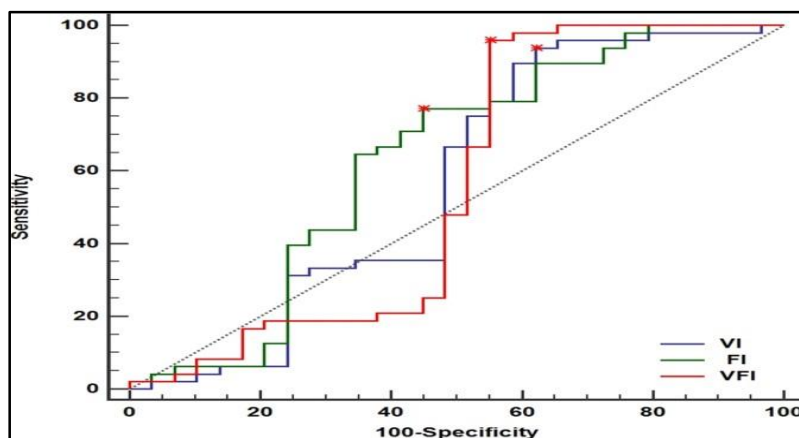
	<i>Histopathology</i>				<i>*p-value</i>
	<b>No Adenomyosis (n=29)</b>		<b>Adenomyosis (n=48)</b>		
VI	17.4	(4.2 – 23.2)	15.4	(3.4 – 18.2)	.328
FI	33.3	(29.5 – 37.5)	36.6	(33.8 – 38.4)	.060
VFI	3.2	(0.2 – 9.3)	2.1	(0.8 – 6.5)	.424

Data presented as number, median (range).

\*Using Mann-Whitney U test.

A comparison between 3D Doppler transvaginal ultrasound indices in patients whether confirmed (n=48) or excluded (n=29) to have adenomyosis by histopathology, (these data indicate that Doppler indices is statistically non-significant for the diagnosis of adenomyosis) as shown in (table 6 and figure 1).

Receiver-operating characteristic (ROC) curve analysis was used to examine the diagnostic (or predictive) value of 3D Doppler indices. Areas under ROC curves were compared using the DeLong method, indicating non-significance of Doppler indices as a diagnostic tool for adenomyosis.



**Figure (1):** Receiver operating characteristic (ROC) curve analysis for prediction of adenomyosis using VI, FI, or VFI.

**DISCUSSION**

This study included 77 patients who were previously diagnosed by two-dimensional ultrasonography to have adenomyosis, and were scheduled for hysterectomy, underwent a preoperative 3d Doppler transvaginal ultrasound and MRI; the diagnosis was proved by the histologic examination.

This study aimed to compare the accuracy of 3D transvaginal ultrasound with MRI in

diagnosing adenomyosis in comparison with the gold standard histopathology.

The most common clinical presentation in this study was abnormal uterine bleeding 48/77 (62.33%) followed by chronic pelvic pain 14/77 (18.18%) and multiple symptoms in 15/77

(19.48%). Similar results were obtained by the study done by Ya-Min et al. (20) and Elkattan et al. (21). The most common presentation in their study was menorrhagia 51/95 (53.7%), 90/123 (73%)

followed by dysmenorrhea 17/95 (17.9%), 10/123 (8%) and multiple symptoms 17/95 (17.9%), 18/123 (14.6%) respectively.

In the current study the disease prevalence was 62.3% (48/77) patients. According to *Graziano et al.* (22), the prevalence of adenomyosis ranges from 5 to 70%. Exacoustos et al. (11) showed the histological prevalence of adenomyosis of 44.4% (32/72 patients), Bazot et al. (19) showed the histological prevalence of adenomyosis of 33% (40/120) this high variability is due to several factors such as the diagnostic criteria, the characteristics of the sample under analysis, and the researcher's skills.

In the present study 3D-TVS showed sensitivity and specificity 95.8% and 87.6% respectively, a positive and negative predictive value 68.7% and 80% respectively with overall accuracy of 70.1% for diagnosis of adenomyosis. Which comes with positive correlation to results expressed by *Andres et al.* (23), a systematic evaluation of the literature in the last 10 years was done to determine the accuracy of 3D TVUS for the diagnosis of adenomyosis, pooled sensitivity and specificity for all combined imaging characteristics was 88.9% and 56.0% respectively. Poor definition of junctional zone showed the highest pooled sensitivity (86%) and the highest pooled specificity (56.0%) for the diagnosis of adenomyosis with 3D TVUS. A limitation of this study is that we did not compare the criteria used for diagnosis of adenomyosis.

*Gaafar et al.* (24) evaluated 100 patients who underwent TAH after a preoperative 3D TVUS, the diagnostic accuracy of 3D ultrasonography versus uterine pathology was assessed, in pre-menopausal women having abnormal uterine bleeding showed sensitivity and specificity (90% and 92.8%) respectively, a PPV and NPV (69.2% and 98.1%) respectively with overall accuracy 92.42% in diagnosis of adenomyosis, which differ from our study that we include patients having abnormal uterine bleeding, chronic pelvic pain or combined symptoms.

A study by Luciano et al. (25) included 54 symptomatic premenopausal women underwent preoperative 3D TVS of the uterus to evaluate alterations to the JZ, results of the sonographic features were correlated with the histopathologic findings of the ultrasound-based targeted biopsy specimens of the uterus, the results showed sensitivity and specificity (92% and 83%) with overall accuracy 90% for diagnosis of adenomyosis, thus 3D TVS demonstrates high diagnostic accuracy in detection of site and position of adenomyosis in the uterine walls.

One of the strengths of our study is that it included only the patients who had hysterectomy in contrast to Luciano et al. who had targeted biopsy specimens of the uterus, which allow us to exclude

double pathology and give more accurate results, on the other hand a limitation in this study that we did not determine the site of the lesions.

Ahmadi and Haghighi (26) studied the use of 3D ultrasound, in assessing the diagnostic accuracy of 'the presence of a hazy or ill-defined and irregular JZ on 3D coronal plane of the uterus'. They reported a positive predictive value (PPV) of 95% and an accuracy of 80% for this finding in diagnosing adenomyosis with limitations of this study not determining the overall sensitivity, specificity or accuracy of 3D TVUS in diagnosing adenomyosis.

Also, Exacoustos et al. (11) who studied 72 premenopausal patients undergoing hysterectomy had a preoperative 3D TVUS, three-dimensional sonographic findings of the junctional zone and correlation with histology to diagnose adenomyosis and concluded, a JZdif  $\geq$  4 mm and JZ infiltration and distortion had high sensitivity (88%) and the best accuracy (85% and 82%, respectively), sensitivity and specificity (91% and 88%) with overall accuracy 89% for diagnosis of adenomyosis, which gives a good diagnostic accuracy for adenomyosis.

Struble et al. (2) a review of adenomyosis stated that recent studies indicate that 3-dimensional TVUS is superior to 2-dimensional TVUS for the diagnosis of adenomyosis and may allow for the diagnosis of early-stage disease

In the current study, we compared the doppler indices between patients proved to have adenomyosis from those who are excluded (by histopathology), unlike Elkattan et al., (21) who compared these indices between patients proved to have adenomyosis from those proved to have fibroid (by histopathology).

Our study showed VI= 15.4 (3.4-18.2), FI= 36.6 (33.8-38.4), and VFI = 2.1(0.8-6.5) with no significance in diagnosis of adenomyosis while Elkattan et al. (21) stated that there were higher 3D power Doppler vascular indices in the group with fibroids than adenomyomas (VI, FI, VFI), (2.401, 39.931, 1.29) for fibroid and (1.924, 28.332, 0.89) for adenomyosis respectively, also Ya-Min et al. (20) results revealed that patients with uterine leiomyoma had significantly higher VI (U = 375.50, p < 0.001), FI (U = 386, p < 0.001), and VFI (U = 374.5, p < 0.001) levels than did patients with adenomyosis.

Both *Ya-Min et al.* (20) and *Elkattan et al.* (21) revealed significant difference in vascular location between cases of uterine leiomyoma and adenomyosis, the proportion of peripheral location in the myoma group was higher than that found in the adenomyosis group which tend to be more



scattered, vascular location proved the most powerful among the ultrasonographic parameters.

**Exacoustos et al.** <sup>(11)</sup> used 3D power doppler to distinguish between a myometrial cyst and a vascular component, and between leiomyoma and focal adenomyosis, localized adenomyosis and adenomyoma were characterized by the presence of rare, diffuse vessels, while fibroids had flow aligned along the external myoma capsule, appearing on imaging as a vascular ring.

In the present study, MRI results using the JZ changes and high intensity spots on T2 weighted images compared to histopathology showed low sensitivity and high specificity 55.2% and 81.3% respectively, a positive and negative predictive value 75% and 64% respectively in diagnosing adenomyosis with overall accuracy 71.4%. These results can be compared with results obtained by **Stamatopoulos et al.** <sup>(27)</sup> a prospective study that studied 153 women with an enlarged uterus accompanied by gynecologic symptoms and/or with an asymptomatic pelvic mass, underwent total abdominal hysterectomy assessing the value of Magnetic Resonance Imaging in diagnosis of adenomyosis and fibroid, MRI demonstrated low sensitivity (46.1%), high specificity (99.1%), PPV of 92.3%, and NPV of 88.5%, thus MRI exhibits a high AUC for the diagnosis of adenomyosis.

**Champaneria et al.** <sup>(8)</sup>, a systematic review with meta-analysis of 23 articles comparing ultrasound with MRI for diagnosis of adenomyosis showed that MRI had a pooled sensitivity of 77%, specificity of 89%, positive likelihood ratio of 6.5, and negative likelihood ratio of 0.2.

**Moghadam et al.** <sup>(28)</sup>, a retrospective chart review who stated that MRI and pathology report were the same for 12 of 31 women with adenomyosis, MRI has a high specificity (91%) and a low sensitivity (38%) for diagnosing adenomyosis, Positive and negative predictive values of MRI for adenomyosis were 52% and 85%, respectively, with 80% accuracy a limitation in that study that it include patients that will undergo myomectomy missing another coexisting pathology.

**Sofic et al.** <sup>(29)</sup>, a prospective comparative study stated that, using MRI there is a statistically significant difference in the thickness of the JZ between the control  $M = 14,3\text{mm}$ ,  $SD = 1.3\text{mm}$  and target group (patients with adenomyosis)  $M = 5,6\text{mm}$ ,  $SD = 1,3$ , thus MRI is the method of choice for imaging and evaluation of JZ as an important diagnostic marker in the diagnosis of adenomyosis which come with results of the present study  $24.3 \pm 15.0$  SD.

**Novellas et al.** <sup>(30)</sup> declared that adenomyosis can be diagnosed using MRI with a diagnostic

accuracy of 85%. The most important MR finding in making the diagnosis is thickness of the junctional zone exceeding 12 mm. The principal limitation of MRI is the absence of a definable junctional zone on imaging, which occurs in 20% of premenopausal women.

**Bazot et al.** <sup>(19)</sup>, a prospective study of 120 patients undergoing hysterectomy comparing TAUS, TVUS and MRI for the diagnosis of adenomyosis and stated that in MRI, the presence of a high-signal-intensity myometrial spot was as specific but less sensitive than a maximal junctional zone thickness (JZ(max))  $>12$  mm and a JZ(max) to myometrial thickness ratio  $>40\%$ . Sensitivity, specificity, and positive and negative predictive values of MRI were 77.5, 92.5, 83.8 and 89.2% respectively; these results were similar to our study results. No difference in accuracy was found between TVUS and MRI.

**Dueholm et al.** <sup>(31)</sup> noted that MRI sensitivity was 0.70 (0.46–0.87); specificity 0.86 (0.76–0.93), the combination of MRI and TVS was most sensitive (0.89 [0.64–0.98]). A limitation in Dueholm study that it included all their patients suffering from abnormal uterine bleeding while our patients were more specific to adenomyosis. These results are in accordance with previous studies.

**Reinhold et al.** <sup>(32)</sup> studied 119 consecutive patients undergoing hysterectomy, the endovaginal US scans and MR images were interpreted independently in a double-blind fashion study concluded that the Sensitivity 81%, specificity 91%, PPV 65% and NPV was 95% for MR imaging. The mean junctional zone (JZ) thickness on MR images in patients with and without proved adenomyosis was 15.0 mm (+/- 4.9) and 7.7 mm (+/-3.3), respectively, afterwards, this study established the optimal diagnostic criteria for MRI (JZmax of 12mm). Again our study was specific to adenomyosis in the type of patients and using more criteria to measure JZ and diagnose adenomyosis using MRI.

Most of these studies compared the diagnostic accuracy of 2D TVUS with MRI in the diagnosis of adenomyosis <sup>(8,19,32)</sup> while our current study was to the extent of our knowledge the first study to compare 3D TVUS and Doppler indices with MRI for the diagnosis of adenomyosis.

Also **Graziano et al.** <sup>(22)</sup> stated, even though MRI was traditionally considered more accurate than TVS, recent studies have proved that the two techniques are comparable (especially when a 3D-TVUS is performed), Also, **Dueholm et al.** <sup>(31)</sup> concluded, MRI and TVS were equally good at identifying patients with adenomyosis, but MRI was superior to TVS to exclude the diagnosis of adenomyosis, with equal sensitivity but a higher specificity (sensitivity: MRI, 70%; and TVS 68%;

specificity: MRI 86%; and TVS 65%). The combination of TVS and MRI had the highest sensitivity, but, surprisingly, it also had the lowest specificity. In addition, measuring the difference in junctional zone thickness may optimize the MRI diagnosis. Reinhold et al. <sup>(14)</sup> found that there was no statistically significant difference between the sensitivities and specificities of TVUS and MR imaging, (the sensitivity and specificity were 89% for TVS and 86% for MRI). The positive predictive value was 71% for TVS and 65% for MRI, however, MRI would have had a slightly higher diagnostic efficacy than TVS, if the criteria, afterwards established, had been used.

**Bazot et al.** <sup>(19)</sup> suggested that TVU and MRI have similar accuracy rates for the diagnosis of adenomyosis in the absence of associated disorders. However, **Ascher et al.** <sup>(33)</sup> MRI is significantly better than TVU ( $p < 0.02$ ) for diagnosing adenomyosis.

In the present study it was found, 3D transvaginal ultrasound showed high sensitivity and low specificity in the diagnosis of fibroid (95.8% and 58.3%) respectively, a PPV and NPV (91.3% and 72.2%) respectively with overall accuracy 77.9% that was in agreement with the study done by **Gaafar et al.** <sup>(24)</sup> evaluated the diagnostic accuracy of 3D ultrasonography versus uterine pathology, in 100 pre-menopausal women having abnormal uterine bleeding and showed sensitivity and specificity (96% and 45.45%) respectively, a PPV and NPV (80% and 83.3%) respectively with overall accuracy 80.56% in diagnosis of fibroid..

In our study MRI showed sensitivity and specificity in the diagnosis of fibroid (70.7% and 66.7%) respectively, a PPV and NPV (66.7% and 70.7%) respectively with overall accuracy 68.8%. Our results were comparable to those of **Charalampos et al.** <sup>(27)</sup> who studied the value of Magnetic Resonance Imaging in diagnosis of fibroid and found that MRI demonstrated sensitivity of 94.1%, specificity of 68.7%, PPV of 95.7%, and NPV of 61.1%, also, **Moghadam et al.** <sup>(28)</sup> stated, MRI and pathology were the same for 136 of 144 women with leiomyoma; MRI has a high sensitivity (94%) and a low specificity (33%). Positive and negative predictive values were 95% and 27% with 90% accuracy for diagnosing leiomyoma.

## CONCLUSION AND RECOMMENDATIONS

In conclusion, our study results indicated that, 3D transvaginal ultrasound is highly accurate as MRI in diagnosing adenomyosis and leiomyoma as a preoperative diagnostic tool.

Therefore, as the 3D ultrasonography is more available, cheaper, less time consuming and easier technique, it is recommended to be used in

every day clinical practice, helping the clinicians to reach an accurate diagnosis, select an appropriate treatment, and individualize management for each patient to reach the best outcome therapeutic rates.

## REFERENCES

- McElin TW and Bird CC (1974):** Adenomyosis of the uterus. *Obstet Gynecol Annu.*,3:425.
- Struble J, Reid S Bedaiwy M (2016):** "Adenomyosis: A Clinical Review of a Challenging Gynecologic Condition". *Journal of Minimally Invasive Gynecology*,23 (2): 164–185.
- Bromley B, Shipp TD Beacerraf B (2000):** Adenomyosis: sonographic findings and diagnostic accuracy. *J Ultrasound Med.*, 19: 529–534.
- Farquhar C and Brosens I (2006):** Medical and surgical management of adenomyosis. *Best Pract Res Clin Obstet Gynaecol.*, 20(4):16–603.
- Azziz R (1989):** Adenomyosis current perspectives. *Obstet Gynecol Clin North Am.*, 16:221.
- Vercellini P, Vigan`o P, Somigliana E, Daguati R, Abbiati A, Fedele L (2006):** Adenomyosis: epidemiological factors. *Best Pract Res Clin Obstet Gynaecol.*, 20: 465–477.
- Grimbizis GF, Mikos T, Zepiridis L, Theodoridis T, Miliaras D, Tarlatzis BC and Bontis JN (2008):** Laparoscopic excision of uterine adenomyomas. *Fertil Steril.*, 89(4):61–953.
- Champaneria R, Abedin P, Daniels J, Balogun M and Khan KS (2010):** Ultrasound scan and magnetic resonance imaging for the diagnosis of adenomyosis: systematic review comparing test accuracy. *Acta Obstet Gynecol Scand.*, 89(11):84–1374.
- Kunz G, Beil D, Huppert P, Noe M, Kissler S, Leyendecker G (2005):** Adenomyosis in endometriosis – Prevalence and impact on fertility. Evidence from magnetic resonance imaging. *Hum Reprod.*,20: 2309–2316.
- Sun YL, Wang CB, Lee CY, Wun TH, Lin P, Lin YH, Tseng CC, Chen CH, Tseng CJ (2010):** Transvaginal sonographic criteria for the diagnosis of adenomyosis based on histopathologic correlation. *Taiwan J Obstet Gynecol.*, 49(1):40–4.
- Exacoustos C, Brienza L, Di Giovanni A, Szabolcs B, Romanini ME, Zupi E and Arduin D (2011):** Adenomyosis: three-dimensional sonographic findings of the junctional zone and correlation with histology, *Ultrasound Obstet Gynecol.*, 37: 471–479.
- Reuter K (2013):** <http://emedicine.medscape>.
- Sakhel K and Alfred Abuhamad (2012):** Sonography of Adenomyosis, *J Ultrasound Med*; 31:805–808.
- Reinhold C, Tafazoli F, Mehio A, Wang L, Atri M, Siegeiman ES, and Rohoman L., (1999):** Uterine adenomyosis: endovaginal US and MR imaging features with histopathologic correlation. *Radiographics*, 19: 147–160.
- Hauth EA, Jaeger HJ, Libera H, Lange S and Forsting M (2007):** MR imaging of the uterus and

- cervix in healthy women: determination of normal values. *Eur. Radiol.*, 17: 734-742.
16. **Hulka CA, Hall DA, McCarthy K and Simeone J (2002):** Sonographic findings in patients with adenomyosis: can sonography assist in predicting extent of disease? *AJR Am J Roentgenol.*, 179: 379-383.
  17. **Naftalin J and Jurkovic D (2009):** The endometrial-myometrial junction: a fresh look at a busy crossing. *Ultrasound Obstet Gynecol.*, 34: 1-11.
  18. **Meredith SM, Sanchez-Ramos L, Kaunitz AM (2009):** Diagnostic accuracy of transvaginal sonography for the diagnosis of adenomyosis: systematic review and metaanalysis. *Am J Obstet Gynecol.* ,201(1):107.e1-6. doi: 10.1016/j.ajog.2009.03.021.
  19. **Bazot M, Cortez A, Darai E et al. (2001):** Ultrasonography compared with magnetic resonance imaging for the diagnosis of adenomyosis: correlation with histopathology. *Hum Reprod.*, 16:2427 –2433.
  20. **Ya-min C, Chen Y, Hsu Y, Yueh-Chin Cheng, Ming-Jenn Chen, Yi-Chiang Hsu (2012):** Preoperative three-dimensional power Doppler ultrasonographic evaluation of adenomyosis and uterine leiomyoma, *Digest Journal of Nanomaterials and Biostructures*, 7 (2): 621 – 627.
  21. **Elkattan E, Kamel R, Elghazaly H, ElAriki E. (2015):** Can Three-dimensional (3D) power Doppler and uterine artery Doppler differentiate between fibroids and adenomyomas, *21(1):* 46-51.
  22. **Graziano A, Lo Monte G, Piva I, Caserta D, Karner M, Engl B, Marci R Eur Rev Med Pharmacol Sci (2015)** Diagnostic findings in adenomyosis: a pictorial review on the major concerns, *19(7):*1146-54.
  23. **Andres M, Borrelli G, Ribeiro J, Baracat E, Abrão M (2017):** Transvaginal Ultrasound for the Diagnosis of Adenomyosis: Systematic Review and Meta-Analysis, *J Minim Invasive Gynecol.*,30: S1553-4650.
  24. **Gaafar HM, Ogila AI, Shehata MH, Taher AM, Ibrahim MF (2014):** Accuracy of 3D ultrasound in diagnosing uterine pathology in patients with premenopausal bleeding. *Ultrasound in Obstetrics & Gynecology*, 44 (1): 181–369.
  25. **Luciano DE, Exacoustos C, Albrecht L, LaMonica R, Proffer A, Zupi E, Luciano AA (2013):** Three-dimensional ultrasound in diagnosis of adenomyosis: histologic correlation with ultrasound targeted biopsies of the uterus, *J Minim Invasive Gynecol.*, 20(6):803-10.
  26. **Ahmadi F, and Haghghi H (2013):** Three-dimensional ultrasound manifestations of adenomyosis, *Iran J Reprod Med.*, 11(10): 847–848.
  27. **Stamatopoulos C, Mikos T, Grimbizis G, Dimitriadis A, Efstratiou I, Stamatopoulos P, and Tarlatzis B (2012):** Value of Magnetic Resonance Imaging in Diagnosis of Adenomyosis and Myomas of the Uterus, *19(5):* 620–626.
  28. **Moghadam R, Lathi RB, Shahmohamady B, Saberi NS, Nezhat CH, Nezhat F, Nezhat C (2006):** Predictive value of magnetic resonance imaging in differentiating between leiomyoma and adenomyosis. *JSLs.*,10:216–219.
  29. **Sofic A, Husic-Selimovic A, Carovac A, Jahic E, Smailbegovic V and Kupusovic J (2016):** The Significance of MRI Evaluation of the Uterine Junctional Zone in the Early Diagnosis of Adenomyosis, *Acta Inform Med.*, 24(2): 103–106.
  30. **Novellas S, Chassang M, Delotte J, Toullalan O, Chevallier A, Bouaziz J, Chevallier P (2011):** MRI characteristics of the uterine junctional zone: from normal to the diagnosis of adenomyosis. *Am J Roentgenol.*, 196(5):1206-13.
  31. **Dueholm M, Lundorf E, Hansen ES, Ledertoug S, Sorensen JS, Olesen F (2001):** Magnetic resonance imaging and transvaginal ultrasonography for diagnosis of adenomyosis. *Fertil Steril.*, 76: 588–594.
  32. **Reinhold C, McCarthy S, Bret PM, Mehio A, Atri M, Zakarian R, Glaude Y, Liang L, Seymour RJ (1996):** Diffuse adenomyosis: comparison of endovaginal US and MR imaging with histopathologic correlation. *Radiology*, 199: 151–158.
  33. **Ascher SM, Arnold LL, Patt RH, Schrufer JJ, Bagley AS, Semelka RCR, et al (1994):** Adenomyosis: prospective comparison of MR imaging and transvaginal sonography. *Radiology*, 190:803–806.