

Effect of Chronic Stress on The Testis of The Adult Male Albino Rat and The Role of Ginger

Hadeer Abd El-Mohsen El-Naggar, Fatma El-Nabawia A. El-Safty,
Abeer E. El-mehi, Ayman Abdallah Reafie

Department of Anatomy and Embryology, Anatomy Department, Menoufia University, Menoufia, Egypt

*Corresponding author: Hadeer Abd El-Mohsen El-Naggar, Mobile: 01005537800, E-mail: haderel naggar@yahoo.com

ABSTRACT

Background: Infertility and its problems are one of the most vital problems that ranges from 10% to 15% among couples. Chronic variable stress (CVS) disrupts normal homeostasis of a variety of body systems and is a major cause of male infertility. Ginger is known to have anti-inflammatory and antioxidant properties via its free radical scavenging activity so it can be used in various experimental models as a protective agent against various toxicants.

Objectives: The current work aimed to study the effect of chronic variable stress on the testis and the possible protective and therapeutic roles of the ginger on this effect. **Materials and Methods:** thirty-five adult male albino rats were divided into five groups. Group I; control, group II received ginger only, group III subjected to CVS, group IV CVS + pretreated with ginger and group V CVS + post-treated with ginger. All rats were weighted, sacrificed, blood samples collected to assess testosterone hormone, the testis was weighted to calculate gonadosomatic index and processed for light microscopic study. Paraffin sections were stained by hematoxylin and eosin stain. Immunohistochemical staining for PCNA, caspase-3 and androgen receptor were also performed. **Results:** CVS induced decreased gonadosomatic index, testosterone hormone level, destructive effects on the testis as decreased spermatogenic cells and sperm count, detachment of the cells, vacuolations and apoptosis. Ginger produced great improvement of these effects which was pronounced in the protected group (IV) than the treated one (V). **Conclusion:** CVS caused apoptotic changes in testis and ginger had ameliorating effects on these changes.

Keywords: CVS, testicular apoptosis, Ginger.

INTRODUCTION

Stress is defined as a basic or perceived threat to the homeostasis of an organism ⁽¹⁾. Chronic variable stress (CVS) is a major problem of the modern life, which led to changes in endocrine and reproductive functions along with the central and peripheral nervous systems ⁽²⁾. Male fertility depends on the production of a large number of spermatozoa by spermatogenesis ⁽³⁾. Spermatogenesis is essential for sexual reproduction. This process depends on pituitary gonadotropins, follicle stimulant hormone (FSH) and luteinizing hormone (LH) ⁽⁴⁾ as well as adequate testosterone concentrations ⁽⁵⁾. Both acute and chronic stress ⁽⁶⁾ are able to cause disruption of male reproduction. Aside to the increase in adrenal corticosteroids ⁽⁷⁾, chronic stress induces suppression of testosterone secretion, libido and spermatogenesis in males ⁽⁸⁾, thus lowering fecundity in men ⁽⁹⁾. Ginger (*zingiber officinale*) is one of the most popular food spices known among Asian and African people for long periods ⁽¹⁰⁾. It includes versatile range of active constituents such as volatile oils, proteolytic enzymes, vitamins, and trace elements ⁽¹¹⁾. These constituents gave ginger the priority to be used in many diseases as anti-inflammatory and antioxidant modulator ⁽¹²⁾. The strong antioxidant and protection abilities of ginger to biological tissues and cell membrane lipids against toxicity occur via free radical scavenging activity in a dose dependent manner ⁽¹³⁾. So, this increases its tendency to be used in various experimental models as a protective agent against various toxicants ⁽¹⁴⁾. So, we decide to study the effect

of chronic variable stress on the testis of the adult male albino rats and the possible protective and therapeutic roles of the ginger on this effect.

MATERIALS AND METHODS

Animals: male rats (35 animals, 200±20 grams B. wt.) obtained from... Theodor bilharz animal house, Cairo, Egypt and housed at room temperature and had free access of diet and tap water. Strict care and hygiene were provided to keep them in normal and healthy conditions under the guidelines recommended by ethical committee for animal research, Faculty of medicine Menoufia University.

Experimental substances:

Ginger (*zingiber officinal*): was obtained from Arab Co. for Pharmaceuticals and Medicinal Plants "MEPACO-MEDIFOOD", Egypt. It was available as tablets (each tablet contained 400 mg ginger extract) stored at temperature not exceeding 30 C°

Stress method:

The cages of stressed rats were transferred to another room for stress. The order of the cages being taken to the stressor area was random and balanced from day to day. The stressors were applied at the onset of the dark phase of the cycle to avoid circadian variations of corticosterone.

Stress by immersion in cold water (ICW): Rats were placed individually in a covered tank of cold water (depth = 15.5 cm; temperature = 15°C), where they were either swimming or remaining in an upright



This article is an open access article distributed under the terms and conditions of the Creative Commons Attribution (CC BY-SA) license (<http://creativecommons.org/licenses/by/4.0/>)

position, standing on their hind limbs, and keeping their head above water level. This situation lasted for 15 min. After this time, rats were picked up from water and towel dried. This procedure involves the combination of two well-known physical stressors: cold (15°C) and immersion in water. Thus, the additive components of the two stressful situations, and the duration of the exposure to this stressor was enough to cause an intense response of adrenal axis⁽¹⁵⁾. Male rats from control groups remained undisturbed in their home cages throughout the experiment and were maintained away from stressed males. This procedure was conducted at Theodor Bilharz Research Institute, Cairo, Egypt.

Experimental design:

Thirty-five rats were divided equally into five experimental groups:

- **Group I: (Control):** Consisted of 7 adult male albino rats that kept without any medications and under normal circumstances.
- **Group II: (Ginger only)** Consisted of 7 adult male albino rats that received daily oral dose of ginger (1000 mg/kg) for 50 days and were kept under normal circumstances. According to the guidelines for animal research approved by Ethical Committee of the Faculty of Medicine, Menoufia University, Egypt and in accordance with the guidelines of the US National Institutes of Health on animal care.
- **Group III: (Chronic variable stress)** Consisted of 7 adult male albino rats that were subjected to chronic variable stress for 30 days and received no medications.
- **Group IV: (Chronic variable stress pretreated with ginger)** Consisted of 7 adult male albino rats that received daily oral dose of ginger (1000 mg/kg) for 20 days then were subjected to chronic variable stress for the following 30 days with receiving the same daily oral dose of the ginger (1000 mg/kg).
- **Group V: (Chronic variable stress post-treated with ginger)** Consisted of 7 adult male albino rats that were subjected to chronic variable stress for 30 days and receiving daily oral dose of ginger (1000 mg/kg) at the same time and also for the following 20 days after the end of CVS period.

At the end of the experimental period (50 days), Rats were anaesthetized, weighted, blood samples were collected from the retro-orbital venous plexus then killed by cervical dislocation. The abdomen and scrotum of each animal were opened by a scissor and testes were extracted, weighted and fixed in 10% neutral buffered formalin.

Methods:

1-General measures: The gonadosomatic index (GSI) was calculated (testis weight / body weight x 100)⁽¹⁶⁾.

2-Biochemical assays: The collected blood samples were centrifuged, and plasma was used for hormonal assay to measure serum testosterone hormone level.

3-Histological study: Specimens were fixed in 10% formol saline for 24h and were processed to prepare 5-µm-thick paraffin sections for the following:

- **Hematoxyline - eosin staining** for routine histological examination⁽¹⁷⁾.

4-Immunohistochemical studies: poly-L-lysine coated slides sections were deparaffinized and rehydrated. They were inserted in 3% hydrogen peroxide for blocking the endogenous peroxidase. Microwave antigen retrieval procedure was done. The sections then were incubated in the following antibodies:

- **Proliferating Cell Nuclear Antigen (PCNA)** for quantitatively analyze spermatogenesis⁽¹⁸⁾.
- **Anticaspase-3** for detection of the rate of apoptosis⁽¹⁹⁾.
- **Androgen Receptors (AR)** for Localization of AR expression⁽²⁰⁾.

5-Morphometric study:

Data were obtained from five different sections from each rat of all subgroups and examined using the interactive measuring menu of image analyzer software (**Image J analyzer version 1.43o8, National Institutes of Health, USA and Digimizer version 4.3.5, MedCalc software**) at Anatomy and Embryology Department, Faculty of Medicine, Menoufia University to determine:

- 1- The height of the germinal epithelium in the H&E x 400 stained sections.
- 2-The number of the immune positive cells in PCNA immunohistochemical stained sections.

Statistical analysis

Statistical analysis was performed for the gonadosomatic index (testis weight / body weight x 100) and the hormonal assay of serum testosterone and the data obtained from morphometric study and presented in mean ±SD SPSS 20 (Statistical Package for the Social Sciences, version 20, SPSS Inc, Chicago, Illinois, USA) to analyze the data. Dual comparisons between groups exhibiting significant values were evaluated with a Mann-Whitney U test. These differences were considered significant when probability was less than 0.05.

RESULTS

All outcomes of this study showed non-significant differences between subgroup I (control) and subgroup II (ginger only). Therefore, these two groups were pooled in one control group.

- **General results:** In our study, stressed animals (group III) showed a significant decrease in the GSI as compared to control group. Ginger administration produced an increase in GSI in both groups IV and V but more significant in the pretreated (group IV) than the post-treated (group V). (**Table 1**)
- **Biochemical results:** Testosterone hormone was significantly decreased in the CVS (group III) but there was significant increase with ginger administration in groups IV and V. The level of the

hormone was higher in the pretreated group IV than the post-treated group V. (Table 2)

Table (1): Statistical comparison between studied groups as regards GSI.

	Studied groups Mean ± SD					Mann Whitney U	P Value	Sig.
	Group I	Group II	Group III	Group IV	Group V			
GSI						0.12 #	0.24	NS
	3.12±	3.00 ±	1.85 ±	3.00 ±	2.85 ±	1.27 ##	0.001	S
	0.26	0.14	0.19	0.14	0.12	1.15 ###	0.001	S
						1.00 ####	0.001	S

= comparison between group (I) & group (II) . **S** = significant
 ## = comparison between group (I) & group (III). **NS** = non significant
 ###=comparison between group (III) & group (IV).
 #### =comparison between group (III) & group (V).

Table (2): Statistical comparison studied groups as regards serum testosterone hormone level.

	Studied groups Mean ± SD					Mann Whitney U	P Value	Sig .
	Group I	Group II	Group III	Group IV	Group V			
Testosterone hormone						0.07 #	0.78	NS
	6.62±	6.55 ± 0.42	1.83 ±	6.23 ±	4.90 ± 0.47	4.78 ##	0.01	S
	0.43		0.26	0.46		4.40 ###	0.01	S
						3.07 ####	0.01	S

= comparison between group (I) & group (II) . **S** = significant
 ## = comparison between group (I) & group (III) . **NS** = non-significant
 ###=comparison between group (III) & group (IV) .
 #### =comparison between group (III) & group (V) .

Histological results

The testes of the control rats (group I) showed that the testis was formed of many seminiferous tubules separated from each other by narrow interfollicular spaces. Each tubule surrounded by well-defined basal lamina, lined by stratification of spermatogenic cells and Sertoli cells with mature spermatozoa in the lumen. Clusters of the interstitial cells of Leydig with acidophilic cytoplasm were found in the triangular areas between the seminiferous tubules (Fig. 1).

Histological examination of the CVS group (III) showed massive destructive changes including distortion of the seminiferous tubules with loss of germ cells. Spermatogenic cells showed apoptotic figures as pyknotic nuclei and degenerated ones, decreased height of seminiferous epithelium, total absence of spermatozoa in some tubules, cytoplasmic vacuolations of spermatogenic cells and detachment of

the germ cells from the basement membrane in some tubules. The interstitial tissue contained dilated congested blood vessel and showed vacuolation, hyalinized acidophilic material and degeneration of the interstitial Leydig cells with deeply stained pyknotic nuclei (Fig. 2).

The testicular sections obtained from the pretreated group (IV) showed improvement of the general architecture. Most tubules were more or less similar to that of control and they were lined by normally arrangement spermatogenic cells with numerous mature spermatozoa in their lumen. In spite of the apparent increase of the spermatogenic cell layers, some cells had vacuolated cytoplasm. The inter-tubular space remained wide and contained acidophilic material (Fig. 3). The post-treated group (V) also showed improvement but less pronounced than the treated group (Fig. 4)

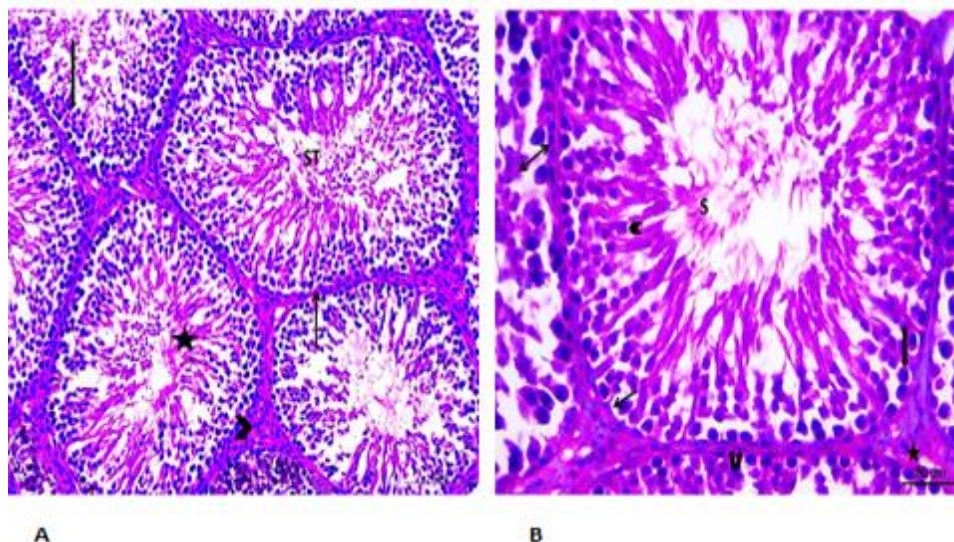


Fig. (1): A photomicrograph of the testis of group I (A): showing rounded to oval seminiferous tubules (ST) with normal alignment and regular basal lamina (Arrow) and contain normal germ cell layers (Notched arrow) and mature sperms (Star) in the lumen. Fine interstitial tissue in between the seminiferous tubules (Arrowhead) (Hx. &E. X200) (B): showing a seminiferous tubule containing different stages of spermatogenic cells; Spermatogonia (Double head arrow), primary spermatocytes (Block arrow), spermatides (Arrow head) and the Sertoli cells (Arrow) in between. Numerous mature spermatozoa (S) appear in the lumen. The myoid cells (Curved arrow) are arranged outside the basal lamina. Numerous interstitial Leydig cells in between the tubules (Star) (Hx. &E. X400).

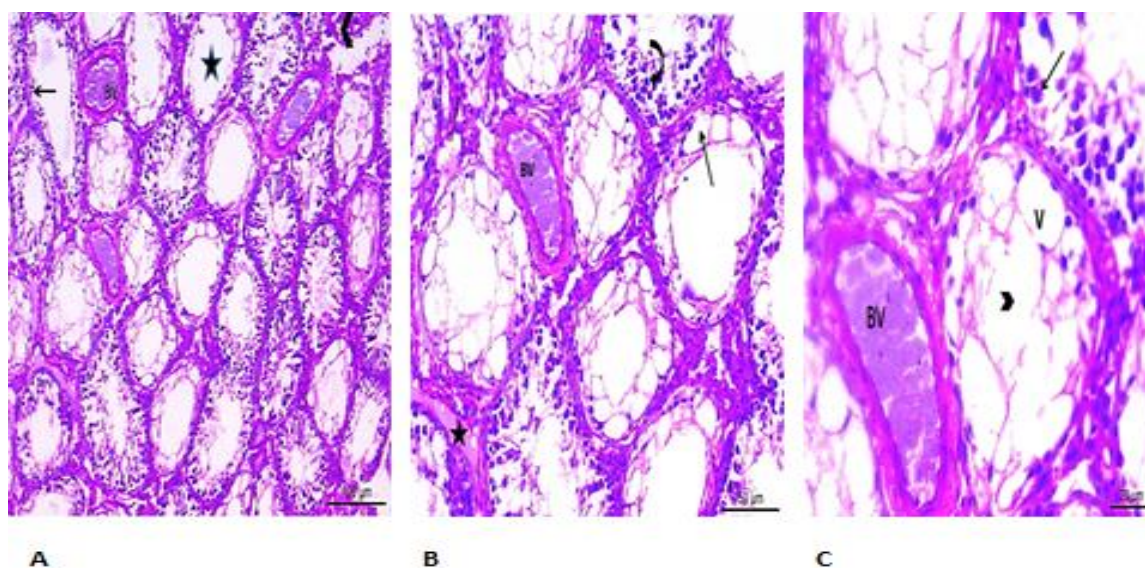


Fig. (2): A photomicrograph of group III (A): showing distortion of the seminiferous tubules (Arrow head) with loss of germ cells (Arrow), loss of sperms (star) and congested blood vessel (BV) (Hx. &E. X100) (B): A higher magnification showing degeneration of the germ cells (curved Arrow) with vacuolation (Arrow). Homogenous acidophilic material appear inbetween the tubules (star) with vacuolations in the interstitial cells of Leydig (Line) (Hx. &E. X200) (C): A higher magnification showing degenerated germ cells (Arrow) with vacuolation (V). The lumen of the tubules contains no sperms (Arrow head). Also there is congested blood vessels (BV) (Hx. &E. X400).

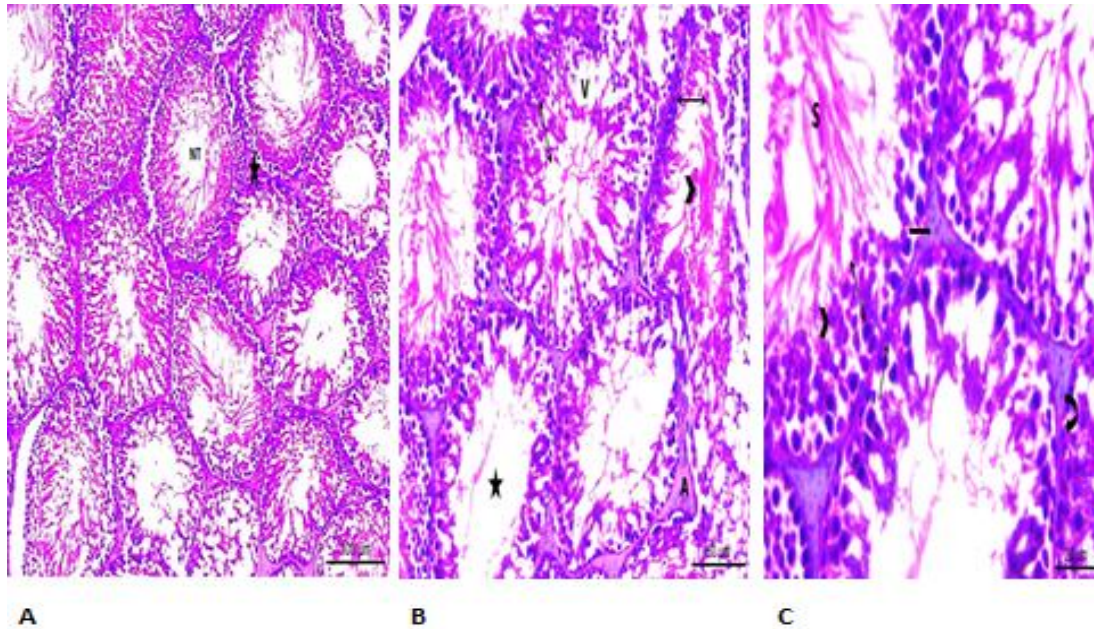


Fig. (3): A photomicrograph of group IV (A): showing multiple seminiferous tubules with regular outline (NT) and normal spermatogenic cells. Normal alignment between the tubules (Star) (Hx. &E. X100) (B): showing multiple oval to rounded seminiferous tubules with abundant number of spermatogenic cells (Double head arrow) with numerous mature sperms (Arrow head). A few degenerations in the tubules as vacuolations (V). Few numbers of tubules contain no sperms (Star). A slight acidophilic material between the tubules (A) (Hx. &E. X200). (C): A higher magnification shows several layers of the spermatogenic cells at different stages; Spermatogonia (Arrow), primary spermatocytes (Double head arrow), spermatids with vacuolated cytoplasm (Arrow head) and the Sertoli cells (Curved arrow) in-between. Numerous mature spermatozoa (S) appear in the lumen. The interstitial spaces contain interstitial Leydig cells (Notched arrow) (Hx. &E. X400).

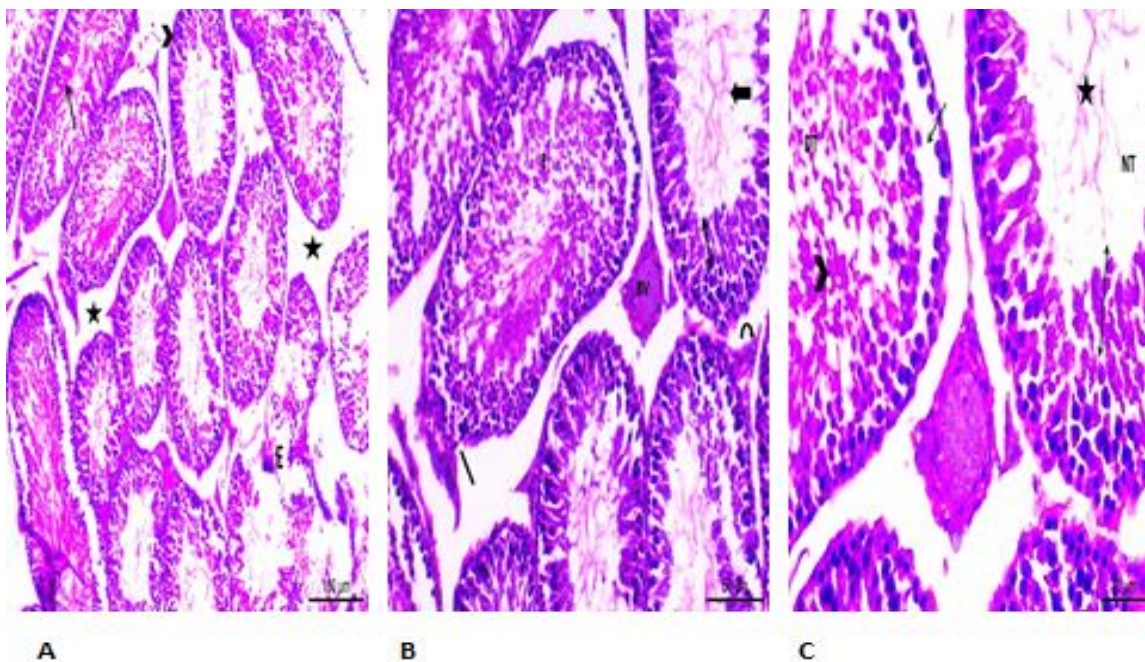


Fig. (4): A photomicrograph of group V (A): showing few distorted seminiferous tubules (E) while most of the tubules are rounded with regular outline (Arrow head) and normal spermatogenic cells (Arrow). The space between the tubules appears wide (Star) (Hx. &E. X100) (B): A higher magnification shows some tubules appear normal with abundant number of spermatogenic cells (Double head arrow) and a moderate amount of spermatozoa (Arrow). While other tubules show detached basal lamina (Line) and exfoliation of the cells in the lumen (E). A slightly congested blood vessel (BV) and a moderate number of interstitial Leydig cells (Curved arrow) (Hx. &E. X200) (C): A higher magnification shows a normal tubule (NT) contains abundant number of spermatogenic cells (Double head arrow) and few numbers of spermatozoa (Star). Another abnormal tubule (DT) show detached cells (Arrow) from the basal lamina and many cells in the center (arrow head) (Hx. &E. X400).

Immunohistochemical results:

PCNA positive cells are those showing proliferative ability in the cell cycle. The control rats showed intense positive PCNA immunostaining (deep brown nuclear reaction) in all nuclei of basal germ cells while sections from the stressed group (III) showed few positive PCNA immunostaining. The pretreated group (IV) showed significant increase in number of PCNA positive cells than the stress group. This increase was a little decreased in post-treated group (V) (**Fig.5**). Control group showed a negative immunoreactivity for Caspase-3 in the germinal epithelium and interstitial cells while there was intense positive caspase-3 immunostaining in the cytoplasm and some nuclei of the CVS group (III). The pretreated group (IV) showed weak immunoreactivity for Caspase-3 but the post-treated (V) group showed higher reactivity to caspase-3 than group IV (**Fig.6**). Androgen receptor (AR) immune-expression was evident in control group, negative in CVS group, strong positive in the pretreated group and weak positive in the post-treated group (**Fig.7**).

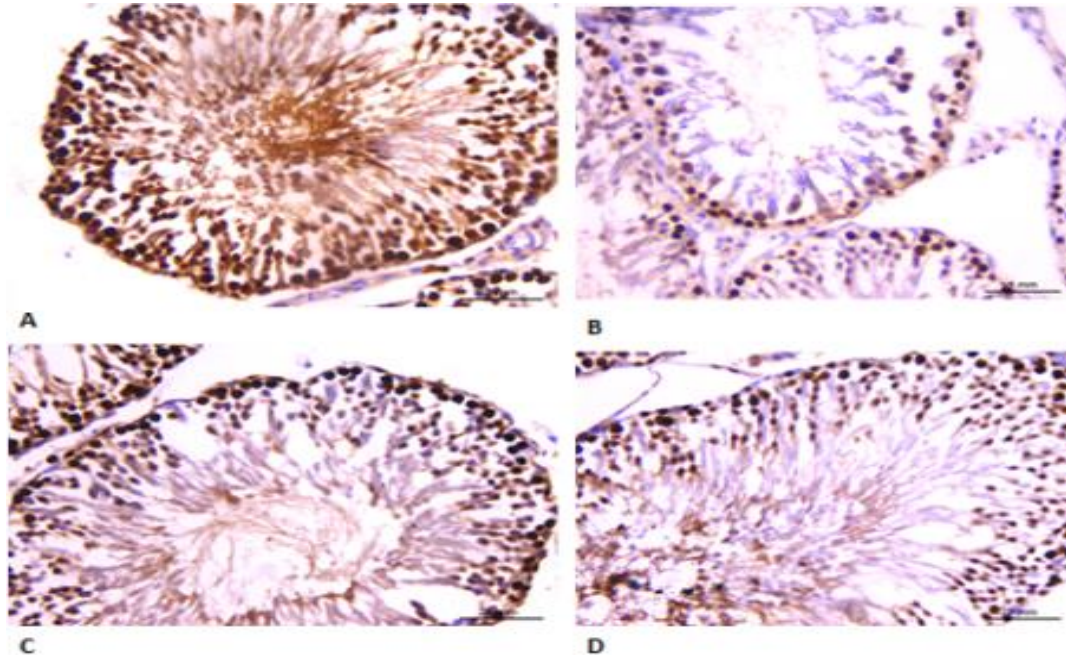


Fig. (5): Proliferating Cell Nuclear Antigen (PCNA) activity, X400

(A): group I showing positive PCNA immunostaining (deep brown nuclear reaction) in most nuclei of the basal germ cells inside the seminiferous tubules (B): group III showing degenerated seminiferous tubules with very few positive PCNA immunostaining in the basal layer of germ cells (C): group IV showing seminiferous tubules with multiple positive PCNA immunostaining of the nuclei of the germ cell (D): group V showing some positive PCNA immunostained germ cells.

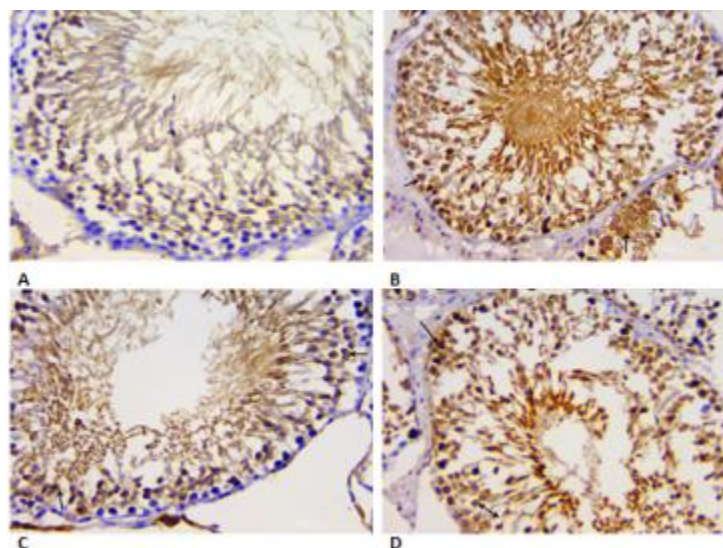


Fig. (6): Caspase-3 activity X400

(A): group I showing negative cytoplasmic immunostaining for caspase-3 (B): group III showing intense positive caspase-3 immuno-staining (deep brown) in the cytoplasm of spermatogonia and other spermatogenic cells (**arrow**) (C): group IV showing weak cytoplasmic caspase-3 immunostaining in some germ cells (**arrow**) (D): group V showing some cells with intense positive cytoplasmic caspase-3 immunostaining (**arrow**).While others show weak cytoplasmic immunostaining (**double head arrow**).

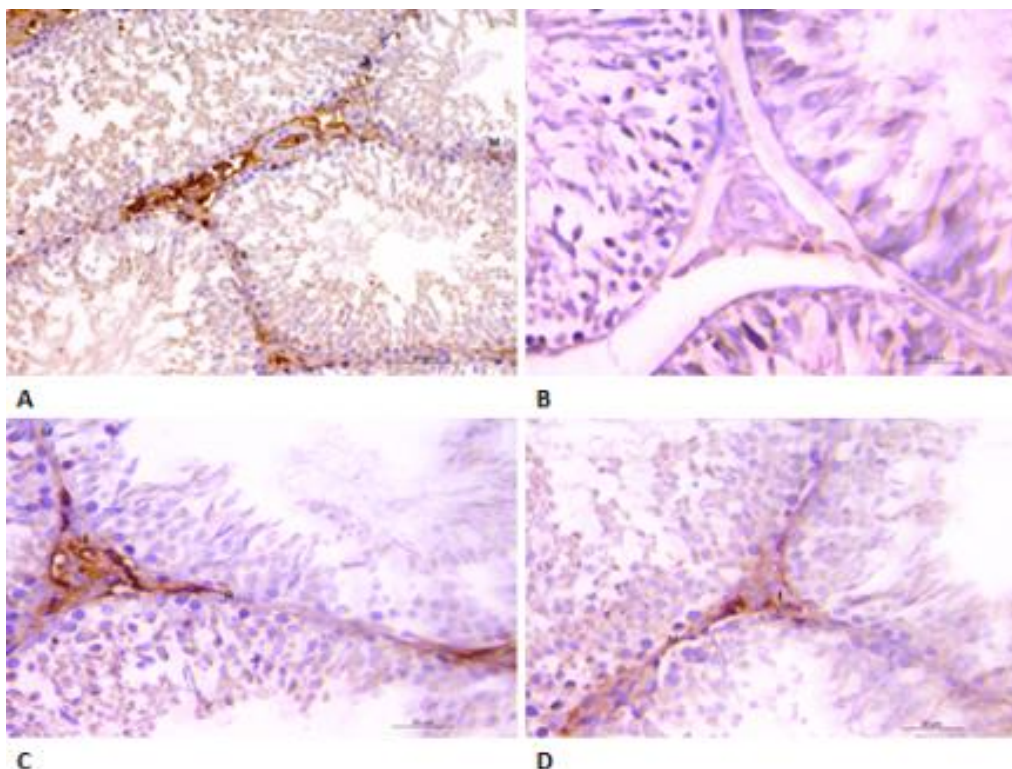


Fig. (7): Androgen Receptors (AR) X400

(A): group I showing intense androgen receptor nuclear immune-expression (brown nuclear staining) in the interstitial cells (I), myoid cell (M) and some Sertoli cells(R) (B): group III showing negative immune-expression of androgen receptors (C): group IV showing intense androgen receptor nuclear immune-expression in the interstitial cells (I) and myoid cells (M) but weak in Sertoli cells (R) (D): group V showing weak androgen receptor nuclear immune-expression in the interstitial cells (I) and myoid cell (M).

Morphometric results and statistical analysis:

a- The height of the germinal epithelium in the H&Ex400 stained sections:

The height of the germinal epithelium was significantly decreased in group III (CVS) compared with group I (control) (9.18 ± 0.58 vs. 41.20 ± 1.30 ; $P < 0.05$).

Ginger co-treatment, there were a significant increase in the height of the germinal epithelium in group IV (pretreated) compared to group III (CVS) (39.60 ± 0.96 vs. 9.18 ± 0.58 ; $P < 0.05$) and a significant increase in group V (post-treated) compared to group III (CVS) (23.60 ± 0.65 vs. 9.18 ± 0.58 ; $P < 0.05$) (Table 3).

b- The number of the immune positive cells in PCNA immunohistochemical stained sections:

The number of the immune positive PCNA cells was significantly decreased in group III (CVS) compared with group I (control) (82 ± 2.1 vs. 252 ± 1.9 ; $P < 0.05$).

Ginger co-treatment, there were a significant increase in the number of the immune positive PCNA cells in group IV (pretreated) compared to group III (CVS) (250 ± 0.8 vs. 82 ± 2.1 ; $P < 0.05$) and a significant increase in group V (post-treated) compared to group III (CVS) (202 ± 1.9 vs. 82 ± 2.1 ; $P < 0.05$) (Table 4)

Table (3): Statistical comparison between studied groups as regards the height of the germinal epithelium in H&E stained sections.

	Studied groups					Mann Whitney U	P Value	Sig .
	Mean \pm SD							
Height of epithelium	Group I	Group II	Group III	Group IV	Group V	0.00 # 32.02 ## 30.42 ### 14.42 ####	1.00 0.01 0.01 0.01	NS S S S
		41.20 ± 1.30	41.20 ± 1.30	9.18 ± 0.58	39.60 ± 0.96			

= comparison between group (I) & group (II). S = significant
= comparison between group (I) & group (III). NS = non-significant
= comparison between group (III) & group (IV).
= comparison between group (III) & group (V).

Table (4): Statistical comparison between studied groups as regards the number of the positive immune PCNA cells.

	Studied groups					Mann Whitney U	P Value	Sig.
	Mean ±SD							
+ve immune PCNA cells	Group I	Group II	Group III	Group IV	Group V	0.20 # 169.8 ## 167.8 ### 119.8 ####	0.86 0.01 0.01 0.01	NS S S S
		252 ± 1.9	252 ± 1.8	82 ± 2.1	250 ± 0.8			

= comparison between group (I) & group (II) . S = significant

= comparison between group (I) & group (III) . NS = non significant

###=comparison between group (III) & group (IV) .

=comparison between group (III) & group (V)

DISCUSSION

In the current study, chronic variable stress (CVS) was particularly chosen as it was confirmed by many studies that CVS disrupt normal homeostasis on a variety of body systems. CVS is known as an endocrine disruptor, it can influence the pituitary-testicular axis ⁽²¹⁾. CVS is also a major cause of male infertility following changes, such as decreased sex hormones, delayed ejaculation, low sexual desire, and low sperm quality ⁽⁶⁾.

Ginger was chosen in this study as it has various pharmacological activities such as antiemetic, antiulcer, anti-inflammatory, antioxidant, antiplatelet, glucose- and lipid-lowering, cardiovascular and anti-cancer activities ⁽²²⁾. The rich phytochemistry of ginger includes components that scavenge free radicals produced in biological systems ⁽²³⁾.

This work was carried out to evaluate the possible effect of ginger on testicular tissue damage induced by chronic variable stress .Also for evaluating the possibility of recovery after stopping treatment. Animals were subjected to chronic variable stress by immersion in cold water (ICW) according to ⁽¹⁵⁾ for a period of 30 days as mentioned by ⁽⁸⁾. Ginger was administrated in a dose of 1000 mg/kg per day according to ⁽²⁴⁾.

Concerning the general results, the present study showed a highly significant decrease of gonadosomatic index in rats subjected to CVS as compared to control group. These results were in harmony with others investigators as ⁽²⁵⁾ who attributed this to corticotropin releasing hormone CRH; a side to its role as the principal hypothalamic regulator of the adrenal axis, it is a major anorexigenic peptide, being responsible for appetite suppression and feeding behavior in stressed rats.

In the present study, the biochemical findings showed that CVS lead to a highly significant decrease in testosterone hormone level when compared with the control level that was explained by ⁽²⁶⁾ as excessive

exposure to glucocorticoids initiates apoptosis in Leydig cells, potentially contributing to the suppression of testosterone level caused by the decline in steroidogenic capacity.

In the current study, the results of androgen receptor immune-expression are further supporting the biochemical result of testosterone hormone. Our results showed that stressed testis revealed negative immune-expression of androgen receptor. This could be explained as disruption of testosterone level leads to negative immune-expression of androgen receptor.

This result also explained by ⁽²⁷⁾ reporting that androgen replacement in ethane dimethane sulfonate (EDS) (which induces higher serum FSH and LH concentrations to suppress endogenous testosterone) treated animals leads to the return of AR immune-staining, back to approximately 75% of the normal level.

As regards the histopathological changes of testes of the stress group: concerning the seminiferous epithelium, CVS has found to cause injurious effects on the testicular tissue including many degenerated spermatogenic cells, decreased frequency of cells with significant decrease in the height of the seminiferous epithelium, most of the cells showed apoptotic signs as pycnotic degenerating nuclei with condensed chromatin. This increased level of apoptosis in stressed animals could be due to decreased testosterone hormone level.

This finding (apoptosis) is in agreement with ⁽²⁸⁾ who states that apoptosis in germ cells can be caused by acute or chronic stress.

This finding explained as the decrease in testosterone in chronically stressed males may promote the apoptotic extrinsic pathway via Fas, through specific signaling pathways in Sertoli cells according to ^(28, 29) and also added that intrinsic apoptotic way, through Bax and Bcl2, has been also involved in

testicular germ cell apoptosis, associated to testosterone decrease in chronically stressed males.

In the present study, this pathological finding (apoptosis) was confirmed also by the results of caspase-3 immunostaining which revealed that CVS increased expression of caspase-3 in spermatogenic cells and Leydig cells. This agreed with⁽³⁰⁾ explaining this as both intrinsic and extrinsic signaling pathways are involved in testicular germ cell apoptosis during chronic stress, converging at caspase-3 activation that is tightly associated with DNA fragmentation.

In the current study, it was observed detachment of degenerated germinal cells into the tubular lumen. This could be due to decrease in testosterone hormone level, since this androgen is essential for the conversion of round spermatids and completion of the spermatogenic cycle. This finding was in agreement with⁽³¹⁾ explained this as testosterone decrease prevents the elongation process of round spermatids during spermiogenesis and causes germinal cell loss.

Cytoplasmic vacuolation and degeneration recorded in the present study could be considered as a sign of cell necrosis, in coincidence with⁽³²⁾ who reported that vacuoles appearing in the seminiferous tubules are most probably representing phagocytic vacuoles remaining after the digestion of the necrotic germ cells.

Additionally, this work showed a decrease in spermatozoa and empty tubules in stress group. This in agreement with⁽³³⁾ who attributed this to defective spermatogenesis.

In the present study, concerning the interstitial cells of Leydig:

Stress has found to cause degeneration, vacuolation and pyknosis. All these findings are signs of apoptosis which could be due to increased glucocorticoids in stressed animals. This finding in agreement with⁽²⁶⁾.

In the present study, PCNA immunostaining of stressed testis (group III) demonstrated few positive immunostaining basal spermatogenic cells with a highly significant decrease as compared with control group. This finding indicates DNA damage, in agreement with⁽³⁴⁾ who stated that PCNA in the testis decreased significantly in the rats stressed for 14 and 21 days.

A few number of studies evaluated the beneficial role of the ginger in dealing with side effects of stress. The current study showed a great improvement in all parameters used with the administration of ginger in stressed rat models. Group IV (pretreated) and group V (post-treated) showed a highly significant improvement as compared to group III (CVS). Also the improvement more pronounced in the protected group IV (pretreated) than the treated group V (post-treated).

In our study, the general results showed a significant increase of GSI in both groups IV and V as

compared with control. This in agreement with⁽³⁵⁾ who stated that oral administration of an aqueous extract of ginger at dose of 600 mg/kg for 8 days significantly increased the relative weight of the testis in Wistar rats, suggesting androgenic activity of ginger.

The biochemical study revealed a significant increase in testosterone hormone level with administration of ginger in both groups IV and V as compared with control. This finding in agreement with⁽³⁵⁾ who stated that supplementation of ginger at 600 mg/kg for eight days increases serum testosterone explaining this finding as ginger supplementation increase the level of testicular cholesterol which could be a seminal factor behind the increased testosterone production.

In our study, the biochemical finding was confirmed by the results of AR immune-expression. Ginger showed positive AR immune-expression in both groups IV and V. This is supported by the finding of⁽³⁶⁾ who stated that immune-expression of AR significantly increased in the diabetic rats treated with ginger.

Histologically, the present study showed great improvement in the structure of the stressed testes with administration of ginger in both groups IV and V. Where, seminiferous tubules surrounded by regular basal lamin, rows of normally arrangement spermatogenic cells with numerous mature spermatozoa in their lumen were noticed. It showed a significant increase in the height of the seminiferous epithelium and normal intertubular space with abundant number of interstitial cells of Leydig.

These improved histological findings could be explained as ginger has strong androgenic effect and powerful antioxidant effect.

This explanation was supported by⁽³⁵⁾ stated that oral administration of an aqueous extract of ginger at dose of 600 mg/kg for 8 days significantly increased the relative weight of the testis, testosterone hormone in Wistar rats suggesting androgenic activity of ginger and also by⁽³⁷⁾ stating that ginger is a strong antioxidant substance and may either mitigate or prevent generation of free radicals and significantly lowered lipid peroxidation by maintaining the activities of the antioxidant enzymes –superoxide dismutase, catalase and glutathione peroxides in rats.

These histological findings were supported by the results of caspase-3 immunostaining. Our study revealed that ginger decreased expression of caspase-3 in spermatogenic cells and Leydig cells in both groups IV and V. That was in agreement with⁽³⁸⁾ who stated that ginger's constituents increased the anti-apoptotic proteins such as Bcl-2 which declined apoptotic proteins like caspase-3.

In the present study, ginger has found to cause a significant increase in PCNA immune-expression in both groups IV and V. This finding was confirmed by⁽³⁶⁾ who stated that ginger increased PCNA immune-

expression with the appearance of many spermatocytes in mitotic stages in the diabetic rats.

In our study, all parameters (GSI, testosterone hormone, histopathological, immunohistochemical) in the stressed rat testes were improved with administration of ginger in a dose of 1000 mg/kg/day. This in agreement with⁽³⁵⁾ but this finding disagree with⁽³⁹⁾ who stated that oral administration of ginger powder at 2000 mg/kg for 35 days slightly but significantly decreased the weight of testes and the ratio of the testis weight to body weight in rats. It would be interesting to further investigate whether long-term administration of ginger powder at higher dosage reduces testicular mass due to a feedback reaction of its androgenic activity.

Conflict of interest: no conflict of interest.

Funds: no funding resources.

REFERENCES

1. **Herman J (2013):** Neural control of chronic stress adaptation. *Frontiers in Behavioral Neuroscience*, 7: 61-65.
2. **McEwen B (2007):** Physiology and neurobiology of stress and adaptation: central role of the brain. *Physiological Reviews*, 87(3): 873-904.
3. **de Kretser D, Loveland K, Meinhardt A et al. (1998):** Spermatogenesis. *Human Reproduction*, 13(1): 1-8.
4. **Hess R, de Franca L (2008):** Spermatogenesis and cycle of the seminiferous epithelium. In, *Molecular Mechanisms in Spermatogenesis*. Ed. Cheng CY. Austin, TX: Landes Bioscience, Pp. 1-15.
5. **O'Donnell L, Meachem S, Stanton P et al. (2006):** Endocrine regulation of spermatogenesis. In *Knobil and Neill's physiology of reproduction*, Academic Press, Pp. 1017-1069.
6. **Wingfield J, Sapolsky R (2003):** Reproduction and resistance to stress: when and how. *Journal of Neuroendocrinology*, 15(8): 711-724.
7. **Nicolaidis N, Kyratzi E, Lamprokostopoulou A et al. (2015):** Stress, the stress system and the role of glucocorticoids. *Neuroimmunomodulation*, 22(1-2): 6-19.
8. **Retana-Márquez S, Viguera-Villaseñor R, Juárez-Rojas L et al. (2014):** Sexual behavior attenuates the effects of chronic stress in body weight, testes, sexual accessory glands, and plasma testosterone in male rats. *Hormones and Behavior*, 66(5): 766-778.
9. **Hjollund N, Bonde J, Henriksen T et al. (2004):** Reproductive effects of male psychological stress. *Epidemiology*, 6: 21-27.
10. **El-Sharaky A, Newairy A, Kamel M et al. (2009):** Protective effect of ginger extract against bromobenzene-induced hepatotoxicity in male rats. *Food and Chemical Toxicology*, 47(7): 1584-1590.
11. **Onwuka F, Erhabor O, Eteng M et al. (2011):** Protective effects of ginger toward cadmium-induced testes and kidney lipid peroxidation and hematological impairment in albino rats. *Journal of Medicinal Food*, 14(7-8): 817-821.
12. **Khaki A, Khaki A (2013):** Antioxidant effect of ginger to prevents lead-induced liver tissue apoptosis in rat. *Journal of Medicinal Plants Research*, 4(14): 1492-1495.
13. **Farag A, Elhalwagy M, Farid H (2010):** Effect of ginger supplementation on developmental toxicity induced by fenitrothion insecticide and/or lead in albino rats. *Pesticide Biochemistry and Physiology*, 97(3): 267-274.
14. **Johari H, Delirnasab F, Sharifi E et al. (2013):** The effects of hydro-alcoholic extract of *Zingiber officinale* on prevention from plumbism in kidney tissue of neonatal rats. *Zahedan J Res Med Sci.*, 15(8): 13-17.
15. **Retana-Márquez S, Domínguez-Salazar E, Velázquez-Moctezuma J (1996):** Effect of acute and chronic stress on masculine sexual behavior in the male rat. *Psychoneuroendocrinology*, 21: 39-50.
16. **Zeyl J, Love O, Higgs S (2014):** Evaluating gonadosomatic index as an estimator of reproductive condition in the invasive round goby, *Neogobius melanostomus*. *Journal of Great Lakes Research*, 40(1): 164-171.
17. **Kiernan J (2015):** *Histological and Histochemical Methods; Theory and Practice*. Butterworth Heinemann, Oxford, UK, 5th edition, Pp.238-310.
18. **Abdel-Dayem M (2009):** Histological and immunohistochemical changes in the adult rat testes after left experimental varicocele and possible protective effects of resveratrol. *Egypt J. Histol.*, 32(1): 81-90.
19. **Dukers D, Meijer C, ten Berge R, Vos W et al. (2002):** High numbers of active caspase 3-positive Reed-Sternberg cells in pretreatment biopsy specimens of patients with Hodgkin disease predict favorable clinical outcome. *Blood, The Journal of the American Society of Hematology*, 100(1): 36-42
20. **Kotula-Balak M, Bablok L, Fracki S et al. (2004):** Immuno-expression of androgen receptors and aromatase in testes of patient with Klinefelter's syndrome. *Folia Histochemica et Cytobiologica*, 42(4): 215-220.
21. **Mohamadpour M, Noorafshan A, Karbalay-Doust S et al. (2017):** Protective effects of curcumin co-treatment in rats with establishing chronic variable stress on testis and reproductive hormones. *International Journal of Reproductive BioMedicine*, 15(7): 447-52.
22. **Shukla Y, Singh M (2007):** Cancer preventive properties of ginger: a brief review. *Food and Chemical Toxicology*, 45(5): 683-690.
23. **Malu S, Obochi G, Tawo E et al. (2009):** Antibacterial activity and medicinal properties of ginger (*Zingiber officinale*). *Global Journal of Pure and Applied Sciences*, 15: 3-4.
24. **Weidner M, Sigwart K (2001):** Investigation of the teratogenic potential of a *Zingiber officinale* extract in the rat. *Reproductive Toxicology*, 15(1): 75-80
25. **Charmandari E, Tsigos C, Chrousos G (2005):** Endocrinology of the stress response. *Annu Rev Physiol.*, 67: 259-284.
26. **Chen Y, Wang Q, Wang F et al. (2012):** Stress induces glucocorticoid-mediated apoptosis of rat Leydig cells in vivo. *Stress*, 15(1): 74-84.
27. **Bremner W, Millar M, Sharpe R et al. (1994):** Immunohistochemical localization of androgen receptors in the rat testis: evidence for stage-dependent expression and regulation by androgens. *Endocrinology*, 135(3): 1227-1234.

28. **Juárez-Rojas A, Garcia-Lorenzana M, Aragón-Martínez A et al. (2015):** Intrinsic and extrinsic apoptotic pathways are involved in rat testis by cold water immersion-induced acute and chronic stress. *Systems Biology in Reproductive Medicine*, 61(4): 211-221.
29. **Nagata S (1999):** Fas ligand-induced apoptosis. *Annual Review of Genetics*, 33(1): 29-55.
30. **Kaufmann T, Strasser A, Jost P (2012):** Fas death receptor signaling: roles of Bid and XIAP. *Cell Death And Differentiation*, 19(1): 42-52.
31. **O'Donnell L, McLachlan R, Wreford N et al. (1996):** Testosterone withdrawal promotes stage-specific detachment of round spermatids from the rat seminiferous epithelium. *Biology of Reproduction*, 55(4): 895-901.
32. **Walter J, Talbot I (1996):** Walter And Talbot General Pathology. Cell response to injury, Churchill L, NewYork; 7th Edition, Pp. 118. <https://www.scopus.com/record/display.uri?eid=2-s2.0-0030145890&origin=inward&txGid=21e856949e63b414533485737ae6ac09>
33. **Bitgul G, Tekmen I, Keles D et al. (2013):** Protective effects of resveratrol against chronic immobilization stress on testis. *International Scholarly Research Notices*, 2013. <https://www.hindawi.com/journals/isrn/2013/278720/>
34. **Tian P, Lv P, Shi W et al. (2019):** Chronic stress reduces spermatogenic cell proliferation in rat testis. *International Journal of Clinical and Experimental Pathology*, 12(5): 1921.
35. **Kamtchouing P, Fandio G, Dimo T et al. (2002):** Evaluation of androgenic activity of *Zingiber officinale* and *Pentadiplandra brazzeana* in male rats. *Asian Journal of Andrology*, 4(4): 299-302.
36. **Al-Shathly M, Ali S, Ayuob N (2020):** *Zingiber officinale* preserves testicular structure and the expression of androgen receptors and proliferating cell nuclear antigen in diabetic rats. *Andrologia*, 52(3): 13528.
37. **Ali B, Blunden G, Tanira M et al. (2008):** Some phytochemical, pharmacological and toxicological properties of ginger (*Zingiber officinale*, Roscoe): a review of recent research. *Food and chemical Toxicology*, 46(2): 409-420.
38. **Soliman A, Anees L, Ibrahim D (2018):** Cardioprotective effect of zingerone against oxidative stress, inflammation, and apoptosis induced by cisplatin or gamma radiation in rats. *Naunyn-Schmiedeberg's Archives of Pharmacology*, 391(8): 819-832.
39. **Rong X, Peng G, Suzuki T et al. (2009):** A 35-day gavage safety assessment of ginger in rats. *Regulatory Toxicology and Pharmacology*, 54(2): 118-123.