

ORIGINAL ARTICLE

Chest Wall Chondrosarcoma: Highly Expectant Survival After Radical Resection and Optimal Reconstruction.

Nour Eldin Gwely¹, Ahmed Mostafa², Hysam Abdelmohty², Walid Hassan²

1)Professor of cardiothoracic surgery, Cardiothoracic Surgery Department, Mansoura University, Egypt.

2)Cardiothoracic surgery Lecturer, Cardiothoracic Surgery Department, Mansoura University, Egypt

Corresponding author

Nour Eldin Gwely Professor of cardiothoracic surgery, Cardiothoracic Surgery Department, Mansoura University, Egypt
Department of Cardiothoracic Surgery (Dep.17), Mansoura University Hospitals, Elgomhoria Street, Mansoura city, Dakahlia province, Egypt
E-mail:

Submit Date 2020-10-28

Revise Date 2020-11-25

Accept Date 2020-12-10

ABSTRACT

Background: Chest wall chondrosarcoma is the most common primary tumor of chest wall. Radical excision with wide safety margin and optimal reconstruction of chest wall by prosthetic material is a corner stone in management. Aim of this study is to evaluate our surgical technique in management of thoracic chondrosarcoma

Patients and Methods: Over a period of 5 years, 24 cases with chest wall chondrosarcoma were reviewed and evaluated in Cardiothoracic Surgery Department in Mansoura University.

Results: in this study, 16 males and 8 females presented by rib chondrosarcoma (87.5%) and sternal chondrosarcoma (12.5%). Patients presented by painful mass were (62.5%) while those with mass only were (37.5%). Wide excision with safety margin of 4-5 cm was done, reconstruction was done by prolene mesh only in 33.3% and by prolene mesh with bone cement in (66.6%) Minimal complications in the form of fever (12.5%), seroma (8.3%) and infection (4.2%) were reported.

Conclusion: We advise aggressive resection of chondrosarcoma with wide safety margin and prosthetic material reconstruction of chest wall as it is the concept to expect high survival and low recurrence rates.

Key word: Chondrosarcoma, prolene mesh, bone cement, chest wall, sterum.



INTRODUCTION

Chest wall chondrosarcoma represents⁽¹⁾ a small percentage of chondrosarcoma (15%), although it represents the most common primary^(2,3) malignant tumor of chest wall.

Chondrosarcoma of ribs arising from both cartilagenous and bony structures⁽⁴⁾ represents 60% of malignant rib tumors.

Chondrosarcoma occurs between the age of 30-40 years and is more common in males than females. Clinical presentation ranges⁽⁵⁾ from painless slowly growing mass, to severely painful mass. Most chondrosarcomas are idiopathic and arise denovo. Radiologically, it appears as an irregular mass arising from the medulla with cortical destruction⁽⁵⁾.

Solid diagnosis can be obtained by histopathological examination to differentiate it from benign tumors, so excisional biopsy is the final⁽⁶⁾ definitive diagnostic tool.

Radical aggressive surgery with minimum clear margin 4-5 cm remains the optimal option for safe results as chemotherapy⁽¹⁾ is not effective and the tumor is relatively radiosensitive.

Prosthetic mesh reconstruction for any size defect provides both essential rigidity with minimal elasticity over the surgical wound so it is the best solution⁽⁶⁾ for reconstruction.

Inadequate excision will lead to local recurrence with serious complications for the patient due to high aggressiveness⁽⁵⁾ in the recurred chondrosarcoma as it is more malignant in behavior.

Aim of this study is to evaluate our surgical technique in management thoracic chondrosarcoma

PATIENTS AND METHODS:

During the period from January 2010 till December 2014, 24 cases with thoracic chondrosarcoma were revised retrospectively in Cardiothoracic Surgery Department, Mansoura University.

Thorough history was taken from all patients as regard age, sex, occupation and special habits. Past history of trauma, radiotherapy for the chest or chemotherapy for treatment of previous malignancy was taken accurately.

Clinical examination including general examination, chest, abdominal and cardiac examination was done. Local examination for the

tumor was done as regard site, size, shape, consistency, attachment or fixation. Other swellings in the body were also examined, (see table 1).

Laboratory investigations including complete blood picture, blood glucose level, liver function tests and renal function tests and tumor markers were done. Radiological investigations were done in all cases including: plain chest radiography both PA and lateral views, chest CT scanning and metastatic workup in the form of CT brain, abdominal US and bone scan.

Surgical treatment:

Firstly planning for the surgical approach for tumor resection and for the way of chest wall reconstruction was done.

Resection of the involved rib or ribs with its intercostal muscles, neurovascular bundles with additional 4-5 cm of the surrounding tissues as a safety margin was done for all cases who had rib chondrosarcoma.

In patients who had sternal tumors, 4-5 cm of the adjacent ribs in addition to the affected portion of the sternum were resected. Keeping an intact part of the sternum was preferred as long as the 4-5 cm safety margin was fulfilled.

Prosthetic materials were used to provide chest wall reconstruction depending on size and site of defects. Chest wall defects less than 6 cm were reconstructed by prolene mesh alone, while that more than 6 cm were reconstructed by bone cement sandwiched between two layers of prolene mesh.

Any sized sternal defect was reconstructed by bone cement sandwiched between two layers of prolene mesh to protect the vital mediastinal structure and achieve satisfactory respiratory function of patients.

Written informed consent was obtained from all participants, the study was approved by the research ethical committee of Faculty of Medicine, Mansoura University. The study was done according to The Code of Ethics of the World Medical Association (Declaration of Helsinki) for studies involving humans.

Statistical analysis: The data were tabulated and analyzed using the Statistical Package for the

Table (1): Preoperative data.

Age (year)		
Range	7 – 62	
Mean ± SD	39.71 ± 17.06	
	No	%
Gender		
Male	16	66.7%
Female	8	33.3%
Symptoms		

Social Sciences (SPSS) version 22.0 (IBM, Chicago, USA). Qualitative data was presented as number and percent. Quantitative data was presented as mean and standard deviation.

RESULTS

The age of our patients ranged from 7-65 years (mean age 39.71±17.06%). Male gender (16 cases) (66.7%) represented double the percentage of female gender (8 cases) (33.3%), (see figure 1).

Nine patients (37.5%) had accidentally discovered a local swelling, while the other-remaining 15 patients (62.5%) had complained of painful swelling (see figure 2) .

Local examination of patients revealed a mass in the right side of chest in 9 patients (37.5%), while the left chest swellings were 12 cases (50%). Lastly, sternal swellings were presented only by 3 cases (12.5%).

Tumors originated from either the ribs or the sternum. Tumors of sternal origin represented 3 cases (12.5%). Tumors of rib origin were anatomically at the posterior axillary line in one patient (4.2%), mid-clavicular line in 7 patients (29.2%), at the anterior axillary line in 7 patients (29.2%) and at the mid-axillary line in 6 patients (25%), (See figure 3).

Excision of the mass with a wide safety margin of 4-5 cm from macroscopic tumor margin followed by chest wall reconstruction by a prolene mesh was done in 8 cases only (33.3%) and in 16 patients (66.7%), a prolene mesh and bone cement were used for reconstruction, (see table 2).

After excision of the tumor in all cases, pathological examination was done for detection of the type of tumor and further management by chemotherapy or radiotherapy.

Some minor complications were seen in the form of fever in 3 patients (12.5%), seroma in 2 patients (8.3%), infection of the wound was superficial in 1 (4.2%) case, (see table 2). Mortality occurred in one female patient where sternal tumor (70x60 mm) was excised with wide safety margin, we think that the patient repair was imperfect and her old age (62 year old) with COPD status were the causes of death. She was ventilated for 6 days then arrested and died in ICU

Age (year)		
Range	7 – 62	
Mean ± SD	39.71 ± 17.06	
Mass only	9	37.5%
Painfull mass	15	62.5%
Side of the mass		
Right	9	37.5%
Left	12	50%
Sternum	3	12.5%
Site of tumor		
Mid-clavicular line	7	29.2%
Anterior axillary line	7	29.2%
Mid axillary line	6	25%
Posterior axillary line	1	4.2%
Tumor from sternum	3	12.5%

(Table (2): Perioperative data.

Size of chest wall defect after excision		
Less than 6 cm	8	33.3%
More than 6 cm	13	54.1%
Method of reconstruction		
Prolene mesh	8	33.3%
Double layer of prolene mesh with bone cement	16	66.7%
Postoperative complication		
Fever	3	12.5%
Seroma	2	8.3%
Wound infection	1	4.2%

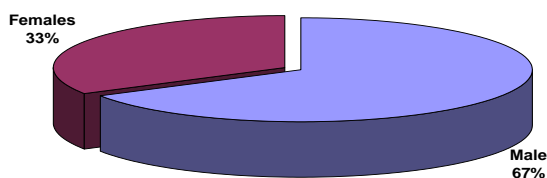


Figure (1): Patient gender

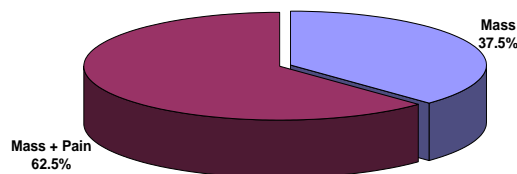


Figure (2): Clinical manifestations of tumor

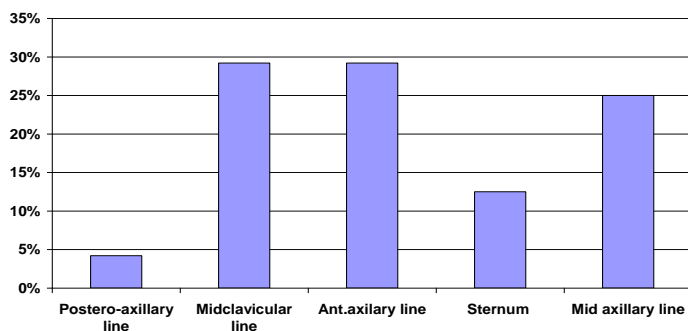


Figure (3): Site of tumor

DISCUSSION

The patient age in our study ranged from (7-62 years) with mean age (39.71±17.6) and this matched with the study of Cavanaugh⁽⁸⁾ in which the mean age was 30.5 years, while in the series of

Pairolero⁽⁹⁾, the mean age was 54.5 years and the mean age was 51.5 years in the study of Daniel⁽¹⁾ in 2011.

Malignant chest wall tumors are more frequent in men compared to women and this

matched with our study which included 16 males (66.7%) and 8 females (33.3%), this was confirmed by Burt⁽¹⁰⁾ study where males were 55% and this also matched with the study of Daniel⁽¹⁾ in which males represented (72%) and females were (27.3%).

Clinical presentation of patients ranged from pain only, mass or painful mass in the study of Sabanathan⁽¹¹⁾, 27% of cases presented by pain while mass presentation was 29% and 44% presented by both, while in our study 62.5% presented by painful mass and 37.50% presented by mass only, this difference is attributed to the fact that our study was conducted only on patients with chondrosarcoma, while the study of Sabanathan⁽¹¹⁾, was done on primary malignant chest wall tumors. Also our results matched with the results of Daniel⁽¹⁾ were palpable asymptomatic thoracic mass represented (27.3%).

Anatomically, the mass originated from the ribs in 87.5% and 12.5% originated from the sternum in our study which matched with Daniel⁽¹⁾ series where 72.7% was rib tumor and 27.3% was originated from the sternum. Arnold and his colleagues⁽¹²⁾ noticed that primary malignant tumor originated in the cartilagenous ends of ribs near the sternum and that malignancy must be always considered and its possibility kept in mind when any patient is presented by chest wall masses.

In our study only 3 cases were diagnosed preoperatively by incisional biopsy and the rest were diagnosed by excisional biopsy depending on frozen section and so aggressive excision with wide safety margin was done when malignancy was proven.

The real problem of the surgeon is not excision of the tumor but reconstruction of the defect. Due to the fact that the larger the defect the more difficult the reconstruction of chest wall and the surgeons are not as aggressive as needed in excision of a wide safety margin, this results in high recurrence rate.

We agree on the view of many surgeons that wide aggressive excision of tumor with safety margin of 4-5 cm from macroscopic growth edge should be considered as confirmed by Jorge and Joes report⁽⁴⁾.

The second role is that chest wall reconstruction must sustain stabilization of bony thoracic frame to avoid paradoxical movement of lungs and respiratory insufficiency as confirmed by Elcin⁽⁷⁾. So we prefer in all our cases to use prosthetic material.

We used prolene mesh in 8 cases (33.3%) in which the chest wall defects were less than 6 cm while in larger defects, prolene mesh with bone cement was used. In thirteen patients (54.1%)

whose the chest wall defect was more than 6 cm and in any sized sternal defects (12.5%), a prosthetic material grafting offers better stabilization than mucocutaneous flaps like pectoralis major muscle flap which was used in the study of Lanfery⁽¹³⁾ in (30.1%). This point of view agreed with the opinion of Daniel⁽¹⁾ in using Marlex mesh in 91% of patients. The presence of prosthetic material and bone cement enabled us to excise a wide safety margin without any hesitation or fear from failure of reconstruction and this point of view agreed with Widhe and Bauer⁽¹⁴⁾.

The wide surgical margin from 4-5 cm results in decreased local recurrence as reported by Widhe and Bauer⁽¹⁴⁾ in their study that 10 years survival for patient treated by wide safety margin resection was 92% compared with 47% intralesional resection.

The use of mesh and primary continuous closure is often quite safe in defects less than 6 cm in size⁽¹⁵⁾, and this confirmed our concept in using only mesh in chest wall defects less than 6 cm, while for any sized sternal tumor we used bone cement sandwiched between two prolene meshes.

Marlex mesh is usually used for reconstruction of chest wall, it has many advantages as high affinity for tissue growth, relatively good shape but its lack of rigidity in patients with extensive defects may result in paradoxical motion of chest wall⁽¹⁶⁾, and this matched with our point of view in using bone cement sandwiched between two prolene meshes for defects larger than 6 cm.

On the other hand, some minor complications like fever, seroma and wound infection occurred with prosthetic material but had no value and was corrected and this is the only disadvantage of prosthetic material use over the use of myocutaneous flap in this study.

Hospital mortality occurred in one patient with large sternal chondrosarcoma with wide excision of more than lower half of the sternum. Really reconstruction was imperfect and other comorbid conditions like old age (62 years), COPD status and insitu infection deteriorated the chest mechanics and respiratory function and the patient died after 7 days in the ICU.

CONCLUSION

We conclude that wide excision with sufficient safety margin (4-5 cm) is facilitated by optimum reconstruction with prosthetic graft material and this is a role to minimize or even to prevent recurrence. We expect high survival rate with this concept.

REFERENCES:

1-Daniel RW, Fernando CA, Anglo F et al. Surgically challenging chondrosarcomas of the

chest wall: five-years follow-up at a single institution. *Clinics*:2011; 66 (3): 501-503.

2-Novoa N, Benito P, Jimenez MF et al. Reconstruction of chest wall defects after resection of large neoplasms: ten-year experience, interactive. *Cardiovasc and Thorac Surg*:2005; 4:250-255.

3-Perry RR, Venzon D, Roth JA and Pass HI. Survival after resection for high grade chest wall sarcomas. *Ann Thoracic Surg*:1990; 49:363-369.

4-Jorge OJ and Joes LP. Large lateral thoracic defect by chondrosarcoma resection chest wall reconstruction using myocutaneous latissimus dorsal flap. *Indian J Plast Surg*:2005; 38: 231-235.

5-Ashesh KJ, Sanjay G, Sudipta S. Sternal chondrosarcoma: A case report. *Indian J Thoracic Cardiovasc*:2011; 27 (4): 182-184.

6-Incarbone M and Pastorino U. Surgical treatment of chest wall tumor. *World J Surg*:2001; 30: 218-225.

7-Elcin A, Serder E, Levent A et al. Chondrosarcoma of the anterior chest wall: surgical resection and reconstruction with titanium mesh. *J Thoracic Disease*:2014; 10: 230-233.

8-Cavanaugh DG, Cabellon SJr, Peake JB. A logical approach to chest wall neoplasms. *Ann Thorac Surg*: 1998;4 (14): 436-437.

9-Pairoler PC and Arnold PG. Chest wall tumors. Experience with 100 consecutive

patients. *J Thorac Cardiovasc Surg*:1985;90:367-372.

10-Burt M, Fulton M, Wessner-Dunlap S, Karpeh M et al. Primary bony and cartilagenous sarcomas of the chest wall: Results of therapy. *Ann Thorac Surg*:1992; 54 (2): 226-232.

11-Sabanathan S, Salama FD, Morgan WE et al. Primary chest wall tumors. *Ann Thorac Surg*:1985; 39:4-15.

12-Arnold PG and Pairolero PC. Chest wall reconstruction an account of 500 consecutive patients. *Plast Reconst Surg*:1996; 98 (5): 804-810.

13-Lanfery E, Grolleau JL, Clock Y et al. Reconstruction of the anterior chest wall by a sandwich type combination of a synthetic support and a muscle flap from the latissimus dorsi. Apropos of case. *Ann Chir Plast Esthet*:1996; 41 (2): 193-196.

14-Widhe B and Bauer HC. Surgical treatment is decisive for outcome in chondrosarcoma of chest wall: A population-based. *J Thoracic Cardiovasc Surg*:2009; 137: 610-614.

15-Chapellier ER, Missena MC, Coutured P et al. Sternal resection and reconstruction for primary malignant tumors. *Ann Thoracic Surg* :2004;77:1001-1007.

16-Matsomoto K, Sano I, Nakamura A et al. Anterior chest wall reconstruction with titanium plate sandwiched between two polypropylene sheets. *Gen Thorac Cardiovasc Surg*:2012; 60:590-592

How to cite

Gwely, N., elsaid, A., abdelmohty, H., rizk, W. Chest Wall Chondrosarcoma: Highly Expectant Survival After Radical Resection and Optimal Reconstruction. *Zagazig University Medical Journal*, 2023; (283-287): -. doi: 10.21608/zumj.2020.47911.1987