

Incidental Finding of Facial Schwannoma: A Case Report

Prempreet Kaur Manjit Singh^{1,2}, Nur'afeena Al Fahmi Binti Abdul Kashaf¹, Azila Alias¹, Nik Adilah Nik Othman²

Case Article

¹Department of Otorhinolaryngology-Head & Neck Surgery, Kuala Lumpur Hospital, Jalan Pahang, 50586 Wilayah Persekutuan Kuala Lumpur; ²Department of Otorhinolaryngology-Head & Neck Surgery, School of Medical Sciences, Universiti Sains Malaysia Health Campus, 16150 Kubang Kerian, Kelantan, Malaysia.

ABSTRACT

Introduction: Facial nerve schwannoma is a rare benign tumour involving any site of the facial nerve where schwann cells are present.

Case report: A 29-year-old lady presented with right ear tinnitus for one year, associated with reduced hearing for the last six months. Otherwise no other cranial nerves were involved. Patient did not complaint of any facial twitching or vestibular symptom. Patient was then investigated using audiological assessment and imaging which concluded the diagnosis as facial nerve schwannoma. In view of normal facial nerve function, the patient received conservative management.

Discussion: Symptoms may differ according to the location of the tumour and also compression on the adjacent structures, namely facial nerve palsy, hearing loss and tinnitus. Treatment option depends on the grade of facial nerve palsy and its prognosis post-surgery. Although the mainstay of treatment is surgical excision, every patient has to be individually assessed and treated accordingly.

Conclusion: Facial nerve schwannoma commonly presents with facial nerve palsy, however, a normal facial nerve does not exclude a facial nerve schwannoma. Therefore, imaging such as HRCT of temporal bone and MRI of internal auditory meatus needs to be done to reach an early diagnosis thus preventing complications.

Key Words: Facial nerve, facial nerve palsy, hearing loss, schwannoma, tinnitus

Received: 4 July 2020, **Accepted:** 25 September 2020

Corresponding Author: Nik Adilah Nik Othman, Department of Otorhinolaryngology - Head and Neck Surgery, School of Medical Sciences, Universiti Sains Malaysia Health Campus, **Tel.:** 0060199377080, **E-mail:** adilahkk@usm.my

ISSN: 2090-0740, March 2021 Vol.22, No.1

INTRODUCTION

Schwannoma arises from ectoderm which is the outermost of the three embryonic germ layers. It is a benign, well capsulated, solitary tumour arising from schwann cells of peripheral nerve sheath.^[1] Facial nerve schwannomas (FS) are rare benign tumours arising from the facial nerve. They may arise from anywhere along the facial nerve course; intratemporal (91%) and extratemporal (9%). More than 60% of FS affect two or more segments of the facial nerve. FS may affect any age group but is more common in 3rd and 6th decades of life with no sexual predominance.^[2] Patients commonly present with slowly progressive facial paresis or paralysis, hearing loss, tinnitus, headache or otalgia.^[1] However, there are many instances whereby patients with FS may present with normal facial nerve function.^[1] Management of FS depends on the severity of the disease, such as compression of the brainstem and the House Brackmann (HB) grading of facial nerve palsy. For less severe cases, whereby the HB grading is lesser than grade III, watchful waiting with serial imaging may be done. Other treatment options would be fallopian canal decompression, stereotactic radiosurgery or open surgery for excision of the tumour.^[3]

CASE PRESENTATION:

A 29-year-old Malaysian Chinese lady presented with right ear tinnitus for a year which progressively worsened coupled with reduced hearing for the last six months. There was no history of otalgia, otorrhea, ear fullness or facial weakness. There was also no history of recent trauma or infection.

Clinical examination showed no facial nerve palsy and ear examination revealed normal external ear and tympanic membrane bilaterally. Rinne test was negative on the right ear but positive on the left ear, whereas, Weber test lateralised towards the right ear. Tympanometry showed bilateral type A tracing with pure tone audiometry (Figure 1) revealed right moderate mixed hearing loss with rising configuration and normal hearing on the left ear. In view of the asymmetrical pure tone audiometry finding, we proceeded with auditory brainstem response (ABR), (Figure 2) which showed no delay in latency, suggestive of no retro-cochlear lesion.

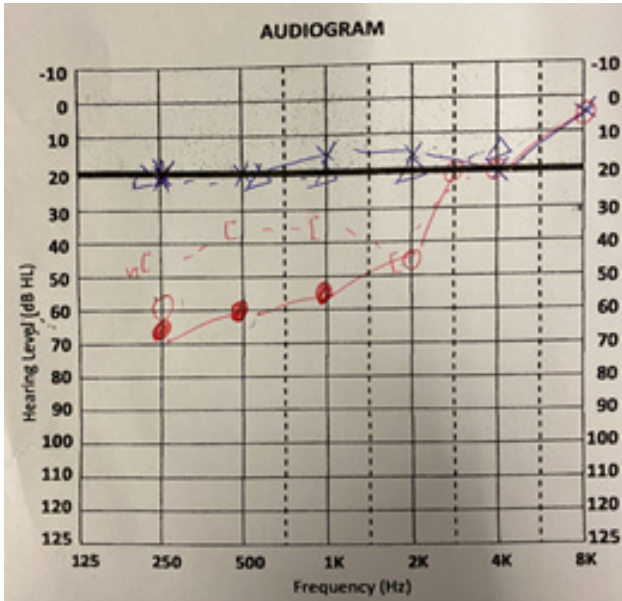


Fig. 1: Audiogram

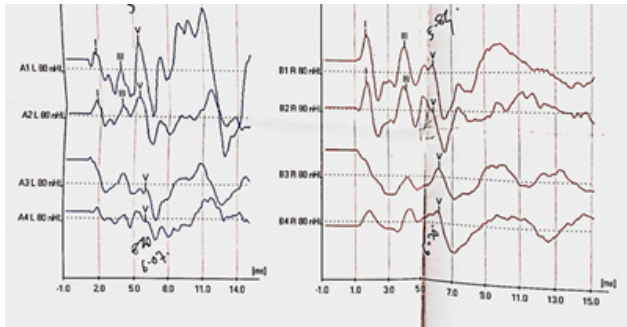


Fig. 2: Auditory brainstem response

Subsequently, a magnetic resonance imaging (MRI) of the brain and internal auditory meatus (IAM) was done. As illustrated in (Figure 3 and Figure 4), features of a hyperintense well-defined lobulated lesion within the right middle ear and temporal bone which seems to follow the course of the right facial nerve, pointed to a differential diagnosis of a facial nerve schwannoma. We then proceeded with High Resolution Computed Tomography (HRCT) scan of the temporal bone to further evaluate the bony and middle ear structures involvement.

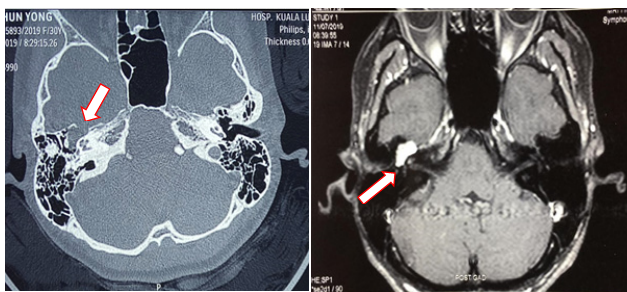


Fig. 3: Axial view shows CT with no bony erosion and MRI T1-weighted image with Gadolinium with hyperintense well-defined lobulated lesion in the right temporal region (arrow).

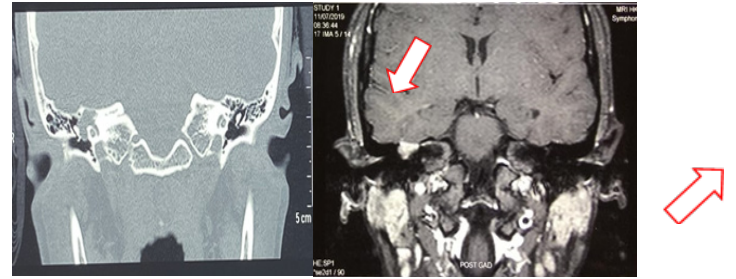


Fig. 4: Coronal view shows CT with no bony erosion of base of skull and T1-weighted image with Gadolinium with hyperintense well-defined lesion in the right middle ear region (arrow).

The patient was then referred to the neurosurgical team for further assessment and management. However, due to normal facial nerve function and possibility of hearing rehabilitation, the patient was not subjected to surgery. Currently the patient is being monitored with yearly MRI and audiological assessment.

DISCUSSION

FS is an uncommon benign tumour which has been reported as less than 1% of all temporal bone tumours.^[4] It usually affects multiple sites and presents as skip lesion. Malignant transformation of schwannoma is rare. Some neuroma such as acoustic neuroma has association with neurofibromatosis.^[1] FS has been diagnosed in 5% of patients with facial nerve palsy.^[3,5] However, 80% of facial nerve palsy is idiopathic.^[6] Commonest site for FS is at the geniculate ganglion fossa with tympanic or labyrinthine segment extension.^[1,4] Audiological and imaging studies may help to diagnose and localize the tumour. Auditory brainstem response (ABR) test is able to narrow down the site of lesion to suggest a retro-cochlear lesion. Further imaging such as high-resolution computed tomography (HRCT) of the temporal bone and MRI of the middle and inner ear, can help to determine the location and extension of the lesion and also to map the plan for operative approach and management. The MRI and HRCT scan will complement each other in clinching the diagnosis. The facial canal is best identified via CT scan, whereas the MRI shows the extent and nature of tumour. Lesions in the cerebello-pontine angle (CPA) or internal auditory canal (IAC) may present with sensorineural hearing loss due to compression of the acoustic nerve. Therefore, proximal FS is often mistaken for acoustic neuroma prior to surgery. If a FS is located at the IAC, erosion to the anterior superior margin of the canal and geniculate ganglion will be seen in the imaging, which can differentiate between FS and acoustic neuroma.^[6] Whereas, FS arising from tympanic cavity may enclose or erode the ossicles leading to conductive hearing loss.^[6]

Surgical management of FS depends on the symptoms and also the location of the schwannoma on the facial nerve.^[1] Before embarking into surgery, preservation of hearing should be considered and taken seriously.^[5] For a patient with long standing facial nerve palsy, complete removal of the tumour with reconstruction of the facial nerve is advocated.^[7] However, in patients with no facial nerve palsy, it is suggested to delay the surgery until patient develops at least a HB grade III facial palsy due to the fact that one of the complication of surgery is facial nerve palsy itself.^[7] These patients can be followed up to look for development of compressive signs such as brainstem compression, labyrinthine erosion or worsening facial nerve palsy. For patients showing worsening of symptoms or radiological findings, treatment will be catered according to patient's condition and preference.

Besides complete excision of the tumour, other treatment options available include fallopian canal decompression, stereotactic radiosurgery and microsurgical excision with facial nerve repair which are categorized under facial nerve preservation technique.^[3] Treatment options are determined by the extent of the disease progression. When facial nerve function is between HB grade II and IV, irradiation or fallopian nerve decompression is the treatment option.^[3] For patients with facial nerve palsy HB grade IV-VI, microsurgical excision with facial nerve reconstruction is considered.^[1,3] FS involving the geniculate ganglion will require a combined middle cranial fossa-transmastoid approach, meanwhile a proximal FS will require a transmastoid approach alone.^[6] And these approaches need also to consider the requirement of hearing preservation.

CONCLUSION

For our patient, her presentation mimicked an acoustic neuroma. However, further investigation and imaging led us to the diagnosis of FS with HB grade I. This condition does not require surgical intervention thus was managed conservatively.

Despite having an initial diagnosis of acoustic neuroma based on clinical examination, further imaging such as MRI is essential to avoid missing an incidental tumour such as FS. We would like to stress the point that in this modern era, clinicians should not

hesitate to acquire an early imaging modality to come to a complete and accurate diagnosis to ensure prompt management and avoid complication.

ABBREVIATION

FS-facial nerve schwannoma, HB-House-Brackmann, IAM-internal auditory meatus, MRI-magnetic resonance imaging, HRCT-high resolution computed tomography, ABR-auditory brainstem response, CPA-cerebello-pontine angle, IAC-internal auditory canal.

CONFLICT OF INTEREST

There are no conflicts of interest.

REFERENCES

1. McMonagle B, Al-Sanosi A, Croxson G, Fagan P. Facial schwannoma: results of a large case series and review. *The Journal of Laryngology & Otology*. 2008;122: 1139–1150.
2. Rainsbury JW, Whiteside OJ, Bottrill ID. Traumatic facial nerve neuroma following mastoid surgery: A case report and literature review. *J Laryngol Otol*. 2007; 121:601-605.
3. Chen MC, Tseng TM, Hung SH, Chen PY. Facial nerve schwannoma: A case report and review of the literature. *Oncology Letters*. 2014;8: 2787-2789.
4. Saumya M, Haritosh KV, Merin Sara M, Roshni K, Yogesh GD. Diagnostic paradox behind facial nerve schwannoma. *Head and Neck Cancer Research*. 2017; Volume 2.
5. Santhi T, Vivek S. Facial Nerve Schwannoma – A Diagnostic and Surgical dilemma: A Case Report. *International Journal of Scientific Study*. 2019; 7(5): 107-110.
6. Latack JT, Gabnielsen TO, Knake JE, Kemink JL, Graham MD, Gebarski SS, Yang PJ. Facial nerve neuromas: Radiologic evaluation. *Radiology*. 1983; 149(3): 731-739.
7. Kohmura E, Aihara H, Miyake S, Fujita A. Intradural facial nerve schwannoma: Diagnostic and therapeutic problems. *Skull base*, 2007; 17(3): 215-222.