

# Intramedullary Screw Fixation of Midshaft Clavicle Fractures

Waleed B. Abdelreheem<sup>a</sup>, Ahmad S. Allam<sup>b</sup>, Mohamed S. Singer<sup>b</sup>, Eslam A. Table<sup>b</sup>

<sup>a</sup> Department of Orthopaedic, Mansoura international specialized hospital, Mansoura, Egypt. <sup>b</sup> Department Orthopedic Surgery, Faculty of Medicine, Benha University, Egypt

**Correspondence to:** Waleed B. Abdelreheem, Department of Orthopaedic, Mansoura international specialized hospital, Mansoura Egypt.

**Email:**

waleedgait@gmail.com

**Received:** 1 May 2020

**Accepted:** 28 May 2020

**Abstract**

**Aim:** To investigate the use of intramedullary screw for fixation of mid-shaft clavicle fractures including indications, preoperative planning, operative technique, and complications during the study period. **Setting and design:** Prospectively we used intramedullary screw for fixation of mid-shaft clavicle fractures either nondisplaced, minimally displaced guided by fluoroscopy. **Patients and methods:** The study included 20 patients after obtaining informed consent who underwent mid-shaft clavicle fractures using intramedullary screw fixation between February 2018 and January 2019. **Statistical analysis used:** The software for statistical package for social sciences for Windows 10 was used for all statistical calculations. Each variable was tested for its normal value using the Mann-Whitney Test and exact P values were calculated. Significance was set at the P value of less than 0.05. **Results:** All cases had “good to excellent” functional

results according to the Constant and Murley shoulder score. **Conclusion:** Our results show that intramedullary screw fixation of mid-shaft clavicle fractures inserted from the lateral to the medial fragment is a simple, reliable and effective method of treatment with overall satisfactory functional and cosmetic results and low morbidity.

**Key-words:** Mid-shaft - Clavicle fracture - Screw fixation - Intramedullary.

**Key Messages**

Intramedullary screw fixation of mid-shaft clavicle fractures is a safe and relatively easy surgical procedure to treat mid-shaft clavicle fracture with several advantages.

## **Introduction**

Fractures of the clavicle account for about 4 % of all adult fractures and 70 % of these fractures occur in the middle-third of the clavicle. Displacement occurs in about 70 % of all mid-shaft clavicular fractures. <sup>[1]</sup>

Traditionally, the treatment of clavicle fractures has been exclusively non-operatively. <sup>[2]</sup> The disadvantages of conservatively treated displaced mid-shaft clavicular led to a tendency towards surgical treatment. <sup>[3]</sup>

The indications for surgical treatment of clavicle fractures are complete displacement and/or 15 to 20 mm or more of shortening are considered as a relative indications for surgical fixation, whereas open fractures and neurovascular compromise remain absolute indications. <sup>[4]</sup>

Intramedullary fixation is an alternative method of fixation for mid-shaft clavicle fractures and has prospective advantages of a minimal skin incision, less soft-tissue disruption and less prominent implants. Smaller incisions reduce the risk injury of supraclavicular nerve branches and also reduce the risk of infection. Additionally, intramedullary fixation avoids possible damage to nearby subclavian vessels and

the brachial plexus from drill bits or protruding screws. <sup>[4]</sup>

The technique of intramedullary screw fixation has many advantages as it provide a rigid three-point fixation, easy, safe, with less complications and excellent functional outcomes. It allows intramedullary compression, stability, stress share, little periosteal stripping, early recovery after surgery and short hospital stay. <sup>[5]</sup>

---

## **Subjects and Methods**

Our study began in 2018 through 2019 as a prospective study in which twenty patients with acute mid-shaft clavicle fractures were treated by open reduction and internal fixation using intramedullary screw in orthopedic department of Benha faculty of Medicine and Mansoura International Specialized Hospital after obtaining informed consent for the procedure and for taking intraoperative photos. Patients were followed-up, the follow-up duration was for a minimum of six months and a maximum of 1 year.

Several subsets of mid-shaft clavicle fractures were included in the study: Simple displaced fractures and complex displaced fractures according to Robinson

classification. [6] The Constant and Murley shoulder score was followed for evaluation of the functional results of the study (Table 1). [7]

Preoperative planning started by proper X ray views of the affected shoulder including AP and oblique views. The fixation device used in our study was the partially threaded 6.5 mm cannulated screw. A guide wire of 2.8 mm is used to determine the initial trajectory under fluoroscopic guidance.

Under general anesthesia, the patient was placed in beach-chair position on a radiolucent operating table with the C-arm draped into the field for intraoperative fluoroscopic imaging (Figure 1).

A 3-cm incision was used in Langer's lines over the palpable distal end of the medial fragment (Figure 2). The platysma muscle was identified and its fibers were divided longitudinally, care is taken to prevent injury to the middle branch of the supraclavicular nerve. Once the fracture was exposed, interposed periosteum and soft tissue were removed from the fracture site.

The medial fragment was grasped with a towel clip or bone reduction forceps (Figure

3). Once the orientation was established, the canal was opened with a 3.5 mm drill bit under fluoroscopic guidance; care is taken to avoid perforation the medial aspect of the clavicle (Figure 4).

The lateral fragment was then delivered out of the wound and drilled with a 4.5 mm drill bit until its tip perforates posterolateral cortex and could be felt beneath the skin. A small incision was made directly over the exiting drill bit for insertion of the screw. The ideal exit point was in the posterolateral clavicle which is halfway between the conoid tubercle and the distal clavicle and at the equator of the clavicle (Figure 5).

A guide wire was reversed from the fracture site to exit point. The fracture was reduced and the guide wire placed across both fracture fragments and advanced the wire medially while maintaining the reduction by holding the fracture site. A 5-mm cannulated drill bit was passed over the guide wire while maintain the reduction. A partially threaded cannulated 6.5-mm screw of appropriate length is advanced from the posterolateral aspect of the clavicle in a retrograde fashion from lateral-to-medial

direction. The length of the screws varied according to the curvature of the clavicle. Final position was checked by fluoroscopy

46

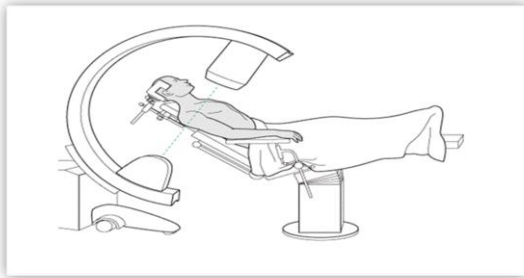


Figure 1: Illustrated photo: The beach-chair position with the C-arm.

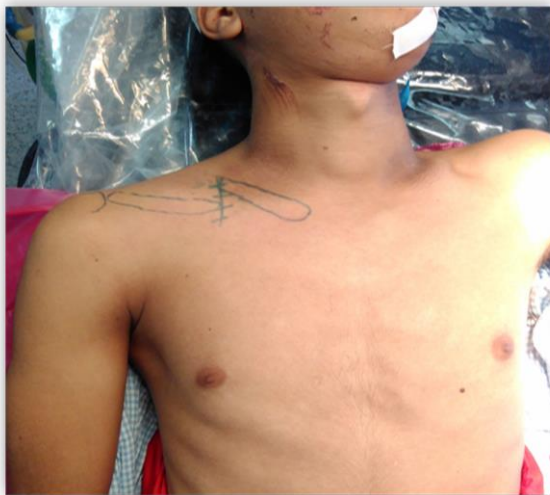

Figure 2: Clinical photo: A 3-cm incision is made in the natural skin creases over the distal aspect of the medial fragment

(Figure 6 - 10). Patients were discharged from hospital once their general and their wound condition allowed

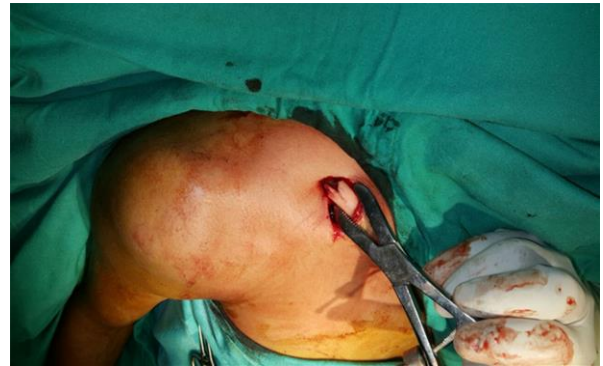

Figure 3: Intra-operative photo: The medial fragment is grasped with bone reduction forceps

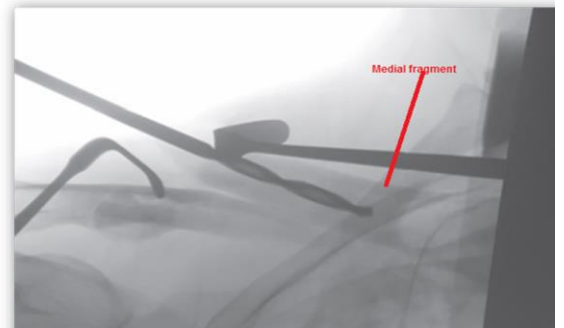

Figure 4: Intra-operative fluoroscopic image photo: Opening of the medial canal with a 3.5-mm drill bit.

47

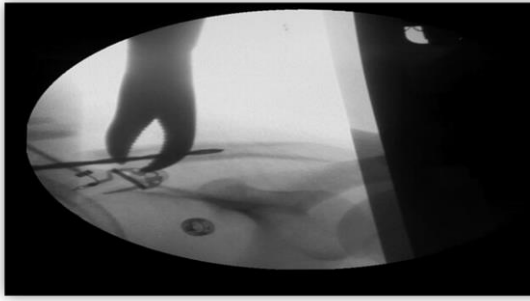


Figure 5: Intra-operative fluoroscopic image photo: The lateral fragment drilled with a 4.5 mm drill bit from fracture site until its tip

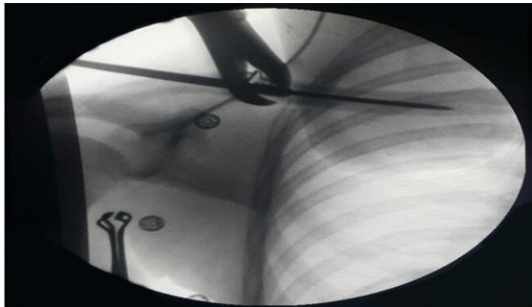


Figure 6: Intra-operative fluoroscopic image photo: partially threaded canullated 6.5-mm screw of the measured length is advanced from the posterolateral aspect of the clavicle in a retrograde fashion from lateral-to-medial

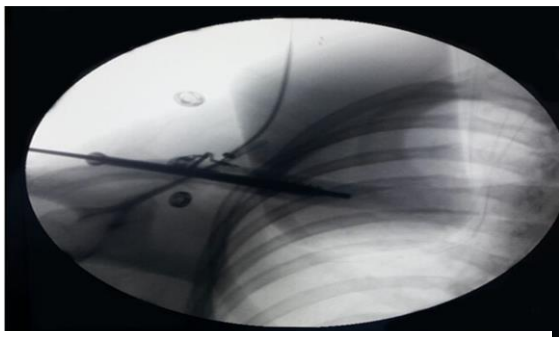


Figure 7: Intra-operative fluoroscopic image photo: assessment of the final position of the screw (anteroposterior view).

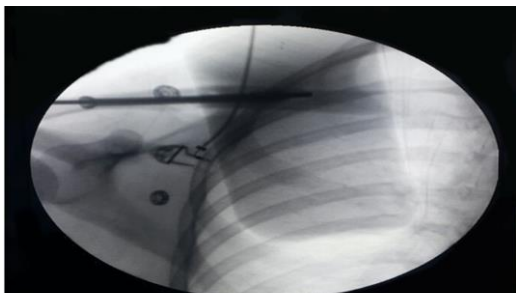


Figure 8: Intraoperative fluoroscopic x-ray: assessment of the final position of the screw (cephalic tilt view)

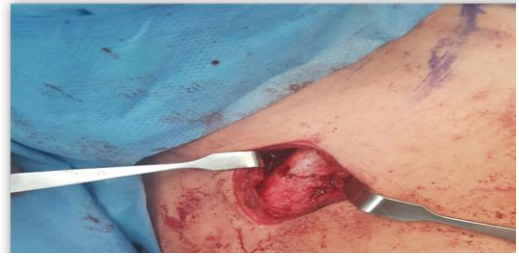

Figure 9: Intra-operative photo: the fracture site was compressed after advancing of the partially threaded canullated 6.5-mm

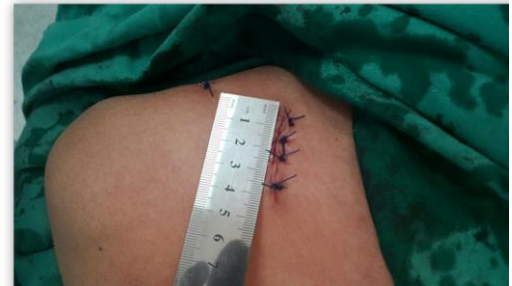

Figure 10: Clinical photo: closure of the skin, **the arrow** refers to incision at posterolateral aspect of the clavicle for screw insertion.

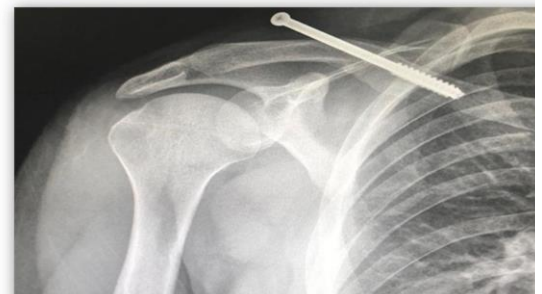

Figure 11: Anteroposterior x-ray: Prominent head of the screw

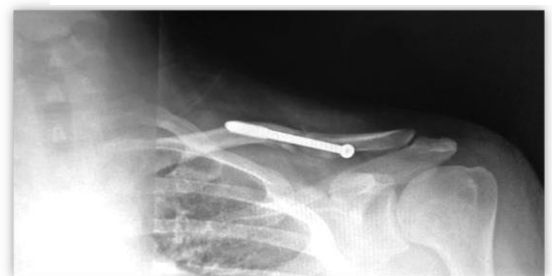

Figure 12: Cephalic tilt view x-ray: Medial fragment cortex penetration

Table 1: Costant and Murley detailed category scoring.			
Category Score			Points
Pain	None		15
	Mild		10
	Moderate		5
	Sever		0
Activity of daily living	Activity level	Full work	4
		Full recreation/sport	4
		Unaffected sleep	2
	Positioning	Up to waist	2
		Up to xiphoid	4
		Up to neck	6
		Up to top of head	8
		Above head	10
Range of motion	Forward elevation	0 - 30 °	0
		31 - 60 °	2
		61 -90 °	4
		91 - 120 °	6
		121 - 150 °	8
		150 - 180 °	10
	Lateral elevation	0 - 30 °	0
		31 - 60 °	2
		61 -90 °	4
		91 - 120 °	6
		121 - 150 °	8
		150 - 180 °	10
	External rotation	Hand behind the head with elbow held forward	2
		Hand behind the head with elbow held back	2
		Hand above the head with elbow held forward	2
		Hand above the head with elbow held back	2
		Full elevation from on top of head	2
	Internal rotation	Dorsum of hand to lateral thigh area	0
		Dorsum of hand to buttock	2
		Dorsum of hand to lumbosacral area	4
		Dorsum of hand to waist	6
		Dorsum of the hand to inter-scapular region (T <sub>7</sub> vertebra)	8
		Dorsum of the hand to T <sub>12</sub> vertebra	10
	Strength		
Total			100

---

## Results

The research was carried out on the 20 patients. Of these, 2 (10%) were females and 18 were males (80%). The mean age of the patients was 29.7 years with the youngest patient being 18 and the oldest 52 years old. The injury mechanism was road traffic accident in 12 patients (60%) and falling on shoulder was responsible for fractures in 5 cases (25%), whereas 3 cases (15%) were fractured due to direct trauma to the clavicle (Table 2). We performed all the operations in beach-chair position.

Eleven patients had right side fractures; nine patients had the fracture on the left side.

Operation time was on average 47 minutes (40 – 60 minutes). The operation time was measured from the starting of the incision till the last suture. The length of the incision was on average 2.5 cm.

We used 6.5 mm partially threaded cannulated screws in all patients with average length of 110 mm.

In all cases, immediate postoperative radiographs showed that the screws were successfully placed across the fracture line.

The duration of post-operative admission for our patients was average from 24 to 48 hours. Patients were discharged in arm sling; they began pendulum exercises and light daily activities during 1st week post-operative and active assisted motion at 2nd week. Early motion of the shoulder and the elbow with light daily activities was encouraged to improve function and to restore patient independence. The Suture was removed from ten to fourteen days postoperative. We followed the patients for at least 6 months (average was 7.3 months) and in each follow up, we assessed the union, pain quantity, range of motion and return to preoperative activities. The fractures showed union at a mean of 13.8 weeks postoperatively (range 12-20 weeks).

All the patients got back to their preoperative activities at the end of the follow-up period.

The Constant and Murley shoulder score was applied for all patients. At final follow up; thirteen patients (65%) had excellent results; seven patients (35%) had good results (Table 3).

Out of twenty patients included in this study, six patients (30%) had complications, whereas fourteen patients (70%) had no complications at the end of the follow-up. Three patients (15%) had prominent head of the screw (Figure 11), they did not find it painful or restricting motion but only complaint of disfigurement and they refused removal of the screw. Two patients (10%) had intra-operative complication in the form of medial

fragment cortex penetration, with no further management done, just observed during the follow-up (Figure 12). One patient (5%) had intra-operative complication in the form of intra-operative fissure crack at the fracture site during driving of the screw managed by vicryle suture augmentation (Table 4). There was no neurological or vascular complication in all patients at the end of the follow-up.

Table 2: Mechanism of injury.

<b>Mechanism of injury</b>	<b>No. of patients</b>	<b>Percentage</b>
Road traffic accident	12	60%
Falling on shoulder	5	25%
Direct trauma	3	10%
Total	20	100%

Table 3: Final functional outcome results according to Constant and Murley shoulder score.

<b>Final score</b>	<b>No. of patients</b>		<b>Percentage (%)</b>
Excellent	13		65%
Good	7		35%
Total	20		100%
<b>Minimum</b>	<b>Maximum</b>	<b>Mean</b>	<b>Standard deviation</b>
82	100	93.75	6.52



Table 4: Complications encountered in the patients at the end of the follow up.

Complications			Group				Total	Chi-square	
			Excellent	Good	Poor	Fair		X <sup>2</sup>	P value
Intra-operative	Medial fragment cortex penetration	No.	1	1	0	0	2	8.459	0.037
		%	50%	50%	0%	0%	100%		
Intra-operative	Intra-operative fissure crack at the fracture site	No.	1	0	0	0	1		
		%	100%	0%	0%	0%	100%		
Post-operative	Prominent head of the screw	No.	0	3	0	0	3		
		%	0%	100%	0%	0%	100%		
No complications		No.	11	3	0	0	14		
		%	78.57%	21.43	0%	0%	0%		
<b>Total</b>		No.	13	7	0	0	20		
		%	65%	35%	0%	0%	100%		

## Discussion

Traditionally, the treatment of clavicle fractures has been exclusively non-operatively the clavicular mal-union was of radiographic interest only without any clinical relevance. [2] However, recently studies demonstrated the disadvantages of conservatively treated displaced mid-shaft clavicular fractures as the non-unions,

residual loss in shoulder strength, persistent pain and disappointing cosmetic results might have led to unsatisfactory results in about one third of patients, [8] leading to a tendency towards surgical treatment. [3]

The recent treatment tends to manage displaced mid-shaft clavicle fractures with internal fixation which provides more rigid immobilization and early pain relief, and avoids shortening and deformity which were the main disadvantages associated with non-operative management. [9]

Previously used intramedullary devices as wires cannot provide rotational stability of the clavicle, <sup>[10]</sup> while in our study, the three-point fixation offered by the curvature of the bone provides a stable fixation, the medullary cavity of the clavicle is nearly fulfill with the large diameter of the partial threaded screw which also provides a compression lag effect at the fracture site, all these factors provide a stable fixation.

The technique of intramedullary screw fixation has many advantages as it provide rigid three-point fixation, easy, safe, with less complications and excellent functional outcomes. It allows intramedullary compression, stability, stress share, little periosteal stripping, early recovery after surgery and short hospital stay. <sup>[5]</sup>

In our study procedure we used 6.5 mm partially threaded cannulated screw inserted from lateral fragment after drilling of it over a guide wire was found to be easier and less technically demanding.

We believe that intramedullary screw fixation of mid-shaft clavicle fractures can produce excellent results in selected patients.

---

## Conclusion

Open reduction and intramedullary fixation of fresh mid-shaft clavicle fracture using a cannulated 6.5 mm partially threaded screw inserted from the lateral to the medial fragment, is a simple, reliable and effective method of treatment for the selected cases with overall satisfactory functional and cosmetic results and low morbidity.

---

## References

- 1) Khan LA, Bradnock TJ, Scott C, Robinson CM. Fractures of the clavicle. *J Bone Joint Surg. (Am)* 2009; 91:447–460.
- 2) Neer CS. Nonunion of the clavicle. *Journal of the American Assosiation.* 1960; 172:1006–1011.
- 3) Smekal V, Oberladstaetter J, Struve P. Shaft fractures of the clavicle: current concepts. *Arch Orthop Trauma Surg.* 2009; 129:807–815.
- 4) Eichinger JK, Balog TP, Grassbaugh JA. Intramedullary fixation of clavicle fractures: anatomy, indications, advantages and disadvantages. *J Am Acad Orthop Surg.* 2016; 24:455–464.
- 5) Abo El Nor T. Displaced mid-shaft clavicular fractures: surgical treatment with intramedullary screw fixation. *Arch Orthop Trauma Surg* 2013; 133: 1395–1399.
- 6) Robinson CM. Fractures of the clavicle in the adult: Epidemiology and classification. *J Bone Joint Surg (Br).* 1998; 80(3):476–84.
- 7) Constant CR, Murley AH. A clinical method of functional assessment of the

shoulder. Clin Orthop Relat Res 1987; 214:160–164.

8) Hill JM, McGuire MH, Crosby LA. Closed treatment of displaced middle-third fractures of the clavicle gives poor results. J Bone Jt Surg (Br). 1997; 79:537–538.

9) Douraiswami B, Naidu DK. Open reduction and plating for displaced mid third

clavicle fractures – A prospective study. J Clin Orthop Trauma 2013 Dec; 4(4): 174–179.

10) Ngarmukos C, Parkpian V, Patradul A. Fixation of fractures of the midshaft of the clavicle with Kirschner wires. Results in 108 patients. J Bone Joint Surg Br 1998; 80(1):106–108.

**To cite this article:** Waleed B. Abdelreheem, Ahmad S. Allam , Mohamed S. Singer , Eslam A. Table. Intramedullary Screw Fixation of Mid-shaft Clavicle Fractures. BMFJ 2020; 37 (surgical issue):44-54. DOI: 10.21608/bmfj.2020.29170.1254