

The Role of Diffusion-Weighted Magnetic Resonance Imaging in the Evaluation of Patient with Non Traumatic Orbital Lesions

Hala Abou Senna, Tojan Taha, Zahraa Udyi Hatm*

Department of Radiodiagnosis, Faculty of Medicine - Ain Shams University

*Corresponding author: Zahraa Udyi Hatm, e-mail: zahraauday100@gmail.com

ABSTRACT

Background: orbital lesions represent a spectrum of benign and malignant lesions in adults and children that can be challenging to diagnose and treat. Imaging plays an important role in diagnosis, due to a potentially limited clinical examination and risks associated with biopsy. Magnetic resonance imaging (MRI) is a powerful tool for imaging the orbit, due to the excellent tissue contrast it provides.

Aim: this study aims at assessing the ability of diffusion weighted magnetic resonance imaging to differentiate the benign from malignant orbital lesions.

Patients and Methodology: this study population included 25 patients; they were attended El-Demerdash University Hospital with non-traumatic orbital lesions. All patients had fulfilled specific inclusion and exclusion criteria. The patients were evaluated by MRI orbit and diffusion study in attempt to differentiate the benign orbital lesions from malignant one.

Results: the pool of our study is 25 patients (16 female and 9 males) with orbital lesions, the patients age ranged from 1 year to 70 years. There are 48% of the cases diagnosed as having benign lesions and 52% have malignant lesions. Retinoblastoma is the commonest (12%) pathological diagnosis. The calculated apparent diffusion coefficient (ADC) values of the lesions ranged from $0.6 - 2.1 \times 10^{-3} \text{ mm}^2/\text{sec}$. The ADC value of $0.89 \times 10^{-3} \text{ mm}^2/\text{sec}$ is a cut off between benign and malignant orbital masses.

Conclusion: we concluded that the combination of conventional MRI finding and ADC calculation together with clinical finding could improve the diagnostic efficacy of MRI in the differentiation between benign and malignant orbital masses with considering the cut off ADC value between benign and malignant orbital masses.

Keywords: Diffusion-Weighted Magnetic, Resonance Imaging in, Non Traumatic Orbital Lesions

INTRODUCTION

Orbital lesions represent a spectrum of benign and malignant lesions in adults and children that can be challenging to diagnose and treat. Imaging plays an important role in diagnosis, due to a potentially limited clinical examination and risks associated with biopsy. Magnetic resonance imaging (MRI) is a powerful tool for imaging the orbit; due to the excellent tissue contrast it provides⁽¹⁾.

Proptosis is one of the most common indications for an ophthalmologist to order imaging. The two imaging techniques for the brain and orbit are computed tomography (CT) and MRI. Imaging techniques for visualizing pathology of the brain and orbit continue to evolve and improve. The clinicians now have a wide variety of diagnostic tests from which to choose. Additional noninvasive magnetic resonance (MR) characterization of tumors has become available through diffusion-weighted imaging (DWI)⁽²⁾.

DWI can help characterize indeterminate orbital lesions and greatly aid in tissue characterization with high accuracy when used in conjunction with clinical and conventional MRI findings, providing an additional noninvasive

predictor of histological nature and tool for guiding intervention⁽¹⁾.

Diffusion weighted MRI is based on the assessment of the random water proton movement within tissues and reflects cellular density and tissue architecture, providing imaging techniques that does not require the use of ionizing radiation or MR contrast agents and can easily be implemented into a standard MRI protocol. Changes in water molecular diffusion can be measured in vivo with DWI. This measurement of the self-diffusion coefficient of water indicates the mobility of water within tissue and is called the apparent diffusion coefficient (ADC)⁽³⁾.

AIM OF THE WORK

This study aims at assessing the ability of diffusion weighted magnetic resonance imaging to differentiate the benign from malignant orbital lesions.

PATIENT AND METHOD

Study Population

This study included 25 patients, who were attended El-Demerdash University Hospital with non-traumatic orbital lesions.

Inclusion criteria

- All age groups.
- Patient with clinical and radiological findings of non-traumatic orbital lesions.

Exclusion criteria

- Traumatic lesion.
- Patients with bad general condition.
- Electronically, magnetically, and mechanically activated implants.
- Ferromagnetic or electronically operated active devices like automatic cardioverter.
- Defibrillators and cardiac pacemakers.
- Metallic splinters in the eye.
- Ferromagnetic haemostatic clips in the central nervous system.

Patient preparation

- For the patient who needs anaesthesia, fasting four hours before the scan is required.

Technique

1. Conventional MRI

All the patients were evaluated by MRI orbit with diffusion in El-Demerdash University Hospital, using a 1.5 T scanner (Achieva, Philips Medical Systems, Best, Netherlands, Release 2.6, and Level 3).

The total time of the scan is about half an hour.

All the cases were examined in supine position with standard circularly polarized head coil using the following sequences:-

- Scout T1.
- Axial T2WI brain spin echo.
- Axial T1WI spin echo orbit.
- Axial STIR orbit.
- Coronal T1WI spin echo.
- Coronal T2WI spin.

The lesions were evaluated in MRI commenting on:

- Signal behaviour on T1 and T2 (iso, hypo and hyper intense relative to muscles)
- Presence of intratumoral hemorrhagic or necrotic components.

2. MR Diffusion Imaging

Diffusion-weighted MRI were obtained using a multi section single-shot echo planar imaging sequence (TR/TE/NEX: 2200/139 ms/1)

field of view 195mm, matrix size, 128 – 128 , section thickness 4 mm , section gap 0.3 mm with b values of 0 and 800 s/mm². The signal intensity of the lesion on DWI (b = 800) was classified as hypointense (free diffusion) or hyperintense (restricted diffusion). The ADC maps were calculated automatically by the MRI software. Measurements of ADC were made in different regions of interest (ROI) of the lesions and the mean ADC value was calculated. The ADC values were expressed 10⁻³ mm²/s.

The ADC was measured by manually placing regions of interest in tumor regions on the ADC map.

We compared the ADC maps and other MRI carefully and placed the regions of interest only in the solid tumor components (and not the cystic, necrotic, and hemorrhagic tumor areas).

Cystic and necrotic components were differentiated as areas of hyperintensity on T2-weighted MR Images. Hemorrhagic lesions were differentiated on unenhanced T1-weighted MR images as areas of hyper intensity and not suppressed on STIR images.

Histopathological analysis of the masses was after the MRI examination to correlate the histopathology with the DWI results.

The study was done after approval of ethical board of Ain-Shams University and an informed written consent was taken from each participant in the study.

Statistical Analysis

IBM SPSS statistics (V. 24.0, IBM Corp., USA, 2016) was used for data analysis.

- The description of data was in the form of mean ± SD.
- The Kolmogorov–Smirnov (K–S) test was used for diagnosis normality of data distribution.
- The analysis of data was to test statistical significant difference.
- The "p" value was considered significant if ≤0.05 at the 95% confidence interval.

RESULTS

The pool of our study is 25 patients (16 females and 9 males) with orbital lesions the patients' age ranged from 1 year to 70 years (Figure 1).

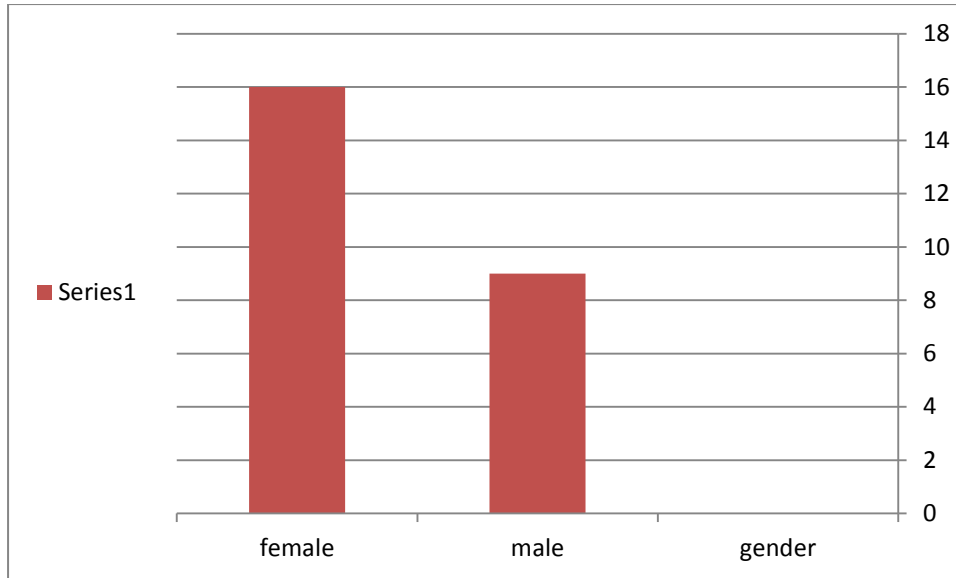


Figure (1): Sex distribution of the studied patients.

Conventional MRI as well as diffusion study was performed in attempt to differentiate the benign orbital lesions from malignant one.

Pathology of lesions

In the present study, there are 12 (48%) of the cases diagnosed as having benign lesions and 13 (52%) of the cases have malignant lesions (Figure 2).

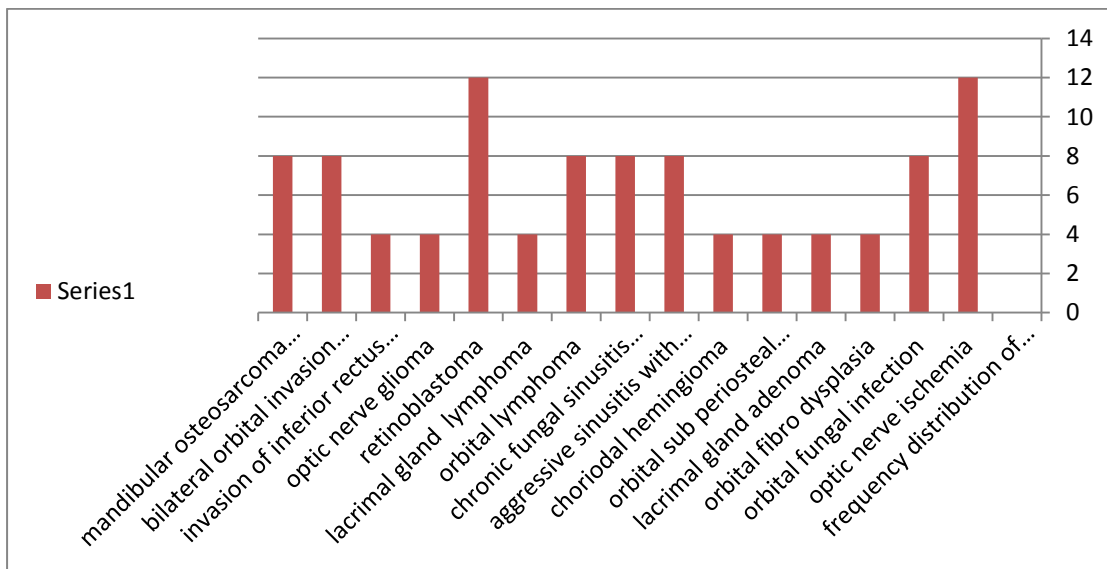


Figure (2): Frequency distribution of lesion type.

On the basis of histological diagnosis, retinoblastoma is the commonest between pathological diagnoses (12%).

Diffusion criteria of the lesions

Calculated ADC Values

The calculated ADC values of the lesions ranged from 0.6 – 2.1 x 10⁻³ mm²/sec (Figure 3).

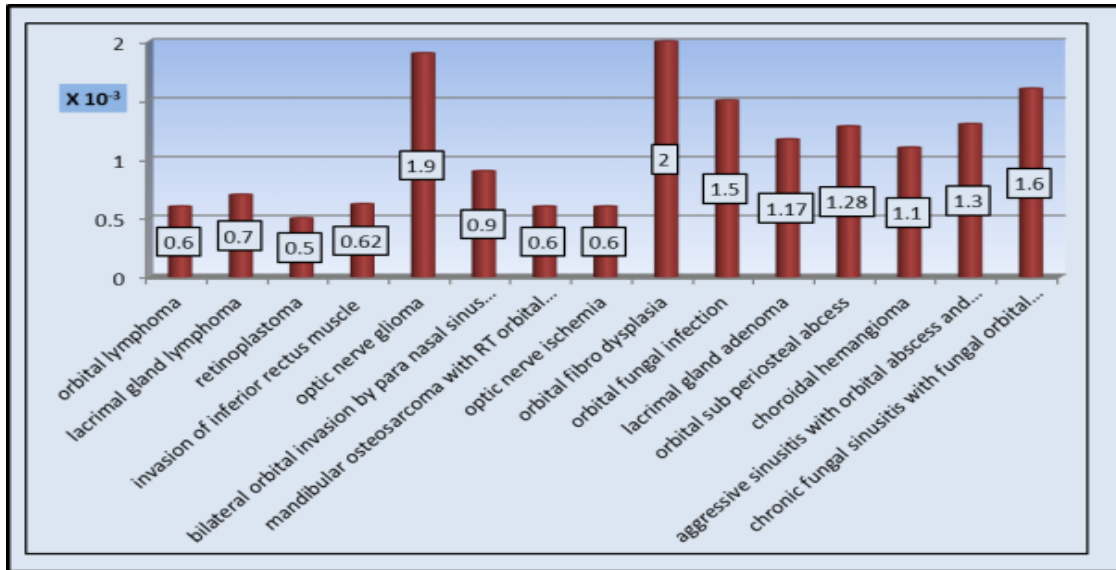


Figure (3): ADC values of orbital lesion.

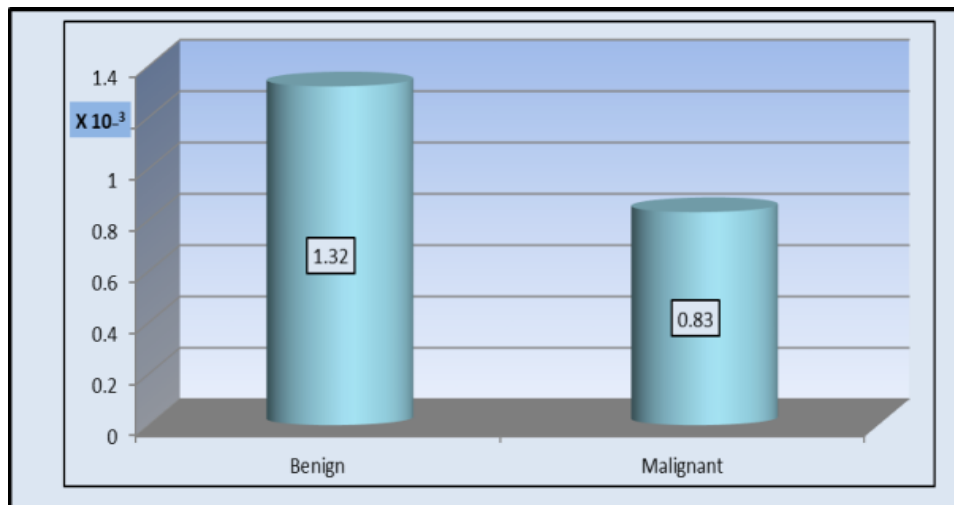


Figure (4): Bi chart of orbital lesions malignant tumors show lower ADC values than benign lesions. Therefore ADC value of 0.89 x10⁻³ mm²/sec is a cut off between benign and malignant orbital masses by sensitivity 90.5% and specificity 83.3%.

DISCUSSION

Lesions of the orbit comprise a spectrum of benign and malignant pathologies. Differentiating malignant from benign orbital lesions presents a challenge as it is still difficult to do so with different routine imaging modalities. Multi detector computed tomography and magnetic resonance imaging are used to localize orbital lesions and delineate their extent. However, exact diagnosis and differentiating

malignant from benign orbital pathologies may be difficult because of non-specific and overlapping imaging findings, and tumors may be misdiagnosed in cases of unexpected rare lesions entities⁽⁴⁾.

Patient history and clinical features are important in the differential diagnosis of orbital lesions; however the clinical findings may vary from patient to patient⁽⁵⁾.

Orbital imaging is required to confirm diagnosis and characterize the lesion; however, it is frequently very difficult to differentiate each specific disease on the basis of image characteristics alone because of intrinsic similarities. The presence of bone destruction strongly favors the diagnosis of a malignant orbital lesion. However, not all malignant orbital lesions produce bone destruction. Furthermore, long-standing cases of benign orbital lesions (as benign pleomorphic adenomas) can lead to bone destruction⁽⁵⁾.

So, although CT and MRI are complementary imaging techniques in localization and characterization of orbital lesions, distinction between different tumor types, malignant and benign neoplasms or even neoplastic and non-neoplastic lesions is frequently not possible by using either clinical criteria or conventional imaging, and biopsy is usually required. Therefore, it would be clinically useful to have a non invasive method to help lesion characterization⁽⁵⁾.

Diffusion weighted imaging (DWI) can provide in vivo physiologic information, complementing morphologic findings from conventional MRI in the clinical setting. DWI is a non invasive potential diagnostic tool for in vivo tissue characterization. The application of this newer technique is a clinical aid to the ophthalmologist for in vivo diagnosis of certain diseases⁽⁴⁾.

Our results also go in the same way as the results of the study done by Sepahdari *et al.*⁽¹⁾, who also done their study on total of 25 patients. Thirteen (52%) patients had malignant lesions and 12 (48%) had benign lesions. The most common malignant lesions were lymphoma (n=3) and metastasis (n=5). Significantly lower ADCs and lower ADC ratios were seen in malignant lesions compared with benign lesions, irrespective of patient age ($P < 0.02$); between adult malignant and adult benign lesions ($P < 0.05$).

Elkhamary⁽⁵⁾ concluded that selection of $0.90 \times 10^{-3} \text{ mm}^2/\text{sec}$ as a threshold ADC value for differentiating malignant lacrimal tumors from benign lesions was achieved with high accuracy.

Limitations of the study

They were that it has been done on several orbital compartments, also the numbers of the lesions in each compartment are few and some benign entities are not included as inflammatory pseudo tumor. So we are looking for extending this study to include the lesions in each compartment separately and different pathological entities. Also, the other limitation is to include patient form all ages, so we need further study for pediatric and adult age groups separately.

CONCLUSION

We can conclude that the combination of conventional MRI finding and ADC calculation together with clinical finding could improve the diagnostic efficacy of MR imaging in the differentiation between benign and malignant orbital masses with considering a cut off ADC value of $0.89 \times 10^{-3} \text{ mm}^2/\text{s}$ between benign and malignant orbital masses with specificity 83.3% and sensitivity 90.5%.

REFERENCES:

- 1. Sephadari AR, Aakalu VK, Setabutr P *et al.* (2010):** Indeterminate orbital masses: restricted diffusion at MR imaging with echo-planar diffusion-weighted imaging predicts malignancy. *Radiology*, 256: 554-564.
- 2. Roshdy N, Shahin M, Kishk H *et al.* (2010):** MRI in diagnosis of orbital masses. *Curr Eye Res.*, 35(11): 986-991.
- 3. Black EH, Calvano CJ, Nesi FA *et al.* (2012):** Smith and Nesi's (Eds.), ophthalmic plastic and reconstructive surgery. Springer Press.
- 4. Abdel Razek AAKA and Elkhamary S (2011):** MRI of retinoblastoma. *The British Journal of Radiology*, 84: 775-784.
- 5. Elkhamary SM (2012):** Lacrimal gland lesions: can addition of diffusion-weighted MR imaging improve diagnostic accuracy in characterization? *The Egyptian Journal of Radiology and Nuclear Medicine*, 43: 165-172.