

## Comparative Study between Myoring and Ferrara Ring Intracorneal Implantation Using Femtosecond Laser for Treatment of Keratoconus

Hany M. Sammour, Mahmoud M. Ismail, Abdelghany I. Abdelghany, Mahmoud A. Shafeek  
Department of ophthalmology, Faculty of Medicine, Al-Azhar University, Cairo, Egypt\*

### ABSTRACT

**Background:** Keratoconus is a bilateral progressive, non-inflammatory ectatic corneal disease characterized by changes in corneal collagen structure and organization. Though the etiology remains unknown, novel techniques are continuously emerging for the diagnosis and management of the disease. Intracorneal rings are an effective way for treating keratoconus; the surgery is safe and has an adequate biocompatibility. The procedure is adjustable and reversible and, most importantly, effective in improving unaided visual acuity (UAVA), best corrected visual acuity (BCVA).

**Aim of the Work:** To compare the efficacy of MyoRing versus Ferrara ring using femtosecond laser for treatment of keratoconus as regards the visual outcome, refractive changes, keratometry reading (K-max), proper depth tilt and haze by anterior segment OCT and complications.

**Patients and Methods:** This study included forty eyes of patients with keratoconus. They were divided into two groups. Group (A) included twenty eyes of patients with keratoconus subjected to femtosecond laser assisted MyoRing implantation, while Group (B) included twenty eyes of patients with keratoconus subjected to femtosecond laser assisted Ferrara ring implantation.

**Results:** In group (A) MyoRing all patients showed improvement in UAVA, BCVA, refraction and K-max except 4 patients (20%) who showed no visual improvement despite the refractive and topographic improvement. Using the anterior segment OCT in interpretation of visual, refractive and topographic findings showed that those 4 patients had their MyoRings implanted at shallower depth with presence of intracorneal ring tilt. In group (B) Ferrara ring all patients showed improvement in UAVA, BCVA, refraction and K-max except 2 patients (10%) who showed no visual improvement despite the refractive and topographic improvement. Using the anterior segment OCT in interpretation of visual, refractive and topographic findings showed that those 2 patients had their Ferrara rings implanted at shallower depth with presence of intracorneal ring tilt.

**Conclusion:** In comparison between two rings, there were no differences in different parameters except that the Ferrara ring showed more improvement in BCVA and spherical component. Using the anterior segment OCT in assessment of implanted rings, helped us to explain the non-improvement in visual outcomes despite the refractive and topographic improvements.

**Keywords:** keratoconus, Anterior segment OCT, MyoRing, Ferrara ring, femtosecond laser.

**INTRODUCTION** Keratoconus is a bilateral progressive, non-inflammatory ectatic corneal disease characterized by changes in corneal collagen structure and organization. Though the etiology remains unknown, novel techniques are continuously emerging for the diagnosis and management of the disease<sup>1</sup>.

Common methods of vision correction for keratoconus range from spectacles and rigid gas permeable contact lenses to other specialized lenses. Corneal collagen cross linking is effective in stabilizing the progression of the disease. Intracorneal ring segments can improve vision by flattening the cornea in patients with mild to moderate keratoconus. Topography guided customized ablation treatment betters the quality of vision by correcting the refractive error and improving the contact lens fit. In advanced keratoconus with corneal scarring, lamellar or full thickness

penetrating keratoplasty will be the treatment of choice<sup>1</sup>.

Intracorneal rings are an effective way for treating keratoconus; the surgery is safe and has an adequate biocompatibility. The procedure is adjustable and reversible and, most importantly, effective in improving unaided visual acuity (UAVA), best corrected visual acuity (BCVA). It reduces the manifest refractive spherical equivalent (MRSE) and keratometry readings, improves contact lens tolerance, and reduces the anisometropia between the two eyes. Intracorneal rings have a positive impact on the quality of life in keratoconic patients<sup>2</sup>.

The Myoring (DIOPTEx) is a complete, flexible, continuous, PMMA ring designed to correct moderate and high myopia. The diameter ranges from 5.0 to 8.0 mm, the thicknesses ranges from 150 to 350 µm and the width of the ring is 0.5mm. The anterior surface

is convex and the posterior surface is flat, with a radius of curvature of 6.0 mm. It can be considered a permanent contact lens, which, rather than being placed on top of the cornea, is squeezed into the cornea slightly underneath the corneal surface<sup>3</sup>.

The Ferrara ICRS are made of polymethylmetacrilate (PMMA) Perspex CQ acrylic segments. They vary in thickness, and are available in 0.15, 0.20, 0.25 and 0.30mm. The segment cross-section is triangular, and the base for every thickness and diameter is 0.60mm. The segments have 90, 120, 160 or 210 degrees of arc<sup>4</sup>.

The femtosecond laser can be programmed to create tunnels for segment placement at predictable corneal depth. Studies show that tunnel creation with femtosecond laser is easier, faster, more precise and more comfortable for the patient over the mechanical technique<sup>5,6</sup>.

Anterior segment OCT quantitative imaging allows comprehensive 3-D quantitative analysis of the keratoconic cornea and the changes produced by ICRS treatment, as well as monitoring of the ICRS three-dimensional location<sup>7</sup>.

#### AIM OF THE WORK

To compare the efficacy of MyoRing versus Ferrara ring using femtosecond laser for treatment of keratoconus as regards the visual outcome, refractive changes, keratometry reading (K-max), proper depth tilt and haze by anterior segment OCT and complications.

#### PATIENTS AND METHODS

Forty eyes of patients with keratoconus were subjected to this study and were divided into two groups. Group (A) included twenty eyes of patients with keratoconus subjected to femtosecond laser assisted MyoRing implantation, while Group (B) included twenty eyes of patients with keratoconus subjected to femtosecond laser assisted Ferrara ring implantation.

##### Study design

A comparative interventional therapeutic study from May 2015 till May 2017.

It was approved by the ethical board of Al-Azhar University and an informed written consent was taken from each participant in the study

##### Patient's selection

##### Inclusion criteria:

- Age: 16 – 40 years.
- Both gender

- Thinnest corneal pachymetry higher than 390 um.
- Maximum keratometry between 48 to 60 D.
- Refraction: Patients with myopic component > astigmatic component where included in group (A) MyoRing and patients with astigmatic component > myopic component where included in group (B) Ferrara ring.
  - Clear central cornea
- B) Exclusion criteria:**
  - Age: <16 or > 40 years.
  - Thinnest pachymetry less than 390micron.
  - Evidence of subepithelial or mid anterior stromal scar or opacities.
  - Maximum Keratometry readings 60 D or more.
  - Pregnancy, diabetes or autoimmune disease.

##### Preoperative evaluation:

A complete ocular examination included: visual acuity, refraction, slit-lamp examination, indirect Ophthalmoscopy, Keratometry and corneal topography.

##### -Visual Acuity:

Uncorrected (UCVA) and best corrected visual acuity (BCVA).

##### -Refraction:

Manifest and cycloplegic refraction were done, cycloplegic refraction is done one hour after instillation of 1% cyclopentolate eye drops.

##### -Slit Lamp Examination:

Anterior segment examination using the slit lamp was performed.

##### -Indirect ophthalmoscopy:

Fundus examination was done to assess the periphery as well as the central part of the retina.

##### -Keratometry and Corneal Topography:

Using corneal topography (Orbscan II and Orbscan III) with the curvature map, corneal thickness map, anterior and posterior elevation maps were done.

##### Nomogram used:

MyoRing diameter and thickness selection were based on manufacturer's nomogram, which is based on central average keratometry reading (average Sim K) (*table 1*)<sup>8</sup>.

Ferrara ring selection was based on manufacturer's nomogram table (*table 2*) (*Figure 1*), which is based on the manifest refraction (subjective) versus centration of the cone<sup>4</sup>.





In our study we preferred to put the incision on the flat meridian guided by the preoperative topography.

**Table (1):** Nomogram for MyoRing implantation

Keratometry	Mesopic pupil (mm)	Diameter (mm)	Thickness (um)
$K \leq 44$	$< 5.5$	6	240
	$< 4.5$	5	240
$44 < K \leq 48$	$\geq 4.5$	6	280
	$< 4.5$	5	280
$48 < K \leq 52$	$\leq 4.5$	6	320
$K \geq 52$	$< 4.5$	5	320

**Table (2):** Nomogram for Ferrara ring implantation

SE (D)	Cone Type I	Cone Type II	Cone Type III	Cone Type IV
$> -10.00$	250/350	250/350	300/350	350/350
-8.25 to -10.00	200/300	200/300	250/300	300/300
-6.25 to -8.00	150/250	150/250	200/250	250/250
-4.25 to -6.00	0/200	0/200	150/200	200/200
$< -4.00$	0/150	0/150	150/150	150/150

Map	Distribution of Ectasia	Description
	0%/100%	All the ectatic area is located at one side of the cornea.
	25%/75%	75% of the ectatic area is located at one side of the cornea.
	33%/66%	66% of the ectatic area is located at one side of the cornea.
	50%/50%	The ectatic area is symmetrically distributed on the cornea.

**Figure (1):** Nomogram selection for Ferrara ring.

**The procedure:**

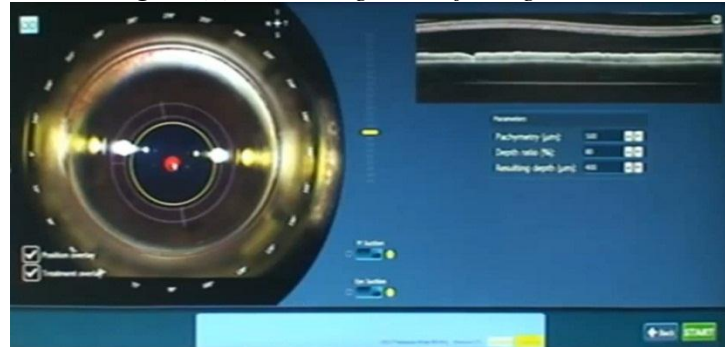- The procedure was performed under topical anesthesia using benoxinate hydrochloride 0.4%.
- Povidone iodine (Betadine) 5% was used to sterilize the eye, and povidone iodine 10% to sterilize the eyelids and surrounding skin.
- A plastic sterile drape (Opsite) was applied to draw away the lashes, followed by the application of a wire speculum to separate the eyelids.
- Placement of a suction ring to the eye followed by docking of the cone (**Figure 2**), centering and adjusting cone with Intraoperative guided anterior segment OCT (**Figure 3**).
- A tunnel for Ferrara ring (*Ferrara, AJL, Spain*) (**Figure 4**) and a pocket for Myoring (*Keratex, ITM, USA*) implantation were performed at 80% of the corneal thickness with the aid of femtosecond laser (**Figure 5**).
- After clearance of the gas bubbles, a spatula was passed gently (**Figure 6**) and the intracorneal rings were implanted under full aseptic conditions with a special forceps and placed in the final position with a Sinskey hook (**Figure 7**).
- Contact lens was then applied.



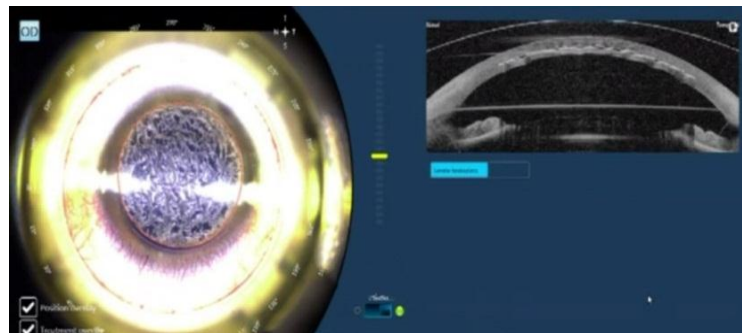
**Figure (2):** Docking of the cone.



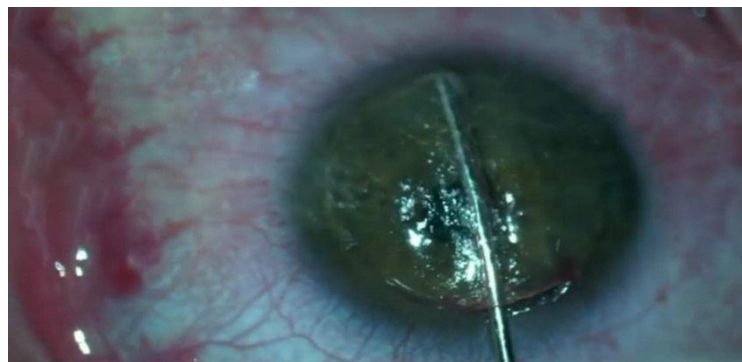*Figure (3): Centering and adjusting cone.*



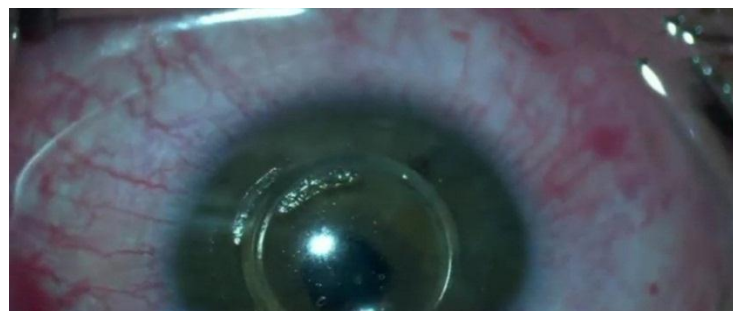*Figure (4): Tunnel creation for Ferrara ring.*



*Figure (5): Pocket creation for MyoRing.*



*Figure (6): Passing a spatula gently.*



*Figure (7): MyoRing insertion into the pocket.*

**Post-operative medication:**

- Topical Antibiotic eye drops (e.g. Gatifloxacin 0.3%, 5times/day for one week).
- Topical steroid eye drops (e.g. Prednisolone acetate 1%, 5times/day for one week).
- Lubricant eye drops.

**Postoperative follow-up:**

All patients were followed up for one year (1<sup>st</sup> month, 3<sup>rd</sup> month, 6<sup>th</sup> month and 12<sup>th</sup> month ), with corneal topography was done at 3<sup>rd</sup>, 6<sup>th</sup>month and anterior segment OCT at 3<sup>rd</sup> month.

*Both groups were compared as regards to:*

- Uncorrected visual acuity improvement.
- Best corrected visual acuity improvement.
- Astigmatism reduction.
- Spherical reduction.
- Keratometry reading (K-max).
- Postoperative complications (e.g. extrusion, deposits, infection).

Anterior segment OCT was done at 3<sup>rd</sup> month to assess intracorneal ring depth, tilt and haze

The depth of the intracorneal ring was measured from the apex of the ring perpendicular to the anterior corneal surface.

Tilt was measured by drawing a straight line (using anterior segment OCT software) between the inner edges of the intracorneal ring in both the vertical and horizontal cut scans passing through the apex of the cornea.

The anterior segment OCT was also used to assess the corneal haze which was defined as hyperreflective area along the site of insertion of intracorneal rings.

**The study was done after approval of ethical board of al-Azhar university and an informed written consent was taken from each participant in the study.**

**Statistical analysis**

*Table (3): Comparison between groups according to demographic data.*

Demographic Data	Group (A) MyoRing	Group (B) Ferrara	t/x2*	p-value
<b>Age (years)</b>				
Mean±SD	27.75±5.46	24.75±5.56		
Range	17_38	17_35	2.965	0.093
<b>Gender</b>				
Female	7(58.33%)	6(64.15%)		
Male	5(41.67%)	7(53.85%)	0.404*	0.525

**Mean Sphere readings:**

*In Group (A)* mean preoperative sphere was -10.96±5.31 D which shows a highly statistically significant difference along the periods of follow up postoperatively p-value was <0.001

Data were analyzed using Statistical Program for Social Science (SPSS) version 20.0. Quantitative data were expressed as mean± standard deviation (SD). Qualitative data were expressed as frequency and percentage.

The following tests were done:

- Independent-samples t-test of significance was used when comparing between two means.
- Paired sample t-test of significance was used when comparing between related samples.
- Chi-square (X2) test of significance was used in order to compare proportions between two qualitative parameters.
- Probability (P-value)
  - P-value <0.05 was considered significant.
  - P-value <0.001 was considered as highly significant.
  - P-value >0.05 was considered insignificant.

**RESULTS**

**Demographic Data:**

*In Group (A)* twenty eyes of 12 patients had Femtosecond laser assisted MyoRing implantation. There were 7 females (58.33%) from which 5 had a bilateral MyoRing implantation and 5 males (41.67%) from which 3 had a bilateral MyoRing implantation. The mean age was 27.75±5.46SD years (range: 17-38 years).

*In Group (B)* twenty eyes of 13 patients had Femtosecond laser assisted Ferrara ring implantation. There were 6 females (46.15%) from which 4 had a bilateral Ferrara ring implantation and 7 males (53.85%) from which 3 had a bilateral Ferrara ring implantation. The mean age was 24.75±5.56 years (range: 17-35 years).

*Comparison between Groups* there were no statistically significant difference between groups according to demographic data.

**Table (4):** Difference between preoperative and follow-up postoperatively according to sphere in group (A).

Sphere	Group (A) MyoRing	Mean Diff.	t-test	p-value
<b>Preoperative</b>	-10.96±5.31			
<b>At 1st month</b>	-4.50±5.94	-6.46	-10.95	<0.001
<b>At 3rd month</b>	-4.33±5.64	-6.64	-11.72	<0.001
<b>At 6th month</b>	-4.23±5.51	-6.74	-12.00	<0.001
<b>At 12 month</b>	-4.00±4.97	-6.96	-12.73	<0.001

*In group (B)* mean preoperative sphere was -3.79±3.47 D which shows a highly statistically significant difference along the periods of follow up postoperatively p-value was <0.001.

**Table (5):** Difference between preoperative and follow up postoperatively according to sphere in group (B).

Sphere	Group (B) Ferrara	Mean Diff.	t-test	p-value
<b>Preoperative</b>	-3.79±3.47			
<b>At 1st month</b>	0.19±2.42	-3.98	-5.99	<0.001
<b>At 3rd month</b>	0.13±1.86	-3.91	-6.02	<0.001
<b>At 6th month</b>	-0.19±1.43	-3.60	-5.43	<0.001
<b>At 12 month</b>	-0.11±1.24	-3.68	-5.83	<0.001

*In Comparison between Groups* there was a statistically significant difference between two groups throughout the follow up period as regard the spherical reading.

**Table (6):** Comparison between groups according to sphere.

Sphere	Group (A) MyoRing	Group (B) Ferrara	t-test	p-value
<b>Preoperative</b> Mean±SD Range	-10.96±5.31 -21_-5	-3.79±3.47 -11.75_2	25.561	<0.001
<b>At 1st month</b> Mean±SD Range	-4.50±5.94 -17.5_3	0.19±2.42 -4_4	10.683	0.002
<b>At 3rd month</b> Mean±SD Range	-4.33±5.64 -16.75_2	0.13±1.86 -3_3	11.241	0.002
<b>At 6th month</b> Mean±SD Range	-4.23±5.51 -15.5_2	-0.19±1.43 -3_2.5	10.059	0.003
<b>At 12 month</b> Mean±SD Range	-4.00±4.97 -14.5_1	-0.11±1.24 -2.75_2	11.539	0.002

**Mean Cylinder reading:**

*In Group (A)* mean preoperative cylinder was -3.85±3.23 D which shows a statistically significant difference along the periods of follow up postoperatively.

**Table (7):** Difference between preoperative and follow up postoperatively according to cylinder in group (A).

Cylinder	Group (A) MyoRing	Mean Diff.	t-test	p-value
<b>Preoperative</b>	-3.85±3.23			
<b>At 1st month</b>	-2.40±1.67	-1.45	-2.89	0.009
<b>At 3rd month</b>	-2.24±1.67	-1.61	-3.33	0.003
<b>At 6th month</b>	-1.99±1.59	-1.86	-3.72	0.002
<b>At 12month</b>	-1.50±1.54	-2.35	-4.13	0.002

*In group (B)* mean preoperative sphere was -6.13±2.52 D which shows a highly statistically significant difference along the periods of follow up postoperatively p-value was <0.001.

**Table (8):** Difference between preoperative and follow up postoperatively according to cylinder in group (B).

Cylinder	Group (B) Ferrara	Mean Diff.	t-test	p-value
<b>Preoperative</b>	-6.13±2.52			
<b>At 1st month</b>	-1.96±2.00	-4.16	-8.46	<0.001
<b>At 3rd month</b>	-1.56±2.00	-4.56	-8.64	<0.001
<b>At 6th month</b>	-1.25±1.61	-4.88	-9.52	<0.001
<b>At 12month</b>	-1.24±1.60	-4.89	-9.58	<0.001

*In Comparison between Groups* there was a no statistically significant difference between two groups throughout the follow ups as regard the cylinder reading.

**Table (9):** Comparison between groups according to change of cylinder.

Cylinder	Group (A) MyoRing	Group (B) Ferrara	t-test	p-value
<b>Preoperative</b> Mean±SD Range	-3.85±3.23 -11_-0.25	-6.13±2.52 -10_-0.25	6.173	0.017
<b>At 1st month</b> Mean±SD Range	-2.40±1.67 -5_0	-1.96±2.00 -8_1.75	0.563	0.457
<b>At 3rd month</b> Mean±SD Range	-2.24±1.67 -5_0	-1.56±2.00 -8_1.75	1.337	0.255
<b>At 6th month</b> Mean±SD Range	-1.99±1.59 -5_0	-1.25±1.61 -7_1	2.127	0.153
<b>At 12month</b> Mean±SD Range	-1.50±1.54 -4.5_2	-1.24±1.60 -7_1	0.279	0.600

**Mean UAVA:**

*In Group (A)* mean preoperative UAVA was 1.20±0.030 LogMAR (range 0.1-1.4 Log MAR)

*In group (B)* mean preoperative UAVA was 1.04±0.33 LogMAR (range 0.2-1.4 LogMAR).

*In Comparison between Groups* there was a no statistically significant difference between two groups throughout the follow up postoperatively.

**Table (10):** Comparison between groups according to unaided visual acuity.

UAVA (LogMAR)	MyoRing	Ferrara ring	t-test	p-value
<b>Preoperative</b> Mean±SD Range	1.20±0.30 0.1-1.4	1.04±0.33 0.2-1.4	2.609	0.115
<b>At 1st month</b> Mean±SD Range	0.65±0.33 0.2-1.3	0.71±0.25 0.3-1	0.504	0.482
<b>At 3rd month</b> Mean±SD Range	0.64±0.33 0.2-1.3	0.71±0.25 0.3-1	0.574	0.453
<b>At 6th month</b> Mean±SD Range	0.62±0.32 0.2-1	0.67±0.25 0.3-1	0.309	0.581
<b>At 12 month</b> Mean±SD Range	0.61±0.32 0.2-1	0.65±0.24 0.3-1	0.156	0.695

**Mean BCVA:**

*In Group (A)* mean preoperative BCVA was 0.92±0.29 LogMAR (range 0.4-1.3 LogMAR)

*In group (B)* mean preoperative BCVA was 0.75±0.33 LogMAR (range 0.3-1.3 LogMAR).

*In Comparison between Groups* there was a statistically significant difference between two groups at the end of follow up.

**Table (11): Comparison between groups according to best corrected visual acuity.**

BCVA (LogMAR)	MyoRing	Ferrara ring	t-test	p-value
<b>Preoperative</b>				
Mean±SD	0.92±0.29	0.75±0.33	3.11	0.086
Range	0.4-1.3	0.3-1.3		
<b>At 1st month</b>				
Mean±SD	0.50±0.29	0.31±0.16	6.413	0.016
Range	0.1-1	0.1-0.7		
<b>At 3rd month</b>				
Mean±SD	0.45±0.29	0.42±0.28	0.11	0.742
Range	0.1-1	0.2-1		
<b>At 6th month</b>				
Mean±SD	0.42±0.31	0.47±0.34	0.194	0.662
Range	0.1-1	0.2-1		
<b>At 12 month</b>				
Mean±SD	0.39±0.31	0.67±0.36	6.709	0.014
Range	0.1-1	0.2-1		

**Mean K-max Readings:**

**In Group (A)** mean preoperative K-max was 52.56±4.44 SD (range 47.4\_59.8 D)

**In group (B)** mean preoperative K-max was 52.90±3.93 SD (range 46.4\_59 D).

**In Comparison between Groups** there was a no statistically significant difference between two groups throughout the follow up postoperatively.

**Table (12): Comparison between groups according to K-max.**

Kmax	Group (A) MyoRing	Group (B) Ferrara	t-test	p-value
<b>Preoperative</b>				
Mean±SD	52.56±4.44	52.90±3.93	0.068	0.795
Range	47.4_59.8	46.4_59		
<b>At 3rd months</b>				
Mean±SD	46.48±5.25	45.97±4.70	0.103	0.750
Range	39.6_56.9	37.7_55.2		
<b>At 6th months</b>				
Mean±SD	46.68±6.07	44.82±4.77	1.148	0.291
Range	39.2_64.4	35.42_53.3		

**Complications:**

No intraoperative complications had occurred during surgeries.

Postoperative complication included only the presence of intrastromal deposits which was observed at first month and lasted throughout the follow up period, **In Group (A)** 4 eyes (20%) had intrastromal deposits, and **In Group (B)** 7 eyes (35%) had intrastromal deposits.

**In Comparison between Groups** there was no statistically significant difference between two groups.

**Table (13): Comparison between groups according to intrastromal deposits.**

Intrastromal deposits	Group (A) MyoRing	Group (B) Ferrara	x2	p-value
At 1st day	0(0.0%)	0(0.0%)	-	-
At 1st month	4(20.0%)	7(35.0%)	1.129	0.288
At 3rd month	4(20.0%)	7(35.0%)	1.129	0.288
At 6th month	4(20.0%)	7(35.0%)	1.129	0.288
At 12 month	4(20.0%)	7(35.0%)	1.129	0.288

**Anterior segment OCT:**

Ant OCT done at the 3<sup>rd</sup> month of follow up to assess the proper depth of intracorneal rings which was defined as 80%±3% of initial corneal thinnest location, presence of intracorneal ring tilt and corneal haze showed:



**In Group (A)** mean depth of implanted rings was 74.43±12.54 % (range 37.9\_82.5 %) with 16 rings (80%) were within the proper depth, 6 rings (30.0%) were tilted, and one ring (5.0%) showed corneal haze.

**In Group (B)** mean depth of implanted rings was 78.35±3.66 % (range 65\_82.5 %) with 18 rings (90.0%) were within the proper depth, 4 rings (20.0%) were tilted, and one ring (5.0%) showed corneal haze.

**In Comparison between Groups** there was a no statistically significant difference between two groups.

**Table (14):** Comparison between groups according to Ant OCT.

Ant OCT	Group (A) MyoRing	Group (B) Ferrara	t/x2*	p-value
<b>Depth</b>				
Mean±SD (%)	74.43±12.54	78.35±3.66	1.802	0.187
Range (%)	37.9-82.5	65-82.5		
<b>Depth%</b>				
More shallow	4(20.0%)	2(10.0%)	0.784*	0.376
Within proper depth	16(80.0%)	18(90.0%)		
<b>Tilt</b>				
No tilt	14(70.0%)	16(80.0%)	0.533*	0.465
Tilted	6(30.0%)	4(20.0%)		
<b>Haze</b>				
Corneal haze	1(5.0%)	1(5.0%)	0.000*	1.000
No corneal haze	19(95.0%)	19(95.0%)		

**DISCUSSION**

Our study included 40 eyes with keratoconus, twenty eyes were subjected to Femtosecond laser assisted MyoRing implantation (Group A), and the other twenty were subjected to Femtosecond laser assisted Ferrara ring implantation (Group B). Preoperative visual acuity, refraction and topography were done, followed by twelve month of follow up of visual acuity, refraction, topography and anterior segment OCT.

To our knowledge this study is the first one to compare between the MyoRing and Ferrara ring intracorneal implantation in keratoconic patients by means of Femtosecond laser technology.

Also unique to our study is the use of Anterior segment OCT in assessment of Femtosecond laser assisted MyoRing implantation.

**Group (A) MyoRing:**

In our study **mean preoperative sphere** was -10.96±5.31 D which showed a highly statistically significant difference along the periods of follow up postoperatively, being -4.50±5.94 D at 1<sup>st</sup> month, -4.33±5.64 D at 3<sup>rd</sup> month, -4.23±5.51 D at 6<sup>th</sup> month and -4.00±4.97 D at 12<sup>th</sup> month.

This goes with a study done by *Hosney et al.*<sup>9</sup> who investigates 15 femtosecond-assisted MyoRing implantation with mean change in sphere postoperatively was 4.45±2.18 D.

*Jabbarvand et al.*<sup>10</sup> in a study done on 98 keratoconic eyes of 98 patients had worst

results, where mean preoperative sphere was -5.48± 4.30 D with postoperative mean change in sphere was 0.08±2.81 D at 1<sup>st</sup> month, 0.08±2.90 D at 3<sup>rd</sup> month, 0.10±2.90 D at 6<sup>th</sup> month and 0.09±2.91 D at 12<sup>th</sup> month. We owe this to the large pool of patients in his study which included keratoconic patients of grade I (15.3%), II (37.7%), III (24.5%) and IV (22.4%).

In our study **mean preoperative cylinder** was -3.85±3.23 D which showed a statistically significant difference along the periods of follow up postoperatively, being -2.40±1.67 D at 1st month, -2.24±1.67 D at 3rd month, -1.99±1.59 D at 6th month, -1.50±1.54 D at 12th month.

This goes with a study done by *Alio et al.*<sup>11</sup> who evaluated the clinical outcome after implantation of the MyoRing by means of femtosecond laser technology on 12 eyes of 11 patients and reported mean preoperative cylinder -6.75±2.99 D which changed postoperatively to -2.07±1.20 D at 1<sup>st</sup> month, -2.07±1.30 D at 3<sup>rd</sup> month and -2.45±1.35 D at 6<sup>th</sup> month.

In comparison to our study *Daxer et al.*<sup>12</sup> performed a study on 15 eyes of 11 patients with keratoconus to assess the results of implantation of MyoRing with mean preoperative cylinder -3.50±1.20 D and reported a statistical significant reduction in cylinder *P*= .0007 postoperatively, however the mean change was less than our study being-

1.27±0.75 D postoperatively. We owe this due to wide range of age included in his study 22 to 60 years old.

In our study mean preoperative UAVA was 1.20±0.030 LogMAR which changed postoperatively to 0.65±0.33 at 1<sup>st</sup> month, 0.64±0.33 at 3<sup>rd</sup> month, 0.62±0.32 at 6<sup>th</sup> month and 0.61±0.32 at 12<sup>th</sup> month.

This goes with the study done by *Alio et al.*<sup>11</sup> who reported mean preoperative UAVA 1.36±0.33 LogMAR which changed postoperatively to 0.69±0.32 at 1<sup>st</sup> month, 0.60±0.30 at 3<sup>rd</sup> month and 0.61±0.25 at 6<sup>th</sup> month.

This was also consistent with *Jabbarvand et al.*<sup>10</sup> who reported mean preoperative UAVA 1.17±0.36 LogMAR which changed postoperatively to 0.66±0.31 at 1<sup>st</sup> month, 0.60±0.25 at 3<sup>rd</sup> month, 0.61±0.27 at 6<sup>th</sup> month and 0.62±0.28 at 12<sup>th</sup> month.

In our study the mean preoperative BCVA was 0.92±0.29 LogMAR which changed postoperatively to 0.50±0.29 at 1<sup>st</sup> month, 0.45±0.29 at 3<sup>rd</sup> month, 0.42±0.31 at 6<sup>th</sup> month and 0.39±0.31 at 12<sup>th</sup> month.

This goes with the study done by *Alio et al.*<sup>11</sup> who reported mean preoperative BCVA 0.43±0.24 LogMAR which changed postoperatively to 0.44±0.26 at 1<sup>st</sup> month, 0.33±0.22 at 3<sup>rd</sup> month and 0.32±0.18 at 6<sup>th</sup> month.

Also *Jabbarvand et al.*<sup>10</sup> in his study reported preoperative mean BCVA 0.85±0.26 LogMAR and changed postoperatively to 0.51±0.24 at 1<sup>st</sup> month, 0.48±0.21 at 3<sup>rd</sup> month, 0.47±0.23 at 6<sup>th</sup> month and 0.52±0.22 at 12<sup>th</sup> month.

In our study *mean preoperative K-max* was 52.56±4.44 D, which changed postoperatively to 46.48±5.25 D at 3<sup>rd</sup> month and 46.68±6.07 D at 6<sup>th</sup> month.

This correlates with the 18 month study done by *Mohebbi et al.*<sup>13</sup> on 47 eyes of 46 patients with keratoconus and reported preoperative mean K-max 53.57±3.72 D which changed postoperatively to 46.20±4.34 D at 3<sup>rd</sup> month and 47.08±3.84 D at 6<sup>th</sup> month.

Our results was also consistent with a study done by *Al-Tuwairqui et al.*<sup>14</sup> who investigates 18 eyes with femtosecond laser-assisted MyoRing implantation with mean preoperative K-max 51.46±4.38 D which changed postoperatively to 45.10±3.37 D in 3<sup>rd</sup> month and 43.71±1.57 D in 6<sup>th</sup> month.

This also goes with a study done by *Janani et al.*<sup>15</sup> who investigates 40 eyes MyoRing implantation with mean preoperative K-max 52.73±4.14 D which changed postoperatively to 49±24D with 3 years of follow up.

In our study no *intraoperative complication* had occurred, this is consistent with the studies done by *Daxer et al.*<sup>8</sup>, *Alio et al.*<sup>10</sup>, *Jabbarvand et al.*<sup>11</sup> and *Janani et al.*<sup>15</sup>. Postoperative included the presence of intrastromal deposits in 4 eyes (20%)<sup>8,10,11,15</sup>.

In our study *the Anterior segment OCT showed mean* depth of implanted rings 74.43±12.54 % with 16 rings (80%) within the proper depth, 6 rings (30.0%) tilted, and one ring (5.0%) showed corneal haze.

Using the anterior segment OCT in interpretation of our results helped us to explain the non-improvement in BCVA in 4 patients (20%) despite the improvement in their refractive and topographic results, as it showed that the MyoRing implanted in those patient were placed at a shallower depth than the preoperative planned one, being implanted at a depth 37.90%, 60.30%, 54.30% and 52.50% of the initial thinnest corneal location.

Also using the anterior segment OCT showed that the MyoRings implanted in those 4 eyes were tilted, which can explain the non-improvement in BCVA despite the refractive and topographic improvement, mostly through induction of high order aberrations.

#### **Group (B) Ferrara ring:**

The refractive results in our study were a little bit different from other studies published.

In our study *mean preoperative sphere* was -3.79±3.47 D which shows a highly statistically significant difference along the periods of follow up postoperatively, being 0.19±2.42 D at 1st month, 0.13±1.86D at 3rd month, -0.19±1.43 D at 6th month and -0.11±1.24 D at 12th month.

In a retrospective study done by *Kaya et al.*<sup>16</sup> on 17 eyes with keratoconus implanted Ferrara ring using femtosecond Laser technology, he reported mean preoperative sphere -3.95±1.41 D which changed to -1.81±2.11 D at one year postoperative.

Also *Ancèle et al.*<sup>17</sup> studied the effect of Ferrara ring implantation in 25 eyes of 25 patients with keratoconus and showed a mean preoperative sphere -4.39±5.18 D which changed postoperatively to -2.34±4.99 D at 1<sup>st</sup> month, -3.21±4.98 D at 3<sup>rd</sup> month and -1.83±3.16 D at 6<sup>th</sup> month.

In our study *mean preoperative cylinder* was -6.13±2.52 D which shows a statistically significant difference along the periods of follow up postoperatively, being -1.96±2.00 D at 1st month, -1.56±2.00 D at 3rd month, -1.25±1.61 D at 6th month and -1.24±1.60 D at 12th month.

**Kwitko and Severo**<sup>18</sup> in retrospective study with mean follow up 13.0 month assessed the outcome of Ferrara intracorneal ring segment for 51 keratoconus eyes of 47 patients and reported mean preoperative cylinder  $-3.82 \pm 2.13$  D which changed postoperatively to  $-2.16 \pm 2.07$  D.

**Kaya et al.**<sup>16</sup> also showed a mean preoperative cylinder  $-3.54 \pm 1.26$  D which changed to  $-2.31 \pm 1.03$  at one year postoperative.

**Ancèle et al.**<sup>17</sup> showed a mean preoperative cylinder  $-4.19 \pm 2.06$  D which changed postoperatively to  $-2.77 \pm 1.72$  at 1<sup>st</sup> month,  $-2.75 \pm 1.62$  at 3<sup>th</sup> month and  $-2.57 \pm 1.47$  at 6<sup>th</sup> month.

**Hamdi**<sup>19</sup> also studied the effect of Ferrara intrastromal corneal ring segment implantation in 100 cases of keratoconus and reported mean preoperative cylinder  $5.18 \pm 2.10$  D which changed postoperatively to  $-2.90 \pm 2.50$  D at 6<sup>th</sup> month.

Unlike the refractive results, the change in UAVA and BCVA were greater in our study compared to other studies.

In our study the *mean preoperative UAVA* was  $1.04 \pm 0.33$  LogMAR which changed postoperatively to  $0.71 \pm 0.25$  at 1<sup>st</sup> month,  $0.71 \pm 0.25$  at 3<sup>rd</sup> month,  $0.67 \pm 0.25$  at 6<sup>th</sup> month and  $0.65 \pm 0.24$  at 12<sup>th</sup> month, with 19 patients (95%) had improvement in UAVA.

**Kwitko and Severo**<sup>18</sup> in their retrospective study with mean follow up 13.0 month showed improvement in UCVA in 86.4% of eyes.

**Kaya et al.**<sup>16</sup> in his study showed improvement in UAVA in 88.2% of patients.

In our study the *mean preoperative BCVA* was  $0.75 \pm 0.33$  LogMAR which changed postoperatively to  $0.31 \pm 0.16$  at 1<sup>st</sup> month,  $0.42 \pm 0.28$  at 3<sup>rd</sup> month,  $0.47 \pm 0.34$  at 6<sup>th</sup> month and  $0.67 \pm 0.36$  at 12<sup>th</sup> month, with 18 patients (90%) had improvement in BCVA.

**Kwitko and Severo**<sup>18</sup> in their retrospective study with mean follow up 13.0 month showed improvement in BCVA in 86.4% of eyes. Also **Ancèle et al.**<sup>17</sup> showed an improvement in BCVA in 72.8% of his patients. **Hamdi**<sup>19</sup> reported in his prospective study 64% improvement in BCVA.

Also the mean change in K-max in our study was greater than other studies.

In our study the *mean preoperative K-max* was  $52.90 \pm 3.93$  D, which changed postoperatively to  $45.97 \pm 4.70$  D at 3<sup>rd</sup> month and  $44.82 \pm 4.77$  D at 6<sup>th</sup> month.

**Kaya et al.**<sup>16</sup> showed a mean preoperative K-max  $51.95 \pm 3.78$  D which changed

postoperatively to  $48.67 \pm 3.00$  at one year postoperative.

**Ancèle et al.**<sup>17</sup> showed a mean preoperative K-max  $54.27 \pm 6.52$  D which changed postoperatively to  $51.42 \pm 5.75$  at 3<sup>th</sup> month and  $50.39 \pm 4.88$  at 6<sup>th</sup> month.

In our study no *intraoperative complication* had occur which was consisting with **Kaya et al.**<sup>16</sup> and **Ancèle et al.**<sup>17</sup>.

Postoperative complications included the presence of intrastromal deposits in 7 eyes (35%). **Ruckhofer et al.**<sup>20</sup> reported the presence of intrastromal deposits in the lamellar channels with incidence up to 60% with severity of the deposits increased with segment thickness.

In our study *the Anterior segment OCT showed* that the mean depth of implanted rings was  $78.35 \pm 3.66$  % with 18 rings (90.0%) were within the proper depth, 4 rings (20.0%) were tilted, and one ring (5.0%) showed corneal haze.

**In 2012 Ortiz et al.**<sup>7</sup> conducted a study on ten keratoconic eyes to characterize the geometrical properties of keratoconic corneas upon intracorneal ring segments implantation using anterior segment OCT, and reported that the 3D ICRS depth correlated with the ICR planned depth which was higher for femtosecond technique ( $15 \pm 20$  um between the planned and achieved depth), and showed a small tilt of the ICR between 7 and 90 days postoperative.

We can claim that the overall results of our study were better than other studies published about the Ferrara ring implantation in keratoconic patients, however our refractive results were less than other studies, the improvement in UAVA and BCVA were greater, which was confirmed also by improvement in topographic findings.

Using the anterior segment OCT in interpretation of our results helped us to explain the non-improvement in BCVA in 2 patients (10%) despite the improvement in their refractive results, as it showed that the Ferrara rings segments implanted in those patients were placed at a shallower depth than the preoperative planned one, being implanted at a depth 72.9% and 65% of the initial thinnest corneal location.

Also using the anterior segment OCT showed that the Ferrara rings implanted in those 2 eyes were tilted, which can explain the non-improvement in BCVA despite the refractive improvement, mostly through induction of high order aberrations.

**Lyra et al.**<sup>21</sup> in a recent retrospective study done on 241 eyes in 182 patients with keratoconus analyzed the topographic findings

after Ferrara intracorneal ring segment implantation and compared those changes with visual outcomes and reported that the implantation of the Ferrara ICRS changes the corneal tomographic parameters in both anterior and posterior surfaces but despite the changes in corneal parameters a poor correlation was found with the visual outcomes with further study to be done. We claim that the use of anterior segment OCT in interpretation of visual and topographic findings can explain the outcomes after intracorneal ring implantation.

***In Comparison between the two Groups:***

There was a statistical significant difference between two groups throughout the follow up periods postoperatively as regard the **mean spherical reading** being more in group(B) Ferrara ring with  $p=0.002$  at 1<sup>st</sup> month,  $p=0.002$  at 3<sup>rd</sup> month,  $p=0.003$  at 6<sup>th</sup> month and  $p=0.002$  at 12<sup>th</sup> month.

**The mean cylinder reading** showed no statistical significant difference between two groups throughout the follow up periods postoperatively.

**As regard the mean change in UAVA** there was a no statistical significant difference between two groups throughout the follow up periods postoperatively.

**The mean change in BCVA** showed a statistical significant difference between two groups throughout the follow up periods postoperatively being more in group (B) Ferrara ring with  $p=0.019$  at 1<sup>st</sup> month,  $p=0.033$  at 3<sup>rd</sup> month,  $p=0.027$  at 6<sup>th</sup> month and  $p=0.028$  at 12<sup>th</sup> month.

There was no statistical significant difference between two groups throughout the follow up periods postoperatively as regard the **K-max readings**.

**The postoperative complications and anterior segment OCT** findings showed also no statistical difference between two groups.

**CONCLUSION**

Intracorneal rings are one of the most effective treatments in the management of keratoconic patients. It is a safe and reversible technique, which can regularize the irregular corneal surface resulting in improvement of visual function in non-progressive patients.

Using the femtosecond laser technology has allowed us to implant the intracorneal rings at the desired depth which minimize to a great extent the intraoperative complication.

Using the anterior segment OCT in assessment of implanted rings, helped us to explain the non-improvement in visual

outcomes despite the refractive and topographic improvements.

In comparison between two rings, there were no differences in different parameters except that the Ferrara ring showed more improvement in BCVA and spherical component.

**REFERENCES**

- (1) **Shetty R, Kaweri L, Pahuja N, Nagaraja H, Wadia K, Jayadev C, Nuijts R and Arora V (2015):** Current review and a simplified "five-point management algorithm" for keratoconus. *Indian J Ophthalmol.*, 63:46-53.
- (2) **de Freitas SPJ, Avila MP, Paranhos A and Schor P (2010):** Evaluation of the impact of intracorneal ring segments implantation on the quality of life of patients with keratoconus using the NEIRQL (National Eye Institute Refractive Error Quality of life) instrument. *Br J Ophthalmol.*, 94:101-5.
- (3) **David P, Piñero, Jorge L and Alio JL (2010):** Intracorneal ring segments in ectatic corneal diseases. *Clin. Exp. Ophthalmol.*, 38: 154–67.
- (4) **Torquetti L, Ferrara G, Almeida F, Cunha L, Ferrara P, and Merayo-Loves J (2013):** Clinical outcomes after intrastromal corneal ring segments reoperation in keratoconus patients. *Int J Ophthalmol.*, 6 (6):796-800.
- (5) **Shabayek MH and Alió JL (2007):** Intrastromal corneal ring segment implantation by femtosecond laser for keratoconus correction. *Ophthalmol.*, 114:1643–52.
- (6) **Ertan A and Kamburoğlu G (2007):** Analysis of centration of Intacs segments implanted with a femtosecond laser. *J Cataract Refract Surg.*, 33:484–7.
- (7) **Ortiz S, Pérez-Merino P, Alejandro N, Gamba E, Jimenez-Alfaro I and Marcos S (2012):** Quantitative OCT-based corneal topography in keratoconus with intracorneal ring segments. *Biomed Opt Express*, 3(5): 814–24.
- (8) **Daxer A, Mahmoud H and Venkateswaran RS (2010):** Intracorneal continuous ring implantation for keratoconus: one-year follow-up. *J Cataract Refract Surg.*, 36(8): 1296-302.
- (9) **Hosney M, El-Mayah E, Sidky MK and Anis M (2015):** Femtosecond laser-assisted implantation of complete versus incomplete rings for keratoconus treatment. *Clin Ophthalmol.*, 9:121-7.
- (10) **Jabbarvand M, Salamatrad A, Hashemian H, Mazloumi M and Khodaparast M (2013):** Continuous intracorneal ring implantation for keratoconus using a femtosecond laser. *J Cataract Refract Surg.*, 39(7).
- (11) **Alio JL, Piñero DP and Daxer A (2011):** Clinical Outcomes after Complete Ring Implantation in Corneal Ectasia Using the Femtosecond Technology. A Pilot Study. *Ophthalmol.*, 118(7).
- (12) **Daxer A, Mahmoud H and Venkateswaran RS (2010):** Intracorneal continuous ring implantation for keratoconus: one-year follow-up. *J Cataract Refract Surg.*, 36(8): 1296-302.

- (13) Mohebbi M, Hashemi H, Asgari S, Bigdeli S and Zamani KA (2016): Visual outcomes after femtosecond-assisted intracorneal MyoRing implantation: 18 months of follow-up. *Graefes Arch Clin Exp Ophthalmol.*, 254(5):917-22.
- (14) Al-Tuwairqui WS, Osuagwu UL, Razzouk H, AlHarbi A and Ogbuehi KC (2016): Clinical evaluation of two types of intracorneal ring segments (ICRS) for keratoconus. *Int Ophthalmol.*, 1:1-14.
- (15) Janani L, Jadidi K, Mosavi SA, Nejat F, Naderi M and Nourijelyani K (2016): Myo Ring Implantation in Keratoconic patients: 3 years Follow-up Data. *J Ophthalmic Vis Res.*, 11(1):26-31.
- (16) Kaya V, Utine CA, Karakus SH, Kavadarli I and Yilmaz OF (2011): Refractive and visual outcomes after Intacs vs Ferrara intrastromal corneal ring segment implantation for keratoconus: A comparative study. *J Refract Surg.*, 27(12):907-12.
- (17) Ancèle E, Malecaze F, Arné JL and Fournié P (2011): Predictive factors for successful Ferrara intracorneal ring segment implantation in keratoconus. *J Fr Ophtalmol.*, 34(8):513-20.
- (18) Kwitko S and Severo NS. (2004): Ferrara intracorneal ring segment for keratoconus. *J Cataract Refract Surg.*, 30(4):812-20.
- (19) Hamdi IM (2011): Preliminary results of intrastromal corneal ring segment implantation to treat moderate to severe keratoconus. *J Cataract Refract Surg.*, 37(6):1125-32.
- (20) Ruckhofer J, Twa MD and Schanzlin DJ (2000): Clinical characteristics of lamellar channel deposits after implantation of Intacs. *J Cataract Refract Surg.*, 26 (10): 1473-9.
- Lyra JM, Lyra D, Ribeiro G, Torquetti L, Ferrara P and Machado A (2017): Tomographic Findings After Implantation of Ferrara Intrastromal Corneal Ring Segments in Keratoconus. *J Refract Surg.*, 33(2):110-5.