

Role of Magnetic Resonance Cholangio-Pancreaticography in Differentiating between Benign and Malignant Causes of Biliary Obstruction

Sahar Mohamed El gaafary, Ahmed Samy Abdelrahman,
Zeinab Mahmood Muhammed

Department of radiology, Faculty of Medicine – Ain Shams University

*Corresponding author: sahar61egypt@yahoo.com, ahmedsamy@yahoo.com, Dr.zeinab-mahmood@yahoo.com.

ABSTRACT

Background: the initial evaluation of obstructive jaundice involves distinguishing between intra and extra hepatic biliary obstruction. The goal of any radiologic procedure is to confirm the presence of biliary obstructive by detecting biliary dilatation, its exact location, extent and probable cause. **Aim of the Study:** to evaluate the role of Magnetic Resonance Cholangio-Pancreatography in differentiating benign from malignant causes of biliary obstruction using surgical, ERCP or histopathological findings as a gold standard. **Patients and Methods:** a prospective study done on 20 patients with clinical and laboratory finding suggestive of biliary obstruction. All patients underwent non enhanced MRCP on 1.5 Tesla machine (Philips). The final diagnosis of MRCP was correlated with results of ERCP in addition to biopsy and histological diagnosis to those patients had neoplasms. **Results:** Out of 20 cases, there were 11 benign and 9 malignant cases. Mean age of patients with malignant obstruction was more than benign with slight female preponderance. The diagnostic accuracy of MRCP in differentiating benign from malignant biliary obstructive diseases in correlation with surgical, ERCP and histopathological outcome was 85.7%, 96.3%, and 93.3% respectively. It was found that irregular, asymmetric and long segment narrowing was more common in malignant stricture. **Conclusion:** MRCP is a rapid and non-invasive, procedure in assessing cases with suspicions biliary obstructions. It offered a diagnostic accuracy nearly equivocal to ERCP. MRCP can also replace the diagnostic part of ERCP procedure, so that time is spent only on its therapeutic part, and hence decreasing complications of a lengthy ERCP. **Recommendations:** benign or malignant nature of biliary obstruction can be assured by MRCP by observation of stricture margin, dilatation, and length and accordingly proceed to next step in management. MRCP is an efficient diagnostic procedure for detection of presence, level, cause of obstruction and routinely advocated before any intervention is planned.

Key words: Magnetic resonance cholangio-pancreaticography, benign, malignant, biliary obstruction

Introduction

obstructive jaundice is a type of jaundice in which there is blockage of flow of bile from the liver to the intestine resulting in redirection of excess bile and its products, like bilirubin into the blood. It can lead to complications like ascending cholangitis, hepatorenal syndrome, and mal-absorption and hence requires urgent intervention. The role of radiologist therefore is important in early diagnosis and in accurately delineating the level and the cause of obstruction, thus helping in staging as well as preoperative assessment of tumor respectability⁽¹⁾.

Benign and malignant biliary obstructions are difficult to differentiate with imaging alone. Benign obstruction is most commonly caused by choledocholithiasis. Other causes are post cholecystectomy stricture, inflammatory stricture formation secondary to pancreatitis and idiopathic cause, choledochal cyst, primary sclerosing cholangitis, and Mirrizi syndrome⁽²⁾.

Received: 7/3/2017

Accepted: 14/3/2017

Malignant obstruction is most commonly caused by cholangiocarcinoma. Other causes are cancer head of pancreas, gall bladder carcinoma, lymph nodes and metastasis⁽²⁾.

Ultrasonography (USG) is usually used as initial imaging modality to diagnose the biliary obstruction, but artifacts due to bowel gas, gall bladder and bile duct calculi, breathing artifacts and obesity brings it down in the list of imaging modality of choice in obstructive jaundice⁽³⁾.

CT scan has limited value in helping diagnose CBD stones because many of them are radiolucent and CT scan can only image calcified stones. It is also less useful in the diagnosis of cholangitis because the findings that specifically suggest bile duct infection (increased attenuation due to pus, bile duct wall thickening, and gas) are seen infrequently. Lastly, CT scan is expensive and involves exposure to radiation, both of which

DOI: 10.12816/0038195

lessen the routine use CT scans compared to US examinations ⁽⁴⁾.

Endoscopic Retrograde Cholangio-Pancreatography (ERCP) was the standard established procedure for evaluation of patients with obstructive jaundice. Yet it's an invasive procedure, and has an inherent complication rate of 3–9 % and mortality rate of 0.2–0.5 %. ERCP currently has an almost exclusively therapeutic role ⁽¹⁾.

Magnetic resonance cholangio-Pancreatography (MRCP) is a promising approach for biliary and pancreatic duct imaging, which uses MR imaging to visualize fluid in the biliary and pancreatic ducts as a high signal intensity on heavily T2-weighted sequences. This technique is especially useful in neoplastic diseases of pancreatic or biliary ducts ⁽⁵⁾.

Furthermore, when MRCP is performed as a part of full abdominal examination, it can provide a one-step evaluation of nature and site of ductal disease and the extent and stage of any underlying tumor, including detection of any associated adenopathy or liver metastasis. As MRCP is a noninvasive technique, which is free from complications and of comparable accuracy to ERCP, its role needs to be evaluated in various causes of biliary obstruction ⁽⁶⁾.

Aim of the Work

To evaluate the role of Magnetic Resonance Cholangio-Pancreatography in differentiating benign from malignant causes of biliary obstruction using surgical, ERCP or histopathological findings as a gold standard.

Patients and Methods

This prospective study was done from October 2016 to March 2017. Total 20 patients with clinical and laboratory finding suggestive of biliary obstruction were included in our study. They were 10 males and 10 females ranging in age from 22 years to 72 years with mean age of 51 years. This study was conducted in Radio-diagnosis Department, Ain-shams University. All patients underwent non enhanced MRCP on 1.5 Tesla machine (Philips). The final diagnosis of MRCP was correlated with results of ERCP in addition to biopsy and histological diagnosis to those patients had neoplasms.

● Inclusion criteria

1. Patients with clinical and laboratory finding suggestive of biliary diseases such as: jaundice, pruritis and change in color of the urine or stool.

● Exclusion criteria

Patients who had contraindications to MRI examination such as:

1. Patients with metallic implant insertion.
2. Cardiac pacemakers.
3. Metallic foreign body in-situ.
4. Patients having history of claustrophobia and patients who required sedation or ventilation will be excluded from the study.

II-Methods

All patients in our study were subjected into the following:

A- Clinical assessment including:

Clinical history: symptoms and signs related to the biliary duct disease e.g. right upper quadrant pain, dyspepsia, pruritis, and changes of the urine or stool.

B- Laboratory assessment including:

Laboratory diagnosis of cholestatic jaundice was based on raised liver function tests including total bilirubin, direct bilirubin, total protein, and AST, ALP, GGT, and prothrombin time.

C- Imaging assessment including:

- 1- MRCP was performed for all patients
- 2- ERCP was done in 20 patients with histopathological diagnosis

MRCP technique:

a) Instruction and preparation of the Patient

- Patients were instructed have overnight fast for a least 4 hours prior to the examination to reduce the amount of fluid in the stomach and the small bowel in order not to obscure the extra-hepatic biliary tree.
- It was important to ask the patient to hold breathing respiration that was determined the overall success of the examination.
- No pre-medications or contrast medium was needed, only the in-cooperative children were given oral sedatives.
- As in other MRI examination, it is important to remove any ferromagnetic materials in patients clothes that degrade the images and are potentially hazardous to the patients.

b) Patient Position

The patient lies supine with head first on the examination couch and circular surface (synergy body) coil was used to obtain a high signal-to-noise ratio and high spatial resolution.

c) MRCP protocol

- MRCP examination were performed on a 1.5-T MR unit with using 8 channels circular, polarized, phased array body coil.
- All patients were subjected to MRCP study which consists of image acquisition followed by image processing and analysis.

(1) Image acquisition:-

The entire MR examination was performed under the guidance of a radiologist, to determine the location of MRCP slabs that properly fit the entire length of the common bile duct and intrahepatic ducts.

- First a **multi planner fast field echo (FFE) localizer** upon which the Pulse sequences were planned starting from the diaphragm to

the lower border of both kidneys with slice thickness 9 mm

- then **conventional axial and coronal T2 weighted FSE images of the upper abdomen**

The first step in performing MRCP is to localize the pancreatico-biliary duct. The axial T2 fat spin-echo (FSE)MRI of the upper abdomen served as guide to optimally localize the biliary system and to determine the correct obliquity of the coronal oblique section of MRCP images. The axial sequence was added to minimize the risk of missing small per papillary lesions.

*From the previous axial T2 images the angle of MRCP examination was chosen from the cut at which the CBD or the region of suspected lesion tend to appear. Usually the obliquity of the angle from 20 to 40 degree from the standard coronal plane, to give the maximum coverage for the right and left liver lobes.

Table (1): MRCP protocol parameters.

Scanning parameters	2D T2 SSFSE	3D heavy T2 FAT SAT	Thick slab heavy T2
TR(ms)	1050	1860	3120
TE(ms)	120	840	1200
Time of Scan	1.39	2.33 min	0.02 per slab (30 to 40 sec)
Slice thickness	6.0	3.0 mm	40.0mm
spacing	0.0	0.0	0.0
Freq	256	384	320
phase	224	160	256
NEX	1.00	2.00	1.00
FOV (mm)	40.0	32.0	34.0
Phase FOV	0.90	1.00	1.00
Acquisition plane	Axial /coronal	Coronal oblique	coronal
Hand width (Hz/ pixel)	62.50	62.50	62.50
Matrix size	252x512	268x512	268x166
Flip angle	150°	180	180

2) Image processing:.

The imaging data obtained after the scanning were reviewed on workstation with 2D and 3D capability with multiple editing options.

A- Two Dimensional (2D), Single shot heavily T2 weighted Multisection sequences (single slice technique):

- Breathing hold imaging minimizes motion artifacts, which may interfere with the imaging of small sized bile ducts.
- The angle of the coronal ^{image} could be changed several times and the thick coronal slabs were obtained at different

angles from a horizontal plane pass through the head of pancreas to ensure including the distal part of the pancreatico-biliary tract in all images. The first slab was acquired at the direct coronal plane and about 4-5 slabs with different degrees of obliquity were acquired on either side of the mid horizontal plane.

B-Thick slap Respiratory Triggered Three Dimensional (3D) MR Cholangiopancreatography with MIP Reconstruction

- Multi-section MRCP was performed with respiratory triggering in order to reduce respiratory motion artifacts. The data were acquired between successive respiratory cycles (i.e. from the end of expiration to the beginning of the following inspiration). The use of respiratory triggering increased the actual scan time depending on the patient's breathing pattern and respiration rate.
 - Images were obtained in right anterior oblique plane parallel to the longitudinal axis of the biliary tree.
 - images reconstruction and post processing of the MRCP source images was performed by a radiologist using a MIP image produced in the coronal plane. Then, the radiologist edited and removed unnecessary anatomical details from the image by using a manual cutting device at the work station to form one or few coronal MIP images showing the entire biliary system anatomy.
 - After three dimensional VR and MIP images were obtained, the native axial and coronal thin sections source images were viewed, allowing optimal evaluation of small bile duct branches or any small accessory bile ducts.
- 2- The level of obstruction, the morphological aspect at the obstruction site.
 - 3- Any additional information provided by the axial T1WI and T2WI (tumor depiction with demonstration of its extension, the - presence of lymphadenopathy or metastases).
 - 4- Calculi were diagnosed when rounded, ovoid, or irregularly shaped signal voids were identified within a dilated or non-dilated bile duct.
 - 5- Stenosis was defined as a transition of ductal dilation to signal void or a tapered appearance of CBD
 - 6- Abrupt narrowing of the CBD.
 - 7- The presence of a mass and a stricture with an irregular margin, asymmetric dilatation or long length stricture.

Our results were finally correlated with conventional cholangiography (ERCP, PTC), surgery and percutaneous biopsy.

The study was done after approval of ethical board of Ain- shams university and an informed written consent was taken from each participant in the study.

Statistical analysis

Data analysis was done using rates, ratios and percentages of different diagnosis. Diagnostic effectivity was calculated for MRCP which included sensitivity, specificity and accuracy by comparing with surgical, histopathological or ERCP findings. Statistical analysis was done by using chi-square test and p-value was calculated.

3-Image analysis and interpretation:

In analysis of the MRCP images we focused on the following:

- 1- The degree of dilatation of the intrahepatic and extra hepatic bile ducts and the pancreatic duct.

Results

Table (1): The final diagnosis of 20 patients with clinical suspicious of different biliary diseases.

Type of lesion	No. of lesions	Percentage
Benign	11	55%
Malignant	9	45%
Total	20	100.0%

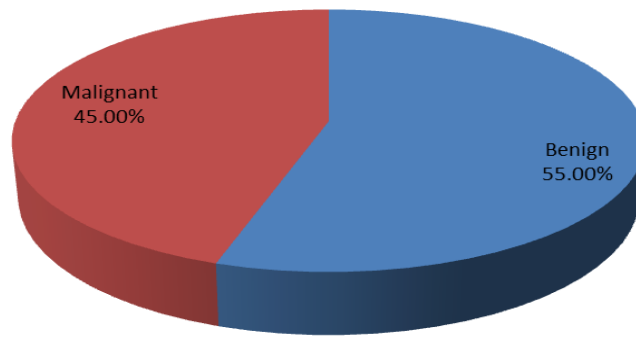


Figure (1): Benign and malignant biliary diseases among the examined cases.

This study included 20 patients were classified into 11 benign lesions (55%) and 9 malignant biliary lesions (45%).

Table (2): The main cause of biliary obstruction in 11 benign lesions.

Benign lesion	No. of cases	Percentage
Calcular obstruction	7	63.6%
Inflamatory stricture	2	18.2%
Choledocal cyst	2	18.2%
Total	11	100%

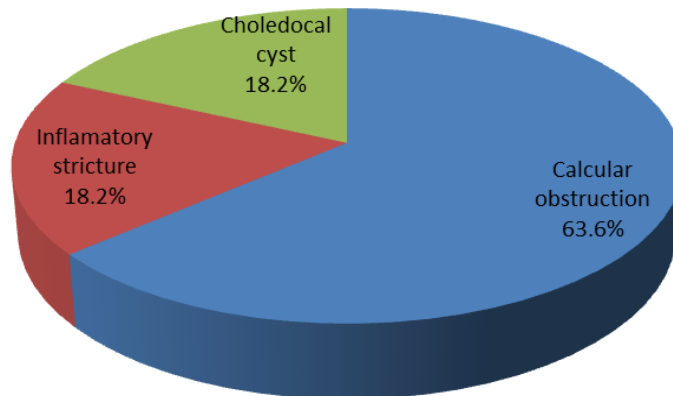


Figure (2): Different benign biliary diseases in 13 patients.

As regard the 11 benign lesions in this study, they were classified as follow: 7 (63.3%) of calcular obstruction, 2 cases (18.2%) of congenital biliary

disease, 2 cases (18.2%) inflamatory stricture, The most common cause of benign obstruction was calcular biliary obstruction.

Table (3): Histopathological diagnosis in 9 malignant cases.

Histopathological type of malignant obstructive jaundice	No. of cases	Percentage
Cholangiocarcinoma	4	44.44%
Metastasis	1	11.11%
Pancreatic head adenocarcinoma	2	22.22%
Periampulary carcinoma	2	22.22%
Total	9	100.00%

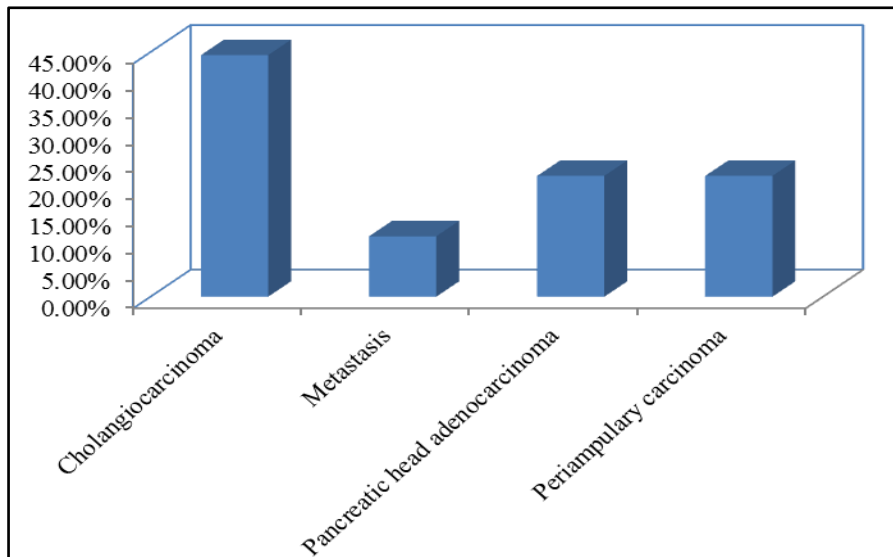


Figure (3): Histopathological type of malignant obstructive jaundice. Malignant biliary diseases in 7 patients.

The most common cause of malignant obstruction was cholangiocarcinoma.

Table (4): Level of obstruction by MRCP in 18 cases.

Level of obstruction	No. of cases	Percentage
Distal CBD	11	61.11%
CHD	3	16.67%
Cystic duct	2	11.11%
Porta - hepatis	1	5.56%
Proximal CBD	1	5.56%
Total	18	100.00%

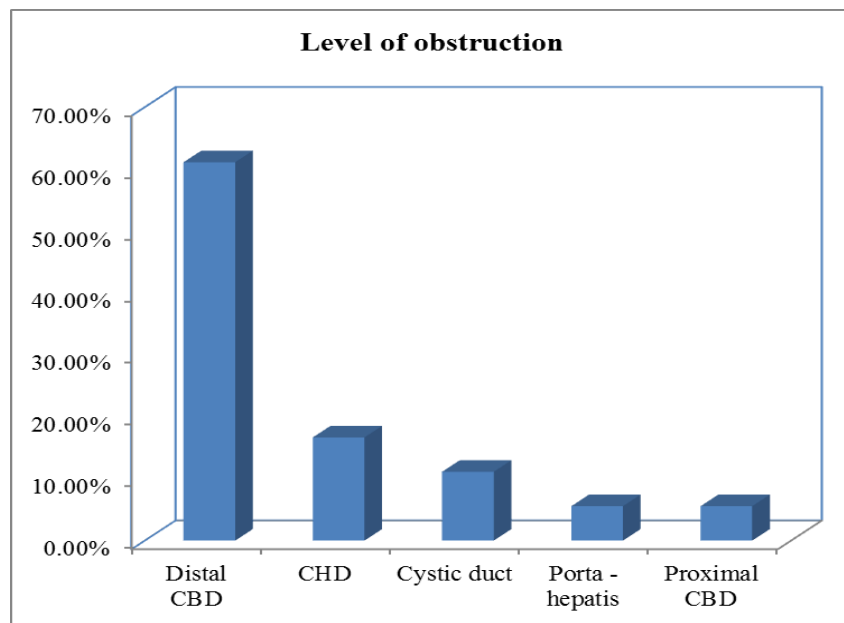


Figure (4): Level of biliary obstruction

The most common level of obstruction was at the distal end of the common bile duct.

The **intrahepatic bile ducts** dilatation was considered:

Mild: when localized to the central ones.

Moderate: when extending only to the first and second order branches.

Marked: when involving the most peripheral branches as well.

The **extra-hepatic bile duct** was measured at porta-hepatis, immediately distal to

the confluence of the right and left hepatic ducts. The normal diameter was 6mm- 8 mm, and up to 10 mm who had previously undergone cholecystectomy. Dilatation up to 10mm was graded mild, from 10-13mm as moderate and above 13mm as marked.

The pancreatic duct was measured at its widest point and was considered normal if this measurement was 2 mm or less. The pancreatic duct dilatation was graded as mild, moderate and marked.

Table (5): Degree of dilatation of IHBR, CBD and MPD (No=20).

	IHBR		CBD		MPD	
	No.	%	No.	%	No.	%
Normal	1	5.0%	7	35.0%	16	80.0%
Mild	4	20.0%	4	20.0%	2	10.0%
Moderate	5	25.0%	4	20.0%	0	0.0%
Marked	10	50.0%	5	25.0%	2	10.0%
Total	20	100.0%	20	100.0%	20	100.0%

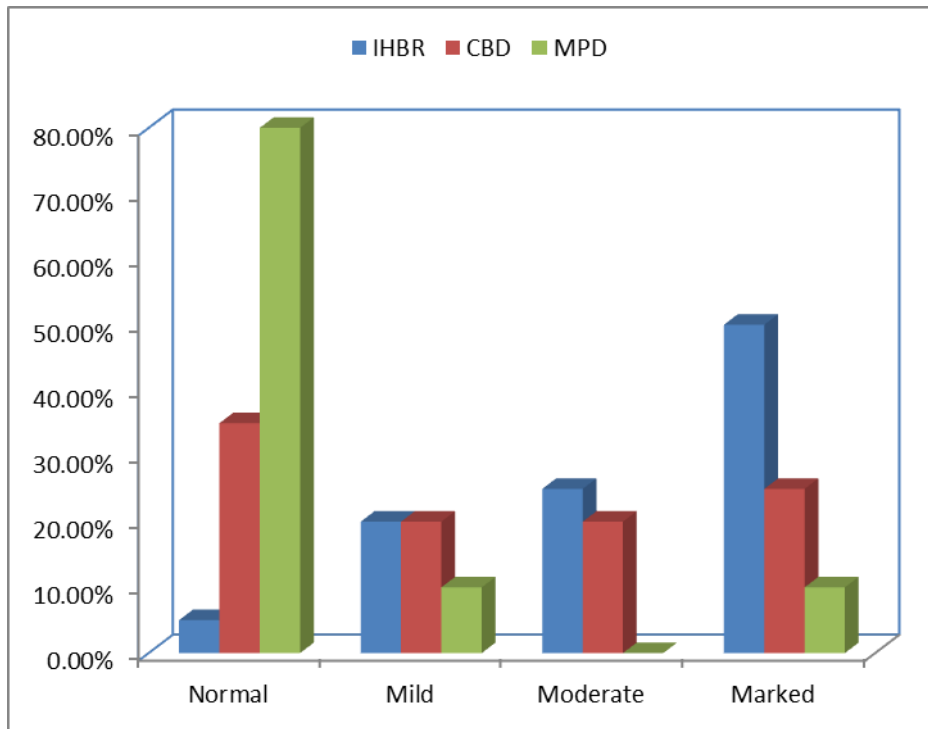


Figure (5): Degree of dilatation of IHBR, CBD, and MPD

Table (6): Distribution of cases according to the shape of obstruction in 18 cases.

Morphology	Frequency	Percent
Meniscus sign	4	22.22%
Abrupt occlusion	5	27.78%
Extrinsic compression	2	11.11%
Irregular asymmetrical stricture	1	5.56%
Multiple filling defect	3	16.67%
Smooth regular stricture	2	11.11%
Tapering lower end	1	5.56%
Total	18	100.00%

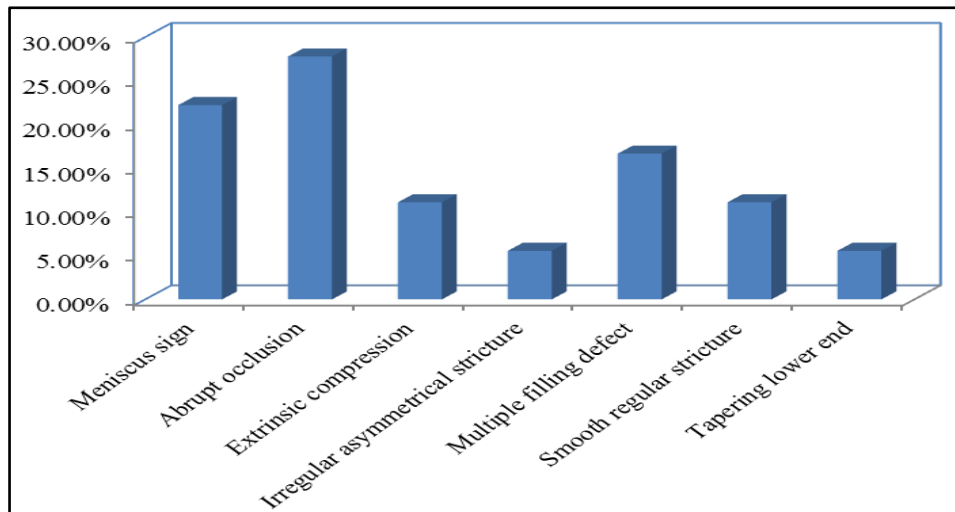


Figure (6): Bar chart morphology distribution of the study group.

The table showed that the most common shape of obstruction was abrupt occlusion malignant.

Table (7): Relation between final diagnostic according to MRCP of the study group.

MRCP	Final Diagnostic				Total		Chi-square test	
	Malignant		Benign					
	No.	%	No.	%	No.	%	x2	p
Malignant	7	100%	2	15.4%	9	45%	22.174	<0.001
Benign	0	0%	11	84.6%	11	55%		
Total	7	100%	13	100%	20	100%		

This table shows highly statistically significant relation between final diagnostic according to MRCP of the study group.

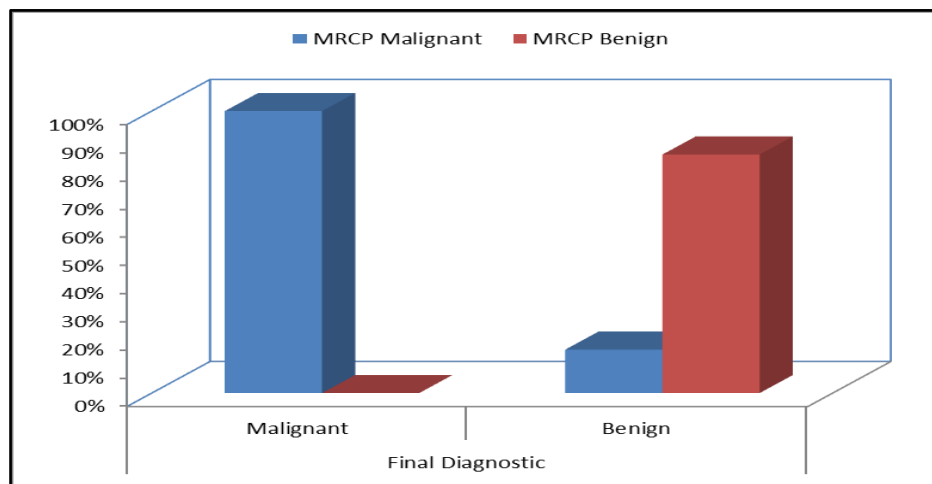


Figure (7): Bar chart between final diagnostic according to MRCP of the study group.

Table (8): The Sensitivity and Specificity of MRCP in diagnosis of 20 patients (11 benign and 9 malignant).

Statistics	MRCP
Sensitivity (%)	100%
Specificity (%)	83.3 %
Positive Predictive Value (PPV) (%)	80 %
Negative Predictive Value (NPV) (%)	100.0%
Accuracy (%)	90 %

Receiver operating characteristics (ROC) curve was sensitivity of 100% specificity of 83.3% positive predictive value of 80%, negative predictive value of 100% with diagnostic accuracy of 90%.

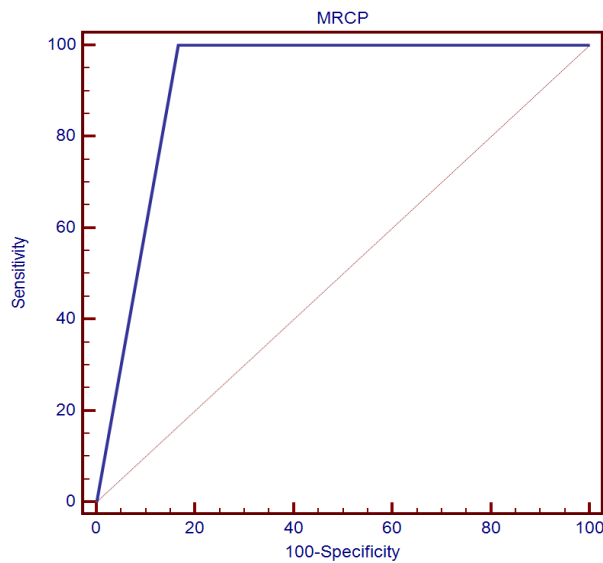


Figure (8): ROC curve, sensitivity and specificity, diagnostic Performance of MRCP in Discrimination of final diagnostic.

Discussion

Biliary disorder are one of the common problems routinely seen in the clinical practice, hence the advance in ultrasound, CT and MRI technology over the past decade have a fundamental role for evaluation the biliary system often the initial importance task is to delineate the aim of imaging is directed to define the level and the cause of obstruction ⁽⁷⁾.

Erickson and Graza, concluded the most algorithms for evaluating the patients of suspected biliary obstruction disease clinical and laboratory investigation first then confirmed by using non invasive imaging methods such as trans-abdominal ultrasound, CT, MRI, and MRCP⁽⁸⁾.

Ultrasound is virtually always the first imaging modality in evaluation of the biliary system. However it is operator dependent and is limited in virtualization of the distal end CBD and pancreatic region due to interference by the overlying bowel gas and obesity that can degrade the imaging quality⁽⁹⁾.

The gold standard investigation used in detection of obstructive jaundice is direct endoscopic retrograde cholangio-Pancreatography (ERCP), percutaneous transhepatic cholangiography (PTC), or intraoperative cholangiography. Although ERCP is associated with many complications such as pancreatitis, cholangitis, hemorrhage, duodenal

perforation and a morbidity rate of 1-7% and mortality rate of 0.2 -1% ⁽¹⁰⁾.

The advantage of MRCP over ERCP, it is as a non invasive imaging modality of the biliary tree, cheaper, no need of ionizing radiation and contrast media, is less operator dependent, allows better visualization of ducts proximal to an obstruction and when combined with conventional T1 and T2 weighted imaging sequences allows detection of extra ductal disease and has few contraindication with no recorded morbidity and mortality ⁽¹¹⁾.

As reported by **Adamek et al.** MRI with MRCP was significantly more accurate than CT in differentiation between benign and malignant lesions in patients with suspected distal biliary tumors, mainly due to information obtained on MRCP images of the biliary and pancreatic duct anatomy ⁽¹²⁾

The most common symptoms we found in patients with biliary obstruction were right upper quadrant pain and yellowish discoloration of skin and sclera. Loss of appetite and weight loss were more common symptoms found in patients with malignant pathologies similar to **Saluja et al. and Irie et al.** ^(13,14).

This study included 20 patients. They were 10 male (50%) and 10 female (50%) with age ranging from 22-72 years and mean age 50 years. The most common age group in both male and

female was 40-60 years; these results are consistent with **Verma et al.** who reported a study with age ranging from 3-80 years with mean age 50 years⁽¹⁵⁾.

The causes of biliary obstruction were found as benign in 11(55%) patients and malignant in 9(45%) patients. the benign biliary disease was the most common cause of biliary obstruction; these results are consistent with **Hasan and Almassry**, who mentioned that the benign biliary disease was most common cause seen in 18 (85.6%) patients out of the 29 biliary obstructive cases⁽¹⁶⁾. Yet this is not consistent with **Verma et al.** who mentioned that the malignant obstructive jaundice was common and it was found in 69 patients(62.73%) than 41 patients(37.27%) had benign etiology⁽¹⁵⁾.

The 11 benign lesions were categorized as 7 (63.6%) calcular obstruction, 2 (18.2%) inflammatory stricture, 2 (18.2%) choledochal cyst.

All 7 cases of choledocholithiasis were correctly diagnosed on MRCP so, the sensitivity, specificity, and diagnostic accuracy was 100%, these results are consistent with **mandelia et al.**, who reported that the Sensitivity Of MRCP in detection of choledocholithiasis 1-100%, Specificity 85-100% and accuracy 90-100%⁽¹⁷⁾.

In the current study, it was noted that choledocholithiasis was the main cause of benign obstructive jaundice. Our results are consistent with **Singh et al.**, **mandelia et al.**, and **Francesco et al.** who reported that the choledocholithiasis was the common presentable cause of obstructive jaundice^(17,18,19).

Mandela et al. has mentioned that the sensitivity, specificity and diagnostic accuracy in MRCP diagnosis of choledocholithiasis ranged from 81%- 100%, 85%-100% and 90%-100% respectively and this is matching with our study, MRCP could correctly diagnose all 7 cases of CBD stones so, the sensitivity, specificity and diagnostic accuracy was 100%⁽¹⁷⁾.

Hasan and Almasry, concluded that MRCP is now commonly used as a non invasive diagnostic tool in many patients suspected of having biliary stones, detected the length of the stone as well as the exact location of it. Both coronal images and 3D images that rotated at different angles are useful also; an axial plane tends to better outline the most distal common bile duct and pancreatic

duct segments. More over MRCP could detect the site of obstruction in the CBD of all 7 calcular obstruction in our study; were 4 in the distal portion of the CBD, 2 in the cystic duct and 1 in CHD as rounded, oval signal void filling defects surrounded by high signal intensity bile on T2 WI associated with proximal dilated hepatic biliary ducts⁽¹⁶⁾.

In the current study, there were 2 (18.2%) cases of choledochal cysts which were correctly diagnosed on MRCP. According to **Todani's classification** 2 cases of fusiform intra-hepatic choledochal cyst (TypeV)⁽²⁰⁾. This is consistent with **Suzuki , et al** who reported that MRCP has been shown to be 100% accurate in the evaluation of choledochal cyst⁽²¹⁾.

The 2 cases of inflammatory stricture, which showed bile duct wall thickening, with diffusion restriction, were correctly diagnosed by MRCP and proved by ERCP.

The 9 malignant lesions were categorized as 4 (44.4%) cholangiocarcinoma, 1 (11.1%) metastasis, 2 (22.2%) pancreatic carcinoma, and 2 (22.2%) periampullary carcinoma.

In the current study, the mean age of patients with malignant biliary obstruction was higher than benign obstruction, and this is consistent with **suthar et al.**, **Verma et al.** and **Saluja et al.**^(13,15,22).

Malignant lesions were predominant in female patients, and this is not consistent with **suthar et al.** who reported that malignant obstructive jaundice was common in male patients⁽²²⁾.

In this study the most common cause of malignant obstructive jaundice was cholangiocarcinoma, and this is consistent with **Kushwah et al.** who reported that most common cause of malignant obstructive jaundice was cholangiocarcinoma.⁽⁹⁾ Yet not consistent with **Verma et al. and Al-Obiady et al.** who reported that the most common malignant obstructive jaundice were pancreatic carcinoma and periampullary tumors^(15,23).

The site of cholangiocarcinoma was distal CBD in 2 patients, and klatskin cholangiocarcinoma in 2 cases.

Among 9 malignant lesions, MRCP was correctly diagnose 7 cases while 2 cases was falsely diagnosed as periampullary tumors and these are confirmed by results of ERCP and

histopathological diagnosis as one case of small pancreatic cyst and the second as distal benign stricture.

The small pancreatic cyst in our study, which is falsely diagnosed as periampullary mass, the MRCP showed compression and tapering of the distal end of the CBD, moderate intra and extra-hepatic biliary dilatation as well as the main pancreatic duct, with diffusion restriction.

The second case with benign stricture which is also falsely diagnosed as periampullary mass, the MRCP showed bulging mass in the terminal end of the CBD measuring about 1 cm in largest dimension, dilatation of IHBR and CHD, with diffusion restriction and in reviewing the MRCP image it is seen as bulging sphincter of oddi inside the duodenum which was explained by previous passage of stone.

The most common level of obstruction was at the distal end of CBD in 11 cases out of 20 representing 61.1%. these results are consistent with **Al-obiadi *et al.*** who reported that the distal end of CBD obstruction was found in 69 patients out of 80 representing 79%⁽²³⁾.

In the present study, MRCP was able to detect the level of obstruction in 20 cases (100%) and the cause of obstruction in 18 cases with percentage (90%), this is consistent with **Parashari *et al.*** who reported that the sensitivity of MRCP in identifying the level of obstruction was found to be 100%⁽²⁴⁾.

The morphology of the stricture was clearly evaluated at MRCP.

In our study, abrupt cut off was detected in 5 cases (27.77%), tapering lower end was detected in 1 case (5.56%), irregular filling defect was detected in 1 case (5.56%), and smooth regular stricture in 2 cases (11.11%).

In our study the, the malignant lesion was suspected with abrupt cut off of the bile duct, with shouldered margins while the benign lesions on the other hand were smooth, gradually tapered stenosis.

In our study, the irregular, and long length structure, and asymmetrical dilatation of biliary radicals were more commonly associated with malignant structures. Smooth, short length stricture and symmetrical dilatation biliary radicals were more commonly seen in benign strictures, and this is similar to (13), who

suggested that malignant strictures were irregular with an asymmetric dilatation because of the nature of involvement of the bile duct by the malignant tumour.

Yu *et al.* also reported that malignant strictures were significantly thicker and longer than the benign strictures and upstream CBD dilatation was larger in the infiltrative cholangiocarcinoma cases than in the benign cases⁽²⁵⁾.

In their study **Park *et al.*** concluded that MR Cholangio-pancreatography is comparable to ERCP in differentiating extrahepatic bile duct cholangiocarcinoma from a benign stricture and showed that a lengthy narrowed segment with irregular margins and asymmetric narrowing is suggestive of malignancy⁽²⁶⁾.

Kim *et al.* showed that a narrowed segment with the following MR imaging features is more likely to be malignant: hyperenhancement relative to the liver during the portal venous phase, length of over 12 mm, wall thickness greater than 3 mm, indistinct outer margin, luminal irregularity, and asymmetry⁽²⁷⁾.

Among 20 patients, 18 were correctly diagnosed and properly evaluated by MRCP. The sensitivity, specificity and diagnostic accuracy of MRCP for differentiation of benign from malignant causes of biliary obstruction was 85.7%, 96.3%, and 93.3% respectively. This prospective study included 20 patients, they were 10 Male (50%) and 10 Female (50%) with age ranging from 22 -72 with mean age of 50 years. The most common age group in males and females was 40-60 years.

Limitations

Surgical/histopathological correlation could not be performed in all cases as some cases of malignant pathologies were treated conservatively.

Conclusion:

We found that MRCP is a rapid and non-invasive, procedure in assessing cases with suspicions biliary obstructions. MRCP offered a diagnostic accuracy nearly equivocal to ERCP. MRCP can also replace the diagnostic part of ERCP procedure, so that time is spent only on its therapeutic part, and hence decreasing complications of a lengthy ERCP.

A benign stricture can be differentiated from a malignant one if it shows regular, symmetric and short segment narrowing. Irregular, asymmetric

and long segment narrowing was more commonly found in malignant stricture.

Recommendations

From this study, it is recommended that its benign or malignant nature of biliary obstruction can be assured by MRCP by observation of stricture margin, dilatation, and length and accordingly proceed to next step in management. MRCP is an efficient diagnostic procedure for detection of presence, level, cause of obstruction and routinely advocated before any intervention is planned.

References

- [1] **Rana SS, Bhasin DK, Sharma V, Rao C, Gupta R, and Singh K (2013):** Role of endoscopic ultrasound in evaluation of unexplained common bile duct dilatation on magnetic resonance cholangiopancreatography. *Ann Gastroenterol.* , 26(1):66–70.
- [2] **Katabathina VS, Dasyam AK, Dasyam N, and Hosseinzadeh K(2014):** Adult Bile Duct Strictures: Role of MR Imaging and MR Cholangiopancreatography in Characterization. *Radio Graphics*, 34:565–86.
- [3] **Patel HT, Shah AJ, Khandelwal SR, Patel HF, and Patel MD (2009):** MR cholangiopancreatography at 3.0 T. *Radiographics: a review publication of the Radiological Society of North America, Inc.* ,29(6):1689–706.
- [4] **Nanashima A, Abo T, and Sakamoto I (2009):** Three-dimensional cholangiography applying C-arm computed tomography in bile duct carcinoma: a new radiological technique. *Hepatogastroenterology*, 56(91-92):615-8.
- [5] **Romagnuolo J, Bardou M, Rahme E, Joseph L, Reinhold C, and Barkun AN(2003):** Magnetic resonance cholangiopancreatography: A meta-analysis of test performance in suspected biliary disease. *Ann Intern Med.* ,139:547–57.
- [6] **Kim JH, Kim MJ, Park SI, Chung JJ, Song SY, and Kim KS(2002):** MR cholangiography in symptomatic gallstones: Diagnostic accuracy according to clinical risk group. *Radiology*, 224:410–6.
- [7] **Bhargava SK, Usha T, BhattS, KumariR, Bhargava S (2013):** imaging in obstructive jaundice: A review with our experience. *JEMSA.*, 26 (1):34-46.
- [8] **Erickson R.A and Garza AA (2001):** EUS with EUS –guided fine needle aspiration as first endoscopic test for the evaluation of obstructive jaundice, *American Society for gastrointestinal Endoscopy*, 53:36-41.
- [9] **Kushwah A, Jain S, Agarwal R and Tomar S (2015):** Biliary tract obstructive diseases: A comparative evaluation by ultrasonography and magnetic resonance cholangiopancreatography. *International Journal of Scientific Study*, 3(4): 149-153.
- [10] **Hyodo T, Kumano S, Kushihata F, Okada F, Hirata M, Takada Y et al. (2012):** CT and MR cholangiography: advantages and pitfalls in perioperative evaluation of biliary tree. *The British Institute of Radiology*, 85: 887-896.
- [11] **Griffin n, edwards GC& Grant LA(2012):** Magnetic resonance cholangiopancreatography: the ABC of MRCP. *insights imaging.* *European society of radiology*, 3: 11-21.
- [12] **Adamek HE, Albert J, Breer H, Weitz M, Schilling D et al. (2000):** Pancreatic cancer detection with magnetic resonance cholangiopancreatography and endoscopic retrograde cholangiopancreatography: a prospective controlled study. *Lancet*, 356: 190-193.
- [13] **Saluja SS, Sharma R, Pal S, Sahni P, Chattopadhyay TK (2007):** Differentiation between benign and malignant hilar obstructions using laboratory and radiological investigations: A prospective study. *HPB.*, 9: 373–82.
- [14] **Irie H, Honda H, Tajima T et al. (2008):** Optimal MR cholangiopancreatographic sequence and its clinical applications. *Radiology*, 26: 397-387.
- [15] **Verma SK, Maheshwari S, Sharma NK, Prabhat KC(2010):** Role of oral health professional in pediatric obstructive sleep apnea. *Natl J Maxillofac Surg.*, 1: 35-40.
- [16] **Hasan DJ and AlMassry HN(2010):** Magnetic resonance cholangiopancreatography in conjunction with 3D for assessment of different biliary

obstruction causes, *Egy. J Radio. Nucl. Med.*, 41: 483-489.

[17] **Mandelia K, Gupta A.K, verma A.K, sharma S (2013):** The value of magnetic resonance cholangio-pancreatography (MRCP) in the detection of choledocholithiasis. *Journal of clinical and diagnostic research*, 7 (9): 1941-1945.

[18] **Singh A, Mann SH, Thukral CL, and Singh NR (2014):** Diagnostic accuracy of MRCP as compared to Ultrasound / CT in patients with obstructive jaundice. *Clin Diagn Res.*, 8 (3): 103-107.

[19] **Francesco SF, Federea F, Lural K *et al.* (2005):** US, MRCP, CT, ERCP. A comparative study on 131 patients with suspected biliary obstruction. *Diagnostic Med. Tech. – Sci Minit.*, 11(3): 8-18.

[20] **Todani T, Watanabe Y, Narusue M, Tabuchi K, Okajima K (1977):** Congenital bile duct cysts: Classification, operative procedures, and review of thirty-seven cases including cancer arising from choledochal cyst. *Am J Surg.*, 134: 263–69.

[22] **Suthar M, Purohit S, Bhargav V, Goyal P (2015):** Role of MRCP in Differentiation of Benign and Malignant Causes of Biliary Obstruction. *J Clin Diagn Res.*, 9: TC08-12.

[24] **Parashari UC, Khanduri S, Bhadury S, Updhyay D, Kishore K (2015):** Diagnostic role of magnetic resonance cholangiopancreatography in evaluation of obstructive biliopathies and correlating it with final diagnosis and clinical profile of patients. *J Nat Sci Biol Med.*, 6(1): 131-138.

[25] **Yu XR, Huang WY, Zhang BY, Li HQ, Geng DY (2014):** Differentiation of infiltrative cholangiocarcinoma from benign common bile duct stricture using three-dimensional dynamic contrast-enhanced MRI with MRCP. *Clinical Radiolog*, 69: 567–73.

[26] **Park MS, Kim TK, Kim KW, Won K, Park SW, Lee JK *et al.* (2004):** Differentiation of extrahepatic bile duct cholangiocarcinoma from benign stricture: finding at MRCP versus ERCP. *Radiology*, 233: 234–40.

[27] **Kim JY, Lee JM, Han JK, Kim SH, Lee JY, Choi JY *et al.* (2007):** Contrast-enhanced MRI combined with MR Cholangiopancreatography for the evaluation of patients with biliary strictures: differentiation of malignant from benign bile duct strictures. *J Magn Reson Imaging*, 26(2): 304–12.