

The Histological and Immunohistochemical Study of Tramadol Induced Testicular Toxicity and Protective Effects of Resveratrol in Adult Male Albino Rats

Original
Article

Eman El Bana, Nagla A. S. Sarg, Eman E. Elwakeel

Departments of Anatomy and Embryology, Faculty of Medicine, Benha University, Egypt.

ABSTRACT

Background and Objectives: Tramadol is a centrally acting analgesic drug. Chronic intake of Tramadol has negative impacts on testis. Resveratrol is considered to be a natural compound that has antioxidant and anti-inflammatory effects.

Aim : The present study was designed to monitor the impacts of the use of Tramadol on the testis of adult male albino rats and the beneficial effects of Resveratrol.

Materials and Methods: 40 adult male albino rats were classified randomly into 4 groups. Each one included 10 rats as follows: Group I (control group): received 0.1 ml of physiological saline solution. Group II: received Resveratrol 20 mg/kg/day orally for 4 weeks. Group III: (Tramadol-treated group): received Tramadol 50 mg/kg/day orally for 4 weeks. Group IV: received Tramadol 50 mg/kg body weight daily orally followed by Resveratrol 20 mg/kg body weight daily by intragastric gavage for 4 week. Blood samples were obtained to assess serum levels of testosterone, FSH and LH. Testes were removed and prepared for histological examination and immunohistochemical staining. The experimental data were analyzed using IBM SPSS Statistics software.

Results: Tramadol-treated group showed severe distortion of the testicular structure in which many seminiferous tubules were degenerated with losing their normal histological architecture. Meanwhile, sections of testes of group IV (Tramadol–Resveratrol treated group) showed nearly normal histology. Positive immune-reactivity for PCNA in the control, Resveratrol treated and Tramadol - Resveratrol treated groups while, Tramadol- treated group showed few positive immuno-reactivity for PCNA. Serum LH, FSH and testosterone hormones levels were significantly higher in Tramadol-Resveratrol treated group compared to Tramadol treated group.

Conclusion: Intake of Tramadol induced testicular damage which can be ameliorated by administration of Resveratrol in the concomitant with Tramadol treatment.

Key Words: Antioxidants, testis, tramadol, resveratrol.

Revised: 14 September 2019, **Accepted:** 24 September 2019.

Corresponding Author: Eman El Bana, MD, Department of Anatomy and Embryology, Faculty of Medicine, Benha University, Benha, Egypt., **Tel.:** 01028003776, **E-mail:** emankasb@yahoo.com

ISSN:2536-9172, December 2019, Vol. 3, No. 2

INTRODUCTION

Nonsteroidal Analgesics are the most commonly consumed drugs all over the world. Tramadol hydrochloride (a synthetic analogue of codeine) is centrally acting analgesic drug which is mainly used to suppress moderate to severe pain^[1]. Also, it is used for premature ejaculation^[2], as an antidepressant^[3], post-herpetic neuralgia and treatment of diabetic neuropathy^[4,5].

long-term administration of Tramadol has many complications as psychological addiction, physical addiction, respiratory depression^[6], negative effects on testis, liver, thyroid gland and kidney^[7,8].

Resveratrol (trans- 3, 5, 4'-trihydroxy -trans- stilbene, RES) is a natural compound with polyphenolic structure. It is found in grapes, red wine and has been indicated to obtain a wide range of biological effects, such as lifespan extension^[9,10], cardio-protective, anti-inflammatory^[11,12],

anticancer^[13,14], and protective against environmental toxins^[15,16].

De la Lastra and Villegas. (2007) proved that, Resveratrol induces antioxidant effects through the release of antioxidant enzyme and minimizing lipid peroxidation^[12].

The present study was designed to monitor the impacts of the use of Tramadol on the testis of adult male albino rats and the beneficial effects of Resveratrol.

MATERIALS AND METHODS

Animals:

40 adult male albino rats (*Rattus norvegicus*) ,aged 8 weeks (weighting 120g-150g) were obtained from the

Animal House of the Faculty of Veterinary Medicine, Benha University, Egypt. Animals were kept at $25 \pm 2^\circ\text{C}$ humidity of 50-60% and on 12h light/ 12h dark cycle. They were fed with standard diet with grant reach to water and libitum. Care of animals was planned according to the guidelines of the Animal Ethical Committee of the Faculty of Medicine, Benha University.

Drugs and chemicals:

All Tramadol: Tramadol (Hikma Pharmaceutical Co. Giza, Egypt; Catalog Number: T712515) was in the form of Tramadol hydrochloride tablets (200mg/tablet). Each tablet is suspended in 20 ml distilled water. It was given as 50mg/kg body weight daily by intragastric gavage for 4 weeks^[7].

Resveratrol (RES): Resveratrol (Sigma-Aldrich Saint Louis, Missouri, USA; Catalog Number: R001) was in the form of white powder. Resveratrol was suspended in carboxy methyl cellulose, as it is less soluble in water. Resveratrol was orally administered by gavage 20 mg/kg body weight daily for 4 weeks^[15]. The doses were freshly prepared immediately before administration.

Experimental protocol

40 adult male albino rats were classified into 4 groups:

- Group I (control group): This group included 10 animals that received 0.1 ml of physiological saline solution by intragastric gavage for 4 weeks.

-Group II (Resveratrol treated group): it included 10 animals that received Resveratrol at a dose of 20 mg/kg body weight by intragastric gavage daily for 4 weeks^[16].

-Group III: (Tramadol treated group): it included 10 animals that received Tramadol at a dose of 50 mg/kg body weight daily orally by intragastric gavage for 4 weeks^[7].

-Group IV (Tramadol – Resveratrol treated group): it included 10 animals that were given Tramadol orally 50 mg/kg body weight daily followed by Resveratrol orally by intragastric gavage 20 mg/kg body weight daily for 4 weeks(Total period of 4 weeks)^[15].

Evaluation Methods:

Histological Study:

After 4 weeks for all groups, the animals were anesthetized by using chloroform inhalation and dissected. Blood samples were taken from the heart. Serum samples obtained by centrifugation of blood samples at 3000 rpm for 3 min were stored at -20°C until analysis. Both testes were removed and fixed in modified Bouin's solution (0.2% picric acid 2% (v/v) formaldehyde in PBS) and then

transferred to 70% alcohol for histological process. The tissues were processed by dehydration in 90% alcohol, absolute alcohol and finally dipped in xylol. The testes were embedded in paraffin wax and blocks were prepared and labeled. 5 μm thickness sections were cut using rotatory microtome. The sections were stained by using Haematoxylin and Eosin^[17]. Histological examination was performed by using an Olympus BX60 light microscope at Faculty of medicine, Benha University, Egypt.

Immunohistochemical Study:

Proliferating cell nuclear antigen (PCNA) is an intranuclear polypeptide. Synthesis of PCNA and its expression is in link to cell proliferation. It is involved in DNA excision, repair and replication^[18]. In this study, PCNA was used to analyze spermatogenesis. Immunohistochemical staining was performed using primary antiserum to PCNA. It is a ready-to-use mouse monoclonal antibody (Lab. Vision Corporation Laboratories, CA, USA, catalogue number: MS106P). The primary antibody was diluted in Tris buffered saline with a dilution of 1:50, as determined by the data sheet. The sections were incubated with the primary antibody overnight at $+4^\circ\text{C}$. The binding of the primary antibody was observed using a commercial avidinbiotin peroxidase detection system recommended by the manufacturer (DAKO, Carpinteria, USA). A mouse monoclonal antibody was applied in place of the primary antibody to act as a negative control. Diaminobenzene (DAB) as the chromogen was used for staining of sections and counterstained with hematoxylin^[17, 19]. The tissues were examined for PCNA immunostaining using light microscope (x 400). Microscopic fields were chosen at random. A percentage of immuno-labeled cells to all basal cells was estimated by PCNA-LI for each seminiferous tubule.

Morphometric study:

The image analyzer computer system “Leica Qwin 500 C” (Cambridge, England) was used for data analysis. All measurements were done using $\times 400$ magnification and within 10 non-overlapping fields for each specimen. The mean area % of PCNA immuno-expression was quantified.

Biochemical indices:

Testosterone (ng/ml), follicle stimulating hormone (FSH) and Luteinizing hormone (LH) (mIU/ml) were estimated using enzyme linked immunosorbent assay (ELISA) kits according to manufacture structure in the Clinical Pathology Department, Faculty of Medicine, Benha University.

Statistical analysis:

The experimental data were analyzed using IBM SPSS Statistics software, Version 19 (IBM Corp., Armonk,

NY, USA). Differences between groups were compared by One-way analysis of variance (ANOVA). In each test, the data was expressed as the mean (M) value, standard deviation (SD) and differences were considered to be highly significant at $P \leq 0.01$, significant at $P \leq 0.05$ and non-significant at $P > 0.05$.

RESULTS

Light microscopic results:

In control group, histological findings of H&E sections of the testes showed, closely packed seminiferous tubules with most probably normal architecture as the testes appeared surrounded by a regular capsule. The seminiferous tubules were noticed to be lined by spermatogenic cells and Sertoli cells. Spermatogenic epithelium formed of; spermatogonia, primary spermatocytes, spermatids, and sperms. Studied sections showed, Sertoli cells resting on the basement membrane between the spermatogenic cells with oval nuclei. Primary spermatocytes were seen with large rounded nuclei, partially condensed chromosomes and were described as largest spherical cells. Spermatids were noticed as round cells having pale rounded nuclei. The tubules separated from each other by loose interstitial connective tissue containing the Leydig cells which appeared with vesicular nuclei and cytoplasmic lipid droplets (Figure 1).

Examination of H&E stained sections in RES-treated group (Group II) showed nearly the normal histological profile with no detectable variation in comparison with group I (Figure 2).

In group III (Tramadol treated group), there was severe distortion of the testicular structure as many seminiferous tubules were degenerated with losing their normal histological architecture, completely devoid of spermatogenic epithelium and few contained remnants of the epithelial cells while other tubules contained only congested blood vessels with dark necrotic hyalinized material in the interstitium. Vacuoles appeared between the degenerated spermatogenic cells, replacing them. Sertoli cell was resting on irregular basement membrane and there was detached spermatogenic cells (Figure 3). Spermatogenic epithelium appeared with dark exfoliated pyknotic nuclei with absence of sperms (Figure 4).

Meanwhile, sections of testes of group IV (Tramadol-Resveratrol treated group) showed nearly the normal histological structure. Few empty spaces were still seen among spermatogenic epithelium. Interstitial spaces showed blood vessels and polygonal Leydig cells with pale nuclei and acidophilic vacuolated cytoplasm. However, few cells with darkly stained nuclei were observed (Figure 5).

Immunohistochemical results:

Examination of testicular sections of the control group, RES-treated group and Tramadol with RES-treated group revealed, PCNA positive immunoreaction that appeared as brown nuclear deposits in spermatogonia and primary spermatocytes (Figures 6, 7&10). On the other hand, testicular sections of group III (Tramadol treated group) showed few positive immunoreactive spermatogonia and primary spermatocytes (Figures 8 & 9).

Morphometric results

The mean areas % of PCNA immuno-reactivity for all groups were compared. There was insignificant decrease in PCNA immuno-expression ($P > 0.05$) in groups II & IV as compared with control group. The mean area % of PCNA immuno-reactivity was highly significantly increased in control group as compared to group III ($P < 0.01$). The mean area % of PCNA immuno-reactivity was significantly increased in groups II & IV as compared to group III ($P \leq 0.05$). Also, area % of PCNA immuno-reactivity was insignificantly

decreased in group IV as compared to group II ($P > 0.05$) (Table 1 and Figure 11).

Biochemical indices results

Serum LH and FSH levels were found to be significantly decreased in Tramadol treated animals compared to the control animals ($p < 0.05$) with significantly higher levels in Tramadol-RES treated group compared to Tramadol treated group ($p < 0.05$).

On the other hand, serum testosterone was significantly lower in Tramadol treated animals compared to the control group ($p < 0.001$) but significantly higher in Tramadol-RES treated group compared to Tramadol treated animals ($p < 0.001$), suggesting that RES treatment relieved testicular toxicity and increased testosterone secretion (Table 2 and Figure 12).

Table (1): The mean values of area % PCNA immuno-reactivity \pm SD in all groups

Mean% \pm SD	Group I	Group II	Group III	Group IV	F test	P value
PCNA	19.17 \pm 2.27	17.76 \pm 2.85	0.81 \pm 0.16	13.26 \pm 3.47	4.272	0.045
Significance ≤ 0.05	With group III	With group III	With groups I, II & IV	With group III		

Table (2) :The mean values of FSH,LH & Testosterone± SD in all groups

Mean% ± SD	Group I	Group II	Group III	Group IV	F test	P value
FSH (mIU/ml)	2.76± 0.019	2.5± 0.3	0.92± 0.075	2.2± 0.36	16.128	0.001
LH (mIU/ml)	2.43± 0.18	2.33± 0.157	1.03± 0.316	2.1± 0.2	25.28	0.000
Testosterone (ng/ml)	4.12± 0.11	3.9± 0.36	1.6± 0.65	3.4± 0.35	22.31	0.000
Significance ≤ 0.05	With group III	With group III	With groups I, II& IV	With group III		

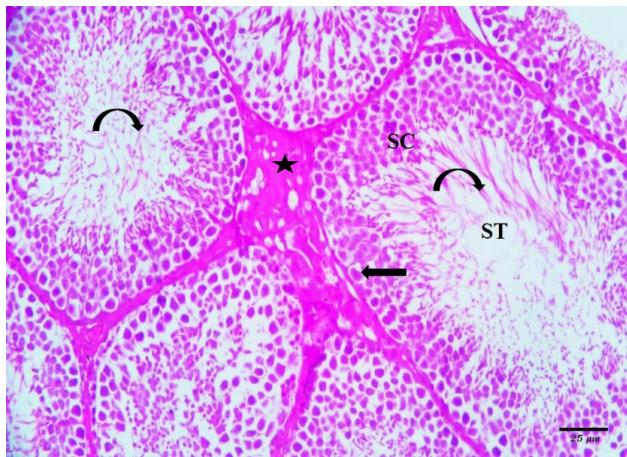


Fig. 1: Photomicrograph of control testicular section showing seminiferous tubules (ST) lined by spermatogenic epithelium (SC) and Sertoli cell (arrow), with sperms (curved arrow) in their lumens with Leydig cells (asteric) between the seminiferous tubules [H&E, x400].

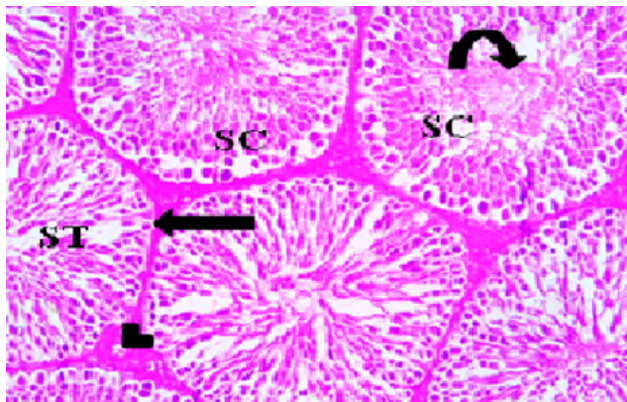


Fig. 2: Photomicrograph of Resveratrol group testicular section showing most probably normal architecture seminiferous tubules (ST) lined by spermatogenic epithelium (SC) and Sertoli cell (arrow), with sperms (curved arrow) in their lumens. Normal blood vessel (arrow head) embedded through interstitial tissue between the seminiferous tubules [H&E, x 400].

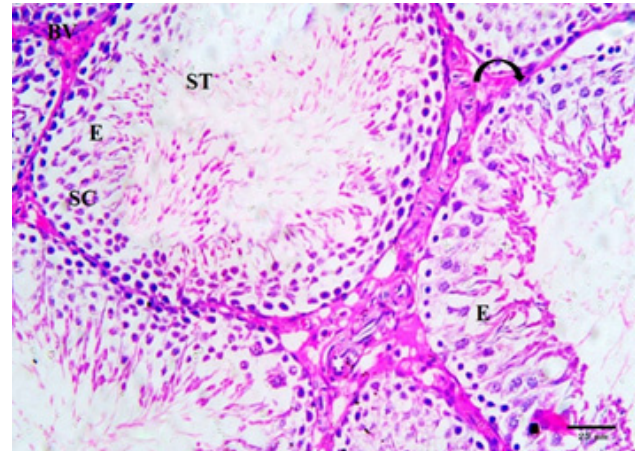


Fig. 3: Photomicrograph of Tramadol- treated group of testicular section illustrating distorted seminiferous tubules (ST), Sertoli cell (curved arrow) resting on irregular basement membrane, detached spermatogenic cells (SC), Spermatogenic cells appear with many exfoliate pyknotic or irregular darkly stained nuclei, empty spaces (E) and the interstitial tissue contains congested blood vessels (BV) [H&E, x400].

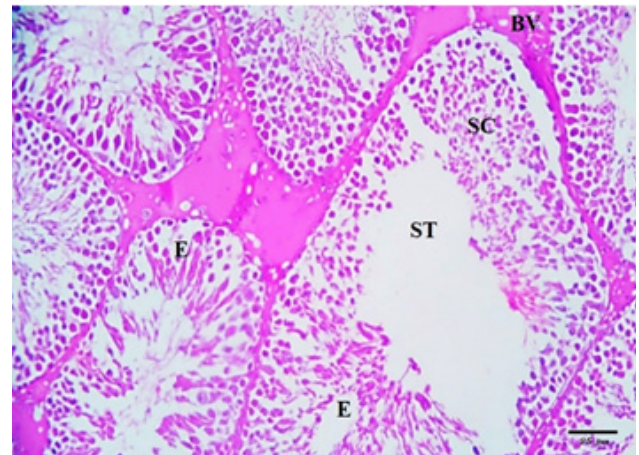


Fig. 4: Photomicrograph of Tramadol- treated group of testicular section illustrating deformed seminiferous tubules (ST) with detached spermatogenic cells (SC), Spermatogenic cells appear with pyknotic or irregular darkly stained nuclei. Note appearance of empty spaces (E) and the interstitial tissue contains congested blood vessels (BV) [H&E, x400].

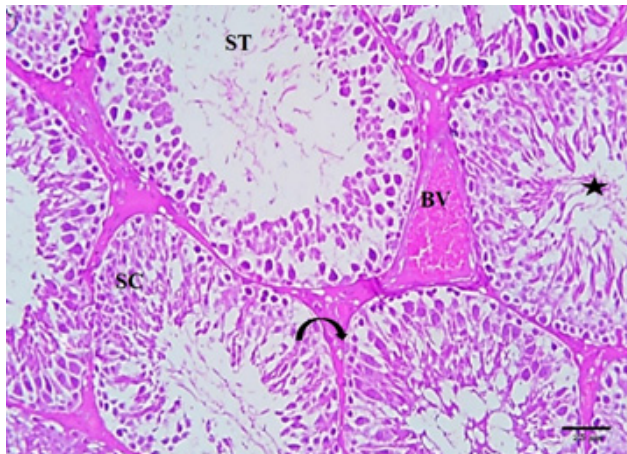


Fig. 5: Photomicrograph of Tramadol and Resveratrol- treated group (group IV) of testicular section showing more or less normal seminiferous tubules (ST) lined by spermatogenic epithelium (SC) and Sertoli cell (curved arrow), the lumen filled with sperms (asteric). Note congested blood vessel in the interstitial tissue (BV) [H&E, x400].

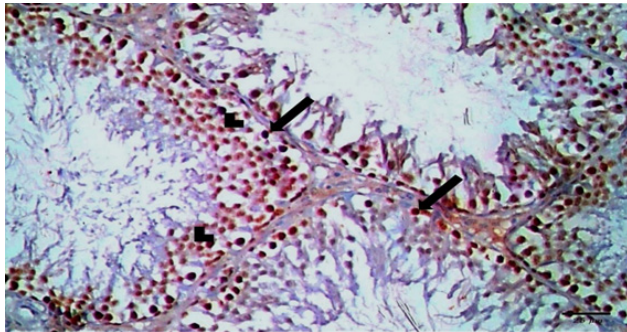


Fig. 6: Photomicrograph of PCNA immunostained testicular section of control group showing positive nuclear immunoreaction in spermatogonia (arrow) and primary spermatocytes (arrowhead) [x400].

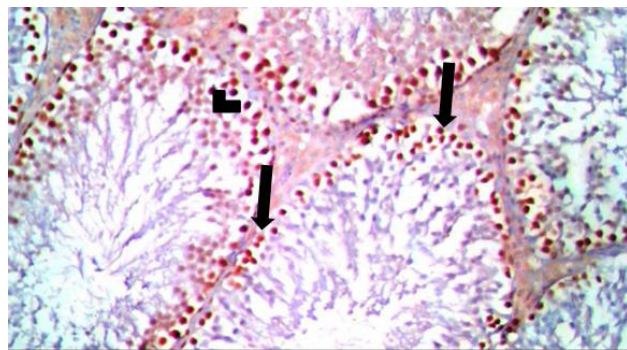


Fig. 7: Photomicrograph of PCNA immunostained testicular section of Resveratrol group showing positive nuclear immunoreaction in spermatogonia (arrow) and primary spermatocytes (arrowhead) [x400].

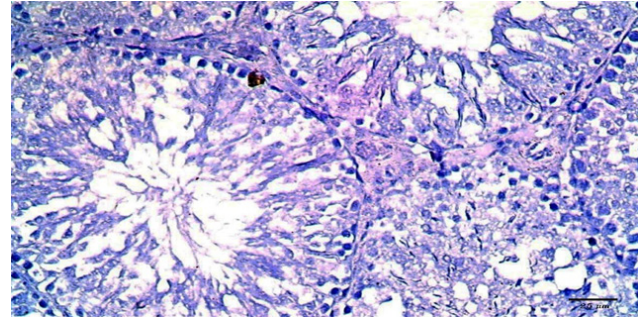


Fig. 8: Photomicrograph of PCNA immunostained testicular section of Tramadol treated group showing negative nuclear immunoreaction in spermatogonia and primary spermatocytes [x400].

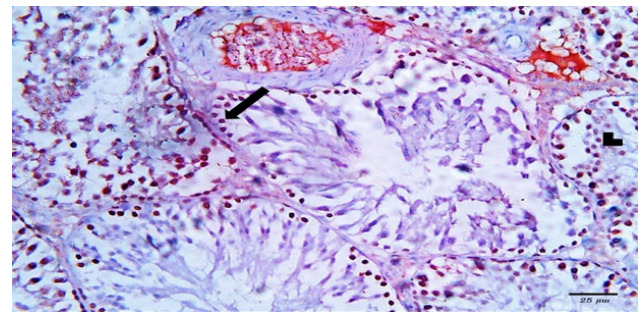


Fig. 9: Photomicrograph of PCNA immunostained testicular section of Tramadol treated group showing few positive spermatogonia (arrow) and primary spermatocytes (arrowhead) [x400].

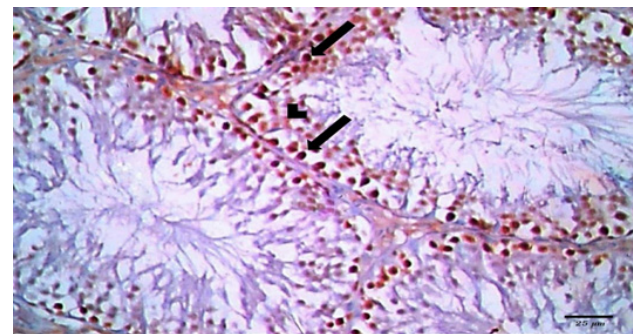
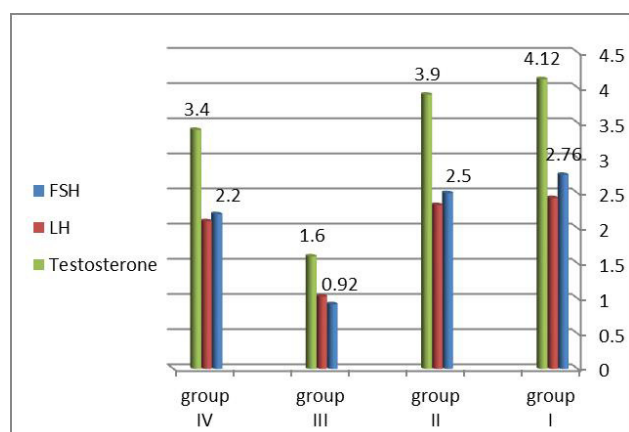
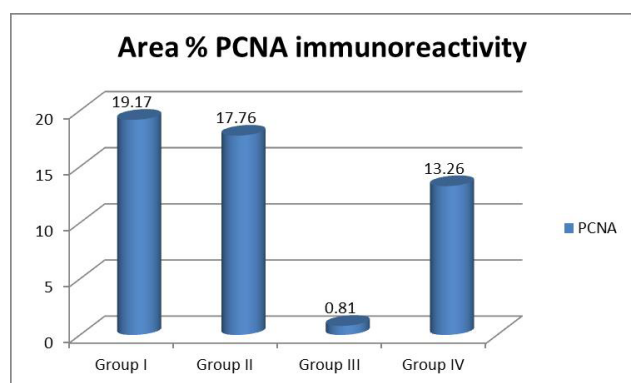


Fig. 10: Photomicrograph of PCNA immunostained testicular section of Resveratrol and Tramadol-treated group (group IV) showing positive nuclear immunoreaction in spermatogonia (arrow) and primary spermatocytes (arrow head) [x400].



DISCUSSION

Tramadol is a centrally acting opioid that considered to be the first choice to relief pain. Opioids were used as analgesic drugs without considering many complications. One of these complications that rarely considered was hypogonadism^[20].

In this study, the testis of the rats treated with Tramadol showed irregularity of the seminiferous tubules with disorganization and degeneration of spermatogenic cells. The damaged spermatogenic cells were exfoliated in the lumen, which showed absence of sperms. Vacuoles appeared between the degenerated spermatogenic cells, replacing them. There was irregular degenerated basement membrane of seminiferous tubules. Some seminiferous tubules were ruptured. Also; the degree of spermatogenesis was evaluated using PCNA with significant decline in the rats treated with Tramadol.

These findings were in agreement with El Sawy & Abdel Malak, (2015) who reported that, Tramadol induced variable degree of degeneration in the seminiferous tubules with vacuolization of spermatogenic layers. Darkly stained nuclei were sloughed into the tubular lumen. The mean values of seminiferous tubules diameter and the mean germinal epithelial height were significantly decreased^[21].

It was mentioned in previous study done by Salah, *et al.*, (2019) that, the abnormalities in the testicular

structures including atrophy of seminiferous tubules with focal testicular degeneration and single or multiple layers of vacuolated spermatocytes that may be referred to the oxidative damaging effect of free radicals. Tramadol produces lipid peroxidation that leading to structural and functional damage of cells^[22].

Ahmed & Kurkar, (2014) reported that, Tramadol increased the testicular levels of nitric oxide, lipid peroxidation and decreased the anti-oxidant enzymes activities significantly compared with the control group as well as immunohistochemical examinations showed that Tramadol increased the expression of endothelial nitric oxide synthases in testicular tissues^[8].

In the present study, the testis of the rats treated with Tramadol and Resveratrol showed nearly the normal histological profile. Few empty spaces were still seen among spermatogenic epithelium. Interstitial spaces showed blood vessels and polygonal Leydig cells with oval nuclei and acidophilic vacuolated cytoplasm. However, few cells with darkly stained nuclei were observed.

Fikriye, *et al.*, (2017) reported that, Resveratrol at a dose of 20 mg/kg daily resulting in improvement of testicular damage. The immunohistochemical results within this study were similar to the findings in our study^[23].

Similarly, Youssef & Zidan, (2016) stated that, Resveratrol prevents the lipid peroxidation and DNA damage induced by oxidative stress^[24]. Also it was reported that, Resveratrol improves sperm maturation and lowers the oxidative stress in seminiferous tubules^[25].

Apoptosis plays a great role in toxicity. In this study, immunohistochemical staining by PCNA was used to demonstrate apoptosis. However, RES treatment at daily doses of 20 mg/kg decreased the apoptotic cell count induced by Tramadol. Kasdallah-Grissa, (2006) and Samy, *et al.*, (2014) proved that the protective effects of RES could also be mediated by its promising effect on apoptosis. The use of Resveratrol resulting in improvement of the mRNA expression of Bcl-2 levels and also decreasing expression of Bax genes and p53 in healthy and CdCl₂-intoxicated rats, so RES may have a protecting effect on testicular tissue^[25,26].

Resveratrol has antioxidant potential. So, RES has the ability to reach peroxidized rigid membranes and increase membrane fluidity that helps to interact in a more effective way with radicals. Therefore, RES has a beneficial effect against DNA damage which happened because of Reactive Oxygen Species (ROS) and lipid peroxidation^[26,27].

Within another study, it was reported that the impacts of small concentrations of RES were associated with activation of genes that are responsible for oxidative phosphorylation and mitochondrial biogenesis. From

which, it was concluded in other study that, RES apart from being an antioxidant, could mobilize the spermatozoa energetic metabolism and therefore improve the motility and viability of spermatozoa^[28].

Avdatek *et al.*, (2018) reported that, Resveratrol protects cells against oxidative cytotoxic effects and organizes the action of mitochondrial superoxide dismutase 2 levels that resulting in suppression of mitochondrial oxidative stresses^[29].

It was recorded in the present study that, the average levels of sex hormones (serum LH, FSH and testosterone) were significantly decreased in Tramadol treated group in comparison with control group. On the other hand, RES treated group showed that, the levels of these hormones were significantly improved if compared with Tramadol treated group suggesting that RES treatment relieved testicular toxicity and increased testosterone secretion.

These results are in agree with Osadolor & Omo-Erhabor., (2016) who found that the direct effect of Tramadol on the hypothalamic–pituitary axis leading to reduction in the levels of LH, FSH and testosterone with induction of the levels of estradiol and prolactin^[30]. Also resulted in reduction of testosterone secretion, which could be involved in the involution of the seminiferous epithelium^[31].

Normal spermatogenesis is induced by FSH and LH. When the level of peripheral LH is reduced, testosterone secretion will be decreased, resulting in involution of the epithelium of seminiferous tubules. Another explanation for Tramadol to suppress testosterone secretion is to produce nitric oxide (NO)^[32]. From the previous mentioned studies, It can be summarized that, the hormonal deficiency is responsible for degenerative changes that happened to the germ cells. In addition, the testicular function was affected by Tramadol treatment, through increasing production of nitric oxide and oxidative stress.

Within another study, El-Gaafarawi., (2006) explained that, RES stimulated the gonadotropin secretion which is a major endocrine regulator in spermatogenesis. In that study, in RES treated group, serum FSH and LH levels which stimulates spermatogenesis in tubules and testosterone production in Leydig cells were significantly increased when compared with the control group^[33].

Sharma *et al.*, (2014) reported that, RES in testicular toxicity induced by doxorubicin and cypermethrin, there were significant increase in the levels of LH, FSH and testosterone^[34]. These findings denotes that, Resveratrol improves testicular function after exposure to testicular toxicity.

CONCLUSION

This study concluded that Resveratrol ameliorated Tramadol induced testicular damage by reducing oxidative stress and by enhancing level of sex hormones.

ABBREVIATIONS

RES: Resveratrol
 FSH: Follicle stimulating hormone
 LH: Luteinizing hormone
 PCNA: Proliferating Cell Nuclear Antigen
 ROS: Reactive Oxygen Species
 NO: Nitric oxide

CONFLICT OF INTEREST

There are no conflicts of interest.

REFERENCES

1. Osadolor1, H. B. and Omo-Erhabor, J. A. (2016): Effects of Tramadol on Fertility Hormones (Follicle Stimulating Hormone, Luteinizing Hormone, Prolactin, Testosterone, Estrogen and β -HCG) in Laboratory Rabbits. *British Journal of Medicine & Medical Research*. 14(8): 1-11. ISSN: 2231-0614.
2. Khan AH and Rasaily D (2013): Tramadol use in premature ejaculation: daily versus sporadic treatment. *Indian J Psychol Med*; 35:256–259.
3. Barber J. (2011): Examining the use of tramadol hydrochloride as an antidepressant. *Exp Clin Psychopharmacol*; 19:123–130.
4. Lindsay TJ, Rodgers BC, Sava THV and Hettinger K. (2010): Treating diabetic peripheral neuropathic pain. *Am Fam Physician*; 82:151–158.
5. Bell AL. (2011): Herpes zoster and postherpetic neuralgia: prevention and management. *Am Fam Physician*; 83:1432–1437.
6. Hafez EM, Issa SY and AbdelRahman SM. (2015): Parenchymatous toxicity of Tramadol: histopathological and biochemical study. *J Alcohol Drug Depend*; 3:225.
7. Elsayy MM, Abdel Malak HW. (2015): Effect of Tramadol abuse on testicular tissue of adult albino rats: a light and electron microscopic study. *Egypt J Histol*; 38:356–366
8. Ahmed, M.A., Kurkar, A. (2014): Effects of opioid (Tramadol) treatment on and detection

- efficiency of the peroxidase antiperoxidase (PAP), avidin-biotin (LAB) methods. *Am.J.Clin.Pathol.* Jul;92(1):62-67.
9. Baur JA, Sinclair DA. (2006): Therapeutic potential of Resveratrol: the in vivo evidence. *Nat Rev Drug Discov.*; 5:493–506. 11.
 10. Baur JA, Pearson KJ, Price NL, Jamieson HA, Lerin C, Kalra A, Prabhu VV, Allard JS, Lopez-Lluch G, Lewis K, PistellPJ, Poosala S, Becker KG, (2006): Resveratrol improves health and survival of mice on a high-calorie diet. *Nature.*; 444:337– 42.
 11. Delmas D, Lancon A, Colin D, Jannin B and Latruffe N. (2006): Resveratrol as a chemopreventive agent: a promising molecule for fighting cancer. *Curr Drug Targets.*;7:423–42.
 12. De la Lastra CA, and Villegas I.(2007): Resveratrol as an antioxidant and pro-oxidant agent: mechanisms and clinical implications. *BiochemSoc Trans.*; 35:1156–60.
 13. Leonard S., Xia C., Jiang B. H. *et al.*, (2003): “Resveratrol scavenges reactive oxygen species and effects radical-induced cellular responses,” *Biochemical and Biophysical Research Communications*, vol. 309, no. 4, pp. 1017–1026,.
 14. Brittes J, Lúcio M, Nunes C, Lima JL, Reis S. (2010): Effects of Resveratrol on membrane biophysical properties: relevance for its pharmacological effects. *ChemPhys Lipids*; 163: 747–754. *Cell Apr 17*; 69(2):367-374.
 15. Chang CC, Chang CY, Huang JP, Hung LM. (2012): Effect of Resveratrol on oxidative and inflammatory stress in liver and spleen of streptozotocin-induced type 1 diabetic rats. *Chin J Physiol*; 55:192-20.
 16. Das S, Das DK. (2007): Anti-inflammatory responses of Resveratrol. *Inflamm Allergy Drug Targets.*;6:168–73.
 17. KeirnanJA(2015): *Histological and histochemical methods, theory and practice.* 5 ed. : Scion Publishing Limited Press;
 18. Jiang Y., Peng T., Y. Luo, M. Li, and Y. Lin, (2008): “Resveratrol reestablishesspermatogenesis after testicular injury in rats caused by 2,5-hexanedione,”*Chinese Medical Journal*, vol. 121, no. 13, pp. 1204–1209,.
 19. Das S, Das DK. (2007): Resveratrol a therapeutic promise for cardiovascular diseases. *Recent Pat Cardiovasc Drug Discov.*;2:133–8.
 20. Reddy, R.G. (2010): Aung T, Karavitaki N, Wass JAH. Opioid induced hypogonadism. *BMJ.*, 341:605–606.
 21. El Sawy, M. M. and Abdel Malak H.W. (2015): Effect of tramadol abuse on testicular tissue of adult albino rats: a light and electron microscopic study. *The Egyptian Journal of Histology*, 38:356-366
 22. Salah, S., Wagih M., Zaki A., Fathy, W. and Eid, A. (2019): Long-term effects of tramadol on the reproductive function of male albino rats: an experimental biochemical and histopathological study. *Middle East Fertility Society Journal*, 24:3 pages; 1-6.
 23. Fikriye, Y. Ö., Orhan, Ö., Semra, Y., Çiğdem, Ç. Ü. and Kevser, E. (2017): Protective role of Resveratrol on testicular germ cells in mice with testicular toxicity. *Turk J Urol*; 43(4): 444-50.
 24. Youssef, H. S., and Ziadan, H. M. (2016):. *Histopathological and Biochemical Effects of Acute & Chronic Tramadol drug Toxicity on Liver, Kidney and Testicular Function in Adult Male Albino Rats.*
 25. Kasdallah-Grissa A, Mornagui B, Aouani E, Hammami M, Gharbi N, Kamoun A, *et al.* (2006) : Protective effect of Resveratrol on ethanol-induced lipid peroxidation in rats. *Alcohol Alcohol*;41:236-9
 26. Samy M Eleaw, Mahmoud A Alkhateeb, Fahaid H Alhashem, Ismaeel Bin-Jaliah, Hussein F Sakr, Hesham M Elrefaey,etal (2014): Resveratrol Reverses Cadmium Chloride-Induced Testicular Damage And Subfertility By Downregulating P53 And Bax And Upregulatinggonadotropins And Bcl-2 Gene Expression. *Journal Of Reproduction And Development*, Vol. 60, No 2.
 27. Fukui M, Yamabe N and Zhu BT. (2010): Resveratrol attenuates the anticancer efficacy of paclitaxel in human breast cancer cells in vitro and in vivo. *Eur J Cancer* ; 46: 1882-1891.
 28. Lagouge M, Argmann C, Gerhart-Hines Z, Meziane H, Lerin C, Daussin F, Messadeq N, Milne J, Lambert P, Elliott P, Geny B, Laakso M, Puigserver P and Auwerx J. (2006):Resveratrol improves mitochondrial function and protects against metabolic disease by activating SIRT1 and PGC-1 α . *Cell*; 127: 1109–1122.
-

29. Avdatek, F., Birdane, Y.O., Turkmen, R., Demirel, H.H. (2018): Ameliorative effect of resveratrol on testicular oxidative stress, spermatological parameters and DNA damage in glyphosate-based herbicide-exposed rats. *Journal of Andrologia*. Volume 50, issue 7.
30. Osadolor H. B. and Omo-Erhabor J. A. (2016): Effects of Tramadol on Fertility Hormones (Follicle Stimulating Hormone, Leutinizing Hormone, Prolactin, Testosterone, Estrogen and β -HCG) in Laboratory Rabbits. *British Journal of Medicine & Medical Research* 14(8): 1-11.
31. Juan ME, González-Pons E, Munuera T, Ballester J, Rodríguez Gil JE, and Planas JM. (2005): Trans-Resveratrol, a natural antioxidant from grapes, increases sperm output. *J Nutr*; 135:757-60.
32. Ahmed MA, Kurkar A. (2014): Effects of opioid (tramadol) treatment on testicular functions in adult male rats: The role of nitric oxide and oxidative stress. *Clin Exp Pharmacol Physiol*; 41:317–323.
33. El-Gaafarawi I.I. (2006): Biochemical toxicity induced by Tramadol administration in male rats. *Egypt J Hosp Med.*, 23:353–362.
34. Sharma P, Hug AU and Singh R. (2014): Cypermethrin-induced reproductive toxicity in the rat is prevented by Resveratrol. *J Hum Reprod Sci*; 7:99-106.