



REVIEW ARTICLE

Evaluation of Bone Fusion and Clinical Outcome of a Stand-Alone Polyether Ether Ketone Cage Filled with Biphasic Calcium Phosphate Used in One Level Anterior Cervical Discectomy and Fusion

Ashraf El Desouky zaghoul¹; Mohammed Hammad Eltantawy²; Ahmed A. Arab³

1)Neurosurgery Department , Benha Faculty of Medicine, Benha University ,Egypt

2)Neurosurgery Department, Benha Faculty of Medicine, Benha University, enha city, Egypt

3)Neurosurgery Department, Benha Faculty of Medicine, Benha University, Benha city, Egypt

*Corresponding author:

Ashraf El-Desouky, MD,
Associate prof. of neurosurgery,
Department of Neurosurgery
,Benha faculty of Medicine,
Benha university, Benha Egypt

E-mail:

ashrafeldesouky73@gmail.com

Submit Date 2020-10-08

Revise Date 2020-11-16

Accept Date 2020-12-22

ABSTRACT

Background; Although autologous bone grafts harvested from iliac crest were used since the early days of ACDF, they caused donor site morbidities. PEEK cages used in cervical spine surgeries on a wide scale with controversy of their filling material.

This study is to evaluate bone fusion and clinical outcome of one level ACDF using stand-alone PEEK cage filled with Biphasic Calcium Phosphate granules in treatment of degenerative CDD

Methods: A prospective study, where patients with single level degenerative CDD, underwent ACDF using our technique from April 2017 to April 2019 with one year follow up. Preoperative and one-year postoperative Visual Analog Scale (VAS) for neck pain and arm pain assessed. One-year postoperative Odom clinical outcome scoring system, Patient Satisfaction Index (PSI) and bone fusion assessed. Bone fusion considered successful if bridging bone incorporating graft and adjoining vertebral endplates was apparent.

Results: 19 patients included, 14 female patients (73.68%) and 5 male patients (26.32%). The preoperative mean VAS for neck pain and arm pain improved from 7.37 ± 1.74 and 7.96 ± 1.24 to 2.95 ± 1.27 and 2.21 ± 1.01 respectively. This difference found statistically significant. According to Odom scoring system, 15 patients (78.95%) had excellent outcome and 4 patients (21.05%) had good outcome and by using PSI, 16 patients (84.21%) were grade 1 and 3 patients (15.79%) were grade 2. 17 patients (89.47 %) showed bone fusion, while 2 patients (10.53 %) showed non-union.

Conclusion: we found our technique safe and effective alternative with bone fusion and clinical outcome comparable to those of other options.

Key words; Anterior cervical discectomy; PEEK cage; Biphasic calcium phosphate.



INTRODUCTION

In the cervical spine, Spondylosis is the most common cause of neural dysfunction. It may cause compression of the cervical neural axis to present as neck pain, radiculopathy, myelopathy or radiculomyelopathy. Conservative management is the preferred and often only required intervention, while surgery is indicated in unresponsive patients.[1] For the surgical treatment of cervical disc disease, anterior cervical discectomy and fusion (ACDF) is the gold standard. Since this technique is originally described by Smith and Robinson, many modifications of it have been reported. [2] The anterior approach has many advantages including minimal injury of soft tissue,

decompression of the spinal cord and nerve roots under direct visualization, complete removal of degenerative disc and facilitate fusion through access to two vertebral endplates with a considerable surface area.[3] The success of this technique relies on thorough decompression and the development of solid bony fusion.[4] Although complications are rare the most commonly occurring problems are dysphagia, wound hematoma and recurrent laryngeal nerve palsy.[5] Bone grafts and bone graft substitutes can be osteoconductive, osteo-inductive, or osteogenic or have some combination of these properties. Autologous bone grafts work by all three mechanisms.[6] In the early days of ACDF,

autologous bone grafts from the iliac crest were used. [7]. Although autograft remains the gold standard in ACDF, harvest of the graft can cause complications and morbidity, namely donor site pain, hematoma, numbness and infection. [8,9] In the efforts to circumvent the need for autograft, allograft gained popularity but it has its complications e.g. the risk of infection, disease transmission, and possible histocompatibility differences. [10] So, the goal behind the creation of intervertebral cages with bone graft substitute technologies has been developed to minimize or eliminate complications related to the use of autograft and allograft with improving clinical outcomes. [11] Many synthetic materials have been used such as titanium cages, carbon cages, and Polyether Ether Ketone (PEEK) cages. [12] Cervical cages give instant stability and enlarge neural foraminal space. [13] In 1990s PEEK cage was introduced and due to its radiolucency which permits easy evaluation of fusion and its equivalent stiffness to bone, they used in cervical spine surgeries on a wide scale. [14] PEEK itself is inactive and has no ability to connect to bone, Thus PEEK was filled with other substances to encourage new bone formation from bony walls which achieves implant fusion in little time. [15] A few surgeons have used the implantation of an empty cage during the ACDF; however, they have not reached a general agreement due to suspicion of low bone fusion rate. [16]

The aim of the present study is to evaluate the bone fusion and clinical outcome of one level ACDF using a stand-alone PEEK cage filled with BCP granules to test efficacy of the technique we use in our institution in treatment of single level degenerative cervical disc disease

METHODS

Study design: this is an observational prospective clinical study

This study included all patients admitted to Neurosurgery Department of Benha University Hospital with single level degenerative CDD who underwent ACDF using a stand-alone (non-platted) PEEK cage (Amseo medical industries^{MT} Egypt) filled with Biphasic Calcium Phosphate (BCP) granules (BCP BiCalPhos 60%HA+40%TCP granules: Medtronic Sofamor Danek USA Inc.) as synthetic bone graft substitute for interbody fusion from April 2017 to April 2019 with one year follow up for clinical and bone fusion evaluation. All included patients had single level CDD on preoperative MRI cervical spine causing radiculopathy or radiculo-myelopathy and unresponsive to at least three months of conservative treatment before surgery. For all

included patients, history was taken in details and full neurological examination.

Exclusion criteria:

the patients with more than one level CDD, the patients with traumatic CDD, patients operated upon using other bone graft materials e.g. autologous iliac crest graft or local bone graft, using plate system and patients underwent previous cervical disc surgery at another level, were all excluded from our study.

For clinical evaluation of our patients, we used the following 3 parameters;

Firstly, we asked them to quantify their pain pre-op. and one-year post-op. on a Visual Analog Scale (VAS) for neck pain and arm pain ranging from 0 (no pain) to 10 (worst pain) and regarding arm pain we recorded VAS score for every complaining arm.

Secondly, the patients were evaluated at one-year post-op. according to Odom's criteria for their overall clinical outcome. [17] Excellent outcome was considered if there was no complaint referable to cervical disease and the patient was able to perform the daily occupation with no impairment. Good outcome, when there was intermittent discomfort referable to cervical disease but without significant interference with work. Fair outcome, when there was subjective improvement in symptoms with the physical activity significantly impaired and finally, poor outcome when there was worsening or no improvement of clinical status.

Thirdly, we used the Patient Satisfaction Index (PSI) as described by Palit et al. [18], to evaluate the patient's satisfaction with their procedure at one-year post-op. We asked our patient if surgery met his expectations (grade 1), if he would undergo the same operation for the same results although he did not improve as much as he hoped (grade 2), if surgery helped him but he would not undergo same surgery for same outcome (grade 3), or if he is the same or worse as compared to before surgery (grade 4).

For evaluation of bone fusion, we had pre-op. plain X-ray of cervical spine (A-P and lateral) and post-op. follow up plain X-ray (A-P and lateral) before the patients were discharged, then at 3 months, 6 months and 12 months post-op. on their routine follow up.

Bone fusion considered successful if bridging bone incorporating the graft and adjoining vertebral endplates was apparent, with loss of radiolucency at the bone-graft interface in lateral plain X-ray of cervical spine obtained one year after surgery. [19] This assessment was done and approved by the 3 participating authors for all included patients. CT scan was planned only if there was potential for nonunion, in cases of unexpected/poor clinical

outcomes and/ or recurrence of symptoms during follow up to verify fusion at the operated level, Bartels et al 2010.[20]

Surgical procedure: During surgery discectomy was performed under the operating microscope using a scalpel, rongeurs, and curettes and removal of posterior osteophytes were performed thereafter. We carefully opened and resected the posterior longitudinal ligament to enable good visualization of the dura and the nerve root origins. To optimize the vertebral bone-graft interface, decortication of the vertebral endplates was performed. Optimal size of PEEK cage was selected with help of a trial cage inserted to confirm the height of the disc space. Inner cavity of PEEK cage was filled with BCP then was inserted using forceps and tapped into place. Lateral fluoroscopy was performed before closure for optimal PEEK cage position, then good hemostasis, closure in layers over a drain to be removed 24 hours after surgery, Patients were allowed to stand the day after surgery and a hard neck collar worn for 6 weeks postop. The patients were allowed to take off neck collar at bed time. Patients were discharged from hospital within 2-3 days after surgery after initial clinical evaluation and only after doing follow up X-ray A-P and lateral views, normal activity was progressively resumed as tolerated.

Informed consent and ethics committee approval: This research has given approval by Research Ethics Committee (REC) of Benha faculty of medicine, Benha University. A written informed consent was obtained from each patient after explaining all steps of this study. All procedures performed involving human participants were in accordance with the ethical standards of the institutional and/or national research committee and with the 1964 Helsinki declaration and its later amendments or comparable ethical standards.

Statistical analysis : The collected data were described in terms of mean ± Standard Deviation (SD) and range for quantitative data, while for qualitative data described as frequency and percentage. Pre-operative VAS scores for neck pain and arm pain were compared against one-year post-operative scores using paired t-test. Improvement rates were calculated as percentage of VAS scores changes in relation to pre-operative scores. Statistical significance accepted at P 0.05 <. Statistical analyses carried out using STATA/SE version 11.2 for Windows (STATA corporation, College Station, Texas).

RESULTS

From April 2017 to April 2019, 22 patients were operated upon according to the inclusion criteria of this study, 3 patients of them were lost to follow up so only data and results of the remaining 19 cases were analyzed. Table 1 shows the demographic and baseline clinical characteristics of the studied patients. 10 patients were operated at C5-6 level which was the most frequent level operated upon and all 19 cases were intact regarding sphincteric function, as for associated comorbidities, we had 3 patients with DM, 2 patients are hypertensive, one patient known to be hypertensive and diabetic and 3 other patients are smokers all patients showed improvement in their symptoms after surgery. 3 patients of the 4 with pre-op. motor weakness improved to full motor power within 3 months of post-op. physiotherapy while the fourth patient had same motor power as before surgery unchanged during follow up.

Table 2 shows differences in pre and 1-year post-operative neck pain VAS scores. Statistically this difference was found significant at P<0.001 (Figure 1A). Similarly, Table 3 and Figure 1B show Statistically significant reduction in VAS scores for arm pain (radiculopathy) 1-year post-operative as compared to pre-operative.

Table 4, shows the clinical outcomes according to the Odom clinical outcome scoring system and the patient satisfaction index recorded at 1-year post-op.

Of the operated 19 levels and according to lateral radiographs obtained one year after surgery, 17 levels (89.47 %) showed bony fusion according to study criteria, while 2 levels (10.53 %) showed non-union. The two patients with non-union, one of them had excellent outcome and the other one had good outcome according Odom’s criteria and because of such clinical outcomes, additional surgery was not planned.

Regarding post-operative complications, one patient (5.26%) who was operated at C6-7 level had post- operative hoarseness of voice improved gradually to normal in 3 months after surgery. Four patients (21.05%) reported postoperative mild dysphagia and discharged from hospital after 3 days as they improved gradually, and dysphagia disappeared completely within two weeks post-op. and we think this was secondary to retraction. No new neurologic deficit, no wound infections and no patients needed revision surgeries during the follow-up period of our 19 cases.

Table 1: The study population, demographic and clinical characteristics

Total number=19	No.	%
-----------------	-----	---

Gender	Female	14	73.68
	Male	5	26.32
Age (years)	Mean \pm SD; (range)	45.21 \pm 8.22; (34-61)	
Operated level	C3-4	2	10.53
	C4-5	4	21.05
	C5-6	10	52.63
	C6-7	3	15.79
Motor weakness	present	4	21.05
	No weakness	15	78.95
Indication of surgery	Unilateral radiculopathy	5	26.31
	Bilateral radiculopathy	8	42.11
	Radiculomyelopathy (with unilateral radiculopathy)	4	21.05
	Radiculomyelopathy (with bilateral radiculopathy)	2	10.53

Table 2: Differences in pre and 1-year post-operative neck pain VAS scores

No.=19	Neck pain VAS scores		Paired t-test	P
	Mean \pm SD	Range		
Pre-operative	7.37 \pm 1.74	4-10	9.87	<0.001
One-year post-operative	2.95 \pm 1.27	1-6		
Improvement rate (%)	59.01 \pm 17.28	25-90		

VAS: Visual Analog Scale; SD: Standard Deviation; P: Probability

Table 3: Differences in pre- and 1-year post-operative arm pain VAS scores

No.=29*	Arm pain VAS scores		Paired t-test	P
	Mean \pm SD	Range		
Pre-operative	7.96 \pm 1.24	6-10	21.31	<0.001
One-year post-operative	2.21 \pm 1.01	1-4		
Improvement rate (%)	71.87 \pm 13.79	33.33-88.89		

*10 patients had bilateral arm pain

VAS: Visual Analog Scale; SD: Standard Deviation; P: Probability

Table 4: 1-year post-operative clinical outcomes

Total number=19		No.	%
Odom clinical outcome scoring system	Excellent	15	78.95
	Good	4	21.05
Patient satisfaction index	Surgery met patients 'expectations (grade 1)	16	84.21
	Did not improved as much as hoped, but would undergo the same operation for the same results. (grade 2)	3	15.79

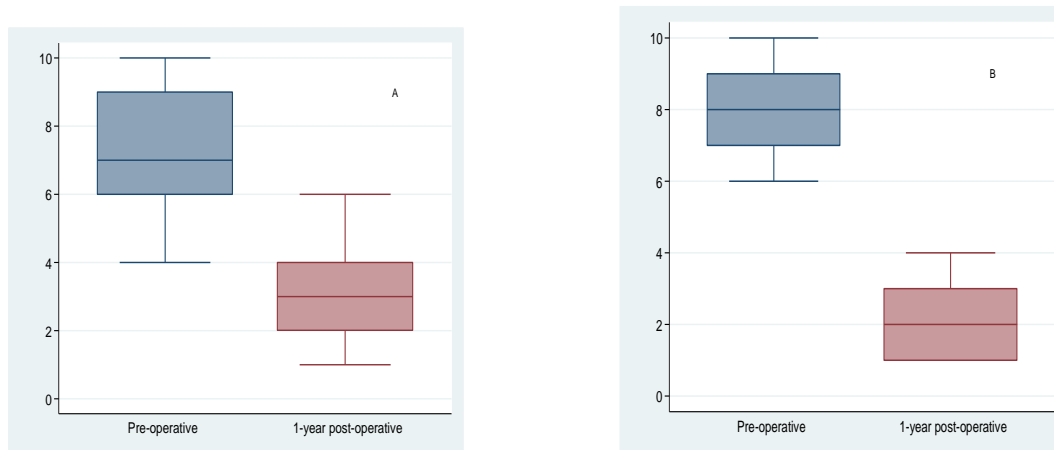


Figure 1: Comparison of pre and 1-year post-operative neck pain VAS scores (A) and arm pain VAS scores (B)
VAS: Visual Analog Scale

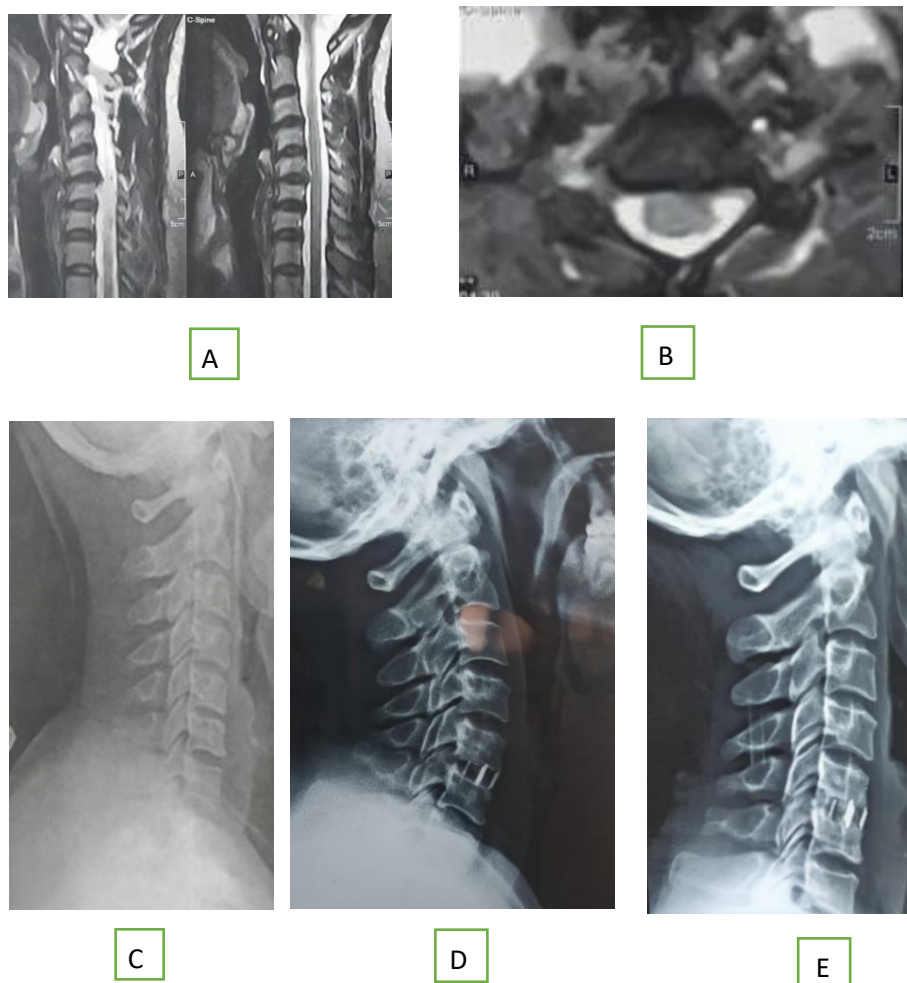


Figure 2: Female patient, 40 years old, with left radiculopathy not responding to conservative management.
* MRI sagittal T2-WI (A) and axial T2-WI (B) showing C5/6 left posterolateral disc protrusion on top of diffuse disc bulge obliterating the anterior subarachnoid space and compromising the left neural exit pathway.
** Plain X-ray lateral views, pre-op; obliterated disc space at C5/6 (C), 24 hours after surgery; peek cage filled with BCP with restoration of disc space height (D), 12 months post -op; bone fusion seen inside the cavity of the cage adjoining the adjacent vertebral endplates with loss of radiolucency at bone-graft interface (E)

DISCUSSION

The creation of intervertebral cages with bone graft substitute technologies has been developed to minimize or eliminate complications of the use of autograft and allograft with the aim of improving clinical outcomes.[11]

Silber et al., evaluated iliac crest bone graft site morbidity in 1-level ACDF, they found that 26.1% of patients had pain at donor site, and 15.7% had numbness. Other complications, which occurred at lower rates, including bruising, hematoma, pelvic fracture, and poor cosmesis. Also, osteoporosis and comorbid conditions made it a challenge to acquire iliac crest autograft, contributing to the popularity of alternative substrates. [21]

There are various types of cervical cages, and various materials are used for filling the cages, controversy exists regarding the type of filling material in the cage. [22] several acceptable and promising graft options for ACDF have been studied for their effectiveness but currently no option is conclusively superior to autograft and this partly due to shortcomings in the literature, as many studies had suboptimal study design, e.g. were small, retrospective, or non-randomized and also, there is no standard criteria for evaluating radiographic bony fusion and clinical outcome which creates heterogeneity of studies.[23] These inconsistencies made direct comparative analysis very difficult.

And also from review of literature,[22,24 , 25] regarding one level ACDF we can notice that there is no general consensus regarding the type of cervical cage and the material that could be used for filling the cage that might be autograft , allograft, or synthetic bone graft substitute, there are many options, and we found the studies comparing these constructs are lacking, also using anterior plate or not in one level ACDF remains debatable, and now how all these variables including different types of cervical cage ,different graft options for filling the cage and use or not of anterior plate instrumentation in one level ACDF could be reflected on the radiological results and most importantly on clinical outcome of the patients remain questionable for further ongoing clinical investigation.

Many studies define success using radiographic parameters, but it is important to note that these do not necessarily correlate to clinical outcomes. [26] Evaluation of interbody fusion remains a challenge and there are no universally accepted criteria for determining radiological fusion.[27]

we considered bone fusion successful if bridging bone incorporating the graft and adjoining vertebral endplates was apparent, with loss of radiolucency at the bone-graft interface in lateral

plain X-ray cervical spine obtained one year after surgery.[19] This assessment was done and approved by the 3 participating authors for all included patients.

As CT scanning at regular follow up visits for routine evaluation of bone fusion was deemed to be unnecessary, costly and potentially harmful to patients, CT scan was planned only for cases of unexpected/poor clinical outcomes and/ or recurrence of symptoms to verify the fusion at the operated level, [20] and because of this and our satisfactory clinical outcome, we didn't need to do post-operative CT scan. We agree that this may result in a higher apparent fusion rate.

one-year post -op., all patients showed variable degree of improvement in their symptoms and had no new neurologic deficit. 3 patients of the 4 with pre-op. motor weakness improved to full motor power while the fourth patient had same motor power as before surgery unchanged during follow up.

The pre-op. mean VAS for neck pain was 7.37 ± 1.74 and one-year post-op. was improved to 2.95 ± 1.27 . This difference was statistically significant at $P < 0.001$. Similarly, we found statistically significant reduction in VAS scores for arm pain 1-year post-op. as compared to pre-op. (7.96 ± 1.24 vs. 2.21 ± 1.01 ; $P < 0.001$). The average improvement rate was 59.01% (± 17.28) for neck pain and 71.87% (± 13.79) for arm pain.

15 patients (78.9%) had excellent outcomes and 4 patients (21.05%) had good outcomes according to the Odom clinical outcome scoring system, and by using the Patient Satisfaction Index (PSI). 16 patients (84.21%) stated that Surgery met their expectations and 3 patients (15.79%) reported that they did not improve as much as they had hoped but they would undergo the same operation for the same results.

one year after surgery, 17 levels (89.47 %) of the operated 19 levels showed bone fusion according to our study criteria, while 2 levels (10.53 %) showed nonunion. The two patients with non-union, one of them had excellent outcome and the other one had good outcome and because of that, additional surgery was not planned.

Although, nonunion has been reported as complication of ACDF using stand-alone cages, the use of a stand-alone cage has become popular, and many reports have described its effectiveness such as stability, restoration of the disc height, and facilitation of bone fusion [7,28,29]

Here we present some clinical trials studied ACDF, although they have used different alternatives for filling standalone cervical cages, the results of our study are comparable to their bone fusion results and clinical outcome.

Bartels et al., reported that after using of stand-alone cages packed with autologous cancellous iliac crest, nonunion occurred in 4.3%. [30] In a similar study of stand-alone cage packed with cancellous iliac bone graft by Yang et al, they reported that nonunion occurred in 14.9% [29] However, according to their reports, in spite of the risk of nonunion, clinical outcomes were good in the nonunion groups.

A stand-alone cage filled with local auto-graft has been used recently for ACDF with favorable results. [7,29]. However, nonunion was reported as a complication of this procedure. [31,32]

According to Shad et al, ACDF with a stand-alone cage packed with local bone graft has good clinical and radiological outcomes without iliac donor site morbidity and high additional costs.[24] In the study by Park et al., they did single level ACDF using a stand-alone PEEK cage packed with local auto-bone in treatment of degenerative cervical disc disease, a bone fusion rate (90.3%) was achieved, and despite the occurrence of nonunion, clinical outcomes of all patients with nonunion were excellent or good, according to Odom's criteria, thus additional surgery was not performed.[33] our results are similar to park et al., with bone fusion rate 89.47% and excellent to good clinical outcome although we used BCP as a filling material of stand-alone peek cage.

The anterior plate has several advantages in ACDF as it increase stability, prevent extrusion of the graft and increase fusion rate, but it has high additional costs and risk of hardware failure.[25] Although anterior plate fixation enhances the fusion rate in multilevel ACDF, debate exists regarding efficacy of non-plating to plating fixation in one-level ACDF.[15]

The fusion rates of single level ACDF at 1-year follow up are 97.1% in patients treated with anterior plates and 92.1% in patients treated with non-platted fusion according to a 2007 meta-analysis.[23]

in the study by Pitzen et al, they reported 91.3% fusion rate, using local auto-bone grafts and anterior plate system.[25] on the other hand Park et al, after single level ACDF using a stand-alone PEEK Cage packed with local auto-bone reported a comparable fusion rate (90.3%) without using plate system along with excellent or good clinical outcomes.[33] Also, our fusion rate and clinical results are similar to park et al., although we used BCP as a filling material Wright, et al. studied one level ACDF without instrumentation using a tricortical autogenous iliac crest bone block inserted under compression and postoperative semirigid neck collar for 2 months. They reported that in 54 patients, there were 6 pseudarthroses

(11%).[34] This is similar to nonunion rate in our study (10.52%) meanwhile we avoided possible donor site complications.

Samartzis et al., reviewed 69 patients who underwent one-level ACDF with autograft, with and without anterior cervical plate fixation and they reported 100% and 90.3% fusion rates for non-plated and plated ACDF procedures respectively. Excellent and good clinical outcome results were obtained for 91.3% of all included patients in their study. Both non plating and plate fixation for ACDF has a high fusion rate and yields a satisfactory clinical outcome. They concluded that solid bone fusion can be adequately obtained without plate fixation and so instrumentation-related complications can be avoided.[35]

The main limitations of this study were the small number of patients included and short term follow up and these to be considered in future studies.

CONCLUSION

We hereby recommend using stand-alone PEEK cage filled with BCP in one level ACDF as a safe and effective alternative with bone fusion rate and clinical outcome comparable to those of other options currently in use for one level ACDF, meanwhile avoiding donor site complications as well as additional cost and possible risks of hardware failure of anterior plate.

List of Abbreviations:

BCP: Biphasic calcium phosphate

DM: Diabetes Mellitus

VAS: visual analogue score

MRI : magnetic resonant image

HTN : hypertension

ACDF: anterior cervical discectomy and fusion

PSI : patient satisfaction index

PEEK: Polyether Ether Ketone

CT : computerized tomography

HA : Hydroxyapatite

Disclosure of potential conflicts of interest

Declaration of interest and Funding information.: The authors report no conflicts of interest.

Authors' contributions: All authors have participated in the research and article preparation. All authors have read and approved the final article.

Authorship

All authors have made contributions to the following: (1) the conception and design of the study, acquisition of data, analysis and interpretation of data, (2) drafting the article and revising it critically for important intellectual content, (3) final approval of the version to be submitted.

ACKNOWLEDGMENT

We would like to thank Dr. Hanaa El-Sayed Bayomy, Associate Professor of Public Health and Community Medicine, Benha Faculty of Medicine, Benha University for great effort in accomplishing the statistical analysis of this study
www.bu.edu.eg & www.fac.bu.edu.eg

REFERENCES

1. Whitecloud TS: Modern alternatives and techniques for one-level discectomy and fusion. *Clin Orthop Relat Res.* 1999 Feb;(359):67-76.
2. Ba Z, Zhao W, Wu D, Shen B, Yu B, Wang Z: Box cages packed with local decompression bone were efficient in anterior cervical discectomy and fusion: five- to 10-year follow-up. *Spine (Phila Pa 1976)* 37: E1260-E1263, 2012
3. Thomas KA, Toth JM, Crawford NR, et al: Bioresorbable polylactide interbody implants in an ovine anterior cervical discectomy and fusion model: three-year results. *Spine*, 2008, 33: 734–742.
4. Elmeshtawy M, Elnady B, Hassan K, Ahmad H, Hassan M, Fouad M, Abo El-fadl A: Two or more levels anterior cervical discectomy and fusion (ACDF) using stand-alone PEEK cages filled with bone graft substitute. *Egy Spine J*, 2013 6:30-37.
5. Fountas KN, Kapsalaki EZ, Nikolakakos LG, et al: Anterior cervical discectomy and fusion associated complications. *Spine*, 2007, 32: 2310–2317.
6. Aghdasi B, Montgomery SR, Daubs MD, Wang JC: A Review of Demineralized Bone Matrices for Spinal Fusion: The Evidence for Efficacy. *The Surgeon* 2013 ,11:39-48.
7. Lee CH, Hyun SJ, Kim MJ, Yeom JS, Kim WH, Kim KJ, et al.: Comparative analysis of 3 different construct systems for single-level anterior cervical discectomy and fusion: stand-alone cage, iliac graft plus plate augmentation, and cage plus plating. *J Spinal Disord Tech* 2013 ,26: 112-118.
8. Chau AM, Mobbs RJ.: Bone graft substitutes in anterior cervical discectomy and fusion. *Eur Spine J*, 2009, 18: 449–464.
9. Silber JS, Anderson DG, Daffner SD, et al.: Donor site morbidity after anterior iliac crest bone harvest for single-level anterior cervical discectomy and fusion. *Spine (Phila Pa 1976)*. 2003;28(2):134-139.
10. Samartzis D, Shen FH, Goldberg EJ and Howard S: Is autograft the gold standard in achieving radiographic fusion in one-level anterior cervical discectomy and fusion with rigid anterior plate fixation? *Spine (Phila Pa 1976)*, 2005 Aug 1; 30 (15): 1756–1761.
11. Moreland DB, Asch HL, Clabeaux DE, et al: Anterior cervical discectomy and fusion with implantable titanium cage: initial impressions, patient outcomes and comparison to fusion with allograft. *Spine J*, 2004, 4: 184–191.
12. Thome C, Krauss JK, Zevgaridis D: A prospective clinical comparison of rectangular titanium cages and iliac crest autografts in anterior cervical discectomy and fusion. *Neurosurg Rev* 2004 ,27:34-41.
13. Kulkarni AG, Hee HT, Wong HK: Solis cage (PEEK) for anterior cervical fusion: preliminary radiological results with emphasis on fusion and subsidence. *Spine J*2007, 7: 205-209.
14. Torstrick FB, Safranski DL, Burkus JK: Getting PEEK to Stick to Bone: The Development of Porous PEEK for Interbody Fusion Devices. *Tech Orthop* 2017, 32:158-166.
15. Pan U, Chen Y, Shen Q: Flexural Mechanical Properties of Functional Gradient Hydroxyapatite Reinforced Polyetheretherketone Biocomposites. *Journal of Materials Science &Technology* 2016 ,32:4-40,
16. Pechlivanis I, Thuring T, Brenke C, Seiz M, Thome C, Barth M, et al.: Non-fusion rates in anterior cervical discectomy and implantation of empty polyetheretherketone cages. *Spine (Phila Pa 1976)* 2011 ,36: 15-20.
17. Odom GL, Finney W, Woodhall B.: Cervical disk lesions. *J Am Med Assoc*, 1958, 6: 23–28.
18. Palit M, Schofferman J, Goldthwaite N, et al: Anterior discectomy and fusion for the management of neck pain. *Spine*, 1999, 24: 2224–2228.
19. Gercek E, Arlet V, Delisle J, et al: Subsidence of stand-alone cervical cages in anterior interbody fusion: warning. *Eur Spine J*, 2003, 12: 513–516.
20. Bartels RH, Beems T, Schutte PJ, Verbeek AL.: The rationale of postoperative radiographs after cervical anterior discectomy with stand-alone cage for radicular pain. *J Neurosurg Spine*. 2010;12(3):275-279.
21. Silber JG 3rd, Johnson J.: Iliac crest autogenous bone grafting: donor site complications. *J South Orthop Assoc*. 2000;9(2):91-97.
22. Min WK, Bae JS, Park BC, Jeon IH, Jin HK, Son MJ, et al.: Proliferation and osteoblastic differentiation of bone marrow stem cells: comparison of vertebral body and iliac crest. *Eur Spine J* 2010, 19: 1753-1760.
23. Fraser JF, Hartl R.: Anterior approaches to fusion of the cervical spine: a meta-analysis of fusion rates. *J Neurosurg Spine*. 2007; 6:298–303.
24. Shad A, Leach JC, Teddy PJ, Cadoux-Hudson TA: Use of the Solis cage and local autologous bone graft for anterior cervical discectomy and fusion: early technical experience. *J Neurosurg Spine* 2005, 2: 116-122.
25. Pitzen T, Kiefer R, München D, Barbier D, Reith W, Steudel WI: Filling a cervical spine cage with local autograft: change of bone density and assessment of bony fusion. *Zentralbl Neurochir* 2006, 67: 8-13.
26. McConnell JR, Freeman BJC, Debnath UK, Grevitt MP, Prince HG, Webb JK.: A prospective randomized comparison of coralline hydroxyapatite with autograft in cervical interbody fusion. *Spine*. 2003; 28:317–323.
27. Carreon LY, Glassman SD, Djurasovic M.: Reliability and agreement between fine-cut CT scans and plain radiography in the evaluation of posterolateral fusions. *Spine J*, 2007, 7: 39–43.
28. Bartels RH, Donk RD, Feuth T: Subsidence of stand-alone cervical carbon fiber cages. *Neurosurgery* 2006, 58: 502-508.

29. Yang JJ, Yu CH, Chang BS, Yeom JS, Lee JH, Lee CK: Subsidence and nonunion after anterior cervical interbody fusion using a stand-alone polyetheretherketone (PEEK) cage. Clin Orthop Surg 2011, 3: 16-23.
30. Bartels RH, Donk R, van Azn RD: Height of cervical foramina after anterior discectomy and implantation of a carbon fiber cage. J Neurosurg 2001, 95: 40-42.
31. van Jonbergen HP, Spruit M, Anderson PG, Pavlov PW: Anterior cervical interbody fusion with a titanium box cage: early radiological assessment of fusion and subsidence. Spine J 2005 ,5: 645-649.
32. Kast E, Derakhshani S, Bothmann M, Oberle J: Subsidence after anterior cervical inter-body fusion. A randomized prospective clinical trial. Neurosurg Rev 2009 ,32: 207-214.
33. Park HW, Lee JK, Moon SJ, Seo SK, Lee JH, Kim SH: The efficacy of the synthetic interbody cage and grafton for anterior cervical fusion. Spine 2009, 34:591-595.
34. Wright IP, Eisenstein SM.: Anterior cervical discectomy and fusion without instrumentation. Spine (Phila Pa 1976). 2007 Apr 1;32(7):772-4.
35. Samartzis D, Shen F H, Lyon C, Phillips M, Goldberg E J, An H S.: Does Rigid Instrumentation Increase the Fusion Rate in One-Level Anterior Cervical Discectomy and Fusion? Spine j. Nov-Dec 2004;4(6):636-43

How to Cite:

zaghoul, A., Eltantawy, M., A.Arab, A. Evaluation of Bone Fusion and Clinical Outcome of a Stand-Alone Polyether Ether Ketone Cage Filled with Biphasic Calcium Phosphate Used in One Level Anterior Cervical Discectomy and Fusion. Zagazig University Medical Journal, 2022; (1505-1513): -. doi: 10.21608/zumj.2020.44417.1957